

# Frequency of Bone Marrow Involvement in Hodgkin's Lymphoma on First Presentation

Mohammad Nadeem<sup>1</sup>, Naeem Naqi<sup>1</sup>, Iftikhar Hussain<sup>2</sup>, Javeed Khattak<sup>1</sup>, Riaz Ahmed<sup>1</sup> and Badshah Khan<sup>1</sup>

## ABSTRACT

**Objective:** To determine the frequency of bone marrow involvement in patients of Hodgkin's lymphoma on first presentation at oncology department.

**Study Design:** Case series.

**Place and Duration of Study:** The Oncology Department, Combined Military Hospital, Rawalpindi, from April 2006 to February 2007.

**Methodology:** Thirty five patients of Hodgkin's lymphoma diagnosed on lymph node biopsy presenting for the first time at Oncology Department, Combined Military Hospital, Rawalpindi were included. They were admitted in the ward and evaluated with history, physical examination and staging investigations. Bone marrow trephine biopsy was performed in all patients. Descriptive statistics were used to analyze data.

**Results:** On clinical and radiological evaluation, 8 patients (22.9%) had clinical stage (CS), 12 (34.3%) had CS II, 9 (25.7%) had CS III and 6 (17.1%) had CS IV. The microscopic appearance in bone marrow trephine examination showed lymphoma infiltrates in 6 (17.14%) patients and chronic disorder in 29 (82.85%) patients. Among patients with bone marrow infiltration, one had CS II disease, three had CS III disease and two had CS IV disease. One patient had bone marrow infiltration as the only manifestation of disease.

**Conclusion:** Bone marrow involvement was seen in patients with Hodgkin's lymphoma clinical stage II or higher.

**Key words:** Hodgkin's lymphoma. Bone marrow infiltration. Trephine. Staging.

## INTRODUCTION

Hodgkin's lymphoma was first described by Thomas Hodgkin as a disease of the lymphoid tissue in 1832. The characteristic histological hallmark is the Reed-Sternberg cell which is clonal, confirming its origin from a single malignant cell.<sup>1</sup> The extent of disease determined at the time of diagnosis in the light of staging investigations is vital for planning correct treatment and prognosis. The recommended procedures for correct staging include detailed history and examination, blood chemistry, chest X-ray, computerized scan of thorax, abdomen and pelvis and a bone marrow biopsy.<sup>2</sup> Although the role of bone marrow aspirates and trephine biopsies is criticized by some authors and rendered controversial especially in early stage disease,<sup>3,4</sup> its value is regarded as irreplaceable in staging and in predicting the prognosis by others.<sup>5</sup> Bone marrow involvement represents stage IV of the disease i.e disseminated involvement. This was previously thought to be a poor prognostic factor.<sup>6</sup> Later on, it was shown that bone marrow involvement is not an independent

prognostic factor.<sup>7</sup> Nevertheless, at many centres, bone marrow examination remains a routine staging procedure for Hodgkin's lymphoma at the time of diagnosis.

Bone marrow examination is an invasive and painful procedure and many patients are reluctant to undergo this procedure. Especially in the early stage of the disease, when the involvement of bone marrow is negligible and the patient is planned for chemotherapy it has to be decided whether the patient should be persuaded to undergo this procedure. The present study was planned to determine the frequency of bone marrow involvement in patients of Hodgkin's lymphoma at the time of their first presentation.

## METHODOLOGY

This study was conducted at the Oncology Department, Combined Military Hospital, Rawalpindi, from April 2006 to February 2007. Thirty five consecutive patients aged 16-60 years with Hodgkin's lymphoma diagnosed on lymph node biopsy and presenting for the first time at Oncology Department were studied. Patients who had received chemotherapy for any malignancy previously, childhood cases (age less than 16 years) and older patients (more than 60 years) were excluded from the study.

At presentation, every patient was admitted to the Oncology Ward, Combined Military Hospital, Rawalpindi.

<sup>1</sup> Department of Oncology, Combined Military Hospital, Rawalpindi.

<sup>2</sup> Department of Medical Oncology, PNS Shifa Hospital, Karachi.

**Correspondence:** Lt. Col. Dr. Mohammad Nadeem, House No. 59, Askari-8, Chaklala Airport Road, Rawalpindi.

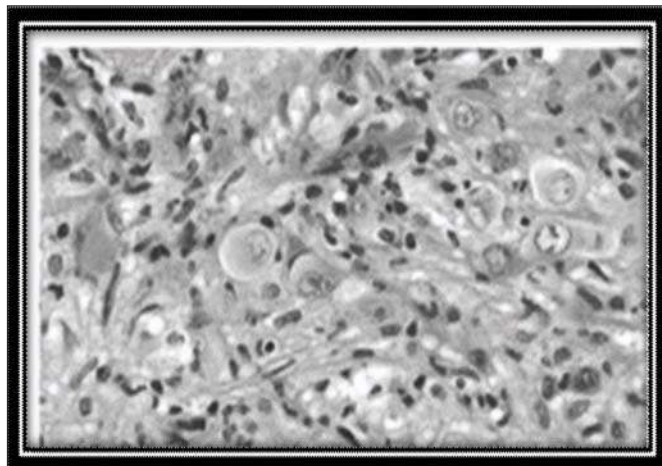
E-mail: [dr\\_nadeempiracha@hotmail.com](mailto:dr_nadeempiracha@hotmail.com)

Received July 31, 2007; accepted October 22, 2009.

A detailed history was recorded followed by a thorough physical examination especially focusing upon the presence of lymphadenopathy and hepatosplenomegaly, recording the size of each. This was followed by base line and staging investigations which comprised blood complete picture, serum urea and creatinine, liver function tests, chest X-Ray PA view/ computerized axial tomographic scan of thorax, ultrasound or computerized axial tomographic scan of abdomen and pelvis and serum LDH.

Bone marrow aspiration and trephine biopsy were performed in all patients from the posterior superior iliac spine by the standard technique after informed written consent. About 0.5-1 ml of aspirate was taken. Slide smears were made without delay and later on stained with Leishmann's stain. This was examined under the light microscope by a consultant hematologist. For bone marrow trephine, Jamshidi needle was used and a specimen measuring 1.5-2 cm was obtained which was fixed and embedded in paraffin. Later on, sections were stained with Hematoxylin and Eosin, Reticulin and Trichrome silver stains. The slides were examined by a consultant hematologist and histopathologist. It was ensured that the bone marrow smears and sections of trephine biopsies were examined by the same consultant hematologist and histopathologist respectively. No ethical issue was encountered in this study.

Bone marrow involvement in Hodgkin's lymphoma was defined as identification of mononuclear Reed-Sternberg cells or their variants in a cellular background of Hodgkin's lymphoma in routine paraffin embedded hematoxylin and eosin section of bone marrow trephine specimen examined under light microscope (Figure 1).<sup>8</sup>



**Figure 1:** Bone marrow trephine biopsy showing involvement by Hodgkin's lymphoma (Hematoxylin-Eosin, original magnification x 40).

The data was analyzed using statistical package SPSS version 11.0. Mean and standard deviations were calculated for numerical variables like age and body surface area. Frequencies (percentages) were calculated

for categorical variables like gender, stage of disease and frequency of involvement of bone marrow.

## RESULTS

Out of the 35 patients selected for the study, 25 (71.4%) were males and 10 (28.5%) were females. The mean age of the patients was 35 ± 13.0 years. The mean body surface area was 1.6 ± 0.18 m<sup>2</sup>. On clinical and radiological evaluation 8 (22.8%) had CS I, 12 (34.2%) had CS II, 9 (25.7%) had CS III and 6 (17.1%) had CS IV. Liver and spleen were the extranodal sites in CS IV disease. Mixed cellularity was the commonest histopathological type which was seen in 25 (71.4%) patients and lymphocyte depleted the least common seen in only 1 (2.8%) patient (Table I).

Microscopic examinations of bone marrow trephine showed lymphoma infiltrates in 6 (17.14%) patients and chronic disorder in 29 (82.85%) patients (Table II).

**Table I:** Frequency of different types of Hodgkin's lymphoma.

Histological type	Number of patients	Percentage
Mixed cellularity	25	71.4
Nodular sclerosis	9	25.7
Lymphocyte depleted	1	2.8

**Table II:** Frequency of bone marrow involvement.

Bone marrow status	Number of patients	Percentage
Bone marrow involved	6	17.14
Bone marrow not involved	29	82.85

However, none had positive corresponding bone marrow aspirate. One patient who had stage IIA disease was found to have bone marrow infiltrates on trephine biopsy, while three patients had CS III disease and two patients had CS IV disease. One of the patients who was being evaluated for pancytopenia had bone marrow infiltration with Hodgkin's lymphoma as the only manifestation of the disease. The histopathological type in three (50%) patients with bone marrow involvement was mixed cellularity. It was nodular sclerosis in two (33.3%) patients and lymphocyte depleted in one (16.6%) patient. Out of the 6 patients with bone marrow infiltration, 4 were restaged to stage IV disease after bone marrow examination i.e one from CS IIA, two from CS IIIA and one from CS IIIB. In two cases, the stage remained unchanged.

## DISCUSSION

The value of bone marrow examination in staging of Hodgkin's lymphoma is controversial especially in the early stage of the disease i.e. in patients with clinical stage IA or IIA disease the incidence has been reported to be < 1% in most series.<sup>9</sup> However, in patients with clinical stage IV disease, the presence of bone marrow infiltration has prognostic implications.<sup>6</sup>

In a study conducted at a regional centre in the UK,<sup>3</sup> among 955 cases of Hodgkin lymphoma, 5.2% patients had evidence of bone marrow involvement after trephine biopsy. All patients with bone marrow involvement had clinical stage IIB disease or higher. In another study conducted at Mexico, 91 patients with Hodgkin's lymphoma were assessed for bone marrow involvement which was found in 3.3% of cases who had clinical stage III disease.<sup>10</sup> In a large study reported from Italy, bone marrow involvement in Hodgkin's lymphoma was found to be 8% at diagnosis.<sup>11</sup> In an Indian study, 20% patients had bone marrow infiltration on bone marrow biopsies.<sup>12</sup> In the diagnosis of marrow involvement by Hodgkin's lymphoma, bone marrow aspirates should be avoided as they are reported to be positive in only 5% in one review<sup>14</sup> and 10%<sup>3</sup> in another study where the bone marrow biopsy showed infiltration by Hodgkin's lymphoma.

The frequency of bone marrow infiltration in this series was 17.4% (6 out of 35) which is slightly higher than the above quoted international studies but comparable to the regional data. As in the Indian study, all patients with bone marrow infiltration had positive trephine biopsies and unremarkable bone marrow aspirates showing that a biopsy is superior to an aspirate in detecting bone marrow involvement in Hodgkin's lymphoma.<sup>11</sup> This is also consistent with the findings from a large study from the USA.<sup>14</sup> The reason for a higher frequency in this series may be the late presentation of patients as the maximum number of patients with bone marrow infiltration had CS III disease. Among the patients with early stage disease in our series, only one patient with CS II disease was found to have bone marrow infiltration which upstaged his disease to stage IV and so his treatment plan was changed on this information.

No patient with CS I (A and B) was found to have bone marrow infiltration in this study. However, in a large study of 955 cases with 50 positive bone marrow biopsies, the disease was upstaged in thirty two patients but the treatment plan remained unchanged in all cases.<sup>3</sup> In this study, among patients with bone marrow involvement, mixed cellularity was the commonest histopathological type which was seen in 50% cases and this was also the commonest overall histological type seen in 74% patients. In the Mexican study, nodular sclerosis was the commonest histopathological type seen in 45% cases.<sup>10</sup> Similarly, nodular sclerosis was the commonest observed type in a study from Kuwait.<sup>15</sup> Among the patients with bone marrow involvement, the histology type commonly seen was lymphocyte depleted, quoted as 50-75% in one series.<sup>13</sup> Mixed cellularity histology type has been recognized as a risk factor for bone marrow involvement in an Italian study.<sup>11</sup> In this study, who was being investigated for pancytopenia one patient (2.8%) had bone marrow involvement as the only

manifestation of Hodgkin's lymphoma. This has been quoted as 5% in an Italian study and just 1% in another study.<sup>11,15</sup>

The risk factors associated with bone marrow involvement in Hodgkin's lymphoma and their impact on the treatment plan and prognosis of the disease was not studied. A Greek study has investigated and suggested a clinical prediction rule for bone marrow involvement in Hodgkin's lymphoma.<sup>16</sup> No local study is available on this subject till yet. Further local studies are required to find the important risk factors for bone marrow involvement in Hodgkin's lymphoma in our population, especially in the early stage of the disease when it would change the treatment plan.

## CONCLUSION

Bone marrow involvement in Hodgkin's lymphoma was maximum in CS II and beyond, therefore we recommend that bone marrow examination should be performed as a part of staging investigations in patients with Hodgkin's lymphoma when it is CS II or high.

## REFERENCES

- Stein H, Diehl V, Marafioti T. Hodgkin's disease. In: Mauch PM, Armitage JO, Diehl V, Hoppe RT, Weiss LM, editors. Hodgkin's disease. Philadelphia: *Lippincott Williams & Wilkins*; 1999: p.121-70.
- Armitage JO, Maugh PM, Harris NL, Bierman P. Non-Hodgkin's lymphoma. In: Devita VT, Hellman S, Rosenbergh SA, editors. Cancer: principles and practice of oncology. 6th ed. Philadelphia: *Lippincott Williams & Wilkins*; 2001: p. 2256-316.
- Howell SJ, Grey M, Chang J, Morgenstern GR, Cowan RA, Deakin DP, *et al.* The value of bone marrow examination in the staging of Hodgkin's lymphoma: a review of 955 cases seen in a regional centre. *Br J Hematol* 2002; **119**:408-11.
- Kanaev SV, Novikov SN, Zhukova LA, Pozharisskii KM, Leeman EE, Gershanovich ML. Risk factors for bone marrow involvement in Hodgkin's disease. *Vopr Onkol* 2001; **47**:39-44. Russian.
- Buhr T, Langer F, Schlue J, von Wasielewski R, Lehmann U, Braumann D, *et al.* Reliability of lymphoma classification in bone marrow trephines. *Br J Hematol* 2002; **118**:470-6.
- Specht L. Prognostic factors in Hodgkin's disease. *Semin Radiat Oncol* 1996; **6**:146-61.
- Hasenclever D, Diehl V. A prognostic score for advanced Hodgkin's disease. International prognostic factors project on advanced Hodgkin's disease. *N Engl J Med* 1998; **339**:1506-14. Comment in: p. 1547-9.
- Brunning RD. Bone marrow. In: Rosai J, Ackerman LV, editors. Surgical pathology. 4th ed. New Delhi: *Mosby & Elsevier*; 2004: 2047-99.
- Spector N, Nucci M, Oliveira DM, Maiolino A, Portugal RD, Costa MA, *et al.* Clinical factors predictive of bone marrow involvement in Hodgkin's disease. *Leuk Lymphoma* 1997; **26**:171-6.
- Gomez-Almaguer D, Ruiz-Arguelles GJ, Lopez-Martinez B, Estrada E, Lobato-Mendizabal E, Jaime-Perez JC. Role of bone marrow examination in staging Hodgkin's disease: experience in Mexico. *Clin Lab Haematol* 2002; **24**:221-3.

11. Levis A, Pietrasanta D, Godio L, Vitolo U, Ciravegna G, Di Vito F, *et al.* A large-scale study of bone marrow involvement in patients with Hodgkin's lymphoma. *Clin Lymphoma* 2004; **5**:50-5.
12. Ananthamurthy A, Kurien A, Ramnarayan K. The bone marrow in Hodgkin's disease: a two year experience. *Indian J Cancer* 2000; **37**(4):173-83.
13. Franco V, Tripodo C, Rizzo A, Stella M, Florena AM. Bone marrow biopsy in Hodgkin's lymphoma. *Eur J Haematol* 2004; **73**:149-55.
14. Moid F, DePalma L. Comparison of relative value of bone marrow aspirates and bone marrow trephine biopsies in the diagnosis of solid tumour metastasis and Hodgkin lymphoma: institutional experience and literature review. *Arch Pathol Lab Med* 2005; **129**:497-501.
15. Al-Shemmari SH, Al-Humood S, Ameen R, Kamlesh S, Nemej J, Varghese A. Hodgkins disease: Kuwait experience. *Med Princ Pract* 2004; **13**:201-5.
16. Doghmi K, Malfuson JV, El Ouennass M, Fagot T, Forel A, Branquet D, *et al.* Hodgkin's disease with bone marrow involvement. The role of positron tomography. *Presse Med* 2005; **34**:227-9. French.

.....★.....