

Review

Friend or foe: high bone mineral density on routine bone density scanning, a review of causes and management

Celia L. Gregson^{1,2}, Sarah A. Hardcastle¹, Cyrus Cooper² and Jonathan H. Tobias¹

Abstract

A finding of high BMD on routine DXA scanning is not infrequent and most commonly reflects degenerative disease. However, BMD increases may also arise secondary to a range of underlying disorders affecting the skeleton. Although low BMD increases fracture risk, the converse may not hold for high BMD, since elevated BMD may occur in conditions where fracture risk is increased, unaffected or reduced. Here we outline a classification for the causes of raised BMD, based on identification of focal or generalized BMD changes, and discuss an approach to guide appropriate investigation by clinicians after careful interpretation of DXA scan findings within the context of the clinical history. We will also review the mild skeletal dysplasia associated with the currently unexplained high bone mass phenotype and discuss recent advances in osteoporosis therapies arising from improved understanding of rare inherited high BMD disorders.

Key words: DXA, BMD, high bone mass, osteopetrosis, osteoarthritis.

Definition of high BMD

BMD measurement plays an important role in the assessment of osteoporosis and fracture risk. In clinical practice, BMD is most commonly measured using DXA. BMD is then compared against an age-, ethnicity- and gender-specific reference population to compute *T*- and *Z*-scores [number of standard deviations a measured BMD differs from the mean BMD of a young adult population (*T*-score) or age-matched population (*Z*-score)]. In 1994 the World Health Organization defined osteoporosis in terms of BMD and fracture, a *T*-score of ≤ -2.5 and/or a previous fragility fracture [1]. Equivalent definitions for high BMD do not currently exist. While low BMD relates to increased fracture risk, the converse may not hold for high BMD. As we will discuss, high BMD may occur in conditions (i) with increased fracture risk [e.g. osteopetrosis or Paget's Disease (PD)] or (ii) such as artefacts that themselves do not affect fracture risk but may mask low

BMD and (iii) where fracture risk may be reduced but other comorbidities may exist that are only starting to be recognized.

The absence of an upper limit for BMD may risk those with high BMD, potentially due to underlying pathology, being labelled as normal [2]. In 2005, Michael Whyte [2] advocated a high BMD definition as a *Z*-score $> +2.5$ to highlight to clinicians the potential for underlying pathology. Epidemiological studies of high BMD are few and definition thresholds variable [3, 4]. Until recently, high BMD was usually the reserve of case reports and case series. The first systematic analysis of patients undergoing routine clinical DXA scanning, encompassing 335 115 DXA scans across 15 UK centres, used a screening threshold *T*- or *Z*-score $\geq +4$ at any lumbar/hip site [5]. This study was the first to assess the prevalence of high BMD within the general population referred for DXA scanning.

Prevalence of high BMD

If BMD is normally distributed, then a threshold *Z*-score of $\geq +2.5$ should by definition identify 6.2/1000, and a more extreme *Z*-score $\geq +4$ would identify 3/100 000 [6]. In fact, based on assessment at 13 UK hospitals, 5/1000 NHS DXA scans have a *T/Z*-score $\geq +4$, approximately half of

¹Musculoskeletal Research Unit, School of Clinical Sciences, University of Bristol, Bristol and ²MRC Lifecourse Epidemiology Unit, University of Southampton, Southampton, UK.

Submitted 8 October 2012; revised version accepted 16 January 2013.

Correspondence to: Celia L. Gregson, Musculoskeletal Research Unit, University of Bristol, Avon Orthopaedic Centre, Southmead Hospital, Bristol BS10 5NB, UK. E-mail: celia.gregson@bristol.ac.uk

which are explained by artefactual elevations in BMD resulting from osteoarthritic degeneration. Of these incidental cases with high BMD, 35% had been referred due to a suspicion of osteoporosis and 22% because of an underlying medical condition necessitating bone assessment [5].

Causes of high BMD

While a finding of high BMD on conventional DXA scanning most commonly reflects degenerative disease, increases in BMD can also arise secondary to an underlying disorder with skeletal effects. Here we outline a classification for the causes of raised BMD seen on DXA scanning (summarized in Table 1).

Artefactual elevations in BMD measurements

Artefactually raised BMD values do not equate to a true increase in bone mass, but usually result from artefactual elevations in calcium content, which can be recognized by careful inspection of the DXA scan in the context of the clinical history; some examples are shown in Fig. 1. Artefact is important to differentiate, as it may mask osteoporosis.

Osteoarthritic spondylosis

Osteoarthritic spondylosis most commonly explains artefactual elevations in calcium content due to abnormally dense bone at the vertebral margins forming vertebral end-plate sclerosis, facet joint sclerosis and osteophytes (Fig. 1A). Facet joint OA is particularly marked in the lower lumbar spine, giving the recognized pattern of progressive osteoarthritic changes seen in sequential descending lumbar vertebrae, which correlates with rising BMD measures caudally down the spine [7]. Even mild osteophytosis can result in a 24% increase in lumbar BMD [8]. Osteoarthritic spondylosis accounts for 49% of T/Z -score $\geq +4$ on routine DXA assessments [5]. Conversely, osteoarthritic effects on femoral neck BMD are minimal [9].

In clinical practice, where osteoarthritic changes are restricted to one or two vertebrae, these are excluded and the lumbar spine DXA result is based on the mean value of unaffected vertebrae. Confirmatory radiographs are generally not required, as changes suggestive of spondylosis (e.g. end-plate sclerosis, preferential effects on lower lumbar vertebrae) are evident on DXA scan inspection, which may also reveal abnormalities underlying osteoarthritic changes (e.g. scoliosis).

Diffuse idiopathic skeletal hyperostosis

Diffuse idiopathic skeletal hyperostosis (DISH) is a skeletal disorder characterized by widespread calcification at spinal and extra-spinal sites. Although the aetiology is unknown, DISH has been associated with features of the metabolic syndrome [10, 11]. Ossification of spinal ligaments in DISH can overestimate vertebral areal BMD from 24% to 39% and may mask osteoporosis on DXA

scanning [12, 13]. Among older men, in whom DISH is common, DISH has been associated with increased vertebral fracture risk [14]. The prevalence of DISH rises sharply with age and varies according to ethnicity [15].

Ankylosing spondylitis

Syndesmophyte formation at vertebral margins in advanced AS can elevate spinal BMD by increasing calcium content [16]. This is compounded by anterior longitudinal ligament ossification, plus coexistent scoliosis and inflammation (Fig. 1B). Spinal DXA BMD measurements may therefore be high despite loss of trabecular bone resulting in increased fracture risk (particularly vertebral fracture) [17, 18]. Hip BMD is affected less by bony changes in AS and therefore hip DXA has been suggested as a more reliable method to assess fracture risk in these patients [17, 18].

Vertebral fracture

In vertebral fracture, bone mineral content is unchanged, but BMD increases due to a reduction in the denominator (i.e. vertebral area). Although absolute elevations in BMD may be modest, this mechanism is a common artefactual cause for BMD gain during serial DXA monitoring for osteoporosis [19]. Reduction in vertebral area contrasts with the normal finding of successive increases in vertebral area when moving down the spine. In clinical practice, affected vertebrae should be excluded from DXA analysis and mean BMD calculated from the remaining lumbar vertebrae. Although vertebral fractures can be detected by conventional lumbar DXA, vertebral height loss is more accurately quantified by lateral DXA [20]. Following vertebroplasty, polymethylmethacrylate cement will also elevate measured BMD.

Extrinsic artefacts

Calcification of structures anterior to the spine but within the DXA field can artefactually elevate BMD measurements. Although vascular calcification of the abdominal aorta is common, reported in 43% of patients having lumbar DXA assessment (mean age 68 years), there is little evidence from human studies that this significantly affects lumbar spine BMD measures [7, 8, 21–23]. Other radiodense materials can elevate BMD values. Soft tissue iron deposition in thalassaemia major, usually associated with osteoporosis, has been reported to lead to a T -score of up to +4.9 when, interestingly, the lateral DXA view showed the increased density to lie anterior to the vertebral body with the remaining vertebrae registering a T -score of +0.30, presumably representing soft tissue iron deposition [24]. Similarly, abdominal abscesses which can calcify [25], gallstones [26, 27], renal calculi [27] and gluteal silicon implants [28] have been linked to erroneously high BMD values. Gaucher's disease, with excess glycolipid within an overlying enlarged spleen, has been associated with high BMD, particularly at L1 (Z -score +3.8), despite coexistent low hip BMD, possibly reflecting the high glycolipid load or secondary calcification in the spleen [5]. Radiological barium administration

TABLE 1 Classification of the potential causes of a high BMD value detected by DXA scanning

Artefactual causes of raised BMD—no true increase in bone mass			
			OA DISH AS Vertebral fractures Vascular calcification Thalassemia major Abdominal abscesses Gallstones Renal calculi Gluteal silicon implants Gaucher's disease Intestinal barium Surgical metalwork Laminectomy Vertebroplasty and kyphoplasty
True causes of increased bone mass and density			
Localized	Acquired	PD ^a Hypophosphatasias ^a Tumours	Primary malignancies, e.g. osteoblastoma Secondary metastases, e.g. prostate Other tumours
		SAPHO syndrome Chronic infective osteomyelitis Osseous tuberous sclerosis	
Generalized	Acquired	Fluorosis Renal osteodystrophy Acromegaly Hepatitis C-associated osteosclerosis Myelofibrosis Mastocytosis Oestrogen replacement implants	
	Congenital	Reduced bone resorption (Table 2) Increased bone formation (Table 3) Disturbed formation and resorption (Table 3) Unexplained HBM	Osteopetrosis Pycnodysostosis Osteopoikilosis Melorheostosis Sclerosteosis van Buchem's disease LRP5 HBM LRP4 HBM Craniometaphyseal dysplasia Camurati-Engelmann disease Ghosal syndrome

^aMay be congenital.

into overlying bowel may falsely elevate BMD, though this has not been reported to date. Surgical metalwork explains 1.4% of incidental high BMDs on routine DXA scanning [5]. Laminectomy can also increase BMD values [29].

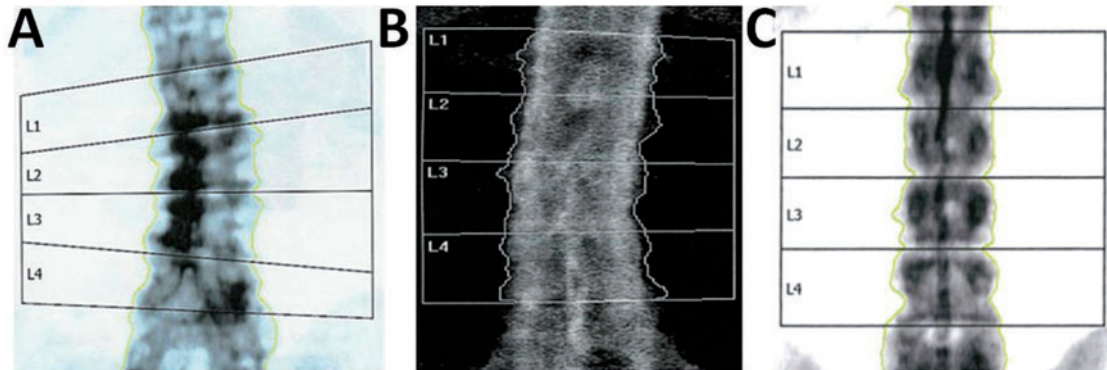
Focal abnormalities causing increased BMD measurements

Focal increases in bone mass can significantly alter BMD measurements. The abnormal site is usually restricted to

one or two specific vertebrae or a hip. However, multiple vertebral involvement can be difficult to distinguish from generalized causes described below.

Paget's disease

PD commonly affects the lumbar spine and hips and has a declining UK age-adjusted prevalence of 2.5% and 1.6% for men and women, respectively [30]. PD, often asymptomatic for many years before diagnosis, explains 1.4% of incidental high BMD values [5]. Excess disorganized woven and lamellar bone expands bone size and raises density,

Fig. 1 Examples of DXA images identified with a T/Z -score $\geq +4$.

(A) Artefactually raised lumbar spine BMD due to osteoarthritic spondylosis. **(B)** Artefactually raised lumbar spine BMD due to ankylosing spondylitis; anterior longitudinal ligament ossification is seen. **(C)** Generalized increase in lumbar spine BMD at all vertebral levels in a case of unexplained HBM.

increasing risk of deformity and fracture. PD may be monostotic (affecting an isolated vertebra) and, after the pelvis, most commonly affects lower lumbar vertebrae [31].

Tumours

Important not to miss, these most commonly occur as osteosclerotic secondary deposits from primary malignancies, e.g. prostate. Breast metastases classically cause osteolytic lesions, but can be osteosclerotic [32], as can gastric [33], colonic [34] and cervical [35] metastases. Increased BMD at an isolated vertebra can reflect a spinal osteoblastoma [36], Ewing's sarcoma [37], carcinoid [38], haemangioma [39] or plasmacytoma [40], both of which can calcify [41, 42], and Hodgkin's disease (5.8% of patients have spinal involvement, but osteosclerotic lesions are rarer than osteolytic) [43, 44]. Skeletal complications of radiotherapy can increase BMD, e.g. pathological fractures and secondary neoplasms. However, spinal osteoradionecrosis does not generally increase BMD, as marrow is replaced by lower density fat [45].

Tuberous sclerosis

Tuberous sclerosis is a rare, autosomal dominant disorder (OMIM 191100) of dysfunctional hamartin and tuberin production, with skeletal manifestations including bone cysts, skull and digital sclerosis and scoliosis [46]. Cortical thickening and increased bone density have been reported on plain radiographs, but DXA values have not been evaluated [47]. Learning difficulties, seizures, cardiac rhabdomyomas, haematuria from renal angiomyolipomas and dermatological features manifest variably [48].

SAPHO syndrome

SAPHO syndrome is rare, poorly understood and possibly explained by infection (*Propionibacterium acnes*). With features similar to the SpAs, up to half of patients suffer vertebral involvement (more frequently thoracic than lumbar) including osteosclerosis, hyperostosis, paravertebral ossification and rarely vertebral collapse [49, 50].

Case series focus on MRI and CT assessment rather than DXA, but BMD is likely to be elevated.

Generalized abnormalities causing high BMD measurements: acquired

Osteosclerosis (Greek etymology: osteo—bone, sclerosis—hardening of a tissue) generally occurs diffusely within the axial skeleton, although focal patterns may also occur secondary to exaggerated trabecular and/or cortical bone formation.

Fluorosis

Fluoride causes diffuse axial osteosclerosis with ligamentous calcification, periostitis and vertebral osteophytosis and has been associated with excessive tea and toothpaste consumption and was historically trialled as an osteoporotic therapy [51–54]. Tea leaves accumulate fluoride absorbed from the soil. Bone turnover markers [ALP, osteocalcin and C-terminal cross-linking telopeptides of type I collagen (CTX)] and BMD can be elevated [Z-scores +14 (lumbar), +7 (hip) but –0.6 (distal radius)], with enhanced cancellous bone formation on iliac crest biopsy [55]. Renal calculi have been associated [55]. Fluoride treatment does not reduce vertebral fracture risk [56, 57].

Renal osteodystrophy

Osteomalacia and soft tissue calcification are common, but renal osteodystrophy may be associated with regions of excessively mineralized bone tissue affecting the ribs, pelvis and spine. Osteosclerosis can produce the classical rugger-jersey spine X-ray appearance, characterized by sclerotic bands along multiple superior and inferior vertebral endplates with relative central lucency [58, 59].

Acromegaly

Untreated acromegaly is characterized by increased bone turnover. Excess growth hormone and insulin-like growth

factor 1 (IGF-1) are anabolic, predominantly affecting cortical, rather than trabecular, bone (so increasing femoral rather than lumbar BMD) [60, 61]. However, reported hip Z-scores of +1.3 probably reflect anabolic attenuation by concurrent hypogonadism [62]. BMD changes may persist during disease remission [63].

Hepatitis C-associated osteosclerosis

Since 1992, diffuse acquired osteosclerosis, with characteristic cranial sparing, has been reported in fewer than 20 cases globally associated with HCV infection [64–79]. In addition to markedly elevated ALP, IGF proteins are apparently elevated, promoting bone formation, increasing osteoprotegerin (OPG) and reducing receptor activator of nuclear factor- κ B ligand (RANKL) levels [69, 80]. Remarkably, in one case report, lumbar spine and femoral neck T-scores of +5.5 and +15.9, respectively, fell over 7 years to +0.5 and +4.0 after successful ribavirin and IFN antiviral treatment [81]; the underlying mechanism remains unclear.

Myelofibrosis

Myelofibrosis is a rare chronic myeloproliferative disorder of bone marrow fibrosis causing marked splenomegaly and osteosclerosis, with an incidence of 0.21/100 000 person-years [82]. Small, sharp bone spicules develop within the bone marrow cavity, increasing BMD (Z-scores ranging from +2 to +6) and bone turnover in one case series of four men [83].

Mastocytosis

A disease of widespread mast cell tissue infiltration, mastocytosis has been associated with both osteoporosis and osteosclerosis. Osteosclerosis is reported in more severe disease associated with higher serum tryptase levels and higher bone turnover [84–87]. The mechanisms are poorly understood, but severe disease, with greater histamine production, may stimulate osteoblastic bone formation, while tryptase may increase OPG, reducing osteoclast activity, favouring osteosclerosis rather than osteoporosis [85, 88]. Disordered serotonin synthesis, also a feature, does not explain BMD variations [89].

Oestrogen implants

Historical use of long-term (i.e. >14 years) high-dose oestradiol implant therapy in women following surgical menopause has been associated with increased BMD in a handful of cases, with mean (s.d.) spinal and femoral neck T-scores of +1.7 (\pm 2.0) and +1.2 (\pm 1.4), respectively [90]. Histomorphometry suggests anabolic skeletal effects through increased osteoblastic activity.

Generalized abnormalities causing high BMD measurements: inherited

Several rare genetic disorders with skeletal effects, collectively termed sclerosing bone dysplasias and osteopetroses, are associated with generalized increased BMD [91]. Unlike spondylosis affecting multiple vertebrae,

these will elevate hip as well as lumbar spine BMD. However, changes in bone structure and quantity have variable effects on fracture risk. In addition to a clinical separation based on increased or decreased fracture risk, a biological separation can be made into disorders in which (i) bone resorption is depressed (Table 2), (ii) bone formation is enhanced (Table 3) and (iii) balance is disturbed between bone formation and resorption (Table 3).

Decreased bone resorption

Osteopetroses (Greek etymology: petro—to turn to stone) are rare genetic conditions of reduced osteoclastic bone resorption. Defective bone remodelling during growth induces skeletal sclerosis and abnormally dense but brittle bones, first described by Albers-Schönberg as marble bone disease [92, 153]. Osteopetrosis is classified by clinical severity (Table 2); autosomal dominant osteopetrosis (ADO) was historically subdivided into type I and type II. ADO1, subsequently identified as secondary to an *LRP5* (low-density lipoprotein receptor-related protein 5) mutation [123] (discussed later), is not a primary osteoclast disease, is not characterized by bone fragility and is better not considered as an osteopetrosis. Two osteopetroses pertinent to adulthood are discussed below.

Autosomal dominant osteopetrosis II

ADOII (Albers-Schönberg disease) is caused by a *CLCN7* mutation with penetrance between 60% and 80%, giving a varied clinical phenotype, including detection as an incidental radiographic finding [154]. Prevalence is estimated at between 0.2 and 5.5/100 000 [155, 156]. The phenotype can include facial nerve palsy, visual loss (in 5–25%), carpal tunnel syndrome, hip OA (in 7%), increased fracture risk and delayed fracture healing, osteomyelitis (in 10–13%), particularly of the mandible, dental abscesses (10%) and deep decay (36%) and in extreme cases bone marrow failure (~3%) [93, 100–103]. In one case series of 94 *CLCN7* mutation cases, almost every adult (98%) had experienced a fracture (including half of their hip), with a third having fractured more than once (five had >15 fractures) [102]. Among another 42 cases from 10 families, age range 7–70 years, the mean number of fractures per person was 4.4 [103]. However, these case series were not performed systematically so patterns are difficult to generalize.

Radiographs feature (i) vertebral end-plate thickening (rugged-jersey spine), (ii) bone-within-bone, particularly in the pelvis, and (iii) transverse sclerotic bands within the distal femorae [100, 103]. However, the radiological phenotype is not ubiquitous (~60–90%) [155, 157]. DXA BMD Z-score ranges from +3 to +15 [100, 102]. The *CLCN7* protein functions as a voltage-gated Cl⁻/H⁺ ion channel and is found in lysosomes and on the ruffled border of osteoclasts. By acid efflux, it facilitates inorganic bone matrix dissolution [158]. Multiple mutations have been identified in association with the range of osteopetrotic phenotypes [159–161].

TABLE 2 Osteopetrotic conditions; the gene defects, function and clinical characteristics

Condition	OMIM	Inheritance	Gene	Mutation	Protein	Function	Symptoms	Reference
Severe/neonatal/ infantile/autosomal recessive osteopetrosis ^a	259700, 604592 602727 607649 602642	AR AR AR AR	<i>TCIRG1</i> <i>CLCN7</i> <i>OSTM1</i> <i>RANKL/TNFSF11</i>	Loss of function Loss of function Loss of function Loss of function	T cell, immune regulator 1, H ⁺ transporting, lysosomal subunit A3 of V-ATPase pump Chloride channel Osteopetrosis-associated transmembrane protein 1 Receptor activator for nuclear factor- κ B ligand/ TNF (ligand) superfamily, member 11	Acidification of the resorption lacuna Acidification of the resorption lacuna β -subunit for CLC-7 Osteoclastogenesis, resorption, survival	Fractures, infections (e.g. osteomyelitis), macrocephaly, frontal bossing, neurological symptoms, CN compression, blindness, deafness, delayed tooth eruption, haemopoietic failure, death (usually before age 10). Osteoclast poor osteopetrosis. Fractures, hydrocephalus, nystagmus, seizures, hypersplenism, less severe course than <i>TCIRG1</i> , <i>CLCN7</i> , <i>OSTM1</i> mutations.	[92–94]
Intermediate autosomal recessive osteopetrosis	603499 259710 259700, 611497	AR AR AR	<i>RANK/TNFRSF11A</i> <i>CLCN7</i> <i>PLEKHM1</i>	Loss of function Partial loss of function Loss of function	Receptor activator for nuclear factor- κ B Chloride channel Pleckstrin homology domain-containing family M (with RUN domain) member 1	Osteoclastogenesis, resorption, survival Acidification of the resorption lacuna Vesicular trafficking	Onset in childhood, fractures, short stature, cranial nerve compression. Osteopetrosis of the skull only (L2–L4 T-score -2.3). Fractures. Raised osteocalcin.	[95] [93, 96] [97]
Osteopetrosis with renal tubular acidosis	259730, 611492	AR	<i>CAII</i>	Loss of function	Carbonic anhydrase II member 1	Intracellular acidification	Developmental delay, short stature, CN compression, blindness, dental complications, fractures, maintained haemopoietic function.	[92, 93]
Osteopetrosis with ecto- dermal dysplasia and immune defect (OLEDAID)	300301	XL	<i>IKBKG</i>	Loss of function	Inhibitor of kappa light polypeptide gene enhancer in B cells, kinase gamma (NEMO)	Unknown	Lymphoedema, severe infections, no teeth, skin abnormalities, early death.	[94]
Leucocyte adhesion deficiency syndrome (LAD-III) and osteopetrosis	612840 612840	AR AR	<i>Kindlin-3/ FERMT3</i> <i>CalDAG-GEF1</i>	Loss of function Loss of function	Kindlin-3 Calcium and diacylglycerol-regulated guanine nucleotide exchange factor 1	Cell adhesion	Bacterial infections, bleeding, osteopetrosis, hepatosplenomegaly.	[98] [99]

(continued)

TABLE 2 Continued

Condition	OMIM	Inheritance	Gene	Mutation	Protein	Function	Symptoms	Reference
Late-onset osteopetrosis (Albers-Schönberg disease) ADOII	166600	AD	CLCN7	Dominant negative effect	Chloride channel	Acidification of the resorption lacuna	Classic radiographic features, fractures, nerve compression, osteomyelitis, dental complications.	[93, 100–103]
Pycnodysostosis	265800, 601105	AR	C7SK	Loss of function	Cathepsin K	Collagen degradation	Delayed cranial suture closure, short stature and phalanges, dental abnormalities, fractures.	[104–106]
Osteopoiikilosis	155950	AD	LEMD3/MAN1	Loss of function	LEM domain-containing 3	LEMD3 antagonizes the BMP and TGF- β signalling pathways	Benign, incidental osteosclerotic foci (can mimic metastases) ^c .	[93, 107, 108]
Melorheostosis	155950	AD	LEMD3/MAN1	Loss of function	LEM domain-containing 3		Characteristic radiographic features ^d , soft tissue symptoms.	[93, 107, 108]
Osteopathia striata ^a with cranial stenosis	300373	XL	WTX	Loss of function	Wilms tumour gene on the X chromosome	Wnt signalling suppression	Macrocephaly, CN compression, cleft palate, skull/long bone sclerosis in females. Usually lethal in males.	[109]

XL: X-linked; CN: cranial nerve. ^aARO incidence is 1/200 000–300 000 live births [94]. ^bAs well as an osteoclast poor ARO phenotype, RANK mutations have also been linked to the Paget's-like diseases (familial expansile osteolysis, expansile skeletal hyperphosphatasia and early-onset PD) [110, 111]. ^cWhen associated with connective tissue naevi, dermatofibrosis lenticularis disseminata then termed Buschke-Ollendorff syndrome [93, 107, 112]. ^dAsymmetric 'flowing hyperostosis' or 'dripping candle wax'. Approximately 200 cases described to date. Soft tissue changes (hypertrichosis, fibromas, haemangiomas and pain) associated with radiographic features in scleritome. Contractures can develop [93, 107, 108, 113]. ^eCan occur in combination with focal dermal hypoplasia, skin pigmentation, hypoplastic teeth, syndactyly, ocular defects and fat herniation through skin and is known as Goltz syndrome [109, 114–116].

TABLE 3 Inherited HBM conditions due to enhanced bone formation, or disturbed formation and resorption; the gene defects, function and clinical characteristics

Condition	OMIM	Inheritance	Gene	Mutation	Protein	Function	Symptoms	Reference
Increased bone formation								
Sclerosteosis	269500	AR	SOST	Loss of function	Sclerostin	Osteoblast Wnt signalling inhibitor	Cutaneous digital syndactyly, excessive height. Skull/mandible thickening, tori ^a , CN palsies (incl. neonatal). Headaches, raised ICP, coning. Back/bone pain. Fracture resistance.	[117, 118–120]
van Buchem's disease ^b	239100	AR	SOST ^c	Reduced function	Sclerostin	Osteoblast Wnt signalling inhibitor	No syndactyly, no excess height. Skull/mandible thickening, tori ^a , CN palsies. Headaches, back/bone pain. Fracture resistance.	[117, 121, 122]
LRP5 HBM	603506	AD	LRP5	Gain of function	LRP5	Osteoblast cell membrane co-receptor regulating Wnt signalling	Asymptomatic or tori ^a , skull/mandible thickening, CN palsies, neuropathy, neuralgia, headaches, back/bone pain, spinal stenosis, reduced buoyancy, craniosynostosis. Fracture resistance.	[123, 124–140]
LRP4 HBM	604270	AD and AR	LRP4	Loss of function	LRP4	Impaired sclerostin-LRP4 interaction	Syndactyly, dysplastic nails, gait disturbance, facial nerve palsy, deafness.	[141]
Cranio metaphyseal dysplasia	123000 218400	AD and AR	ANKH	Loss of function	ANK	Osteoclast-reactive vacuolar proton pump	Macrocephaly, cranial hyperostosis, CN palsies, wide nasal bridge, dental overcrowding, metaphyseal flaring.	[142, 143]
Disturbed balance between bone formation and resorption								
Camurati-Engelmann disease ^d	131300	AD	TGF- β 1	Probable gain of function	TGF- β	Stimulates both osteoblast and osteoclast activity	Onset before 30 years, variable phenotype. Thickened diaphyseal cortices, limb pain, fatigability, muscle weakness, waddling gait. Variably raised ALP, reduced calcium and anaemia.	[144–149]
Ghosal haematodiaphyseal syndrome	274180	AR	TBXAS1	Loss of function	Thromb-oxane synthase	Modulates RANKL and OPG expression	Impaired platelet aggregation (steroid-sensitive), anaemia. Similar to Camurati-Engelmann but metaphyses affected.	[150, 151]

OMIM®: Online Mendelian Inheritance in Man; CN: cranial nerve; ICP: intracranial pressure. ^aTori: oral exostoses, which include torus palatinus and mandibularis found in approximately 25% of a general Caucasian population [152]. ^bInitially known as hyperostosis corticalis generalisata familiaris [121, 122]. ^cA 52-kb intronic deletion downstream of SOST. ^dAlso known as progressive diaphyseal dysplasia.

TABLE 4 Examples of how understanding HBM conditions has helped inform development of new osteoporosis therapies

HBM condition	Molecular target	Drugs in development	Reference
Pycnodysostosis	Cathepsin K	Cathepsin K inhibitors: Odanacatib (Phase III trial) Balicatib (trials discontinued due to dermatological side effects)	[167] [168, 169]
Sclerosteosis and van Buchem's disease	Sclerostin	Anti-SOST antibodies	[170, 171]
<i>LRP5</i> HBM and osteoporosis pseudoglioma syndrome (OPPG)	Inhibition of natural antagonists of osteoblastic Wnt signalling	Glycogen synthase kinase-3 β (GSK3 β) inhibitors Dickkopf 1 (Dkk1) antibodies Secreted frizzled-related protein-1 (Sfrp1) inhibitors	[172] [173, 174] [175]

Pycnodysostosis

First described in 1962 and said to be the malady of both Toulouse-Lautrec and Aesop (of fable renown) [162–164], pycnodysostosis is caused by defective enzymatic degradation of organic bone matrix due to an autosomal recessive mutation in the gene coding cathepsin K [104]. To date, 27 mutations have been reported among fewer than 200 cases globally [104–106]. Secreted by osteoclasts, cathepsin K cleaves type I collagen [165]. The characteristic bone dysplasia includes skull deformities, underdeveloped facial bones with micrognathia, beaked nose, short stature and phalanges, dental caries, persistence of deciduous teeth and abnormally dense but brittle bones [93, 104–106, 166]. Interestingly, understanding of pycnodysostosis has prompted development of a novel class of antiresorptive therapy currently in trial (e.g. odanacatib) [167] (Table 4).

Increased bone formation

Sclerosteosis and van Buchem's disease

Sclerosteosis and van Buchem's disease are clinically similar conditions of generalized enhanced bone formation, increased bone strength and resistance to fracture due to reduced levels of sclerostin [117]. It is thought that mechanical loading reduces osteocytic production of sclerostin, permitting activation of osteoblastic Wnt signalling and bone formation [176]. At least three pharmaceutical companies are currently developing anti-sclerostin antibodies [170, 171] (Table 4). Loss-of-function *SOST* gene mutations cause sclerosteosis, whereas a 52-kb intronic deletion downstream of *SOST*, thought to disrupt post-transcriptional sclerostin processing, results in the milder phenotype of van Buchem's disease. Sclerosteosis causes gigantism, mandible enlargement, torus palatinus and mandibularis, which complicate tooth extractions [118, 177]. Calvarial overgrowth compresses cranial nerves, particularly facial nerves, sometimes from infancy; in one series, 83% of 63 adults had recurrent facial nerve palsies [118]. Hearing loss and headaches are common; craniotomy to alleviate raised intracranial pressure and sudden death by coning

is not uncommon [118, 178]. Cutaneous syndactyly of fingers (present in 76%) and toes is an important defining feature, often accompanying dysplastic or absent nails and camptodactyly [118, 178, 179]. Sclerosteosis is progressive, which may cause bone and back pain requiring spinal decompression [118].

van Buchem's disease is milder than sclerosteosis, importantly without syndactyly or gigantism [117, 178]. Cranial nerve impingements and hearing loss remain common [180]. Management is generally limited to surgical bone removal, however, glucocorticoids have been used to reduce high bone turnover in an isolated case report [181].

LRP5 high bone mass

Ten activating *LRP5* mutations affecting 23 families globally have now been reported [123, 124–139]. Initially cases were described as asymptomatic, with mandible enlargement, osseous tori, a marked resistance to fracture (e.g. in car accidents), thickened cortices on radiographs (without reduced haemopoietic capacity), normal biochemistry and BMD Z-scores of +3 to +8 [124, 182]. However, subsequent case reports describe complications secondary to bone overgrowth: nerve compression causing deafness, cranial nerve palsies, congenital strabismus, sensorimotor neuropathy, spinal stenosis, paresthesias and trigeminal neuralgia [127, 128], in addition to headaches, bone pain and reduced buoyancy [126, 127]. The *G640A* mutation is the only one to link *LRP5* with craniosynostosis requiring craniotomy, developmental delay and a profoundly dysmorphic and pathological phenotype including ventricular septal defect (VSD) [129]. Osteocalcin levels are raised or normal [126, 127, 182]. *LRP5* codes for an essential cell membrane co-receptor within the Wnt signalling pathway, regulating osteoblastic bone formation [140]. Conversely, inactivating *LRP5* mutations causes autosomal recessive osteoporosis pseudoglioma syndrome (OPPG) [183].

Unexplained high bone mass

There remains a population, even after exclusion of all of these listed conditions, with a sporadic finding of

generalized raised BMD (Z -score $\geq +3.2$ at either L1 or hip) on routine DXA scanning with unexplained high bone mass (HBM) in whom fracture risk is not increased, associated with clinical characteristics suggestive of a mild skeletal dysplasia, namely poor buoyancy, mandible enlargement, extra bone at the site of tendon and ligament insertions, broad skeletal frame and larger shoe size, as well as increased BMI [5]. Considered to be relatively benign, this picture explains 35% of incidental findings of raised BMD on routine DXA scanning. As 41% have a first-degree relative with a similar phenotype, it is thought to be an inherited condition. Research is currently under way to identify the genetic cause and fully evaluate the associated phenotype, e.g. metabolic, muscular and joint characteristics, to inform clinical management.

Recent findings suggest that HBM is characterized by increased trabecular BMD and by alterations in cortical bone density and structure, leading to substantial increments in predicted cortical bone strength. Neither trabecular nor cortical BMD appear to decline with age in the tibia of HBM cases, suggesting that attenuation of age-related bone loss in weight-bearing limbs may contribute to their bone phenotype [184]. Furthermore, body composition assessment suggests that HBM is associated with a marked increase in fat mass, particularly android fat, in women but not men [185]. Although elevated BMI is not a recognized feature of skeletal dysplasia, interestingly, a similar finding has been reported in families of HBM due to an activating *LRP5* mutation [186].

Finally, studying HBM may improve our understanding of OA. An inverse relationship between osteoporosis and OA is well documented, with higher hip and/or lumbar spine BMD in individuals with radiographic OA [187–190]. However, osteophytes can artefactually increase measured BMD [9] and, counterintuitively, fracture risk is not reduced in OA [191, 192]. Potential mechanisms linking increased BMD with OA include (i) increased subchondral bone stiffness increasing articular cartilage stresses and damage [193], (ii) activation of the Wnt signalling pathway, thought to have a role in both joint formation and maintenance of joint homeostasis in later life [194] (supported by β -catenin upregulation in knee joint cartilage prior to joint replacement [195]) and (iii) molecular cross-talk between bone and cartilage arising through increased permeability of the bone–cartilage interface [196, 197]. Large joint OA has been reported in ADOII and *LRP5* HBM [103, 127, 138], and unexplained HBM has recently been associated with an increased prevalence of joint replacement [198], suggesting that increased OA risk may represent a further, hitherto unrecognized, consequence of elevated BMD.

Investigation and management of a raised BMD

Initial inspection should classify BMD increases as focal or generalized (spine, hip or both). Focal increases in BMD should be carefully inspected for osteoarthritic changes, which if clearly visible require no further imaging.

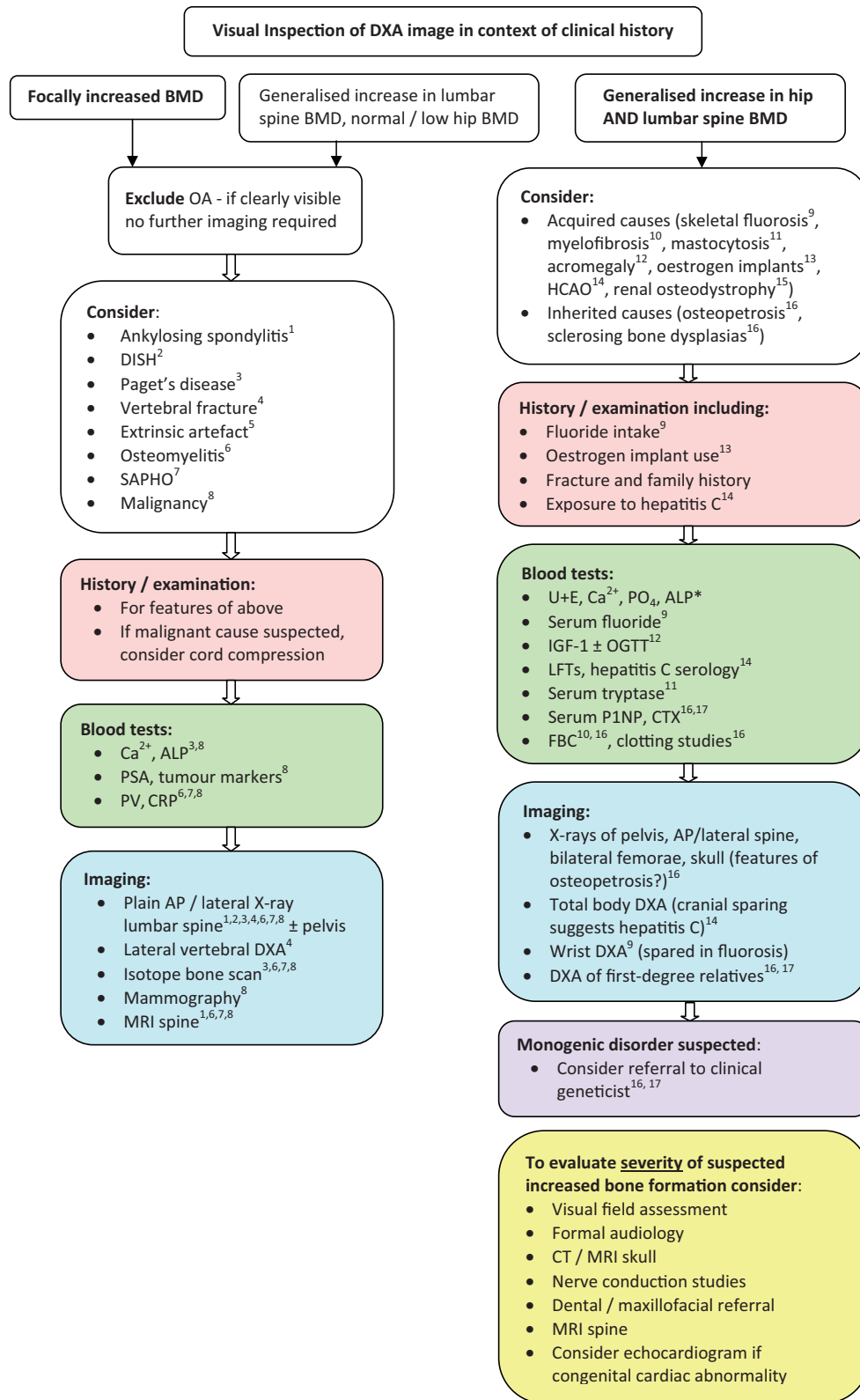
Otherwise, anteroposterior (AP)/lateral lumbar spine \pm pelvis plain X-rays are initially recommended with routine bone biochemistry and inflammatory markers. MRI may be required, particularly if examination prompts doubt regarding spinal cord compression or X-rays raise the possibility of malignancy. Lateral DXA can help with vertebral fracture assessment. Suspected malignancy may require mammography, isotope bone scan, prostate assessment and tumour markers. ALP is usually lowered in hypophosphatasia and raised in active PD, although up to 5% will have a normal ALP in PD [199].

Generalized increased BMD affecting both spine and hip are less commonly seen and the differential diagnosis is wide. Outpatient clinic assessment should include questioning regarding fluoride exposure, hepatitis C risk factors, headaches, bone pain and in women historical oestrogen implant use, plus examination for stigmata of acromegaly, bone overgrowth, nerve compression, splenomegaly (in haemopoietic failure) and dysmorphism suggestive of a mild skeletal dysplasia associated with unexplained HBM. A careful fracture history is essential, including the family history. Blood tests should include bone biochemistry, renal function, full blood count (FBC) and clotting studies, liver function and hepatitis C serology, plus potentially serum fluoride levels, IGF-1 \pm an oral glucose tolerance test if acromegaly is suspected and serum tryptase if mastocytosis is suspected. Bone turnover markers (P1NP and serum CTX) may be useful.

Potentially relevant plain radiographs include AP/lateral lumbar spine, pelvis, bilateral femorae and lateral skull. In ADOII, radiographs show the classic rugger-jersey spine due to vertebral end-plate thickening, bone-within-bone often seen in the pelvis and transverse sclerotic bands within the distal femur [100, 103]. DXA examination showing low distal radius BMD would support the diagnosis of fluorosis [cranial sparing on whole-body DXA scanning, if available, would support hepatitis C-associated osteosclerosis (HCAO)]. Hip and lumbar spine DXA scans in first-degree relatives will help identify relatively asymptomatic inherited HBM conditions. If specific characteristic features suggest a monogenic disorder such as osteopetrosis or sclerosteosis, referral to local clinical genetic services for counselling and genotyping should be considered depending on the severity of symptoms and the family history.

If an inherited condition of increased bone formation is suspected, a number of investigations may be helpful in establishing the severity of the phenotype. Visual field assessment and formal audiology are important as cranial nerve impingement can be managed by surgical decompression. For similar reasons, CT/MRI skull, MRI spine and nerve conduction studies may be helpful. Assessment by dental and/or maxillofacial specialists may be needed. Examination should include cardiovascular examination, and if a severe *LRP5* mutation is suspected, cardiac echocardiography may be needed to exclude VSD. An approach to investigating high BMD measurements is summarized in Fig. 2.

Fig. 2 Flow diagram to guide the investigation and management of raised BMD identified on DXA scanning.



Ca²⁺: Calcium; PSA: prostate specific antigen; PV: plasma viscosity; U+E: urea and electrolytes; PO₄: phosphate; OGTT: oral glucose tolerance test; LFTs: liver function tests; P1NP: N-terminal propeptides of type I procollagen. *Up to 5% with PD will have a normal ALP [161]. Potential diagnoses are each given a superscript digit, to which the investigations then relate.

Conclusion

A BMD *T/Z*-score $>+2.5$ does not generally indicate normal bone density, but is usually caused by an artefactual increase in BMD secondary to lumbar spondylosis which is readily identifiable from inspection of the DXA scan image. However, high BMD measurements may arise from a genuine increase in bone mass. This may be caused by a focal abnormality within the DXA field, such as a Pagetic lumbar vertebra, or a generalized skeletal abnormality resulting from acquired osteosclerosis, or rarely a genetic mutation leading to a sclerosing bone dysplasia. The most common form of sclerosing dysplasia is the currently unexplained HBM phenotype, characterized by a mild skeletal dysplasia; unlike the osteopetroses, this does not convey an increase in fracture risk.

Knowledge of rare genetic skeletal dysplasias has helped guide innovative treatments for osteoporosis (Table 4), e.g. from our understanding of pycnodysostosis, odanacatib was developed [167], as were anti-sclerostin antibodies from our experience of sclerosteosis and van Buchem's disease [170]. Yet, much HBM remains unexplained, better appreciation of which may translate into improved understanding of bone regulation and new therapeutic targets for future osteoporosis therapies, as well as aiding management through greater understanding of associated comorbidities.

Here we have presented a classification for the potential causes of a raised BMD detected by DXA scanning as part of normal clinical practice. This classification should help guide clinical evaluation and diagnosis when the DXA scan is interpreted within the context of the clinical history.

Rheumatology key messages

- A BMD *T/Z*-score $>+2.5$ does not generally indicate normal bone density but warrants evaluation.
- Lumbar osteoarthritic spondylosis accounts for half of *T/Z*-scores $\geq +4$ found on routine DXA scanning.
- When BMD is raised, clinical sequelae depend on the cause, which needs to be established.

Acknowledgements

The High Bone Mass study was supported by the Wellcome Trust and the NIHR CRN (portfolio number 5163). C.L.G. was funded through a Wellcome Trust Clinical Research Training Fellowship (080280/Z/06/Z) and is currently funded by the Medical Research Council at the University of Southampton. S.A.H. is funded through an Arthritis Research UK Clinical PhD Studentship (grant reference 19580).

Disclosure statement: C.C. has received honoraria and consulting fees from Amgen, ABBH, Eli Lilly, Medtronic, Merck, Novartis and Servier. All other authors have declared no conflicts of interest.

References

- 1 World Health Organization. Assessment of fracture risk and its application to screening for postmenopausal osteoporosis. Technical report no. 843. Geneva: WHO, 1994.
- 2 Whyte MP. Misinterpretation of osteodensitometry with high bone density: BMD $Z > \text{ or } = +2.5$ is not 'normal'. *J Clin Densitom* 2005;8:1-6.
- 3 Morin S, Leslie W. High bone mineral density is associated with high body mass index. *Osteoporos Int* 2009;20:1267-71.
- 4 Duncan EL, Danoy P, Kemp JP *et al*. Genome-wide association study using extreme truncate selection identifies novel genes affecting bone mineral density and fracture risk. *PLoS Genet* 2011;7: e1001372.
- 5 Gregson CL, Steel SA, O'Rourke KP *et al*. 'Sink or swim': an evaluation of the clinical characteristics of individuals with high bone mass. *Osteoporos Int* 2012;23:643-54.
- 6 White J, Yeats A, Skipworth G. Tables for statisticians. 3rd edn. Cheltenham: Stanley Thornes, 1979.
- 7 Drinka PJ, DeSmet AA, Bauwens SF *et al*. The effect of overlying calcification on lumbar bone densitometry. *Calcif Tissue Int* 1992;50:507-10.
- 8 Masud T, Langley S, Wiltshire P *et al*. Effect of spinal osteophytosis on bone mineral density measurements in vertebral osteoporosis. *BMJ* 1993;307:172-3.
- 9 Liu G, Peacock M, Eilam O *et al*. Effect of osteoarthritis in the lumbar spine and hip on bone mineral density and diagnosis of osteoporosis in elderly men and women. *Osteoporos Int* 1997;7:564-9.
- 10 Denko C, Malesud C. Body mass index and blood glucose: correlations with serum insulin, growth hormone, and insulin-like growth factor-1 levels in patients with diffuse idiopathic skeletal hyperostosis (DISH). *Rheumatol Int* 2006;26:292-7.
- 11 Li H, Jiang LS, Dai LY. Hormones and growth factors in the pathogenesis of spinal ligament ossification. *Eur Spine J* 2007;16:1075-84.
- 12 Westerveld LA, Verlaan JJ, Lam MG *et al*. The influence of diffuse idiopathic skeletal hyperostosis on bone mineral density measurements of the spine. *Rheumatology* 2009;48:1133-6.
- 13 Eser P, Bonel H, Seitz M *et al*. Patients with diffuse idiopathic skeletal hyperostosis do not have increased peripheral bone mineral density and geometry. *Rheumatology* 2010;49:977-81.
- 14 Diederichs G, Engelken F, Marshall L *et al*. Diffuse idiopathic skeletal hyperostosis (DISH): relation to vertebral fractures and bone density. *Osteoporos Int* 2011;22:1789-97.
- 15 Weinfeld RM, Olson PN, Maki DD *et al*. The prevalence of diffuse idiopathic skeletal hyperostosis (DISH) in two large American Midwest metropolitan hospital populations. *Skeletal Radiol* 1997;26:222-5.
- 16 Muntean L, Rojas-Vargas M, Font P *et al*. Relative value of the lumbar spine and hip bone mineral density and bone turnover markers in men with ankylosing spondylitis. *Clin Rheumatol* 2011;30:691-5.

- 17 Donnelly S, Doyle DV, Denton A *et al.* Bone mineral density and vertebral compression fracture rates in ankylosing spondylitis. *Ann Rheum Dis* 1994;53:117-21.
- 18 Bessant R, Keat A. How should clinicians manage osteoporosis in ankylosing spondylitis? *J Rheumatol* 2002;29:1511-9.
- 19 Scane AC, Masud T, Johnson FJ *et al.* The reliability of diagnosing osteoporosis from spinal radiographs. *Age Ageing* 1994;23:283-6.
- 20 Lewiecki EM, Laster AJ. Clinical review: clinical applications of vertebral fracture assessment by dual-energy x-ray absorptiometry. *J Clin Endocrinol Metab* 2006;91:4215-22.
- 21 Orwoll ES, Oviatt SK, Mann T. The impact of osteophytic and vascular calcifications on vertebral mineral density measurements in men. *J Clin Endocrinol Metab* 1990;70:1202-7.
- 22 Reid IR, Evans MC, Ames R *et al.* The influence of osteophytes and aortic calcification on spinal mineral density in postmenopausal women. *J Clin Endocrinol Metab* 1991;72:1372-4.
- 23 Wang TK, Bolland MJ, Pelt NC *et al.* Relationships between vascular calcification, calcium metabolism, bone density, and fractures. *J Bone Miner Res* 2010;25:2777-85.
- 24 Yildiz M, Canatan D. Soft tissue density variations in thalassemia major: a possible pitfall in lumbar bone mineral density measurements by dual-energy X-ray absorptiometry. *Pediatr Hematol Oncol* 2005;22:723-6.
- 25 Spencer RP, Szigeti DP. Abdominal abscess detected by lumbar bone densitometry examination. *Clin Nucl Med* 1998;23:44.
- 26 Smith JA, Spencer RP, Szigeti DP. Gall stones detected on lumbar bone densitometry examination. *J Clin Densitom* 1998;1:403-4.
- 27 Bazzocchi A, Ferrari F, Diano D *et al.* Incidental findings with dual-energy X-ray absorptiometry: spectrum of possible diagnoses. *Calcif Tissue Int* 2012;91:149-56.
- 28 Hauache OM, Vieira JG, Alonso G *et al.* Increased hip bone mineral density in a woman with gluteal silicon implant. *J Clin Densitom* 2000;3:391-3.
- 29 Spencer RP, Szigeti DP, Engin IO. Effect of laminectomy on measured bone density. *J Clin Densitom* 1998;1:375-7.
- 30 Cooper C, Harvey NC, Dennison EM *et al.* Update on the epidemiology of Paget's disease of bone. *J Bone Miner Res* 2006;21(Suppl 2):3-8.
- 31 Dell'Atti C, Cassar-Pullicino VN, Lalam RK *et al.* The spine in Paget's disease. *Skeletal Radiol* 2007;36:609-26.
- 32 Evans CE, Ward C, Braidman IP. Breast carcinomas synthesize factors which influence osteoblast-like cells independently of osteoclasts in vitro. *J Endocrinol* 1991;128:R5-8.
- 33 Narvaez JA, Narvaez J, Clavaguera MT *et al.* Bone and skeletal muscle metastases from gastric adenocarcinoma: unusual radiographic, CT and scintigraphic features. *Eur Radiol* 1998;8:1366-9.
- 34 Stabler J. Case report: ossifying metastases from carcinoma of the large bowel demonstrated by bone scintigraphy. *Clin Radiol* 1995;50:730-1.
- 35 George J, Lai FM. Metastatic cervical carcinoma presenting as psoas abscess and osteoblastic and lytic bony metastases. *Singapore Med J* 1995;36:224-7.
- 36 Sherazi Z, Saifuddin A, Shaikh MI *et al.* Unusual imaging findings in association with spinal osteoblastoma. *Clin Radiol* 1996;51:644-8.
- 37 Mohan V, Sabri T, Gupta RP *et al.* Solitary ivory vertebra due to primary Ewing's sarcoma. *Pediatr Radiol* 1992;22:388-90.
- 38 Epstein BS. The spine: a radiographic text and atlas. 4th edn. Philadelphia: Lea & Febiger, 1976.
- 39 Lecuyer N, Grados F, Dargent-Molina P *et al.* Prevalence of Paget's disease of bone and spinal hemangioma in French women older than 75 years: data from the EPIDOS study. *Joint Bone Spine* 2000;67:315-8.
- 40 Resnick D. Diagnosis of bone and joint disorders. 4th edn. Philadelphia: Saunders, 2002.
- 41 Sharma LM, Biswas G, Rai SS *et al.* Retro-peritoneal plasmacytoma: a case report and review of literature. *Indian J Cancer* 2004;41:133-4.
- 42 Hagiwara N, Yahikozawa H. Multiple cavernous haemangioma showing marked calcification on cranial radiography. *J Neurol Neurosurg Psychiatry* 2002;72:410.
- 43 Cagavi F, Kalayci M, Tekin IO *et al.* Primary spinal extranodal Hodgkin's disease at two levels. *Clin Neurol Neurosurg* 2006;108:168-73.
- 44 Correale J, Monteverde DA, Bueri JA *et al.* Peripheral nervous system and spinal cord involvement in lymphoma. *Acta Neurol Scand* 1991;83:45-51.
- 45 Mitchell MJ, Logan PM. Radiation-induced changes in bone. *Radiographics* 1998;18:1125-36.
- 46 Umeoka S, Koyama T, Miki Y *et al.* Pictorial review of tuberous sclerosis in various organs. *Radiographics* 2008;28:e32.
- 47 Jonard P, Lonneux M, Boland B *et al.* Tc-99m HDP bone scan showing bone changes in a case of tuberous sclerosis or Bourneville's disease. *Clin Nucl Med* 2001;26:50-2.
- 48 Crino PB, Nathanson KL, Henske EP. The tuberous sclerosis complex. *N Engl J Med* 2006;355:1345-56.
- 49 Takigawa T, Tanaka M, Nakanishi K *et al.* SAPHO syndrome associated spondylitis. *Eur Spine J* 2008;17:1391-7.
- 50 Laredo JD, Vuillemin-Bodaghi V, Boutry N *et al.* SAPHO syndrome: MR appearance of vertebral involvement. *Radiology* 2007;242:825-31.
- 51 Wang Y, Yin Y, Gilula LA *et al.* Endemic fluorosis of the skeleton: radiographic features in 127 patients. *AJR Am J Roentgenol* 1994;162:93-8.
- 52 Hallanger Johnson JE, Kearns AE, Doran PM *et al.* Fluoride-related bone disease associated with habitual tea consumption. *Mayo Clin Proc* 2007;82:719-24.
- 53 Whyte MP, Totty WG, Lim VT *et al.* Skeletal fluorosis from instant tea. *J Bone Miner Res* 2008;23:759-69.
- 54 Joshi S, Hlaing T, Whitford GM *et al.* Skeletal fluorosis due to excessive tea and toothpaste consumption. *Osteoporos Int* 2011;22:2557-60.

- 55 Kurland ES, Schulman RC, Zerwekh JE *et al.* Recovery from skeletal fluorosis (an enigmatic, American case). *J Bone Miner Res* 2007;22:163–70.
- 56 Riggs BL, Hodgson SF, O'Fallon WM *et al.* Effect of fluoride treatment on the fracture rate in postmenopausal women with osteoporosis. *N Engl J Med* 1990;322:802–9.
- 57 Kleerekoper M, Peterson EL, Nelson DA *et al.* A randomized trial of sodium fluoride as a treatment for postmenopausal osteoporosis. *Osteoporos Int* 1991;1:155–61.
- 58 Wittenberg A. The rugger jersey spine sign. *Radiology* 2004;230:491–2.
- 59 Jevtic V. Imaging of renal osteodystrophy. *Eur J Radiol* 2003;46:85–95.
- 60 Kotzmann H, Bernecker P, Hubsch P *et al.* Bone mineral density and parameters of bone metabolism in patients with acromegaly. *J Bone Miner Res* 1993;8:459–65.
- 61 Diamond T, Nery L, Posen S. Spinal and peripheral bone mineral densities in acromegaly: the effects of excess growth hormone and hypogonadism. *Ann Intern Med* 1989;111:567–73.
- 62 Kaji H, Sugimoto T, Nakaoka D *et al.* Bone metabolism and body composition in Japanese patients with active acromegaly. *Clin Endocrinol (Oxf)* 2001;55:175–81.
- 63 Biermasz NR, Hamdy NA, Pereira AM *et al.* Long-term maintenance of the anabolic effects of GH on the skeleton in successfully treated patients with acromegaly. *Eur J Endocrinol* 2005;152:53–60.
- 64 Beyer HS, Anderson Q, Shih MS *et al.* Diffuse osteosclerosis in intravenous drug abusers. *Am J Med* 1993;95:660–2.
- 65 Beyer HS, Parfitt AM, Shih MS *et al.* Idiopathic acquired diffuse osteosclerosis in a young woman. *J Bone Miner Res* 1990;5:1257–63.
- 66 Diamond T, Depczynski B. Acquired osteosclerosis associated with intravenous drug use and hepatitis C infection. *Bone* 1996;19:679–83.
- 67 Fiore CE, Riccobene S, Mangiafico R *et al.* Hepatitis C-associated osteosclerosis (HCAO): report of a new case with involvement of the OPG/RANKL system. *Osteoporos Int* 2005;16:2180–4.
- 68 Hassoun AA, Nippoldt TB, Tiegs RD *et al.* Hepatitis C-associated osteosclerosis: an unusual syndrome of acquired osteosclerosis in adults. *Am J Med* 1997;103:70–3.
- 69 Khosla S, Hassoun AA, Baker BK *et al.* Insulin-like growth factor system abnormalities in hepatitis C-associated osteosclerosis. Potential insights into increasing bone mass in adults. *J Clin Invest* 1998;101:2165–73.
- 70 Manganelli P, Giuliani N, Fietta P *et al.* OPG/RANKL system imbalance in a case of hepatitis C-associated osteosclerosis: the pathogenetic key? *Clin Rheumatol* 2005;24:296–300.
- 71 Schwartz KM, Skinner JA. Hepatitis C-associated osteosclerosis: a case report. *Skeletal Radiol* 2008;37:679–81.
- 72 Shaker JL, Reinus WR, Whyte MP. Hepatitis C-associated osteosclerosis: late onset after blood transfusion in an elderly woman. *J Clin Endocrinol Metab* 1998;83:93–8.
- 73 Tanaka T, Oki S, Muro S *et al.* A case of hepatitis C-associated osteosclerosis in an elderly Japanese man. *Endocr J* 2006;53:393–9.
- 74 Villareal DT, Murphy WA, Teitelbaum SL *et al.* Painful diffuse osteosclerosis after intravenous drug abuse. *Am J Med* 1992;93:371–81.
- 75 Wakitani S, Hattori T, Nakaya H *et al.* Clinical images: hepatitis C-associated osteosclerosis. *Arthritis Rheum* 2003;48:268.
- 76 Whyte MP, Reasner CA. Hepatitis C-associated osteosclerosis after blood transfusion. *Am J Med* 1997;102:219–20.
- 77 Whyte MP. Paget's disease of bone and genetic disorders of RANKL/OPG/RANK/NF-kappaB signaling. *Ann N Y Acad Sci* 2006;1068:143–64.
- 78 Bergman D, Einhorn TI, Forster G. Stone bone syndrome—diffuse sclerosis of bone: a newly described clinical disorder. *Endocr Pract* 1996;2:296.
- 79 Whyte MP, Teitelbaum SL, Reinus WR. Doubling skeletal mass during adult life: the syndrome of diffuse osteosclerosis after intravenous drug abuse. *J Bone Miner Res* 1996;11:554–8.
- 80 Qiu Q, Yan X, Bell M *et al.* Mature IGF-II prevents the formation of 'big' IGF-II/IGFBP-2 complex in the human circulation. *Growth Horm IGF Res* 2010;20:110–7.
- 81 Javier R, de Vernejoul M, Afif N *et al.* Skeletal recovery from hepatitis C-associated osteosclerosis (HCAO) following anti-viral treatment. *Joint Bone Spine* 2011;78:409–11.
- 82 Rollison DE, Howlader N, Smith MT *et al.* Epidemiology of myelodysplastic syndromes and chronic myeloproliferative disorders in the United States, 2001–2004, using data from the NAACCR and SEER programs. *Blood* 2008;112:45–52.
- 83 Diamond T, Smith A, Schnier R *et al.* Syndrome of myelofibrosis and osteosclerosis: a series of case reports and review of the literature. *Bone* 2002;30:498–501.
- 84 Barete S, Assous N, de Gennes C *et al.* Systemic mastocytosis and bone involvement in a cohort of 75 patients. *Ann Rheum Dis* 2010;69:1838–41.
- 85 Johansson C, Roupe G, Lindstedt G *et al.* Bone density, bone markers and bone radiological features in mastocytosis. *Age Ageing* 1996;25:1–7.
- 86 Kushnir-Sukhov NM, Brittain E, Reynolds JC *et al.* Elevated tryptase levels are associated with greater bone density in a cohort of patients with mastocytosis. *Int Arch Allergy Immunol* 2006;139:265–70.
- 87 Rossini M, Zanotti R, Bonadonna P *et al.* Bone mineral density, bone turnover markers and fractures in patients with indolent systemic mastocytosis. *Bone* 2011;49:880–5.
- 88 Chiappetta N, Gruber B. The role of mast cells in osteoporosis. *Semin Arthritis Rheum* 2006;36:32–6.
- 89 Kushnir-Sukhov NM, Brittain E, Scott L *et al.* Clinical correlates of blood serotonin levels in patients with mastocytosis. *Eur J Clin Invest* 2008;38:953–8.
- 90 Vedi S, Purdie DW, Ballard P *et al.* Bone remodeling and structure in postmenopausal women treated with long-term, high-dose estrogen therapy. *Osteoporos Int* 1999;10:52–8.

- 91 International nomenclature and classification of the osteochondrodysplasias. International Working Group on Constitutional Diseases of Bone. *Am J Med Genet* 1998;79:376–82.
- 92 Tolar J, Teitelbaum SL, Orchard PJ. Osteopetrosis. *N Engl J Med* 2004;351:2839–49.
- 93 Whyte MP. Sclerosing bone disorders. In: Rosen CJ, ed. *Primer on the metabolic bone diseases and disorders of mineral metabolism*. 7th edn. Washington, DC: American Society for Bone and Mineral Research, 2008:412–23.
- 94 Balemans W, Van Wesenbeeck L, Van Hul W. A clinical and molecular overview of the human osteopetroses. *Calcif Tissue Int* 2005;77:263–74.
- 95 Sobacchi C, Frattini A, Guerrini MM *et al.* Osteoclast-poor human osteopetrosis due to mutations in the gene encoding RANKL. *Nat Genet* 2007;39:960–2.
- 96 Segovia-Silvestre T, Neutzsky-Wulff A, Sorensen M *et al.* Advances in osteoclast biology resulting from the study of osteopetrotic mutations. *Hum Genet* 2009;124:561–77.
- 97 Del FA, Fornari R, Van Wesenbeeck L *et al.* A new heterozygous mutation (R714C) of the osteopetrosis gene, pleckstrin homolog domain containing family M (with run domain) member 1 (PLEKHM1), impairs vesicular acidification and increases TRACP secretion in osteoclasts. *J Bone Miner Res* 2008;23:380–91.
- 98 Malinin NL, Zhang L, Choi J *et al.* A point mutation in KINDLIN3 ablates activation of three integrin subfamilies in humans. *Nat Med* 2009;15:313–8.
- 99 Pasvolsky R, Feigelson SW, Kilic SS *et al.* A LAD-III syndrome is associated with defective expression of the Rap-1 activator CalDAG-GEFI in lymphocytes, neutrophils, and platelets. *J Exp Med* 2007;204:1571–82.
- 100 Benichou O, Cleiren E, Gram J *et al.* Mapping of autosomal dominant osteopetrosis type II (Albers-Schonberg disease) to chromosome 16p13.3. *Am J Hum Genet* 2001;69:647–54.
- 101 Bollerslev J, Mosekilde L. Autosomal dominant osteopetrosis. *Clin Orthop Relat Res* 1993;45–51.
- 102 Waguespack SG, Hui SL, DiMeglio LA *et al.* Autosomal dominant osteopetrosis: clinical severity and natural history of 94 subjects with a chloride channel 7 gene mutation. *J Clin Endocrinol Metab* 2007, 1;92:771–8.
- 103 Benichou OD, Laredo JD, de Vernejoul MC. Type II autosomal dominant osteopetrosis (Albers-Schonberg disease): clinical and radiological manifestations in 42 patients. *Bone* 2000;26:87–93.
- 104 Gelb BD, Shi GP, Chapman HA *et al.* Pycnodysostosis, a lysosomal disease caused by cathepsin K deficiency. *Science* 1996;273:1236–8.
- 105 Donnarumma M, Regis S, Tappino B *et al.* Molecular analysis and characterization of nine novel CTSK mutations in twelve patients affected by pycnodysostosis. Mutation in brief #961. Online. *Hum Mutat* 2007;28:524.
- 106 Fujita Y, Nakata K, Yasui N *et al.* Novel mutations of the cathepsin K gene in patients with pycnodysostosis and their characterization. *J Clin Endocrinol Metab* 2000;85:425–31.
- 107 Hellemans J, Preobrazhenska O, Willaert A *et al.* Loss-of-function mutations in LEMD3 result in osteopoikilosis, Buschke-Ollendorff syndrome and melorheostosis. *Nat Genet* 2004;36:1213–8.
- 108 Freyschmidt J. Melorheostosis: a review of 23 cases. *Eur Radiol* 2001;11:474–9.
- 109 Jenkins ZA, van Kogelenberg M, Morgan T *et al.* Germline mutations in WTX cause a sclerosing skeletal dysplasia but do not predispose to tumorigenesis. *Nat Genet* 2009;41:95–100.
- 110 Whyte MP, Hughes AE. Expansile skeletal hyperphosphatasia is caused by a 15-base pair tandem duplication in TNFRSF11A encoding RANK and is allelic to familial expansile osteolysis. *J Bone Miner Res* 2002;17:26–9.
- 111 Nakatsuka K, Nishizawa Y, Ralston SH. Phenotypic characterization of early onset Paget's disease of bone caused by a 27-bp duplication in the TNFRSF11A gene. *J Bone Miner Res* 2003;18:1381–5.
- 112 Whyte MP, Murphy WA, Siegel BA. 99mTc-pyrophosphate bone imaging in osteopoikilosis, osteopathia striata, and melorheostosis. *Radiology* 1978;127:439–43.
- 113 Gass JK, Hellemans J, Mortier G *et al.* Buschke-Ollendorff syndrome: a manifestation of a heterozygous nonsense mutation in the LEMD3 gene. *J Am Acad Dermatol* 2008;58(5 Suppl 1):S103–4.
- 114 Goltz RW, Peterson WC, Gorlin RJ *et al.* Focal dermal hypoplasia. *Arch Dermatol* 1962;86:708–17.
- 115 Goltz RW. Focal dermal hypoplasia syndrome: an update. *Arch Dermatol* 1992;128:1108–11.
- 116 Wang X, Reid Sutton V, Omar Peraza-Llanes J *et al.* Mutations in X-linked PORCN, a putative regulator of Wnt signaling, cause focal dermal hypoplasia. *Nat Genet* 2007;39:836–8.
- 117 Staehling-Hampton K, Proll S, Paeper BW *et al.* A 52-kb deletion in the SOST-MEOX1 intergenic region on 17q12-q21 is associated with van Buchem disease in the Dutch population. *Am J Med Genet* 2002;110:144–52.
- 118 Hamersma H, Gardner J, Beighton P. The natural history of sclerosteosis. *Clin Genet* 2003;63:192–7.
- 119 Hansen H. Sklerosteose. In: Opitz H, Schmid F, eds. *Handbuch der Kinderheilkunde*. Berlin: Springer, 2010.
- 120 Brunkow ME, Gardner JC, Van Ness J *et al.* Bone dysplasia sclerosteosis results from loss of the SOST gene product, a novel cystine knot-containing protein. *Am J Hum Genet* 2001;68:577–89.
- 121 Van Buchem FS, Hadders H, Ubbens R. An uncommon familial systemic disease of the skeleton: hyperostosis corticalis generalisata familiaris. *Acta Radiol* 1955;44:109–20.
- 122 Fosmoe RJ, Holm RS, Hildreth RC. Van Buchem's disease (hyperostosis corticalis generalisata familiaris). A case report. *Radiology* 1968;90:771–4.
- 123 Van Hul E, Gram J, Bollerslev J *et al.* Localization of the gene causing autosomal dominant osteopetrosis type I to chromosome 11q12-13. *J Bone Miner Res* 2002;17:1111–7.

- 124 Johnson ML, Gong G, Kimberling W *et al.* Linkage of a gene causing high bone mass to human chromosome 11 (11q12-13). *Am J Hum Genet* 1997;60:1326-32.
- 125 Little RD, Carulli JP, Del Mastro RG *et al.* A mutation in the LDL receptor-related protein 5 gene results in the autosomal dominant high-bone-mass trait. *Am J Hum Genet* 2002;70:11-9.
- 126 Boyden LM, Mao J, Belsky J *et al.* High bone density due to a mutation in LDL-receptor-related protein 5. *N Engl J Med* 2002;346:1513-21.
- 127 Whyte MP, Reinus WH, Mumm S. High-bone mass disease and LRP5. *N Engl J Med* 2004;350:2096-9.
- 128 Boyden LM IK, Lifton RP. High bone mass disease and LRP5. *N Engl J Med* 2004;350:2098-9.
- 129 Kwee ML, Balemans W, Cleiren E *et al.* An autosomal dominant high bone mass phenotype in association with craniosynostosis in an extended family is caused by an LRP5 missense mutation. *J Bone Miner Res* 2005;20:1254-60.
- 130 Renton T, Odell E, Drage NA. Differential diagnosis and treatment of autosomal dominant osteosclerosis of the mandible. *Br J Oral Maxillofac Surg* 2002;40:55-9.
- 131 Bollerslev J, Nielsen HK, Larsen HF *et al.* Biochemical evidence of disturbed bone metabolism and calcium homeostasis in two types of autosomal dominant osteopetrosis. *Acta Med Scand* 1988;224:479-83.
- 132 Bollerslev J, Andersen PE Jr. Radiological, biochemical and hereditary evidence of two types of autosomal dominant osteopetrosis. *Bone* 1988;9:7-13.
- 133 Van Wesenbeeck L, Cleiren E, Gram J *et al.* Six novel missense mutations in the LDL receptor-related protein 5 (LRP5) gene in different conditions with an increased bone density. *Am J Hum Genet* 2003;72:763-71.
- 134 Beals RK. Endosteal hyperostosis. *J Bone Joint Surg Am* 1976;58:1172-3.
- 135 Beals RK, McLoughlin SW, Teed RL *et al.* Dominant endosteal hyperostosis. Skeletal characteristics and review of the literature. *J Bone Joint Surg Am* 2001;83-A:1643-9.
- 136 Scopelliti D, Orsini R, Ventucci E *et al.* [Van Buchem disease. Maxillofacial changes, diagnostic classification and general principles of treatment]. *Minerva Stomatol* 1999;48:227-34.
- 137 van Wesenbeeck L, Odgren PR, Mackay CA *et al.* Localization of the gene causing the osteopetrotic phenotype in the incisors absent (ia) rat on chromosome 10q32.1. *J Bone Miner Res* 2004;19:183-9.
- 138 Balemans W, Devogelaer JP, Cleiren E *et al.* Novel LRP5 missense mutation in a patient with a high bone mass phenotype results in decreased DKK1-mediated inhibition of Wnt signaling. *J Bone Miner Res* 2007;22:708-16.
- 139 Rickels MR, Zhang X, Mumm S *et al.* Oropharyngeal skeletal disease accompanying high bone mass and novel LRP5 mutation. *J Bone Miner Res* 2005;20:878-85.
- 140 Koay A, Brown MA. Genetic disorders of the LRP5-Wnt signalling pathway affecting the skeleton. *Trends Mol Med* 2005;11:129-37.
- 141 Leupin O, Piters E, Halleux C *et al.* Bone overgrowth-associated mutations in the LRP4 gene impair sclerostin facilitator function. *J Biol Chem* 2011;286:19489-500.
- 142 Nurnberg P, Tinschert S, Mrug M *et al.* The gene for autosomal dominant craniometaphyseal dysplasia maps to chromosome 5p and is distinct from the growth hormone-receptor gene. *Am J Hum Genet* 1997;61:918-23.
- 143 Reichenberger E, Tiziani V, Watanabe S *et al.* Autosomal dominant craniometaphyseal dysplasia is caused by mutations in the transmembrane protein ANK. *Am J Hum Genet* 2001;68:1321-6.
- 144 Kinoshita A, Saito T, Tomita H *et al.* Domain-specific mutations in TGF β 1 result in Camurati-Engelmann disease. *Nat Genet* 2000;26:19-20.
- 145 Campos-Xavier A, Saraiva J, Savarirayan R *et al.* Phenotypic variability at the TGF- β 1 locus in Camurati-Engelmann disease. *Hum Genet* 2001;109:653-8.
- 146 Smith R, Walton R, Corner BD *et al.* Clinical and biochemical studies in Engelmann's disease (progressive diaphyseal dysplasia). *Q J Med* 1977;46:273-94.
- 147 Crisp AJ, Brenton DP. Engelmann's disease of bone—a systemic disorder? *Ann Rheum Dis* 1982;41:183-8.
- 148 Saito T, Kinoshita A, Yoshiura Ki. *et al.* Domain-specific mutations of a transforming growth factor (TGF)- β 1 latency-associated peptide cause Camurati-Engelmann disease because of the formation of a constitutively active form of TGF- β 1. *J Biol Chem* 2001;276:11469-72.
- 149 McGowan NWA, MacPherson H, Janssens K *et al.* A mutation affecting the latency-associated peptide of TGF β 1 in Camurati-Engelmann disease enhances osteoclast formation in vitro. *J Clin Endocrin Metab* 2003;88:3321-6.
- 150 Ghosal SP, Mukherjee AK, Mukherjee D *et al.* Diaphyseal dysplasia associated with anemia. *J Pediatr* 1988;113(1 Pt 1):49-57.
- 151 Genevieve D, Proulle V, Isidor B *et al.* Thromboxane synthase mutations in an increased bone density disorder (Ghosal syndrome). *Nat Genet* 2008;40:284-6.
- 152 Garcia-Garcia AS, Martinez-Gonzalez JM, Gomez-Font R *et al.* Current status of the torus palatinus and torus mandibularis. *Med Oral Patol Oral Cir Bucal* 2010;15:e353-60.
- 153 Albers-Schönberg HE. Röntgenbilder einer seltenen Knochenkrankung. *Munch Med Wochenschr* 1903;5:365-8.
- 154 Van Hul W, Bollerslev J, Gram J *et al.* Localization of a gene for autosomal dominant osteopetrosis (Albers-Schonberg disease) to chromosome 1p21. *Am J Hum Genet* 1997;61:363-9.
- 155 Bollerslev J. Osteopetrosis. A genetic and epidemiological study. *Clin Genet* 1987;31:86-90.
- 156 Salzano FM. Osteopetrosis: review of dominant cases and frequency in a Brazilian state. *Acta Genet Med Gemellol (Roma)* 1961;10:353-8.
- 157 Benichou OD, Benichou B, Copin H *et al.* Further evidence for genetic heterogeneity within type II autosomal

- dominant osteopetrosis. *J Bone Miner Res* 2000;15:1900–4.
- 158 Kornak U, Kasper D, Bosl MR *et al.* Loss of the ClC-7 chloride channel leads to osteopetrosis in mice and man. *Cell* 2001;104:205–15.
- 159 Zhang ZL, He JW, Zhang H *et al.* Identification of the *CLCN7* gene mutations in two Chinese families with autosomal dominant osteopetrosis (type II). *J Bone Miner Metab* 2009;27:444–51.
- 160 Pangrazio A, Pusch M, Caldana E *et al.* Molecular and clinical heterogeneity in *CLCN7*-dependent osteopetrosis: report of 20 novel mutations. *Hum Mutat* 2010;31:E1071–80.
- 161 Waguespack SG, Koller DL, White KE *et al.* Chloride channel 7 (*CLCN7*) gene mutations and autosomal dominant osteopetrosis, type II. *J Bone Miner Res* 2003;18:1513–8.
- 162 Maroteaux P, Lamy M. La pycnodysostose. *Presse Med* 1962;70:999–1002.
- 163 Maroteaux P, Lamy M. The malady of Toulouse-Lautrec. *JAMA* 1965;191:715–7.
- 164 Bartsocas CS. Pycnodysostosis: Toulouse-Lautrec's and Aesop's disease? *Hormones (Athens)* 2002;1:260–2.
- 165 Motyckova G, Fisher DE. Pycnodysostosis: role and regulation of cathepsin K in osteoclast function and human disease. *Curr Mol Med* 2002;2:407–21.
- 166 Muto T, Michiya H, Taira H *et al.* Pycnodysostosis. Report of a case and review of the Japanese literature, with emphasis on oral and maxillofacial findings. *Oral Surg Oral Med Oral Pathol* 1991;72:449–55.
- 167 Eisman JA, Bone HG, Hosking DJ *et al.* Odanacatib in the treatment of postmenopausal women with low bone mineral density: three-year continued therapy and resolution of effect. *J Bone Miner Res* 2011;26:242–51.
- 168 Adami S, Supronik J, Hala T *et al.* Effect of one year treatment with the cathepsin-K inhibitor, balicatib, on bone mineral density (BMD) in postmenopausal women with osteopenia/osteoporosis. *J Bone Miner Res* 2006;21(Suppl 1):S24.
- 169 Peroni A, Zini A, Braga V *et al.* Drug-induced morphea: report of a case induced by balicatib and review of the literature. *J Am Acad Dermatol* 2008;59:125–9.
- 170 Padhi D, Jang G, Stouch B *et al.* Single-dose, placebo-controlled, randomized study of AMG 785, a sclerostin monoclonal antibody. *J Bone Miner Res* 2011;26:19–26.
- 171 Lewiecki EM. Sclerostin monoclonal antibody therapy with AMG 785: a potential treatment for osteoporosis. *Expert Opin Biol Ther* 2010;11:117–27.
- 172 Kulkarni NH, Onyia JE, Zeng Q *et al.* Orally bioavailable GSK-3 α/β dual inhibitor increases markers of cellular differentiation in vitro and bone mass in vivo. *J Bone Miner Res* 2006;21:910–20.
- 173 Glantschnig H, Hampton R, Wei N *et al.* Fully human anti-DKK1 antibodies increase bone formation and resolve osteopenia in mouse models of estrogen-deficiency induced bone loss. *J Bone Miner Res* 2008;23:S60–1.
- 174 Heiland GR, Zwerina K, Baum W *et al.* Neutralisation of Dkk-1 protects from systemic bone loss during inflammation and reduces sclerostin expression. *Ann Rheum Dis* 2010;69:2152–9.
- 175 Moore WJ, Kern JC, Bhat R *et al.* Modulation of Wnt signaling through inhibition of secreted frizzled-related protein 1 (sFRP-1) with N-substituted piperidinyl diphenylsulfonamide sulfonamides. *J Med Chem* 2008;52:105–16.
- 176 van Oers RF, Van Rietbergen B, Ito K *et al.* A sclerostin-based theory for strain-induced bone formation. *Biomech Model Mechanobiol* 2011;10:663–70.
- 177 Stephen LX, Hamersma H, Gardner J *et al.* Dental and oral manifestations of sclerosteosis. *Int Dent J* 2001;51:287–90.
- 178 Balemans W, Van Den Ende J, Freire Paes-Alves A *et al.* Localization of the gene for sclerosteosis to the van Buchem disease-gene region on chromosome 17q12–q21. *Am J Hum Genet* 1999;64:1661–9.
- 179 Tacconi P, Ferrigno P, Cocco L *et al.* Sclerosteosis: report of a case in a black African man. *Clin Genet* 1998;53:497–501.
- 180 Van Hul W, Balemans W, Van Hul E *et al.* Van Buchem disease (hyperostosis corticalis generalisata) maps to chromosome 17q12–q21. *Am J Hum Genet* 1998;62:391–9.
- 181 van Lierop AH, Hamdy NA, Papapoulos SE. Glucocorticoids are not always deleterious for bone. *J Bone Miner Res* 2010;25:2520–4.
- 182 Little RD, Carulli JP, Del Mastro RG *et al.* A mutation in the LDL receptor-related protein 5 gene results in the autosomal dominant high-bone-mass trait. *Am J Hum Genet* 2002;70:11–9.
- 183 Gong Y, Slee RB, Fukui N *et al.* LDL receptor-related protein 5 (LRP5) affects bone accrual and eye development. *Cell* 2001;107:513–23.
- 184 Gregson CL, Sayers A, Lazar V *et al.* The high bone mass phenotype is characterised by a combined cortical and trabecular bone phenotype: findings from a pQCT case–control study. *Bone* 2012;51:380–8.
- 185 Gregson CL, Paggiosi M, Crabtree N *et al.* Analysis of body composition in individuals with high bone mass reveals a marked increase in fat mass in women but not men. *J Clin Endocrinol Metab* 2013;98:doi:10.1210/jc.2012-3342.
- 186 Frost M, Andersen T, Gossiel F *et al.* Levels of serotonin, sclerostin, bone turnover markers as well as bone density and microarchitecture in patients with high bone mass phenotype due to a mutation in *Lrp5*. *J Bone Miner Res* 2011;26:1721–8.
- 187 Hart DJ, Mootoosamy I, Doyle DV *et al.* The relationship between osteoarthritis and osteoporosis in the general population: the Chingford Study. *Ann Rheum Dis* 1994;53:158–62.
- 188 Nevitt MC, Lane NE, Scott JC *et al.* Radiographic osteoarthritis of the hip and bone mineral density. The Study of Osteoporotic Fractures Research Group. *Arthritis Rheum* 1995;38:907–16.
- 189 Hart DJ, Cronin C, Daniels M *et al.* The relationship of bone density and fracture to incident and progressive radiographic osteoarthritis of the knee: the Chingford Study. *Arthritis Rheum* 2002;46:92–9.

- 190 Nevitt MC, Zhang Y, Javaid MK *et al.* High systemic bone mineral density increases the risk of incident knee OA and joint space narrowing, but not radiographic progression of existing knee OA: the MOST study. *Ann Rheum Dis* 2010;69:163–8.
- 191 Arden NK, Griffiths GO, Hart DJ *et al.* The association between osteoarthritis and osteoporotic fracture: the Chingford Study. *Br J Rheumatol* 1996;35:1299–304.
- 192 Arden NK, Nevitt MC, Lane NE *et al.* Osteoarthritis and risk of falls, rates of bone loss, and osteoporotic fractures. Study of Osteoporotic Fractures Research Group. *Arthritis Rheum* 1999;42:1378–85.
- 193 Radin EL, Paul IL, Rose RM. Role of mechanical factors in pathogenesis of primary osteoarthritis. *Lancet* 1972;1: 519–22.
- 194 Luyten FP, Tylzanowski P, Lories RJ. Wnt signaling and osteoarthritis. *Bone* 2009;44:522–7.
- 195 Zhu M, Tang D, Wu Q *et al.* Activation of beta-catenin signaling in articular chondrocytes leads to osteoarthritis-like phenotype in adult beta-catenin conditional activation mice. *J Bone Miner Res* 2009;24: 12–21.
- 196 Suri S, Walsh DA. Osteochondral alterations in osteoarthritis. *Bone* 2012;51:204–11.
- 197 Lories RJ, Luyten FP. The bone-cartilage unit in osteoarthritis. *Nat Rev Rheumatol* 2011;7:43–9.
- 198 Hardcastle SA, Gregson CL, Deere K *et al.* Prevalence of joint replacement is increased in high bone mass. Bone Research Society/National Osteoporosis Society annual meeting, Manchester, July 2012.
- 199 Ralston SH, Langston AL, Reid IR. Pathogenesis and management of Paget's disease of bone. *Lancet* 2008; 372:155–63.

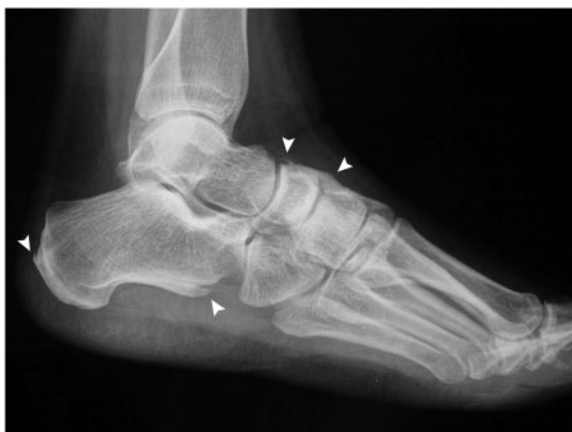Clinical vignette

An overlooked cause of back pain and stiffness

A 47-year-old woman with ichthyosis congenita presented with recent onset of pain at the dorsal aspect of the left foot. She suffered from chronic back pain and stiffness beginning at the age of 40.

Standard X-ray of the left foot revealed new bone apposition in several sites (Fig. 1). Spine X-ray revealed lumbar and dorsal coarse non-marginal syndesmophytes and osteophytes. MRI showed normal sacroiliac joints, with no signs of bone oedema. SpA was excluded (the classification criteria for axial SpA were not fulfilled), and DISH was unlikely (young age). As the patient had been

Fig. 1 Standard radiograph of the left foot.



New bone formation above the tarsum and at the capsular insertion of the calcaneocuboidal joint and bone spur at the calcaneal insertion of the Achilles tendon (arrowheads).

Rheumatology 2013;52:985

doi:10.1093/rheumatology/kes408

Advance Access publication 22 January 2013

taking retinoids, namely acitretin, for about 30 years, retinoid-induced diffuse skeletal hyperostosis was our final diagnosis.

Retinoid treatment has been associated with many rheumatological complications, among which diffuse hyperostosis is by far the most common [1], presumably based on a direct modulation of chondrocyte phenotype. Although the actual frequency is unknown, hyperostosis develops in most patients treated with high doses of retinoids or with small doses over long periods. The patient's symptoms dramatically improved after acitretin discontinuation due to her enrolment in a clinical trial of a new topical drug for ichthyosis.

Acknowledgements

We thank the patient for giving consent to the publication of her medical history and radiographic imaging.

Disclosure statement: The authors have declared no conflicts of interest.

Roberta Gualtierotti¹, Gabriele De Marco¹ and Antonio Marchesoni¹

¹Department of Rheumatology, G. Pini Orthopedic Institute, Milan, Italy.

Correspondence to: Antonio Marchesoni, G. Pini Orthopedic Institute, Piazza A. Ferrari 1, 20122 Milano, Italy. E-mail: marchesoni@gpini.it

Reference

- 1 Neshler G, Zuckner J. Rheumatologic complications of vitamin A and retinoids. *Semin Arthritis Rheum* 1995;24: 291–6.