

Full Clinical Recovery after Topical Acyclovir Treatment of Epstein-Barr Virus Associated Cutaneous B-Cell Lymphoma in Patient with Mycosis Fungoides

M. Sitki Copur^{1,2}, Anita Deshpande¹, Kris Mleczko¹, Max Norvell¹, Gordon J. Hrnicek¹, Suzette Woodward¹, Scott Frankforter¹, Natalie Mandolfo¹, Kai Fu¹, Wing C. Chan²

¹Saint Francis Medical Center, Grand Island; and ²University of Nebraska Medical Center, Omaha, Neb, USA

Abstract

Primary cutaneous T- and B-cell lymphomas are a heterogeneous group of diseases with varied clinical presentations and prognosis. The use of new molecular, histological, and clinical criteria has improved their recognition. Cutaneous B-cell and T-cell lymphomas are seldom found together in the same patient. Here we report a rare case of mycosis fungoides variant of a cutaneous T-cell lymphoma (CTCL) which later developed Epstein-Barr virus (EBV) associated cutaneous B-cell lymphoproliferative disorder. The patient initially presented with generalized erythroderma, extensive plaques, and axillary lymphadenopathy. Histopathology and immunophenotyping of her tumor from the right breast nodule revealed a T-cell lymphoma consistent with mycosis fungoides. She was initially treated with pentostatin, followed by topical mechlorethamine and topical steroids. After progression of her mycosis fungoides with worsening diffuse skin lesions on this regimen, her treatments were changed to oral bexarotene with an initial partial response followed by stable disease. Three years from her initial presentation, she developed ulcerated cauliflower-like nodules on her forehead. Biopsy of these lesions revealed EBV-positive large- and medium-sized pleomorphic B-cells consistent with EBV-driven B-cell lymphoproliferative disorder. She was treated with topical acyclovir cream on the involved skin areas while continuing with oral bexarotene for mycosis fungoides. Skin lesions gradually diminished and totally disappeared after four weeks of topical acyclovir treatment. Bexarotene treatment was continued for another year until the mycosis fungoides progressed and became wide spread causing her death four and a half years after the initial diagnosis. The coexistence of two cutaneous non-Hodgkin lymphomas of different lineage in the same patient and the complete clinical response of EBV-related B-cell cutaneous component to topical acyclovir makes this rare case particularly interesting.

Primary cutaneous B- and T-cell lymphomas have been recognized as a heterogeneous group of cutaneous non-Hodgkin lymphomas with distinct variability in clinical presentation, histopathology, immunophenotype, genetic abnormalities, and prognosis (1). Primary cutaneous T-cell lymphomas (CTCL) comprise a constellation of heterogeneous lymphoproliferative disorders cha-

racterized by clonal accumulation of neoplastic T lymphocytes in the skin. Mycosis fungoides is the most frequent variant of CTCL, clinically characterized by the development of patches, plaques, or tumors. Primary cutaneous B-cell lymphomas are lymphoid neoplasms arising within the skin without evidence of systemic involvement (2). The etiology of both T-cell and B-cell cutaneous lympho-

mas is largely unknown. Viral infectious etiologies, including human T-lymphocyte virus-1 (HTLV-1), human herpes virus-8 (HHS-8), herpes simplex virus (HSV), hepatitis C virus, and Epstein-Barr Virus have been proposed as causative factors. However, none of these entities has been conclusively associated with either primary cutaneous T-cell or B-cell lymphomas (3-6). There have been occasional reports of CTCL associated with B-cell lymphoproliferative disorders, including plasma cell dyscrasia, chronic lymphocytic leukemia (CLL), and B-cell lymphomas (7-9). The coexistence of T- and B-cell cutaneous lymphoma in the same patient, however, is very rare. Here we report a case of Epstein-Barr virus (EBV) related B-cell cutaneous lymphoproliferative disorder (LPD) in a patient with CTCL wherein the B-cell LPD had a complete clinical response to topical acyclovir treatment.

Case Report

A 61-year-old white female was seen for extensive skin rash, axillary lymphadenopathy, and a palpable mass on her right breast. She gave a year history of pruritic erythematous, scaling lesions of her skin, mostly on her trunk and scalp. She had been treated with topical steroids, with minor improvement. Her skin lesions gradually spread to involve her entire body, with diffuse thickening of the skin, generalized erythroderma, and leonine face (Fig. 1). Prior to the referral, she had also noticed a nodule under the skin of her right breast. Physical examination revealed a number of large erythematous scaling patches on her chest, back, arms, thighs, legs, and face, covering almost 70% of her body. There were bilateral

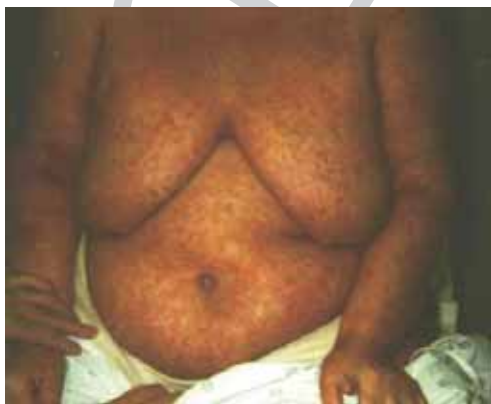

Figure 1. Generalized erythroderma and lesions of mycosis fungoides in the body.

axillary lymph nodes 2-3 cm in size and a palpable 2 cm nodule on the lateral part of her right breast. Physical exam was negative for other sites of lymphadenopathy or hepatosplenomegaly.

Laboratory and Imaging Studies

White blood cells count was 6,900/ μ L (61% neutrophils, 32% lymphocytes, 7% monocytes), hemoglobin 14.5 g/dL, hematocrit 46%, and the platelet count was 298,000/ μ L. Hepatic and renal function panels were normal. The lactate dehydrogenase level was slightly elevated, at 235 IU/L (normal: 20-200 IU/L). Antinuclear antibody screen was negative. No antibodies were detected to human immunodeficiency virus-1 (HIV-1) or HTLV-1. The titers of anti EBV antibodies were as follows: anti-viral capsid antigen IgG >2 enzyme immuno assay (EIA) value (normal <0.9) and anti-nuclear antigen IgG >5 EIA value (normal <0.9). Peripheral blood flow cytometry analysis was negative for phenotypically abnormal cell populations. Mammography revealed a 1.8 \times 2.2 cm mass located laterally corresponding to the palpable abnormality on her physical exam. Computerized tomography scans of the neck, chest, abdomen, and pelvis confirmed bilateral axillary lymphadenopathy but no other sites of lymphoma involvement.

Stereotactic breast biopsy revealed a lymph node with a cytologic and architectural abnormality suspicious for lymphoma (Fig. 2). Polymerase chain reaction (PCR) analysis for T-cell receptor gamma gene rearrangements showed a clonal T-cell process. Further skin biopsy confirmed the diagnosis of mycosis fungoides.

Treatment and Clinical Course

The patient was initially treated with 2'-deoxycoformycin (pentostatin), 4 mg/m²/week for the first 4 weeks and then every 2 weeks until maximal response. After a total of 12 treatments, she had a more than 50% improvement in her skin lesions and her axillary lymphadenopathy resolved. Treatments were changed to topical corticosteroids and topical mechlorethamine (nitrogen mustard, HN₂) which kept her disease under control for almost a year. When she had progressive worsening of the skin lesions and developed allergic reactions to nitrogen mustard, a year after her initial diagnosis, she was given oral bexarotene at a dose of 300 mg/m². She had an initial partial response followed by stable disease for two years.

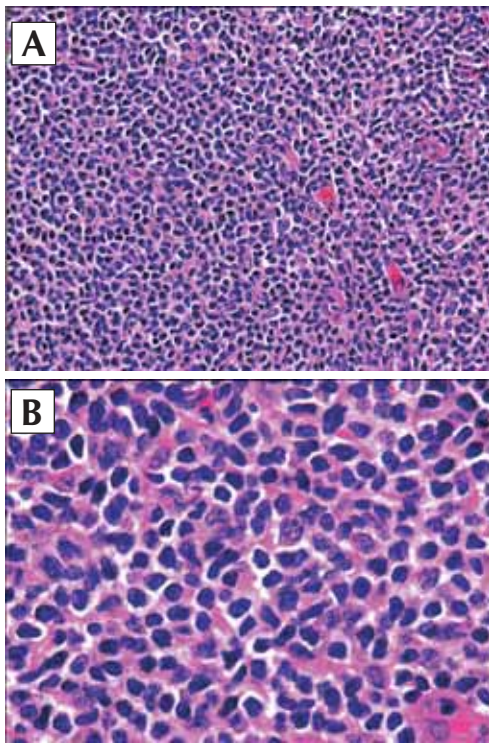


Figure 2. Stereotactic breast biopsy. (A) ($\times 400$ magnification) The lymph node diffusely infiltrated by small lymphocytes with convoluted nuclei. Immunoperoxidase staining of cells for CD3, CD4, and CD5 demonstrated a phenotype of mature helper T-cells, consistent with *mycosis fungoides*. (B) Examination under oil immersion ($\times 1000$ magnification) lens allows better appreciation of the cerebriform convolutions of the nuclear membranes in the neoplastic T-cells.

Three years from the initial presentation, she developed fungating, ulcerated, cauliflower like nodular lesions on her forehead (Fig. 3). The biopsy of these lesions revealed large and medium sized pleomorphic B-cells (Fig. 4) consistent with diffuse large B-cell lymphoma of the skin. There was a partial loss of CD20 expression and a predominance of λ light chain expression with a marked increase in λ to κ ratio, consistent with the presence of a monoclonal B-cell proliferation. These B cells were EBV-positive by *in situ* hybridization for Epstein-Barr virus Encoded RNA (EBER) (Fig. 5). There was no demonstrable clonal T-cell receptor gene rearrangement in this lesion. These new skin lesions were treated with topical 5% acyclovir ointment six times daily while she continued taking oral bexarotene. These nodular skin lesions on her forehead gradually diminished in size and totally disappeared after four weeks of topical acyclovir treatment (Fig. 3). She continued

with oral bexarotene for another year, when mycosis fungoides progressed with wide spread visceral involvement, causing her death four and a half years after the initial diagnosis.

Discussion

Primary cutaneous lymphomas are the second most common group of extranodal non-Hodgkin lymphomas (1). The final diagnosis in cutaneous lymphoma is based on clinical, histopathologic, immunophenotypic, and molecular criteria. Only 20-25% of cutaneous lymphomas are of B-cell origin, whereas as much as 60-65% are CTCLs (1-2). There are several reports of coexistent cutaneous T-cell lymphomas and B-cell malignancies (7-9). In a review of 19 such cases, 5 had

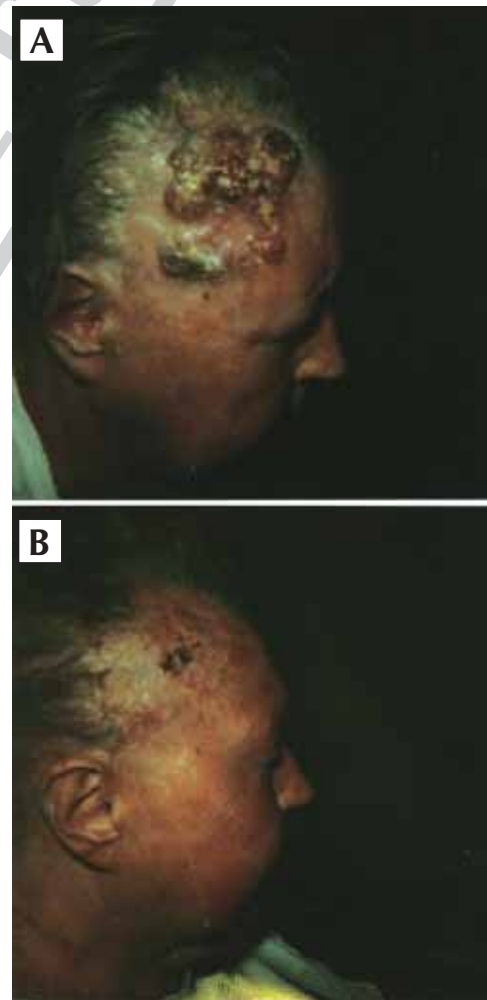


Figure 3. Fungating cauliflower-like ulcerated lesions of Epstein-Barr virus (EBV)-associated cutaneous B-cell lymphoma: (A) before and (B) after topical acyclovir treatment.

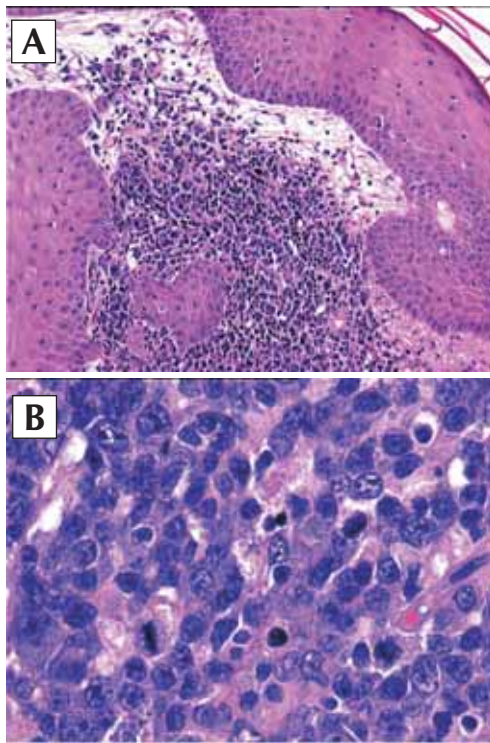


Figure 4. Biopsy of nodular lesion of the forehead. (A) Dense polymorphous lymphoid infiltrate focally hugs the epidermis in this rather tangential skin section evaluated at the medium dry power ($\times 200$ magnification). (B) Oil magnification ($\times 1000$ magnification) reveals a dense infiltrate of large and medium-sized cells with frequent plasmacytoid features. Immunoperoxidase staining for specific antigens showed that cells had a B-cell phenotype, with partial loss of CD20 expression, and were Epstein-Barr virus (EBV) positive.

CTCL preceding the B-cell malignancy, and in another 5 the exact sequence was not clear. The most common B-cell malignancy was CLL (9 cases) (10). The coexistence of two cutaneous non-Hodgkin lymphomas of different lineage is rare. Hull et al (11) reported an 84 year old male patient with mycosis fungoides who later developed chronic lymphocytic leukemia that presented in the skin (leukemia cutis). Kikuchi et al (12) described a patient with long standing erythrodermic cutaneous T-cell lymphoma who developed an EBV-related systemic B-cell lymphoma that spread to involve the skin.

Our patient presented with diffuse erythroderma, skin nodules, and axillary lymphadenopathy without visceral involvement, putting her in the intermediate prognosis group for CTCL (13). After an initial response and stabilization of her CTCL with appropriate treatment, she developed a

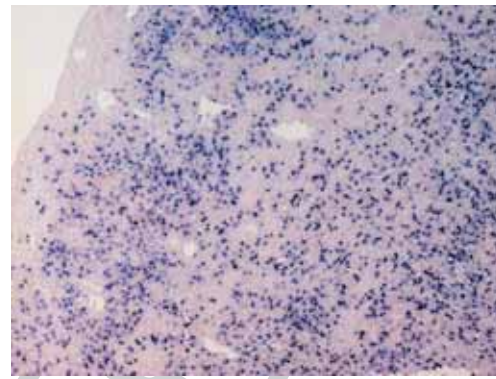


Figure 5. *In situ* hybridization for Epstein-Barr virus Encoded RNA, showing positivity in most of the cells infiltrating the dermis ($\times 100$ magnification).

concurrent EBV-related cutaneous B-cell lymphoma on the skin of her forehead, with no evidence of systemic B-cell lymphoma. Although her EBV-associated B-cell cutaneous lymphoma responded completely to topical acyclovir, the CTCL eventually progressed and caused her death.

Viral infections can be responsible for lymphoproliferative disorders, as illustrated by EBV in endemic Burkitt lymphoma and HTLV-1 in adult T-cell lymphoma leukemia. Additionally, immunosuppressed patients are at risk for EBV induced B-cell lymphoproliferative disorder (LPD) such as post-transplant lymphoproliferative disease (14). Although rare, EBV-related primary cutaneous B-cell LPDs have been reported in several immunocompromised patients (15-17). Lymphoproliferative disorders are more likely to occur in patients with a family history of CTCL and a higher second malignancy risk has been reported in patients with CTCL (18,19). Cytokines are produced by the neoplastic helper/inducer T-lymphocytes in CTCL, as well as normal T-cells. Some of these may promote B-cell growth and subsequent development of a malignant B-cell clone (20-23). Furthermore, an impaired T-cell response caused by CTCL and/or intermittent chemotherapy may permit an uninhibited growth of EBV-transformed B-cells (24,25), leading eventually to a cutaneous B-cell lymphoma.

EBV-related post-transplant lymphoproliferative disorders have been successfully treated by reducing immunosuppression and initiating administration of acyclovir (15,26,27). Acyclovir inhibits continued B-cell proliferation by interrupting EBV replication. Similarly, gancyclovir and

foscarnet are powerful inhibitors of herpesviruses including EBV, but are not available in topical form. Because of the availability, ease of use, and lack of toxicity, we tried topical acyclovir in our patient. Full clinical response to topical acyclovir confirmed the causative role of EBV.

References

- 1 Connors JM, Hsi ED, Foss FM. Lymphoma of the skin. *Hematology (Am Soc Hematol Educ Program)*. 2002; 263-82.
- 2 Querfeld C, Guitart J, Kuzel TM, Rosen ST. Primary cutaneous lymphomas: a review with current treatment options. *Blood Rev*. 2003;17:131-42.
- 3 Tuyp E, Burgoyne A, Aitchison T, MacKie R. A case-control study of possible causative factors in mycosis fungoides. *Arch Dermatol*. 1987;123:196-200.
- 4 Nagore E, Ledesma E, Collado C, Oliver V, Perez-Perez A, Aliaga A. Detection of Epstein-Barr virus and human herpesvirus 7 and 8 genomes in primary cutaneous T- and B-cell lymphomas. *Br J Dermatol*. 2000;143:320-3.
- 5 Wagner M, Rose VA, Linder R, Schulze HJ, Krueger GR. Human pathogenic virus-associated pseudolymphomas and lymphomas with primary cutaneous manifestation in humans and animals. *Clin Infect Dis*. 1998;27: 1299-308.
- 6 Viguier M, Rivet J, Agbalika F, Kerviler E, Brice P, Dubertret L, et al. B-cell lymphomas involving the skin associated with hepatitis C virus infection. *Int J Dermatol*. 2002;41:577-82.
- 7 Weiss VC, Barsky GJ, Solomon LM. Cutaneous T-lymphocyte lymphoma in association with multiple myeloma. *Arch Dermatol*. 1984;120:499-501.
- 8 Allue L, Domingo A, Moreno A, Crespo N, Marcoval J, Peyri J. Simultaneous occurrence of cutaneous T cell lymphoma and low-grade B cell lymphoproliferative diseases. A report of two cases. *J Am Acad Dermatol*. 1990;23(4 Pt 1):677-81.
- 9 Hu E, Weiss LM, Warnke R, Sklar J. Non-Hodgkin's lymphoma containing both B and T cell clones. *Blood*. 1987;70:287-92.
- 10 Grange F, Avril MF, Esteve E, Joly P, Bosq J, de Murets A, et al. Coexistent cutaneous T-cell lymphoma and B-cell malignancy. French Study Group on Cutaneous Lymphomas. *J Am Acad Dermatol*. 1994;31(5 Pt 1):724-31.
- 11 Hull PR, Saxena A. Mycosis fungoides and chronic lymphocytic leukaemia – composite T-cell and B-cell lymphomas presenting in the skin. *Br J Dermatol*. 2000;143: 439-44.
- 12 Kikuchi A, Anzai H, Kosuge H, Naka W, Nishikawa T. Aggressive B-cell lymphoma induced by Epstein-Barr virus infection in erythrodermic cutaneous T-cell lymphoma. *Br J Dermatol*. 1997;136:124-8.
- 13 Sausville EA, Eddy JL, Makuch RW, Fischmann AB, Schechter GP, Matthews M, et al. Histopathologic staging at initial diagnosis of mycosis fungoides and the Sezary syndrome. Definition of three distinctive prognostic groups. *Ann Intern Med*. 1988;109:372-82.
- 14 Hopwood P, Crawford DH. The role of EBV in post-transplant malignancies: a review. *J Clin Pathol*. 2000; 53:248-54.
- 15 Mozzanica N, Cattaneo A, Fracchiolla N, Boneschi V, Berti E, Gronda E, et al. Posttransplantation cutaneous B-cell lymphoma with monoclonal Epstein-Barr virus infection, responding to acyclovir and reduction in immunosuppression. *J Heart Lung Transplant*. 1997;16: 964-8.
- 16 Fardet L, Blanche S, Brousse N, Bodemer C, Fraitag S. Cutaneous EBV-related lymphoproliferative disorder in a 15-year-old boy with AIDS: an unusual clinical presentation. *J Pediatr Hematol Oncol*. 2002;24:666-9.
- 17 Tournadre A, D'Incan M, Dubost JJ, Franck F, Dechelotte P, Souteyrand P, et al. Cutaneous lymphoma associated with Epstein-Barr virus infection in 2 patients treated with methotrexate. *Mayo Clin Proc*. 2001;76:845-8.
- 18 Greene MH, Pinto HA, Kant JA, Siler K, Vonderheid EC, Lamberg SI, et al. Lymphomas and leukemias in the relatives of patients with mycosis fungoides. *Cancer*. 1982;49:737-41.
- 19 Olsen EA, Delzell E, Jegasothy BV. Second malignancies in cutaneous T cell lymphoma. *J Am Acad Dermatol*. 1984;10(2 Pt 1):197-204.
- 20 Salahuddin SZ, Markham PD, Lindner SG, Gootenberg J, Popovic M, Hemmi H, et al. Lymphokine production by cultured human T cells transformed by human T-cell leukemia-lymphoma virus-1. *Science*. 1984; 223:703-7.
- 21 Saed G, Fivenson DP, Naidu Y, Nickoloff BJ. Mycosis fungoides exhibits a Th1-type cell-mediated cytokine profile whereas Sezary syndrome expresses a Th2-type profile. *J Invest Dermatol*. 1994;103:29-33.
- 22 Lee BN, Duvic M, Tang CK, Bueso-Ramos C, Estrov Z, Reuben JM. Dysregulated synthesis of intracellular type 1 and type 2 cytokines by T cells of patients with cutaneous T-cell lymphoma. *Clin Diagn Lab Immunol*. 1999;6:79-84.
- 23 Tartour E, Fossiez F, Joyeux I, Galinha A, Gey A, Claret E, et al. Interleukin 17, a T-cell-derived cytokine, promotes tumorigenicity of human cervical tumors in nude mice. *Cancer Res*. 1999;59:3698-704.
- 24 List AF, Greco FA, Vogler LB. Lymphoproliferative diseases in immunocompromised hosts: the role of Epstein-Barr virus. *J Clin Oncol*. 1987;5:1673-89.
- 25 Gottschalk S, Rooney CM, Heslop HE. Post-transplant lymphoproliferative disorders. *Annu Rev Med*. 2005;56: 29-44.
- 26 Hanto DW, Frizzera G, Gajl-Peczalska KJ, Sakamoto K, Purtilo DT, Balfour HH Jr, et al. Epstein-Barr virus-induced B-cell lymphoma after renal transplantation: acyclovir therapy and transition from polyclonal to monoclonal B-cell proliferation. *N Engl J Med*. 1982; 306:913-8.
- 27 Hanto DW, Frizzera G, Gajl-Peczalska KJ, Sakamoto K, Purtilo DT, Balfour HH, Jr, Simmons RL, Najarian JS. Acyclovir therapy of Epstein-Barr virus induced post-transplant lymphoproliferative disease. *Transplant Proc*. 1985;17:89-92.

Received: February 1, 2005

Accepted: March 29, 2005

Correspondence to:

M. Sitki Copur
Saint Francis Cancer Center
2116 W Fairley Ave
Grand Island, NE 68802-9804, USA
mcpur@sfmc-gi.org