

Full-Endoscopic Interlaminar and Transforaminal Lumbar Discectomy *Versus* Conventional Microsurgical Technique

A Prospective, Randomized, Controlled Study

Sebastian Ruetten, MD, PhD,* Martin Komp, MD, PhD,* Harry Merk, MD,† and Georgios Godolias, MD‡

Study Design. Prospective, randomized, controlled study of patients with lumbar disc herniations, operated either in a full-endoscopic or microsurgical technique.

Objective. Comparison of results of lumbar discectomies in full-endoscopic interlaminar and transforaminal technique with the conventional microsurgical technique.

Summary of Background Data. Even with good results, conventional disc operations may result in subsequent damage due to trauma. Endoscopic techniques have become the standard in many areas because of the advantages they offer intraoperatively and after surgery. With the transforaminal and interlaminar techniques, 2 full-endoscopic procedures are available for lumbar disc operations.

Methods. One hundred seventy-eight patients with full-endoscopic or microsurgical discectomy underwent follow-up for 2 years. In addition to general and specific parameters, the following measuring instruments were used: VAS, German version North American Spine Society Instrument, Oswestry Low-Back Pain Disability Questionnaire.

Results. After surgery 82% of the patients no longer had leg pain, and 14% had occasional pain. The clinical results were the same in both groups. The recurrence rate was 6.2% with no difference between the groups. The full-endoscopic techniques brought significant advantages in the following areas: back pain, rehabilitation, complications, and traumatization.

Conclusion. The clinical results of the full-endoscopic technique are equal to those of the microsurgical technique. At the same time, there are advantages in the operation technique and reduced traumatization. With the surgical devices and the possibility of selecting an interlaminar or posterolateral to lateral transforaminal procedure, lumbar disc herniations outside and inside

the spinal canal can be sufficiently removed using the full-endoscopic technique, when taking the appropriate criteria into account. Full-endoscopic surgery is a sufficient and safe supplementation and alternative to microsurgical procedures.

Key words: endoscopic discectomy, transforaminal discectomy, interlaminar discectomy, percutaneous discectomy, lumbar disc herniation. **Spine 2008;33:931-939**

In spine surgery, the open interlaminar access has been described since the early 20th century.¹⁻⁶ Thirty years after its introduction, alternative methods for operating disc pathologies were developed.⁷ The posterolateral access for vertebral body biopsies was described in the late 1940s.⁸ Percutaneous operations have been performed since the early 1970s.⁹⁻¹⁴ In the late 1970s, a microsurgical procedure involving a microscope was developed to gain interlaminar (IL) access.^{9,15-17} Endoscopes have been used since the early 1980s to inspect the intervertebral space after completed open surgery.¹⁸ The full-endoscopic (FE) transforaminal (TF) operation with posterolateral access evolved out of this.¹⁹⁻³⁴ Endoscope-assisted IL procedures were reported in the literature in the late 1990s.^{2,35-38} The lateral access in FE TF surgery to optimize the route to the spinal canal under continuous visualization has been performed since the late 1990s.³⁹ The development of the FE IL access was seen at the same time.⁴⁰⁻⁴²

Conventional surgeries have been associated with good results.⁴³⁻⁵⁰ Nonetheless, 1 operative consequence is scarring of the epidural space,^{43,51-55} which may be apparent on magnetic resonance imaging^{43,56} but becomes clinically symptomatic in 10% or more of cases^{51,52,55} and makes revision surgery more difficult. An analysis of study results revealed the occurrence of operation-induced destabilization due to the necessary resection of spinal canal structures.^{1,47,57-62} The point of access influences the stabilization and coordination system in the innervation area of the dorsal nerve roots of the spinal nerves.^{53,63,64} The combination of these parameters may explain poor revision-related results.^{52,65,66} The use of microsurgical techniques has reduced tissue damage and its consequences.^{38,67,68} Although conditions of postoperative pain are treatable,^{54,69,70} continuous technical optimization should be attempted. The goal of a new procedure must be to achieve results that commensurate

From the *Department of Spine Surgery and Pain Therapy, Center for Orthopaedics and Traumatology, St. Anna-Hospital Herne, University of Witten/Herdecke, Herne, Germany; †Clinic for Orthopaedics and Orthopaedic Surgery, Ernst Moritz Arndt University Greifswald, Greifswald, Germany; and ‡Center for Orthopaedics and Traumatology, St. Anna-Hospital Herne, University of Witten/Herdecke, Herne, Germany.

Acknowledgment date: April 25, 2007. First revision date: August 25, 2007. Second revision date: December 2, 2007. Acceptance date: December 3, 2007.

The device(s)/drug(s) is/are FDA-approved or approved by corresponding national agency for this indication.

No funds were received in support of this work. No benefits in any form have been or will be received from a commercial party related directly or indirectly to the subject of this manuscript.

Address correspondence and reprint requests to Sebastian Ruetten, MD, PhD, Department of Spine Surgery and Pain Therapy, Center for Orthopaedics and Traumatology, St. Anna-Hospital Herne, Hospitalstrasse 19, 44649 Herne, Germany; E-mail: info@s-ruetten.com

surate with current results⁷¹ while minimizing traumatization and its negative long-term consequences.

Minimally-invasive techniques can reduce tissue damage and its consequences.^{38,67,68} Endoscopic operations have become the standard in many areas. The most widely used FE procedure in patients with lumbar disc disease is TF surgery.^{19–23,26–34,72} Laser and bipolar current may be applied.^{73–75} Removal of the intra- or extraforaminal sequestered material is technically possible.^{26,76} Resection of the sequestered nucleus pulposus material within the spinal canal—that is, a retrograde resection performed intradiscally through the existing annular defect—has been described.^{19–21,31,32,34,77–79} Nonetheless, difficulty in achieving an adequate resection of herniated discs within the spinal canal cannot always be excluded.^{20,39,80–82} With the lateral approach, the spinal canal can be reached more sufficiently under continuous visualization.³⁹ But the osseous perimeter of the foramen and the exiting nerve can limit the working mobility and excision of dislocated herniated material.^{20,31,39} Moreover, the pelvis and the abdominal structures may block access. Thus, there can be limitations to the TF procedure.^{39,40–42} The FE IL access has been developed to enable the extirpation of pathologic entities not successfully achieved using the TF technique.^{40–42}

The goal of this prospective, randomized, controlled study was to compare the results of lumbar discectomies in FE technique via IL and TF approach with those of the conventional microsurgical technique.

■ Materials and Methods

Patient Characteristics

In the prospective, randomized, controlled study, we enrolled 200 patients with clinically-symptomatic disc herniation who underwent discectomies in 2004. There were 116 female and 84 male patients whose age ranged from 20 to 68 years (mean, 43 years). The duration of pain ranged from 1 day to 16 months (mean, 82 days). One hundred sixty-two patients had received a mean of 9 weeks conservative treatment. The indication for surgery was defined according to present-day standards based on radicular pain symptoms and existing neurologic deficits.^{83,84}

Study Groups

One hundred patients each underwent conventional microsurgical (MI), or FE (41 × TF, 59 × IL) discectomy. Randomization was open, since the patients may identify the operation procedure. After determination of the general indication for disc surgery by experienced physicians who were not involved in the operation, randomized assignment was made by nonphysician study staff alternately to the MI or FE group in the sequence of presentation. The surgeon in each case selected the access within the MI and FE group. All operations were performed by 2 surgeons, who have many years of experience in both techniques.

Seventy-seven interventions were performed at the L5–S1 level (39 × MI, 2 × TF, 36 × IL), 64 at L4–L5 (31 × MI, 20 × TF, 13 × IL), 45 at L3–L4 (25 × MI, 13 × TF, 7 × IL), 12 at L2–L3 (5 × MI, 4 × TF, 3 × IL), and 2 at L1–L2 (0 × MI, 2 × TF, 0 × IL).

Inclusion Criteria

All forms of disc herniations were included in the study and randomly assigned to the MI or FE group.

All disc herniations in the MI group localized within the spinal canal were operated under paramedian IL access. A lateral foraminal access was used in the intra- or extraforaminal herniations.

In the FE group all extra- and intraforaminal disc herniations were considered as inclusion criteria for TF access. Based on our earlier experience with limited technical mobility,^{39,85,86} we applied the following inclusion criteria for the TF access if the herniated disc was within the spinal canal: (1) sequestering of material located cranially below the lower edge of the cranial pedicle or caudally not over the middle of the caudal pedicle, and (2) lateral radiologic evidence that the foramen was not overlaid by the pelvis beyond the middle of the cranial pedicle.

The inclusion criteria for IL access were disc herniations located mainly inside the spinal canal, which in our experience were technically difficult to treat using the TF technique given the aforementioned criteria.

Operative Technique

The conventional microsurgical operations were performed with paramedian or lateral access in known standardized technique using a microscope.

The FE TF procedure was performed with access as lateral as possible in the technique described earlier.^{39,85,86} An atraumatic spinal cannula is inserted via the 6 mm skin incision. After insertion of a lead wire, the cannulated dilator is pushed in. Then a surgical sheath with beveled opening is placed. Thereafter, decompression is performed while maintaining visual control and constant irrigation (Figures 1–3). If the anatomic osseous diameter of the intervertebral foramen does not permit direct entry into the spinal canal, the opening is expanded using burrs. In intra- or extraforaminal herniations, or in cases where the position of the exiting nerve is not clear, an extraforaminal approach is made at the caudal pedicle.

The FE IL operation was performed in the technique described earlier.^{40–42,85,87} A dilator is inserted bluntly to the lateral edge of the IL window and an operation sheath with beveled opening directed toward the *Ligamentum flavum*. Thereafter, the procedure is performed under visual control

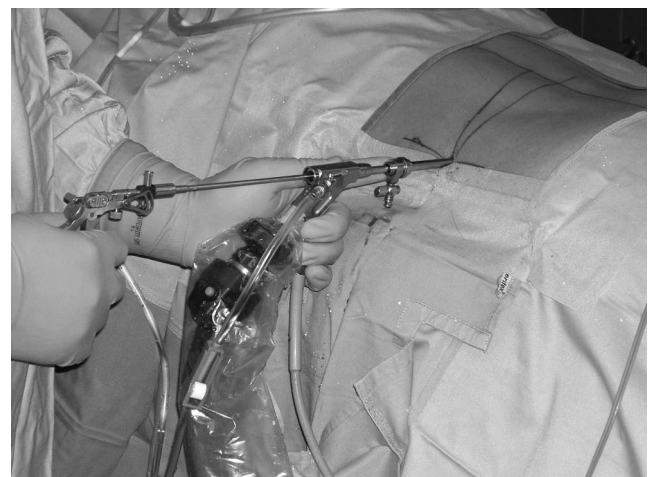

Figure 1. Lateral approach for the full-endoscopic transforaminal operation.

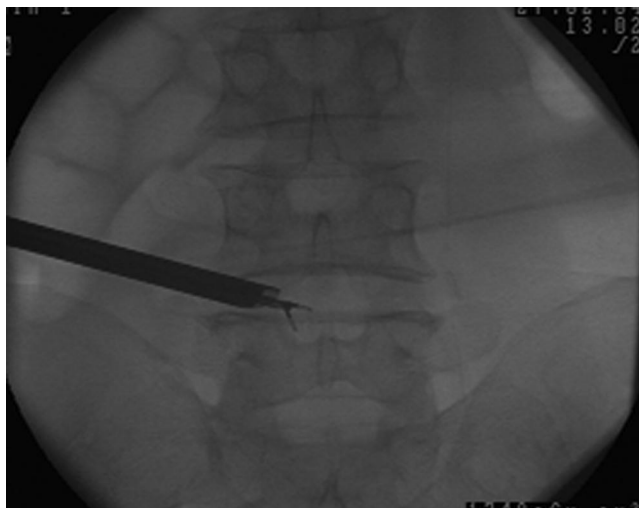


Figure 2. Intraoperative C-arm image of the transforaminal operation.

and constant irrigation (Figures 4–6). A lateral incision of approximately 3 to 5 mm is made in the *Ligamentum flavum*. If the anatomic osseous diameter of the IL window does not allow direct access into the spinal canal through the *Ligamentum flavum*, the opening is expanded further using a burr.

The operation was performed in all groups under general anesthesia. Drainage was applied only in the MI-group. Sequestrotomy alone was performed in small or covered anular defects when the sequestered disc material exceeded the level of the intervertebral space toward cranial or caudal (43 × MI, 39 × FE).

Full-Endoscopic Instruments

The rod-lens optics have an outer diameter of 6.9 mm. The optics contain an intraendoscopic, excentric working canal with a diameter of 4.2 mm. The angle of vision is 25°. The working sheaths used have an outer diameter of 7.9 mm and a beveled opening, which enable creation of visual and working fields in an area without clear anatomically-preformed cavity. All of the operating instruments and optics were products supplied by WOLF (Richard Wolf GmbH, Knittlingen, Germany).

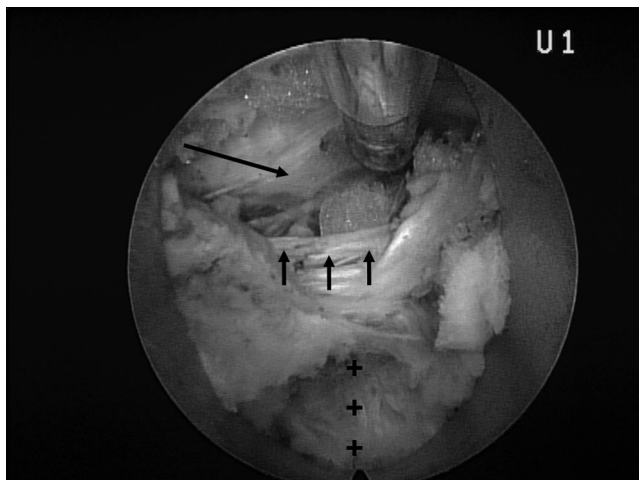


Figure 3. Intraoperative view in transforaminal access with the dura of the *cauda equina* (long arrow), posterior longitudinal ligament (short arrows), and intervertebral disc (crosses).

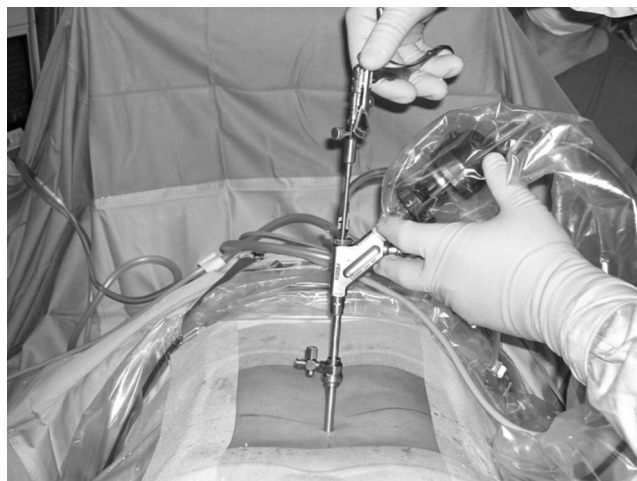

Figure 4. Interlaminar approach for the full-endoscopic operation.

Follow-up

Follow-up examinations were conducted at day 1 (200 patients) and at months 3 (193 patients), 6 (189 patients), 12 (185 patients), and 24 (178 patients) after surgery. All patients received the appropriate questionnaire by mail 4 working days in advance. They came personally to the clinic for follow-up examination. The examinations were performed by 2 physicians in the clinic, who were not involved in the operations. In addition to general parameters, other information was obtained using the following instruments: a VAS for back and leg pain, the German version of the North American Spine Society instrument,^{88,89} and the Oswestry Low-Back Pain Disability Questionnaire (ODI).⁹⁰

Statistical Analysis

The Wilcoxon's rank sum test and the Mann-Whitney *U* test were applied for the comparison of pre- and postoperative global results and comparison of results in the MI *versus* the FE group at various times. The McNemar-Test was used to compare the characteristics of the groups.

The descriptive assessments and analytical statistics were performed depending on the group characteristics with the program package SPSS. A positive significance level was assumed at probability of less than 0.05.

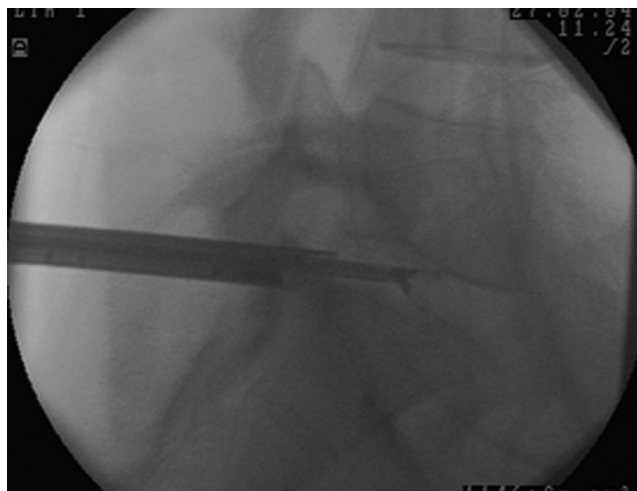


Figure 5. Intraoperative C-arm image of the interlaminar operation.

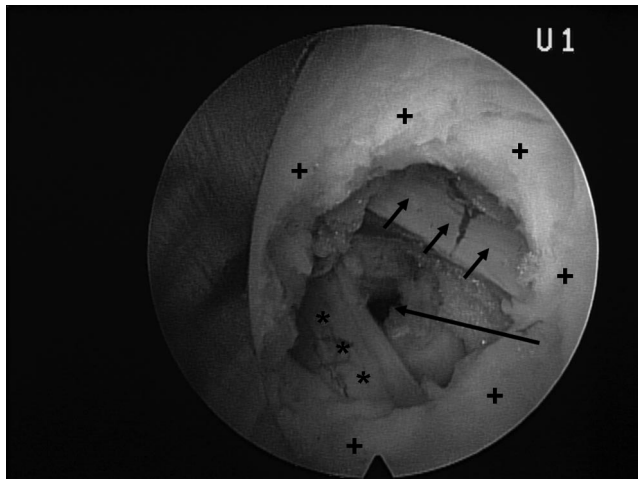


Figure 6. Intraoperative view in interlaminar access with the flammum ligament (crosses), the traversing nerve (stars), dura of the *cauda equina* (short arrows), axilla and defect in the anulus (long arrow).

Results

Baseline Characteristics

One hundred seventy-eight (89%) patients were included in follow-up after 2 years [87 × MI, 91 × FE (38 × TF, 53 × IL)]. The remaining cases were lost for the following reasons: 1 operation-unrelated death, 3 patients moved away and left no forwarding address, 12 patients did not respond to letters or telephone calls, 3 patients underwent revision surgery with conventional spinal canal decompression, and 3 underwent fusion. The patient population was equal in the MI and FE groups. Overall, there were no differences in results in dependence on the individual surgeons.

Operative Technique

The mean operating time in the FE-group was 22 minutes (13–46), and thus significantly shorter ($P < 0.001$) than in the MI-group at 43 minutes (34–72). There were no significant differences within the FE-group (TF 14–37, IL 13–46 minutes). The mean intra- and postoperative blood loss was 45 mL (5–235) in the MI-group; there was no measurable blood loss in the FE-group.

Complete removal of sequestered disc material appeared technically possible based on intraoperative control in combination with the clinical results in both groups. Nonetheless, it cannot be entirely ruled out that portions of the sequester may remain.

Access-related osseous resection was required in 91 cases (91%) in the MI group and in 13 cases (13%) in the FE group (4 × TF = 9.8%, 13 × IL = 22.0%) ($P < 0.001$).

Perioperative Complications

There were no serious complications in either group, such as dural/nerve injury or *cauda equine* syndrome. Eight patients developed a transient postoperative dysesthesia (5 × MI, 1 × TF, 2 × IL). In the MI-group, 2 patients had postoperative bleeding, 1 patient delayed

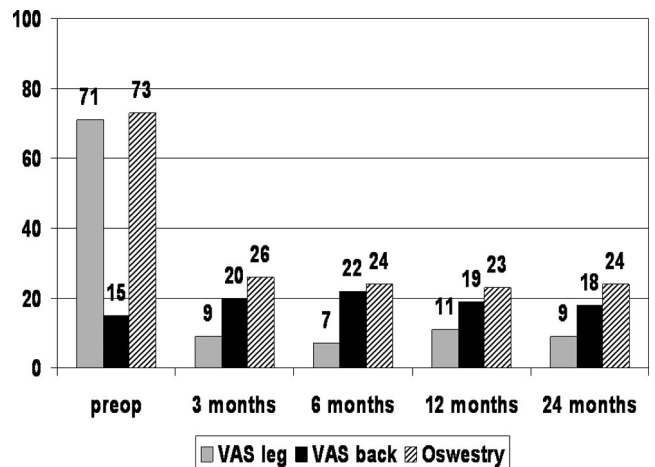


Figure 7. Mean values of VAS leg and back and Oswestry in the MI-group.

wound-healing, 1 patient a soft tissue infection, and 3 patients transient urinary retention. There were no other complications like spondylodiscitis or thrombosis. Overall, the complication rate was significantly elevated in the MI group ($P < 0.05$).

Recurrences

Differentiation was made between 2 types of disc damage: small or covered anular defects; large anular defect. Overall, recurrence was observed in 11 patients (6.2%), 5 times in the MI-group (5.7%) and 6 times in the FE-group (6.6%) (3 × TF = 7.8%, 4 × IL = 5.7%). There were no significant differences. Two recurrences were in the group with small anular defect (1 × MI, 1 × IL), 9 in the group with large anular defect (4 × MI, 3 × TF, 3 × IL) ($P < 0.01$). All patients were reoperated in the same technique as before. The mean operation time in revisions was 57 minutes in the MI-group and 25 minutes in the FE-group. Two patients in the TF-group suffered another recurrence. These repeated recurrences consisted histologically to more than 75% of endplate material.

Clinical Outcome

Figures 7–10 show VAS pain scores, ODI scores, and North American Spine Society Instrument scores. There is constant and significant ($P < 0.001$) improvement in leg pain and daily activities in all groups. After 2 years, 146 (82%) patients no longer had leg pain (69 × MI = 79%, 77 × FE = 85%), 25 (14%) had pain occasionally or the pain was greatly reduced (13 × MI = 15%, 12 × FE = 13%) and 7 (4%) experienced no essential improvement (5 × MI = 6%, 2 × FE = 2%) (Figure 11). The differences in results between the groups were not significant. Twelve patients suffered progradient back pain [10 × MI, 2 × FE ($P < 0.01$)]. Overall, 6 patients (3.3%) (5 × MI, 1 × FE) underwent revision with spinal canal expansion³ and with fusion.³ Neurologic deficits were significantly ($P < 0.001$) reduced when the patient's history of pain was less than 6 days.

One hundred sixty-four (92%) of 178 patients reported subjective satisfaction and would undergo the op-

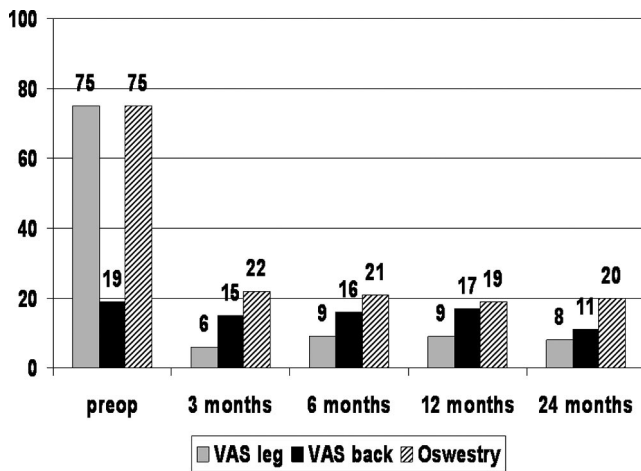


Figure 8. Mean values of VAS leg and back and Oswestry in the FE-group.

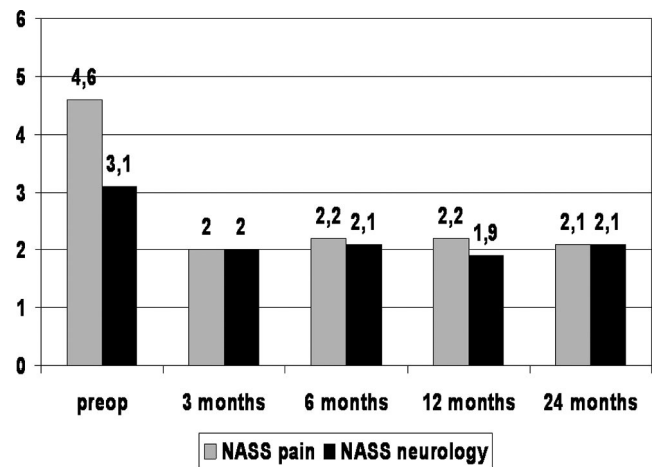


Figure 10. Mean values of NASS pain and neurology in the FE-group.

eration again (77 × MI = 88%, 88 × FE = 97%). Overall, 13 patients had a poor result in terms of no leg pain reduction (7 patients) or had to undergo conventional revision surgery later for persistent leg or back pain (6 patients). Counting the recurrences, a total of 17 (11%) of 184 patients underwent revision (10 × MI, 7 × FE).

Postoperative pain and pain medication were significantly reduced in the FE-group ($P < 0.01$). The mean postoperative work disability in the FE-group was 25 days versus 49 days in the MI-group ($P < 0.01$).

Discussion

To guarantee complete decompression, herniated discs usually have to be resected under visual control, even when a FE technique is used. In terms of posterolateral TF access, various authors have described the removal of sequestered discs from the epidural space via resection from inside the disc through the annular defect.^{19-21,31,32,34} Some authors have described the resection of all forms of disc herniations.^{32,34,78,79,91} The lateral TF access optimizes the route to the spinal canal.^{39,85,86} We, however, see limitations in performing TF procedures, even with a

lateral approach.^{20,39,80-82,85,86} For this reason, the indications, as previously described, could be helpful. Therefore, we use the IL approach in cases in which the herniations are, in our opinion, technically inoperable with the transforminal technique.^{40-42,85} The development of optics with 4.2 mm intraendoscopic working channel and corresponding instruments, shavers and burrs expands the indication spectrum. Parameters such as the osseous diameter of the IL window and intervertebral foramen or the extent of sequestering of the disc material are no longer contraindications and thus operation of every disc herniation is technically possible.^{39-42,85-87}

Studies of endoscopic TF discectomies discuss various operating techniques and indication criteria, but describe good clinical results.^{19-21,31-34,39,40,78,79,85,91-94} The same results are reported for the FE IL operation.^{39-41,85} Microscopic-assisted discectomies achieve good results between 75% and 100%.^{44-50,95} In our study, the clinical results agree with the data in the literature. Comparison studies are hardly still comparative given the operative procedures possible today.^{46,96-99} In our study, a significant and constant improvement was achieved in

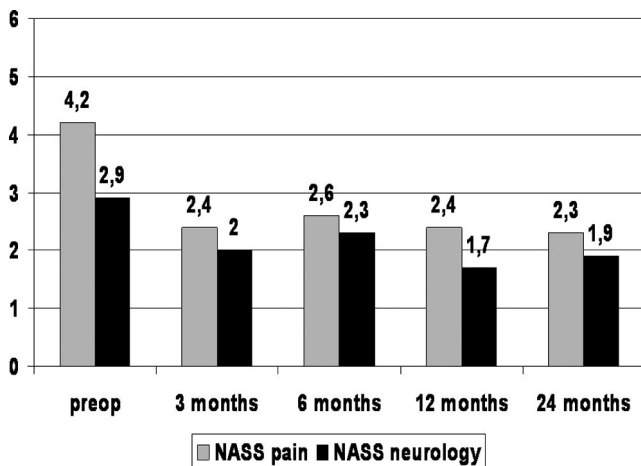


Figure 9. Mean values of NASS pain and neurology in the MI-group.

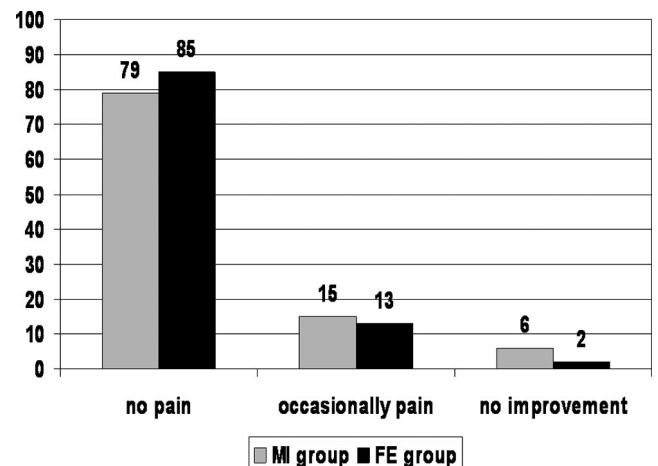


Figure 11. Clinical results in percent in the MI- and FE-group.

the MI- and FE-groups after 2 years without significant differences.

Significantly more patients in the MI-group suffered progradient back pain. Five patients in the MI-group and 1 patient in the FE-group underwent revision with spinal canal expansion or fusion. When resection of spinal canal structures is avoided or the extent reduced, the minimally traumatic disc resection appears capable of reducing operation-induced consequences.^{47,55,100–109} Postoperative pain and work disability were significantly reduced in the FE-group. The rate of nonserious complications was significantly elevated in the MI-group. The results of these parameters in a literature comparison also favor the FE-group.^{80,101,108,110–120} The reduction of neurologic deficits cannot be predicted on the basis of known results.^{52,121}

The rate of recurrent disc herniations was 6.2% and showed no significant differences. The rate corresponds to data in the literature.^{122–126} A large annular defect brought a significantly higher recurrence rate, despite intravertebral extirpation, than a smaller or covered defect. Thus, in our study, an increasing recurrence rate in pure sequestrotomies could not be confirmed. The technical limitations described in extirpation of the intravertebral space in FE technique had no negative effects.^{39,40,85} The type of disc herniation and annular defect appear to be related to the recurrence rate.^{127,128} Minimization of the operation-related annular defect, which is attained in the FE technique, has been discussed as a protective biomechanical factor.^{125,129}

The FE discectomy is possible in uniportal approach in all disc herniations, as reflected in the results of previous studies.^{39–42,85–87} The optics and instruments offer the possibility of bone resection. Thus there are no longer access-related limitations with respect to foraminal stenosis or recess stenosis. The mean operation time in the FE-group of 22 minutes was significantly shorter than in the MI-group with a mean of 42 minutes. No blood loss was observed in the FE-group, no drainage was required. The necessity of resection stabilizing structures was significantly reduced in the FE-group. The FE revisions, unlike those of the MI group, were neither made more difficult nor required longer operation time.¹³⁰ By contrast, epidural scarring, which is made more difficult by revision operations, is expected after the use of conventional techniques.^{43,51–53,55,56,131} Reduced trauma of the *Ligamentum flavum* appears to have certain advantages.^{121,132} When the *Ligamentum flavum* is incised, the opening can be limited to a maximum of 5 mm to insert the endoscope into the spinal canal using the FE IL approach. In applying the FE TF approach, the *Ligamentum flavum* does not need to be opened. The reduction in operation time, traumatization and operation-related sequelae in the FE-group is also found in comparison to the literature.^{80,111,112,114,116–120,133} Although all patients underwent surgery after the induction of general anesthesia in the present study, the use of local anesthetic is also possible.^{26,32–34,72,134}

The goal of surgical treatment of lumbar disc herniations is sufficient decompression with minimization of operation-induced traumatization and its consecutive sequelae. Overall, no disadvantages were found in this study in using the FE technique. The clinical results after 2 years were equal to those of the microsurgical group. This has been taken as the minimum prerequisite for new techniques. At the same time, there are advantages in the operation technique and minimally-invasive procedure around the access and the spinal canal structures.

With the surgical devices and the possibility of selecting an IL or posterolateral to lateral TF procedure, lumbar disc herniations outside and inside the spinal canal can be sufficiently removed using the FE technique, when taking the appropriate criteria into account. We view FE surgery as a sufficient and safe supplementation and alternative to microsurgical procedures. This is a minimally-invasive surgery technique for discectomy, which has long been a validated and established standard procedure. The present study was compared with the most frequently-performed standard microdiscectomy. This is also performed with smaller access using tubular-retractor systems.

In our opinion, the following advantages are offered: facilitation for the operator due to excellent visualization, good illumination, and expanded field of vision with 25° optics; cost-effective procedure due to short operating time, rapid rehabilitation and low postoperative costs of care; reduced anatomic trauma; facilitation of revision operations; monitor image as training basis for assistants. The following must be considered disadvantages: limited possibility of extending the approach in the event of unforeseen hindrances; in the TF technique, the theoretically elevated risk of injury to exiting nerve; and high learning curve.

Attention must be paid especially to the last point of the demanding learning curve in order to avoid complications. Prior observation of/assisting at procedures and workshops with practice on cadavers could be meaningful. Strict adherence to the indication criteria for the appropriate FE access is necessary. “Simple” cases should be operated to begin with, in which no difficulties are to be expected thanks to the anatomic situation. The possibility of intraoperative switch to a standard procedure is helpful if problems are encountered. Nonetheless, it must be remembered that difficulties can never be ruled out during the learning curve.

■ Key Points

- The clinical results of the full-endoscopic technique are equal to those of the microsurgical technique. At the same time, there are advantages in the operation technique and reduced traumatization.

- With the surgical devices and the possibility of selecting an interlaminar or posterolateral to lateral transforaminal procedure, lumbar disc herniations outside and inside the spinal canal can be sufficiently removed using the full-endoscopic technique, when taking the appropriate criteria into account.
- Full-endoscopic surgery is a sufficient and safe supplement and alternative to microsurgical procedures.
- Open and maximally-invasive procedures are necessary in spinal surgery and must be mastered by surgeons so that they also overcome problems and complications encountered when performing full-endoscopic procedures.

References

1. Abumi K, Panjabi MM, Kramer KM, et al. Biomechanical evaluation of lumbar spinal stability after graded facetectomies. *Spine* 1990;15:1142-7.
2. Brayda-Bruno M, Cinnella P. Posterior endoscopic discectomy (and other procedures). *Eur Spine J* 2000;9:24-9.
3. Mixter WJ, Barr JS. Rupture of the intervertebral disc with involvement of the spinal canal. *N Engl J Med* 1934;211:205-10.
4. Putti V. Pathogenesis of sciatic pain. *Lancet* 1927;2:53.
5. Steinke CR. Spinal tumors: statistics on a series of 330 collected cases. *J Nerv Ment Dis* 1918;47:418-26.
6. Stookey B. Compression of spinal cord due to ventral extradural chondromas: diagnosis and surgical treatment. *Arch Neurol Psychiatry* 1928;20:275-91.
7. Hult L. Retroperitoneal disc fenestration in low back pain and sciata. *Acta Orthop Scand* 1956;20:342-8.
8. Valls J, Ottolenghi CE, Schajowicz F. Aspiration biopsy in diagnosis of lesions of vertebral bodies. *JAMA* 1948;136:376.
9. Caspar W. A new surgical procedure for lumbar disc herniation causing less tissue damaging through a microsurgical approach. In: Wüllenweber R, Brock M, eds. *Advances in Neurosurgery* 1977;7:74-7.
10. Gottlob C, Kopchok G, Peng SH, et al. Holmium:YAG laser ablation of human intervertebral disc: preliminary evaluation. *Lasers Surg Med* 1992;12:86-91.
11. Hijikata S. Percutaneous discectomy: a new treatment method for lumbar disc herniation. *J Tohoku Hosp* 1975;5:5-13.
12. Kambin P, Gellman H. Percutaneous lateral discectomy of the lumbar spine: a preliminary report. *Clin Orthop* 1983;174:127-32.
13. Maroon JC, Onik G, Sternau L. Percutaneous automated discectomy: a new approach to lumbar surgery. *Clin Orthop* 1989;238:64-70.
14. Smith L, Garvin PJ, Gesler RM, et al. Enzyme dissolution of the annulus pulposus. *Nature* 1963;198:1311-2.
15. Goald HJ. Microlumbar discectomy—Follow-up of 147 patients. *Spine* 1978;3:183-5.
16. Goald HJ. Microlumbar discectomy: follow-up of 477 patients. *J Microsurg* 1981;2:95-100.
17. Wilson DH, Kenning J. Microsurgical lumbar discectomy: preliminary report of 83 consecutive cases. *Neurosurgery* 1979;42:137-40.
18. Forst R, Hausmann G. Nucleoscopy: a new examination technique. *Arch Orthop Trauma Surg* 1983;101:219-21.
19. Kambin P, Casey K, O'Brien E, et al. Transforaminal arthroscopic decompression of the lateral recess stenosis. *J Neurosurg* 1996;84:462-67.
20. Kambin P, O'Brien E, Zhou L, et al. Arthroscopic microdiscectomy and selective fragmentectomy. *Clin Orthop* 1998;347:150-67.
21. Kambin P, Sampson S. Posterolateral percutaneous suction-excision of herniated lumbar intervertebral discs: report of interim results. *Clin Orthop* 1986;207:37-43.
22. Kambin P, Zhou L. History and current status of percutaneous arthroscopic disc surgery. *Spine* 1996;21:57-61.
23. Kambin P. *Arthroscopic Microdiscectomy*. Baltimore: Urban & Schwarzenberg; 1991.
24. Knight MT, Vajda A, Jakab GV, et al. Endoscopic laser foraminoplasty on the lumbar spine—early experience. *Minim Invasive Neurosurg* 1998;41:5-9.
25. Lee SH, Lee SJ, Park KH, et al. Comparison of percutaneous manual and endoscopic laser discectomy with chemonucleolysis and automated nucleotomy. *Orthopade* 1996;25:49-55.
26. Lew SM, Mehlich TF, Fagone KL. Transforaminal percutaneous endoscopic discectomy in the treatment of far-lateral and foraminal lumbar disc herniations. *J Neurosurg* 2001;94:216-20.
27. Mathews HH. Transforaminal endoscopic microdiscectomy. *Neurosurg Clin North Am* 1996;7:59-63.
28. Mayer HM, Brock M. Percutaneous endoscopic discectomy: surgical technique and preliminary results compared to microsurgical discectomy. *J Neurosurg* 1993;78:261.
29. Savitz MH. Same-day microsurgical arthroscopic lateral-approach laser-assisted (SMALL) fluoroscopic discectomy. *J Neurosurg* 1994;80:1039-45.
30. Siebert W. Percutaneous nucleotomy procedures in lumbar intervertebral disk displacement. *Orthopade* 1999;28:598-608.
31. Stücker R. The transforaminal endoscopic approach. In: Mayer HM, ed. *Minimally Invasive Spine Surgery*. Berlin Heidelberg New York: Springer; 2000:201-6.
32. Tsou PM, Yeung AT. Transforaminal endoscopic decompression for radiculopathy secondary to intracanal noncontained lumbar disc herniations: outcome and technique. *Spine J* 2002;2:41-8.
33. Yeung AT, Yeung CA. Advances in endoscopic disc and spine surgery: foraminal approach. *Surg Technol Int* 2003;11:255-63.
34. Yeung AT, Tsou PM. Posterolateral endoscopic excision for lumbar disc herniation: surgical technique, outcome and complications in 307 consecutive cases. *Spine* 2002;27:722-31.
35. Destandau J. A special device for endoscopic surgery of lumbar disc herniation. *Neurol Res* 1999;21:39-42.
36. Nakagawa H, Kamimura M, Uchiyama S, et al. Microendoscopic discectomy (MED) for lumbar disc prolapse. *J Clin Neurosci* 2003;10:231-5.
37. Perez-Cruet MJ, Foley KT, Isaacs RE, et al. Microendoscopic lumbar discectomy: technical note. *Neurosurgery* 2002;51:129-36.
38. Schick U, Doehner J, Richter A, et al. Microendoscopic lumbar discectomy versus open surgery: an intraoperative EMG study. *Eur Spine* 2002;11:20-6.
39. Ruetten S, Komp M, Godolias G. An extreme lateral access for the surgery of lumbar disc herniations inside the spinal canal using the full-endoscopic uniportal transforaminal approach.—Technique and prospective results of 463 patients. *Spine* 2005;30:2570-8.
40. Ruetten S, Komp M, Godolias G. A new full-endoscopic technique for the interlaminar operation of lumbar disc herniations using 6 mm endoscopes: prospective 2-year results of 331 patients. *Minim Invas Neurosurg* 2006;49:80-7.
41. Ruetten S, Komp M, Godolias G. Full-endoscopic interlaminar operation of lumbar disc herniations using new endoscopes and instruments. *Orthop Praxis* 2005;10:527-32.
42. Ruetten S. The full-endoscopic interlaminar approach for lumbar disc herniations. In: Mayer HM, ed. *Minimally Invasive Spine Surgery*. Berlin Heidelberg New York: Springer; 2005:346-55.
43. Annerzt M, Jonsson B, Stromqvist B, et al. No relationship between epidural fibrosis and sciatica in the lumbar postdiscectomy syndrome. A study with contrast-enhanced magnetic resonance imaging in symptomatic and asymptomatic patients. *Spine* 1995;20:449-53.
44. Ebeling U, Reichenberg W, Reulen HJ. Results of microsurgical lumbar discectomy. Review of 485 patients. *Acta Neurochir* 1986;81:45-52.
45. Ferrer E, Garcia-Bach M, Lopez L, et al. Lumbar microdiscectomy: analysis of 100 consecutive cases. Its pitfalls and final results. *Acta Neurochir Suppl* 1988;43:39-43.
46. Hermantin FU, Peters T, Quartarato LA. A prospective, randomized study comparing the results of open discectomy with those of video-assisted arthroscopic microdiscectomy. *J Bone Joint Surg* 1999;81:958-65.
47. Kotilainen E, Valtonen S. Clinical instability of the lumbar spine after microdiscectomy. *Acta Neurochir* 1993;125:120-6.
48. McCulloch JA. *Principles of Microsurgery for Lumbar Disc Diseases*. Raven Press, NY: Raven Press; 1989.
49. Nystrom B. Experience of microsurgical compared with conventional technique in lumbar disc operations. *Acta Neurol Scand* 1987;76:129-41.
50. Williams RW. Microlumbar discectomy. A 12-year statistical review. *Spine* 1986;11:851-2.
51. Fritsch EW, Heisel J, Rupp S. The failed back surgery syndrome: reasons, intraoperative findings and long term results: a report of 182 operative treatments. *Spine* 1996;21:626-33.
52. Kraemer J. *Intervertebral Disk Diseases*. Stuttgart: Thieme; 1990.
53. Lewis PJ, Weir BKA, Broad RW, et al. Longterm prospective study of lumbosacral discectomy. *J Neurosurg* 1987;67:49-54.

54. Ruetten S, Komp M, Godolias G. Spinal cord stimulation using an 8-pole electrode and double-electrode system as minimally invasive therapy of the post-discectomy and post-fusion syndrome. *Z Orthop* 2002;140:626–31.
55. Schoeggl A, Maier H, Saringer W, et al. Outcome after chronic sciatica as the only reason for lumbar microdiscectomy. *J Spinal Disord Tech* 2002;15:415–9.
56. Ruetten S, Meyer O, Godolias G. Epiduroscopic diagnosis and treatment of epidural adhesions in chronic back pain syndrome of patients with previous surgical treatment: first results of 31 interventions. *Z Orthop* 2002;140:171–5.
57. Maher TR, O'Brien M, Dryer JW, et al. The role of the lumbar facet joints in spinal stability. Identification of alternative paths of loading. *Spine* 1994;19:2667–70.
58. Hopp E, Tsou PM. Postdecompression lumbar instability. *Clin Orthop* 1988;227:143–51.
59. Kaigle AM, Holm SH, Hansson TH. Experimental instability in the lumbar spine. *Spine* 1995;20:421–30.
60. Kato Y, Panjabi MM, Nibu K. Biomechanical study of lumbar spinal stability after osteoplastic laminectomy. *J Spinal Disord* 1998;11:146–50.
61. Kotilainen E. Clinical instability of the lumbar spine after microdiscectomy. In: Gerber BE, Knight M, Siebert WE, eds. *Lasers in the Musculoskeletal System*. Berlin Heidelberg New York: Springer; 2001:241–3.
62. Sharma M, Langrana NA, Rodrigues J. Role of ligaments and facets in lumbar spinal stability. *Spine* 1995;20:887–900.
63. Cooper R, Mitchell W, Illingworth K, et al. The role of epidural fibrosis and defective fibrinolysis in the persistence of postlaminectomy back pain. *Spine* 1991;16:1044–8.
64. Waddell G, Reilly S, Torsney B, et al. Assessment of the outcome of low back surgery. *J Bone Joint Surg Br* 1988;70:723–7.
65. Hedtmann A. The so-called post-discectomy syndrome – failure of intervertebral disc surgery? *Z Orthop* 1992;130:456–66.
66. Kim SS, Michelsen CB. Revision surgery for failed back surgery syndrome. *Spine* 1992;17:957–60.
67. Parke WW. The significance of venous return in ischemic radiculopathy and myelopathy. *Orthop Clin North Am* 1991;22:213–20.
68. Weber BR, Grob D, Dvorak J, et al. Posterior surgical approach to the lumbar spine and its effect on the multifidus muscle. *Spine* 1997;22:1765–72.
69. Devulder J, De Laat M, Van Batselaere M, et al. Spinal cord stimulation: a valuable treatment for chronic failed back surgery patients. *J Pain Symptom Manage* 1997;13:296–301.
70. Rainov NG, Heidecke V, Burkert W. Short test-period spinal cord stimulation for failed back surgery syndrome. *Minim Invasive Neurosurg* 1996;39:41–4.
71. Maroon JC. Current concepts in minimally invasive discectomy. *Neurosurgery* 2002;51:137–45.
72. Chiu JC, Clifford T, Princenthal R, et al. Junctional disc herniation syndrome in post spinal fusion treated with endoscopic spine surgery. *Surg Technol Int* 2005;14:305–15.
73. Epstein J, Adler R. Laser-assisted percutaneous endoscopic neurolysis. *Pain Physician* 2000;3:43–5.
74. Ruetten S, Godolias G. Possibilities of epiduroscopy in the treatment of chronic back pain syndrome using holmium laser and instruments.—First results of 53 patients having had no previous surgical treatment. *Orthop Praxis* 2002;38:315–8.
75. Ruetten S, Meyer O, Godolias G. Application of holmium:YAG laser in epiduroscopy: extended practicabilities in the treatment of chronic back pain syndrome. *J Clin Laser Med Surg* 2002;20:203–6.
76. Jang JS, An SH, Lee SH. Transforaminal percutaneous endoscopic discectomy in the treatment of foraminal and extraforaminal lumbar disc herniations. *J Spinal Disord Tech* 2006;19:338–43.
77. Adson AW, Ott WO. Results of the removal of tumors of the spinal cord. *Arch Neurol Psychiatry* 1922;8:520–38.
78. Yeung AT. Minimally invasive disc surgery with the Yeung Endoscopic Spine System (YESS). *Surg Technol Int* 2000;8:267–77.
79. Yeung AT. The evolution of percutaneous spinal endoscopy and discectomy: state of the art. *Mt Sinai J Med* 2000;67:327–32.
80. Choi G, Lee SH, Raiturker PP, et al. Percutaneous endoscopic interlaminar discectomy for intracanalicular disc herniations at L5–S1 using a rigid working channel endoscope. *Neurosurgery* 2006;58(suppl 1):S59–S68.
81. Lee SH, Kang BU, Ahn Y, et al. Operative failure of percutaneous endoscopic lumbar discectomy: a radiologic analysis of 55 cases. *Spine* 2006;31:285–90.
82. Schubert M, Hoogland T. Endoscopic transforaminal nucleotomy with foraminoplasty for lumbar disc herniation. *Oper Orthop Traumatol* 2005;17:641–61.
83. Andersson GBJ, Brown MD, Dvorak J, et al. Consensus summary on the diagnosis and treatment of lumbar disc herniation. *Spine* 1996;21:75–8.
84. McCulloch JA. Focus issue on lumbar disc herniation: macro- and microdiscectomy. *Spine* 1996;21:45–56.
85. Ruetten S, Komp M, Merk H, et al. Full-endoscopic operation of lumbar disc herniations with the interlaminar and lateral transforaminal approach using new developed instruments and endoscopes. *J Neurosurg Spine* 2007;6:521–30.
86. Ruetten S, Komp M, Godolias G. New developed devices for the full-endoscopic lateral transforaminal operation of lumbar disc herniations. *WSJ* 2006;3:157–65.
87. Ruetten S, Komp M, Godolias G. Lumbar discectomy with the full-endoscopic interlaminar approach using new developed optical systems and instruments. *WSJ* 2006;3:148–56.
88. Daltroy LH, Cats-Baril WL, Katz JN, et al. The North American Spine Society (NASS) lumbar spine outcome instrument: reliability and validity tests. *Spine* 1996;21:741–9.
89. Pose B, Sangha O, Peters A, et al. Validation of the North American spine society instrument for assessment of health status in patients with chronic backache. *Z Orthop* 1999;137:437–41.
90. Fairbank JCT, Couper J, Davies JB, et al. The Oswestry low back pain questionnaire. *Physiotherapy* 1980;66:271–3.
91. Ahn Y, Lee SH, Park WM, et al. Percutaneous endoscopic lumbar discectomy for recurrent disc herniation: surgical technique, outcome and prognostic factors of 43 consecutive cases. *Spine* 2004;29:326–32.
92. Lee SH, Kim SK, Ahn Y, et al. The preoperative radiological findings that affect the clinical outcomes after percutaneous endoscopic lumbar discectomy. *WSJ* 2006;1:133–40.
93. Hoogland T, Schubert M, Miklitz B, et al. Transforaminal posterolateral endoscopic discectomy with or without the combination of a low-dose Chymopapain: a prospective randomized study in 280 consecutive cases. *Spine* 2006;24:890–7.
94. Mariconda M, Galasso O, Secondulfo V, et al. Minimum 25-year outcome and functional assessment of lumbar discectomy. *Spine* 2006;31:2593–9.
95. Andrews DW, Lavyne MH. Retrospective analysis of microsurgical and standard lumbar discectomy. *Spine* 1990;15:329–35.
96. Schreiber A, Suezawa Y, Leu H. Does percutaneous nucleotomy with discoscopy replace conventional discectomy? Eight years of experience and results in treatment of herniated lumbar disc. *Clin Orthop Relat Res* 1989;238:35–42.
97. Mayer HM, Brock M. Percutaneous endoscopic discectomy: surgical technique and preliminary results compared to microsurgical discectomy. *J Neurosurg* 1993;78:216–25.
98. Lee SH, Chung SE, Ahn Y, et al. Comparative radiologic evaluation of percutaneous endoscopic lumbar discectomy and open microdiscectomy: a matched cohort analysis. *Mt Sinai J Med* 2006;73:795–801.
99. Schmid UD. Microsurgery of lumbar disc prolapse. Superior results of microsurgery as compared to standard- and percutaneous procedures (review of literature). *Nervenarzt* 2000;71:265–74.
100. Ebara S, Harada T, Hosono N, et al. Intraoperative measurement of lumbar spinal instability. *Spine* 1992;17:44–50.
101. Faulhauer K, Manicke C. Fragment excision versus conventional disc removal in the microsurgical treatment of herniated lumbar disc. *Acta Neurochir (Wien)* 1995;133:107–11.
102. Goel VK, Nishiyama K, Weinstein JN, et al. Mechanical properties of lumbar spinal motion segments as affected by partial disc removal. *Spine* 1986;11:1008–12.
103. Iida Y, Kataoka O, Sho T, et al. Postoperative lumbar spinal instability occurring or progressing secondary to laminectomy. *Spine* 1990;15:1186–9.
104. Johnsson KE, Redlund-Johnell I, Uden A, et al. Preoperative and postoperative instability in lumbar spinal stenosis. *Spine* 1989;14:591–3.
105. Kambin P, Cohen L, Brooks ML, et al. Development of degenerative spondylosis of the lumbar spine after partial discectomy: comparison of laminotomy, discectomy and posterolateral discectomy. *Spine* 1994;20:599–607.
106. Mochida J, Toh E, Nomura T. The risks and benefits of percutaneous nucleotomy for lumbar disc herniation. A 10-year longitudinal study. *J Bone Joint Surg Br* 2001;83:501–5.
107. Natarajan RN, Andersson GB, Padwardhan AG, et al. Study on effect of graded facetectomy on change in lumbar motion segment torsional flexibility using three-dimensional continuum contact representation for facet joints. *J Biomech Eng* 1999;121:215–21.
108. Ross JS, Robertson JT, Frederickson RC, et al. Association between peridural scar and recurrent radicular pain after lumbar discectomy: magnetic resonance evaluation. *Neurosurgery* 1996;38:861–3.

109. Zander T, Rohlmann A, Kloeckner C, et al. Influence of graded facetectomy and laminectomy on spinal biomechanics. *Eur Spine J* 2003;12:427–34.
110. Balderston RA, Gilyard GG, Jones AM, et al. The treatment of lumbar disc herniation: simple fragment excision versus disc space curettage. *J Spinal Disord* 1991;4:22–5.
111. Bucky PC. Chondroma of intervertebral disc. *JAMA* 1930;94:1552.
112. Caspar W, Campbell B, Barbier DD, et al. The Caspar microsurgical discectomy and comparison with a conventional standard lumbar disc procedure. *Neurosurgery* 1991;28:78–87.
113. Donceel P, Du Bois M. Fitness for work after lumbar disc herniation: a retrospective study. *Eur Spine* 1998;7:29–35.
114. Mayer HM. The microsurgical interlaminar, paramedian approach. In: Mayer HM, ed. *Minimally Invasive Spine Surgery*. Berlin Heidelberg New York: Springer; 2000:79–91.
115. Mochida J, Nishimura K, Nomura T, et al. The importance of preserving disc structure in surgical approaches to lumbar disc herniation. *Spine* 1996;21:1556–64.
116. Ramirez LF, Thisted R. Complications and demographic characteristics of patients undergoing lumbar discectomy in community hospitals. *Neurosurgery* 1989;25:226–31.
117. Rantanen J, Hurme M, Falck B, et al. The lumbar multifidus muscle five year after surgery for a lumbar intervertebral disc herniation. *Spine* 1993;18:568–74.
118. Rompe JD, Eysel P, Zollner J, et al. Intra- and postoperative risk analysis after lumbar intervertebral disk operation. *Z Orthop* 1999;137:201–5.
119. Stolke D, Sollmann WP, Seifert V. Intra- and postoperative complications in lumbar disc surgery. *Spine* 1989;14:56–9.
120. Wildfoerster U. Intraoperative complications in lumbar intervertebral disc operations. Cooperative study of the spinal study group of the German Society of Neurosurgery. *Neurochirurgica* 1991;34:53–6.
121. Aydin Y, Ziyal IM, Dumam H, et al. Clinical and radiological results of lumbar microdiscectomy technique with preserving of ligamentum flavum comparing to the standard microdiscectomy technique. *Surg Neurol* 2002;57:5–13.
122. Boyer P, Srour R, Buchheit F, et al. Lumbar disc hernia. Excision of hernia with or without complementary discectomy? *Neurochirurgie* 1994;40:259–62.
123. Hirabayashi S, Kumano K, Ogawa Y, et al. Microdiscectomy and second operation for lumbar disc herniation. *Spine* 1993;18:2206–11.
124. Stambough JL. Lumbar disk herniation: an analysis of 175 surgically treated cases. *J Spinal Disord* 1997;10:488–92.
125. Wenger M, Mariani L, Kalbarczyk A, et al. Long-term outcome of 104 patients after lumbar sequestrectomy according to Williams. *Neurosurgery* 2001;49:329–34.
126. Carragee EJ, Spinnikie AO, Alamin TF, et al. A prospective controlled study of limited versus subtotal posterior discectomy: short-term outcomes in patients with herniated lumbar intervertebral discs and large posterior anular defect. *Spine* 2006;31:653–7.
127. Yorimitsu E, Chiba K, Toyama Y, et al. Long-term outcomes of standard discectomy for lumbar disc herniation. *Spine* 2001;26:652–7.
128. Carragee EJ, Han MY, Suen PW, et al. Clinical outcomes after lumbar discectomy for sciata: the effects of fragment type and anular competence. *J Bone Joint Surg Am* 2003;85:102–8.
129. Zollner J, Rosendahl T, Herbsthofner B, et al. The effect of various nucleotomy techniques on biomechanical properties of the intervertebral disc. *Z Orthop* 1999;137:206–10.
130. Suk KS, Lee HM, Moon SH, et al. Recurrent lumbar disc herniation: results of operative management. *Spine* 2001;26:672–6.
131. Ruetten S, Meyer O, Godolias G. Endoscopic surgery of the lumbar epidural space (epiduroscopy): results of therapeutic intervention in 93 patients. *Minim Invasive Neurosurg* 2003;46:1–4.
132. De Devitiis E, Cappabianca P. Lumbar discectomy with preservation of the ligamentum flavum. *Surg Neurol* 2002;58:68–9.
133. Wilson DH, Harbaugh R. Lumbar discectomy: a comparative study of microsurgical and standard technique. In: Hardy RW, ed. *Lumbar disc disease*. New York: Raven Press; 1982:147–56.
134. Chiu JC. Evolving transforaminal endoscopic microdecompression for herniated lumbar discs and spinal stenosis. *Surg Technol Int* 2004;13:276–86.