

# Fulminant legionellosis in two patients treated with infliximab for Crohn's disease: Case series and literature review

Adam Hofmann MD<sup>1</sup>, Yanick Beaulieu MD FRCPC<sup>2</sup>, Francis Bernard MD FRCPC<sup>3</sup>, Philippe Rico MD FRCPC<sup>3</sup>

---

A Hofmann, Y Beaulieu, F Bernard, P Rico. Fulminant legionellosis in two patients treated with infliximab for Crohn's disease: Case series and literature review. *Can J Gastroenterol* 2009;23(12):829-833.

Two cases of fulminant pulmonary legionellosis, complicated by prolonged intensive care unit stays and acute respiratory distress syndrome, and who were recently treated with infliximab for Crohn's disease, are described. A review of the literature revealed three additional cases in patients with inflammatory bowel disease, and a total of 22 cases of *Legionella pneumophila* pneumonia in the context of treatment with antitumour necrosis (TNF)-alpha medications. The median age of the patients was 49 years, and men and women were affected equally. The case fatality rate was 14% (three of 22). Early recognition and treatment of this anti-TNF-alpha-related complication would likely result in reduced mortality and morbidity. Physicians prescribing anti-TNF-alpha drugs should be aware of this association.

**Key Words:** Crohn's disease; Infliximab; *Legionella pneumophila*; Tumour necrosis factor-alpha

*Legionella pneumophila* is a ubiquitous intracellular pathogen, and a common etiological agent in community-acquired pneumonia (1). The association of *L pneumophila* pneumonia with antitumour necrosis factor (TNF)-alpha has been reported previously in the literature (2-10) and twice before in patients receiving infliximab for Crohn's disease (4,5). With the growing popularity of anti-TNF-alpha agents for the treatment of inflammatory bowel disease, it is important for physicians to be aware of this readily treatable and potentially life-threatening complication. Two cases of fulminant legionellosis associated with recent infliximab therapy in the context of Crohn's disease are reported, followed by a review and synthesis of the literature describing this association.

## CASE PRESENTATIONS

Both cases were transferred from the referring community hospital to the intensive care unit (ICU) of the Hôpital Sacré-Cœur (Montreal, Quebec) for advanced ventilatory management. At the time of transfer, the referring hospital was undergoing major renovations to its physical plant, including its water supply system. To date, three patients with nosocomial *L pneumophila* pneumonia have been found and local public health authorities have conducted an outbreak investigation.

## Légionellose fulminante chez deux patients traités par infliximab pour maladie de Crohn : Série de cas et revue de la littérature

On décrit ici deux cas de légionellose pulmonaire fulminante compliqués de séjours prolongés aux soins intensifs et d'un syndrome de détresse respiratoire aiguë qui avaient récemment été traités par infliximab pour une maladie de Crohn. Une revue de la littérature a révélé trois autres cas chez des patients atteints de maladie inflammatoire de l'intestin et, en tout, 22 cas de pneumonie à *Legionella pneumophila* dans le contexte d'un traitement par anti-TNF-alpha. L'âge médian des patients était de 49 ans et les hommes et les femmes étaient affectés dans une même proportion. Le taux de mortalité a été de 14 % (trois sur 22). La reconnaissance et le traitement précoces de cette complication liée aux anti-TNF-alpha permettraient de réduire la mortalité et la morbidité. Les médecins qui prescrivent des anti-TNF-alpha doivent être au courant de ce lien.

---

## Case A

A 26-year-old electrician was admitted to the referring hospital two months before transfer for investigation of chronic diarrhea, fistula-in-ano and abdominal pains. The patient's medical history was significant for a motor vehicle collision and a work accident that left him with chronic lumbar spinal pain and post-traumatic stress disorder, for which he took the equivalent of 60 mg of morphine daily and was followed by psychiatry. There was no history of repeated infection or immunodeficiency. During his hospitalization at the referring hospital, he was investigated with a colonoscopy and an abdominal computed tomography scan – a diagnosis of Crohn's disease was tentatively made; however, the patient did not display any extraintestinal manifestations of Crohn's disease. He was treated with prednisone 1 mg/kg/day and escalating doses of 6-mercaptopurine to 1 mg/kg/day, with no response. One month before transfer, the patient received a 5 mg/kg induction dose of infliximab. One week before transfer, he began to experience persistent fevers, with no associated symptoms. On the day of transfer, he experienced rapidly progressive respiratory failure, going from ambient air in the morning to severe hypoxic respiratory failure requiring intubation by the evening. On arrival to hospital, the patient was sedated and intubated. The physical examination revealed a large, muscular,

---

<sup>1</sup>Department of General Internal Medicine, McGill University Faculty of Medicine; <sup>2</sup>Department of Cardiology and Critical Care; <sup>3</sup>Department of Internal Medicine and Critical Care, Hôpital Sacré-Cœur, Montreal University, Montreal, Quebec

Correspondence: Dr Adam Hofmann, Department of Internal Medicine, Sir Mortimer B Davis Jewish General Hospital, Suite G-050, 3755 Côte-Sainte-Catherine Road, Montreal, Quebec H3T 1E2. Telephone 514-340-8222 ext 4974, fax 514-340-7905, e-mail adam.hofmann@mail.mcgill.ca

Received for publication March 13, 2009. Accepted March 22, 2009

**TABLE 1**  
**Clinical characteristics of tumour necrosis factor (TNF)-alpha antagonist-associated legionellosis patients**

Author (reference)	Age, years	Sex	Anti-TNF-alpha drug	Treatment duration	Indication	Concomitant immunosuppressive therapy	Comorbidities	Clinical and radiological features	Community-acquired (C) or nosocomial (N)	Diagnostic modality (serogroup)	Antibiotic therapy	Outcome
<b>Inflammatory bowel disease-associated clinical cases</b>												
Case A	26	M	IFMB (5 mg/kg)	4 weeks	CD	MP, Prednisone	Smoker	BL pneumonia, ARDS requiring HFOV, acute kidney damage requiring hemodialysis	N	LPAg-positive (LP1)	Macrolide	Admitted to ICU, severe hypoxia, hemodialysis-dependent, recovered
Case B	59	M	IFMB (5 mg/kg, two doses)	4 weeks	CD	Methyl-prednisolone	Smoker	BL pneumonia with abscess formation, ARDS requiring HFOV	N	LPAg-positive (LP1)	Macrolide	Admitted to ICU, died as a result of complications of his ICU stay, and sequelae of a massive vertebrobasilar stroke
Beigel et al (2)	58	M	IFMB		CD	Azathioprine, mesalamine, prednisolone	Smoker	UL pneumonia, respiratory failure requiring ICU admission	C	BAL culture, LPAg-positive (LP1)	FLQ	Admitted to ICU, 2 weeks of mechanical ventilation, complete recovery
Kohn et al (4)	71	M	IFMB	11 days	UC	Mesalazine, IV glucocorticoids	N/A	N/A	N	PCR of sputum sample	N/A	Death from septic shock
Tubach et al (5)	27	F	IFMB (250 mg)	1 week	CD	Azathioprine (200 mg/day), prednisone 15 mg/day	None	ARDS, UL pneumonia	C	LPAg-positive (LP1), BAL culture	Rifampicin, FLQ	Recovered, experienced second episode with reintroduction of IFMB
<b>Clinical cases associated with other rheumatic conditions or other inflammatory condition indications for anti-TNF-alpha therapy</b>												
Tubach et al (5)	43	M	ALMB (40 mg biweekly)	71 weeks	RA	MTX, Prednisone	Diabetes mellitus	BL pneumonia, vomiting	C	LPAg-positive (LP1)	FLQ	Recovered
Tubach et al (5)	55	F	ALMB (40 mg monthly)	26 weeks	RA	MTX (7.5 mg/week), prednisone (8 mg/day)	None	UL pneumonia	C	LPAg-positive (LP1)	Macrolide, rifampicin	Recovered
Tubach et al (5)	67	M	ETCP (25 mg twice weekly)	16 weeks	RA	MTX (12.5 mg/week), prednisolone (10 mg/day)	Tobacco-related COPD	UL multilobar pneumonia, ARDS, acute kidney damage requiring hemodialysis	C	LPAg positive (LP1) and BAL culture	Rifampicin, FLQ	Admitted to ICU, recovered
Tubach et al (5)	46	F	IFMB	73 weeks	PD	Prednisone (10 mg/day), thrombopobroman (75 mg/day)	Primary thrombocytopenia	BL lower lobe pneumonia, pleural effusion, ARDS, nausea	C	LPAg-positive (LP1)	Macrolide, rifampicin	Admitted to ICU, alive at discharge
Tubach et al (5)	58	M	IFMB (5 mg/kg)	3 weeks	Psoriasis	None	Smoker (15 pack-years)	UL upper lobe pneumonia, small pleural effusion	C	LPAg-positive (LP1) and PCR-positive sputum samples	Macrolide, FLQ	Recovered
Tubach et al (5)	40	M	ALMB (40 mg biweekly)	34 weeks	RA	Sulfasalazine (2 g/day), betamethasone (2 mg/day)	Diabetes mellitus, tobacco-related COPD	UL bilobar pneumonia, myalgia, vomiting	C	LPAg-positive (LP1)	Rifampicin, FLQ	Recovered

Continued on next page

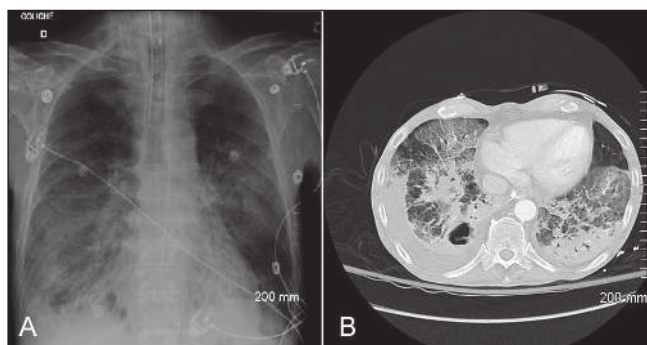
TABLE 1 - CONTINUED

Author (reference)	Age, years	Sex	Anti-TNF-alpha drug	Treatment duration	Indication	Concomitant immunosuppressive therapy	Comorbidities	Clinical and radiological features	Community-acquired (C) or nosocomial (N)	Diagnostic modality (serogroup)	Antibiotic therapy	Outcome
Tubach et al (5)	45	F	ALMB (40 mg biweekly)	36 weeks	JRA	MTX (15 mg/week), prednisone (5 mg/day)	Smoker	UL pneumonia, delirium	C	LPAG-positive (LP1)	Macrolide, then FLQ	Recovered
Tubach et al (5)	66	F	ALMB (40 mg biweekly)	45 weeks	RA	MTX (15 mg/week)	None	Abdominal pain, BL interstitial pneumonia, ARDS, acute kidney damage	C	LP6, seroconversion	FLQ, ceftriaxone	Recovered
Tubach et al (5)	47	M	ALMB (40 mg biweekly)	50 weeks	RA	Prednisone (5 mg/day)	Smoker, water-cleaning system worker	BL upper lobe pneumonia, ARDS, pneumothorax	C	LPAG-positive (LP1), BAL culture	Rifampicin, FLQ	Admitted to ICU, recovered
Tubach et al (5)	69	F	ETCP (25 mg twice weekly); IFMB (3 mg/kg)	45 weeks	RA	MTX (7.5 mg/week), prednisone (5 mg/day)	None	BL diffuse interstitial pneumonia, dyskinnesia, delirium, diarrhea	C	LPAG-positive (LP1)	FLQ	Recovered
Dixon et al (10)	49	M	IFMB	16 weeks	RA	N/A	N/A	N/A	N/A	N/A	N/A	N/A
Dixon et al (10)	59	M	IFMB	128 weeks	RA	N/A	N/A	N/A	N/A	N/A	N/A	N/A
Eisendle and Fritsch (9)	56	M	IFMB (5 mg/kg, two doses)	2 weeks	EP	Prednisolone 20 mg/day	Diabetes mellitus and steroid myopathy	UL pneumonia, septic shock	C	LPAG-negative, BAL and postmortem culture for serogroup 4 and 10	FLQ	Death from multiorgan failure
Li Gobbi et al (6)	38	F	IFMB (3mg/kg; total 200 mg)	2 weeks	RA	MTX (15 mg/week)	None	UL pneumonia	C	LPAG-positive (LP1)	Macrolide	Recovered
Mancini et al (3)	30	M	IFMB (5 mg/kg)	4 weeks	Behçet's disease	MTX	Pulmonary TB from previous cycle of IFMB	UL pneumonia, pleural and pericardial effusions	C	LPAG-positive (LP1)	FLQ, rifampicin	Recovered
Albert et al (8)	73	F	IFMB (150 mg bimonthly)	72 weeks	RA	MTX (15 mg/week), prednisone (5 mg/day)	None	UL pneumonia	C	LPAG-negative, BAL culture positive (serogroup 1)	FLQ	Recovered, resumed IFMB therapy with no sequelae

ALMB Adalimumab; ARDS Acute respiratory distress syndrome; BAL Bronchoalveolar lavage; BL Bilateral; CD Crohn's disease; COPD Chronic obstructive pulmonary disease; EP Erythrodermic psoriasis; ETCP Etanercept; F Female; FLQ Fluoroquinolone; HFOV High-frequency oscillation ventilation; IBD Inflammatory bowel disease; ICU Intensive care unit; IFMB Infliximab; IV Intravenous; JRA Juvenile-onset rheumatoid arthritis; LP Legionella pneumophila; LPAG L pneumophila antigen; M Male; MP 6-mercaptopurine; MTX Methotrexate; N/A Information not available; NSAID Nonsteroidal anti-inflammatory drugs; PCR Polymerase chain reaction; PD Pyoderma gangrenosum; RA Rheumatoid arthritis; TB Tuberculosis; UC Ulcerative colitis; UL Unilateral

young man with no wasting or dermatological abnormalities. The patient was tachypneic and the lung examination revealed diffuse rales on auscultation. The abdominal and lymphatic examinations were unremarkable. There was a partially healed anal fistula. The patient's initial x-ray demonstrated diffuse bilateral patchy and interstitial opacities (Figure 1A). He was started on piperacillin-tazobactam and vancomycin adjusted to renal clearance, azithromycin 500 mg intravenously (IV) daily and caspofungin 50 mg IV daily. Blood was drawn for cultures and urine legionella and pneumococcal antigens were

requested. The patient rapidly became difficult to oxygenate and required high-frequency oscillation ventilation to maintain a partial pressure of oxygen of more than 60 mmHg. On day 2 of his admission, the legionella antigen test (Inverness-Binax, USA) returned a positive result for serogroup 1 *L pneumophila*. The patient recovered sufficiently to be extubated on day 9 of admission. He was treated with a 21-day course of azithromycin. He was left with residual severe kidney disease requiring hemodialysis secondary to acute tubular necrosis, but has otherwise fully recovered.



**Figure 1) A** The patient in case A presented in acute respiratory distress following *Legionella pneumophila* infection, subsequent to infliximab therapy. His initial chest x-ray demonstrates diffuse bilateral patchy infiltrates. **B** The lower cuts on a chest computed tomography scan in the infliximab-associated *L pneumophila* infection in case B demonstrate ground-glass opacities, airspace disease and bilateral pleural effusions, right greater than left. An abscess was also found in the posterobasal segment of the right upper lobe

### Case B

A 59-year-old man with a 40 pack-year history of smoking, chronic obstructive pulmonary disease, a diverting colostomy after sigmoidectomy for diverticulitis 15 years previously and Crohn's disease diagnosed in the context of small intestinal obstruction at the referring hospital five months before transfer is presented. The patient was readmitted to the referring hospital with an enterocutaneous fistula. He was treated with bowel rest, total parenteral nutrition and IV corticosteroids (methylprednisolone 20 mg IV four times a day). The treating physician prescribed a 5 mg/kg dose of infliximab one month before transfer. The patient developed bibasilar infiltrates on his chest x-ray, fever to 39.5°C and a productive cough. He was treated with piperacillin-tazobactam 3.375 g IV every 6 h and ciprofloxacin 400 mg IV twice a day – his fever and cough subsided. A second dose of infliximab was administered the week before transfer. The pulmonary symptoms reappeared and the pulmonary infiltrates progressed to abscess formation over the next few days. On the day of transfer, the patient experienced acute respiratory failure. The inferior lung images on a computed tomography scan of his abdomen confirmed the abscess formation (Figure 1B). On arrival, the patient was awake, responsive and tachypneic, with a respiratory rate of 36 breaths/min on bilevel positive airway pressure of 12/5 cmH<sub>2</sub>O and fraction of inhaled oxygen of 100%. His blood pressure was 105/60 mmHg. Bibasilar rales and decreased air entry was found on pulmonary auscultation. He was tachycardic, with a heart rate of 120 beats/min and bilateral lower extremity pitting edema. There was no indication of increased colostomy output nor was there any evident extraintestinal manifestations of Crohn's disease. His clinical condition quickly worsened, requiring urgent intubation, progressing to severe hypoxic respiratory failure and acute respiratory distress syndrome. Shortly after admission, he was referred to open lung biopsy surgery of the abscesses to identify the etiological agent. This was complicated by pneumothorax and bronchopleural fistula. He was switched to high-frequency oscillation ventilation to facilitate oxygenation and minimize barotrauma. His urine legionella antigen,

sampled on admission to the ICU, was positive for serogroup 1 *L pneumophila*. Bronchoalveolar lavage was initially sterile, but subsequent cultures of the lung biopsy grew cytomegalovirus, and subsequent endotracheal secretion cultures grew antibiotic-sensitive *Pseudomonas aeruginosa* and vancomycin-resistant *Enterococcus* species. His ICU stay was also complicated by candidemia, attributed to his total parenteral nutrition and central venous access catheter. In the context of a known outbreak of legionellosis at the referring hospital, the etiological agent for the initial presentation was believed to be *L pneumophila*. He was treated with a 21-day course of azithromycin 500 mg IV daily, as well as appropriate antibiotherapy for the serial ICU-acquired pathogens. The patient's condition deteriorated as a result of a condition unrelated to legionella. Care was withdrawn in the third week of his ICU admission, whereupon he passed away.

### DISCUSSION

*Legionella*, a water-borne, Gram-negative bacillus, was first recognized to be a human pathogen after an outbreak of pneumonia at a 1976 American Legion convention in Philadelphia, Pennsylvania (USA). It is the etiological agent accountable for 2% to 15% of community-acquired pneumonias requiring hospitalization. Cigarette smoking, chronic lung disease, immunosuppression (including corticosteroid use) and transplant surgery are implicated as risk factors (1). *Legionella* preferentially invades macrophages, and in cell culture rapidly multiplies 100- to 1000-fold within 48 h to 72 h. Its antigenic components, most notably, lipopolysaccharide, are a strong stimulus, producing TNF-alpha, which induces a cell-mediated immune response. TNF-alpha, along with interferon-gamma, interleukin-6 and interleukin-1 are believed to drive an important induction of the innate immune response and play a crucial role in combating infection (11). It stands to reason that inhibiting this response with TNF-alpha antagonists should predispose to legionellosis. In support of this hypothesis, infliximab and other TNF-alpha antagonists have been known since their inception to raise the risk of infection with other intracellular pathogens, such as *Mycobacterium tuberculosis*, *Coccidioides immitis*, *Listeria monocytogenes*, *Histoplasma capsulatum*, *Aspergillus* species and *Pneumocystis jiroveci* (3).

Epidemiological support for this argument comes from the largest case series in the literature – a French registry of patients receiving TNF-alpha antagonists (5). Data suggest a 16.5- to 21-fold higher incidence of *L pneumophila* infection in patients treated with TNF-alpha antagonists than in the general population. This risk increase seems to hold true when compared with disease-matched patients on other immunosuppressive medication, but without exposure to anti-TNF-alpha agents.

The MEDLINE search used the terms “legion\*”, “Crohn\*”, “inflammatory bowel disease and (infliximab OR adalimumab OR etanercept)”, and cross-referenced all articles retrieved for additional cases of legionellosis associated with infliximab or other TNF-alpha antagonists. There are three other documented associations of infliximab-treated Crohn's disease with *L pneumophila* infection. One death is documented in a clinical trial (4), in which the patient died of complications of his infection 11 days after the first dose of infliximab. The second case is described in the aforementioned French registry (5). The third patient was treated in an ICU with mechanical ventilation and appropriate antibiotics, and recovered completely (2).

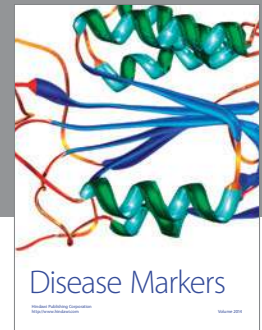
Clinical cases of legionellosis associated with TNF-alpha antagonists are compiled in Table 1. Attempts were made to acquire information by contacting appropriate authors, but were unsuccessful (ie, 'N/A' in Table 1). The patients described in the literature ranged in age from 26 to 73 years (median 49 years), and affected men and women in approximately a 1:1 ratio. The case-fatality rate was 14% (three of 22). Two patients had successful reintroduction of the anti-TNF-alpha agent without relapse; however, another patient experienced an additional episode of legionellosis. This suggests that reintroduction of infliximab or an alternate anti-TNF-alpha agent should be considered with caution – if at all – and with careful regard to possible environmental exposure to the infective agent.

TNF-alpha antagonists are growing in popularity as treatments for a range of immune-mediated illnesses, particularly rheumatological, dermatological and inflammatory gastrointestinal diseases. These agents have been known to predispose to infection with intracellular pathogens. The present review serves to highlight the fact that TNF-alpha antagonists also predispose to infection with *L pneumophila*, a readily diagnosable, common and highly treatable illness. Rapid recognition of legionellosis, and rapid empirical treatment with a fluoroquinolone or macrolide antibiotic significantly reduce mortality (1). Current urinary antigen tests detect only serogroup 1, and many of the cases described were discovered on bronchoalveolar or airway secretion culture. A high index of suspicion should prompt the treating clinician to search for legionella serogroups not detected in urine testing. Therefore, physicians using anti-TNF-alpha agents to treat their patients should be aware of this association and have a low threshold for the diagnosis and treatment of legionellosis in the appropriate clinical context.

## REFERENCES

1. Stout JE, Yu VL. Legionellosis. *N Engl J Med* 1997;337:682-7.
2. Beigel F, Jürgens M, Filik L, et al. Severe *Legionella pneumophila* pneumonia following infliximab therapy in a patient with Crohn's disease. *Inflamm Bowel Dis* 2009;15:1240-4.
3. Mancini G, Erario L, Gianfreda R, et al. Tuberculosis and *Legionella pneumophila* pneumonia in a patient receiving anti-tumour necrosis factor-alpha (anti-TNF-alpha) treatment. *Clin Microbiol Infect* 2007;13:1036-7.
4. Kohn A, Daperno M, Armuzzi A, et al. Infliximab in severe ulcerative colitis: Short-term results of different infusion regimens and long-term follow-up. *Aliment Pharmacol Ther* 2007;26:747-56.
5. Tubach F, Ravaud P, Salmon-Céron D, et al. Recherche Axée sur la Tolérance des Biothérapies Group. Emergence of *Legionella pneumophila* pneumonia in patients receiving tumor necrosis factor-alpha antagonists. *Clin Infect Dis* 2006;43:e95-100.
6. Li Gobbi F, Benucci M, Del Rosso A. Pneumonitis caused by *Legionella pneumoniae* in a patient with rheumatoid arthritis treated with anti-TNF-alpha therapy (infliximab). *J Clin Rheumatol* 2005;11:119-20.
7. Wondergem MJ, Voskuyl AE, van Agtmael MA. A case of legionellosis during treatment with a TNF-alpha antagonist. *Scand J Infect Dis* 2004;36:310-1.
8. Albert C, Vandenbos F, Brocq O, Carles D, Euller-Ziegler L. Legionellosis in patient treated with infliximab. *Rev Med Intern* 2004;25:167-8.
9. Eisendle K, Fritsch P. Fatal fulminant legionnaires' disease in a patient with severe erythodermic psoriasis treated with infliximab after long-term steroid therapy. *Br J Dermatol* 2005;152:585-6.
10. Dixon WG, Watson K, Lunt M, Hyrich KL, Silman AJ, Symmons DP; British Society for Rheumatology Biologics Register. Rates of serious infection, including site-specific and bacterial intracellular infection in rheumatoid arthritis patients receiving anti-tumor necrosis factor therapy: Results from the British Society for Rheumatology Biologics Register. *Arthritis Rheum* 2006;54:2368-76.
11. Friedman H, Yamamoto Y, Klein TW. *Legionella pneumophila* pathogenesis and immunity. *Semin Pediatr Infect Dis* 2002;13:273-9.





**Hindawi**  
Submit your manuscripts at  
<http://www.hindawi.com>

