

# UCLA

## UCLA Previously Published Works

### Title

Functional connectivity of hippocampal networks in temporal lobe epilepsy.

### Permalink

<https://escholarship.org/uc/item/9st6q5s1>

### Journal

Epilepsia, 55(1)

### ISSN

0013-9580

### Authors

Haneef, Zulfi  
Lenartowicz, Agatha  
Yeh, Hsiang J  
[et al.](#)

### Publication Date

2014

### DOI

10.1111/epi.12476

Peer reviewed

Published in final edited form as:

*Epilepsia*. 2014 January ; 55(1): 137–145. doi:10.1111/epi.12476.

## FUNCTIONAL CONNECTIVITY OF HIPPOCAMPAL NETWORKS IN TEMPORAL LOBE EPILEPSY

Zulfi Haneef, MD<sup>1,2</sup>, Agatha Lenartowicz, PhD<sup>3</sup>, Hsiang J. Yeh, BS<sup>4</sup>, Harvey S. Levin, PhD<sup>5</sup>,  
Jerome Engel Jr., MD, PhD<sup>4</sup>, and John M. Stern, MD<sup>4</sup>

<sup>1</sup>Department of Neurology, Baylor College of Medicine, Houston, Texas

<sup>2</sup>Department of Neurology, Michael E DeBakey VA Medical Center, Houston, Texas

<sup>3</sup>Department of Psychology, University of California, Los Angeles, California

<sup>4</sup>Department of Neurology, University of California, Los Angeles, California

<sup>5</sup>Department of Physical Medicine, Baylor College of Medicine, Houston, Texas

### Summary

**Objective**—Temporal Lobe Epilepsy (TLE) affects brain areas beyond the temporal lobes due to connections of the hippocampi and other temporal lobe structures. Using functional connectivity MRI, we determined the changes of hippocampal networks in TLE to assess for a more complete distribution of abnormality.

**Methods**—Regions of interest (ROIs) were defined in the right and left hippocampi in three groups of participants- left TLE (n=13), right TLE (n=11) and healthy controls (n=16). Brain regions functionally connected to these ROIs were identified by correlating resting-state low-frequency fMRI Blood Oxygenation Level Dependent (BOLD) signal fluctuations. The grouped results were compared using independent sample t-test.

**Results**—TLE was associated with increased hippocampal connectivity involving several key areas of the limbic network (temporal lobe, insula, thalamus), frontal lobes, angular gyrus, basal ganglia, brainstem and cerebellum along with reduced connectivity involving areas of the sensorimotor cortex (visual, somatosensory, auditory, primary motor) and the default mode network (precuneus). Left TLE had more marked connectivity changes than right TLE.

**Significance**—The observed connectivity changes in TLE indicate dysfunctional networks that underlie widespread brain involvement in TLE. There are identifiable differences in the connectivity of the hippocampi between left and right TLE.

---

Corresponding author: Zulfi Haneef, MD, Assistant Professor in Neurology, Peter Kellaway Section of Neurophysiology, Department of Neurology, Baylor College of Medicine, One Baylor Plaza, MS: NB302, Houston, TX 77030, Phone: 832-355-4044, Fax: 713-798-0984, haneef@bcm.edu.

### Disclosures and conflicts of interest

1. Dr Engel is funded by NIH Grants P01 NS02808, R01 NS33310, and U01 NS42372, has patents WO 2009/123734A1, and WO 2009/123735A1, receives royalties from MedLink, Wolters Kluwer, Blackwell, and Elsevier, and has received honoraria from Medtronic, Wolters Kluwer, and Best Doctors.
2. Dr. Stern has served as a paid consultant for UCB and Lundbeck. Dr. Stern is an editor of MedLink Neurology, and has received royalties from Wolters Kluwer and from McGraw-Hill
3. The remaining authors have no disclosures/conflicts of interest

We confirm that we have read the Journal's position on issues involved in ethical publication and affirm that this report is consistent with those guidelines

## Keywords

Temporal Lobe Epilepsy (TLE); Hippocampal networks; fMRI; Functional Connectivity; Epilepsy psychopathology; Epileptic Networks

---

## Introduction

Temporal Lobe Epilepsy (TLE) is the most common type of epilepsy in adults. Although it primarily affects the temporal lobes, TLE is thought to be a network disease with widespread extra-temporal effects.<sup>1–3</sup> Structural and functional changes have also been shown beyond the temporal lobes in TLE using MRI<sup>4, 5</sup>, EEG<sup>6, 7</sup>, neuropsychology testing<sup>1, 2</sup>, fMRI<sup>8–10</sup>, SPECT studies<sup>11, 12</sup> and Diffusion Tensor Imaging (DTI).<sup>13, 14</sup> One or both hippocampi are commonly involved in TLE, and this is often visible as hippocampal sclerosis (HS) in structural MRI. Hippocampal involvement can also occur in TLE without HS and also in neocortical TLE.<sup>15</sup> Based on these findings, the hippocampus is apparently a key component in the network abnormality of TLE and may produce widespread network changes due to the distributed nature of hippocampal connections involving entorhinal input, fornix output, and integration in the default mode network (DMN).

Hippocampal networks in TLE have been studied using intracranial EEG.<sup>6, 16, 17</sup> Although intracranial EEG has excellent temporal resolution, the brain coverage in these studies is necessarily limited to the immediate areas surrounding the intracranial electrode contacts. Evaluation of brain networks using functional connectivity of resting state fMRI is a relatively new technique that has been used successfully to identify brain networks in several conditions, including Alzheimer's disease, fronto-temporal dementia, depression, schizophrenia, and autism.<sup>18</sup> Compared to traditional fMRI, functional connectivity MRI (fcMRI) has advantages of not requiring a task during imaging and of having a stronger imaging signal.<sup>18, 19</sup> This technique has the advantage over intracranial EEG of sampling the whole brain. Its reported use to date in TLE illuminates the potential to depict the pathophysiology of network changes.<sup>9, 10, 20–23</sup>

In the present study, we used ROI-based fcMRI to further evaluate the changes in hippocampal networks in TLE during the inter-ictal state to better understand the impact of TLE on brain function. Results complement previous studies and further the understanding of the TLE networks. They also allow for an evaluation of the difference between left and right TLE.

## Methods

### Subjects

The study sample of 40 participants included 11 with right TLE, 13 with left TLE, and 16 controls (Table 1). Written informed consent was obtained prior to scanning from all participants in accordance with guidelines of the University of California, Los Angeles (UCLA) Institutional Review Board that approved the study and in compliance with the 1964 Declaration of Helsinki. Control participants were recruited locally at UCLA. Each control participant had a normal structural MRI and none had a history of neurologic illness or was taking a neurologic medication. Epilepsy participants were patients of the UCLA Seizure Disorder Center who had undergone comprehensive diagnostic testing and were found to be candidates for anteromesial temporal lobe resective epilepsy surgery. The diagnostic evaluation included video-EEG monitoring, high resolution MRI, FDG-PET scanning and neuropsychological testing (Table 1). All of these participants underwent

epilepsy surgery, and post-operative seizure freedom was assessed at the most recent follow-up visit.

Patients remained on their regular medications during the fMRI. None of the patients had a seizure in the 24 hours preceding the imaging. All participants were instructed to relax with eyes closed during imaging. No auditory stimulus was present except for the acoustic noise from imaging. None of the patients had seizures during the study as confirmed by the simultaneous EEG obtained during fMRI as part of a related study. The EEG results were not included in the data analysis other than to exclude seizures. Details of the simultaneous EEG methods are described in Stern et al.<sup>24</sup>

## Imaging

Imaging was performed with a 3T MRI system (Siemens Trio, Erlangen, Germany). Functional imaging was performed with the following parameters: TR=2000 ms, TE=30 ms, FOV=210 mm, matrix= 64 × 64, slice thickness 4 mm, 34 slices. High-resolution structural images were obtained during the same imaging study with the parameters: TR=20 ms, TE=3 ms, FOV = 256 mm, matrix = 256 × 256, slice thickness 1 mm, 160 slices. The images were acquired in the axial plane using a spoiled gradient recalled (SPGR) sequence for the anatomical images and an echo planar imaging (EPI) sequence for the functional images. The imaging sessions included multiple simultaneous EEG and fMRI recordings, each lasting 5 to 15 minutes and combining to include 28 to 60 minutes of fMRI in total.

## Pre-Processing

Pre-processing of the fMRI data was performed using FSL (fMRIB Software Library) version 5.0.2 (Oxford, UK, [www.fmrib.ox.ac.uk/fsl](http://www.fmrib.ox.ac.uk/fsl))<sup>25, 26</sup> which included head movement artifact removal<sup>27</sup>, non-brain tissue elimination<sup>28</sup> high-pass filtering (100 sec), spatial smoothing at 5 mm full-width half-maximum, and mean-based intensity normalization as described previously for resting state fMRI analyses.<sup>29, 30</sup> The following were included as temporal covariates and regressed out using linear regression: 6 motion parameters, white matter signal, cerebrospinal fluid signal, global mean signal, and their associated derivatives. This model also included voxel-wise regressors for additional 'motion scrubbing'<sup>31</sup> done by identifying and omitting TRs that showed instantaneous changes in BOLD intensity that exceeded threshold (75<sup>th</sup> percentile + 1.5 × inter-quartile range). The normalized residuals from this analysis were then used in the seed based analysis, using a minimum of two completed consecutive runs of 10 minutes each (total 20 minutes) for each participant. Scan durations ranged between 28–60 minutes per participant.

## Statistical methods

The residuals from the above analysis were filtered through a low pass filter (<0.1Hz) and then used in the ROI-based correlation analysis. ROIs were selected to include the whole left and right hippocampus and were defined manually using the MNI template.

Subsequently these ROIs were transformed from the standard MNI space to each subject's individual functional brain space. Partial correlations between voxels within the ROI and all other voxels in the brain were calculated separately for each run of each subject. To combine these values across runs, we applied a Fisher's Z transform (FZT) to the correlation maps calculated in the previous step. The residuals from the first nuisance analysis were conditioned for the FZT by removing the mean and dividing by the standard deviation, thus centering the distribution around zero and setting the standard deviation to 1. Ordinary least squares (OLS) simple mixed effect analysis was used to combine data over runs within each subject and subsequently, to combine estimates between subjects in a group model.

The group analysis was performed voxel-wise, using a one-way ANOVA with three levels corresponding to the three groups (left TLE, right TLE, and control subjects). Specific contrasts performed included: 1) TLE (combined left and right) greater than control, 2) control greater than TLE (combined left and right), 3) left TLE greater than controls, 4) control greater than left TLE, 5) right TLE greater than controls, 6) control greater than right TLE, 7) left TLE greater than right TLE, and 8) right TLE greater than left TLE. Gaussian field theory was used to threshold Z statistic images, using a cluster forming threshold of  $Z > 2.0$  and a corrected cluster significant threshold of  $p = 0.05$ .<sup>32</sup> A reverse transform of the earlier FZT was performed to help with interpretation of the resulting parametric maps.

SPSS Statistics, Release Version 17 (SPSS Inc., Chicago) was used to analyze between group differences in the demographic and epilepsy-related measures. The age and gender were compared between the three groups using Kruskal-Wallis and Chi-squared tests respectively. Among patients, the age at epilepsy onset, epilepsy duration and seizure frequency were compared using the Mann-Whitney U test.

## Results

The clinical characteristics of the participants are given in Table 1. There were 15 control subjects (5 females) with a mean  $\pm$  SD age of  $32.1 \pm 11.1$ . Comparison of demographic- and epilepsy-related characteristics between the subjects is shown in Table 2. The presumed underlying etiology of TLE based on pre-surgical MRI and tissue histopathology was heterogeneous (Table 1) with mesial temporal sclerosis being the most common etiology; MRI evidence suggested that seven out of twelve patients with left TLE and four out of eleven patients with right TLE had hippocampal sclerosis (Table 1). Tissue sample integrity did not always allow for histopathological confirmation of this diagnosis.

The results of the hippocampal connectivity comparisons between the different groups are shown in Figure 2 and detailed in Table 3. Compared to controls, TLE was associated with greater connectivity involving bilateral temporal lobes, insula, fornix, frontal poles, angular gyrus, basal ganglia, thalamus, and cerebellum. In addition there was reduced connectivity with the occipital pole, calcarine, lingual, precuneus, sensorimotor cortex and parts of insula and frontal lobes as well as medial frontal areas in TLE. Similar patterns were seen in left and right TLE, but were overall more prominent in left TLE than in right TLE. Particular differences between left and right TLE included absence of reduced connectivity in the sensorimotor cortex in right TLE. Direct comparison of left TLE connectivity greater than right TLE showed signal in the left sensorimotor areas. Comparison of right TLE greater than left TLE did not show significant differences (supplementary figure 1). The connectivity of the ipsilesional hippocampus was reduced to the ventro-medial pre-frontal cortex; otherwise, the connectivity of either hippocampus was equally involved regardless of the side of ictal onset (Figure 2).

The groups were also divided into patients with and without mesial temporal sclerosis (visible in MRI/pathology). Comparison of these groups to controls (supplementary figure 2A–2D) showed findings similar to those seen with TLE (Figure 2). Visual comparison of these groups to each other showed more robust and bilaterally symmetric signal increases as well as medial frontal signal decreases with MTS (supplementary figure 2A–2D). However direct statistical comparison did not show any significant differences (supplementary figure 2E, 2F).

## Discussion

We analyzed the functional connectivity of the left and right hippocampal ROIs in TLE using fMRI. With a network perspective, the areas of increased connectivity involved several key areas of the limbic system (insula/planum polare, fornix, and thalamus) and frontal lobes and reduced connectivity with areas of the sensorimotor systems (visual, somatosensory, auditory, primary motor). Our findings of widespread changes in hippocampal functional connectivity throughout the cerebral hemispheres and brainstem is consistent with other studies in TLE using structural MRI, SPECT, PET, and intracranial EEG.<sup>4-6, 8-11, 23, 33</sup> Prior depth electrode studies have also examined limbic connectivity using evoked potentials showing prominent connections between parts of the hippocampus and the entorhinal cortex, amygdala, insula, and lateral temporal cortex, parahippocampal gyrus, posterior cingulate gyrus, medial superior frontal gyrus and orbitofrontal cortex, although comparison to healthy controls is obviously not possible.<sup>34, 35</sup>

Two previous reports have described hippocampal connectivity using fMRI ROI analysis in right and left TLE.<sup>20, 21</sup> Our results are similar to these studies in showing reduced connectivity of the hippocampus with areas of posterior DMN (precuneus). Similar to our findings, reduced connectivity of the calcarine cortex in right TLE was seen in one of these studies<sup>21</sup> and reduced connectivity with the anterior DMN in the other.<sup>20</sup> Unlike these previous studies which showed reduced connectivity with the limbic areas, we observed both decreased connectivity to parts of the insula as well as increased connectivity involving the limbic structures including temporal lobes, insula, fornix and thalamus. In addition, we observed increased connectivity with other brain regions including frontal lobes, basal ganglia, brainstem and cerebellum unlike the previous studies which did not find areas of increased hippocampal connectivity. Also discordant to the previous studies, we found areas of reduced connectivity in the somatosensory, auditory and primary motor cortex. We found similar connectivity changes in both hippocampi unlike the prior studies quoted which showed greater connectivity reduction in the abnormal hippocampus. These differences in connectivity findings may be related to several factors, including seed characteristics and image analysis techniques and their thresholds; however, the higher threshold is not the basis for the difference. Although the anatomical extent of our results decreases when we use the higher threshold, the distribution of the results remains the same. Functional connectivity studies using other techniques have also been done in TLE, although not in lateralized TLE and are described below in the context of our findings.

### Connectivity changes in different networks

The neurophysiologic basis of functional connectivity in fMRI is unclear. Increased EEG functional connectivity can correspond to decreased fMRI functional connectivity.<sup>7</sup> Reduced functional connectivity between areas of the brain can be associated with increased connectivity elsewhere to compensate for the resulting functional disconnection.<sup>9, 33, 36</sup> Overall, patterns of altered connectivity imply abnormal brain networks and allow contemplation of potential clinical associations as discussed below that could guide future research.

**Temporal lobe/Limbic**—Our findings of mostly increased hippocampal-limbic connectivity correspond to previous reports of increased functional connectivity in the insula and thalamus.<sup>37-39</sup> Other reports have also suggested reduced temporal lobe functional and structural connectivity in TLE.<sup>14, 20-22</sup> Limbic networks are also involved in psychiatric disorders and several areas of altered connectivity that we observed including the insula, lateral frontal poles and bilateral lingual gyri have also been noted to be altered in depression.<sup>40</sup>

**Frontal lobe**—Frontal lobe dysfunction in TLE has been shown by behavioral tests, PET and SPECT imaging.<sup>1, 11, 41</sup> Increased bidirectional functional connectivity between the contra-lesional inferior frontal gyrus and the medial temporal lobe has been shown in TLE with magnetoencephalogram (MEG) dynamic causal models of working memory.<sup>42</sup> We found increased bi-frontal and right lateral frontal connectivity in TLE in agreement with prior reports of increased right frontal connectivity in TLE.<sup>10</sup> We did not find frontal connectivity changes in right TLE consistent with the more prominent frontal lobe dysfunction thought to exist in left TLE.<sup>2, 43</sup> Reduced frontal connectivity maybe related to memory loss, inter-ictal psychosis and language impairment in TLE.<sup>44–46</sup>

**Basal Ganglia and Brainstem**—We saw areas of increased connectivity in the basal ganglia, upper brainstem, and cerebellum. Increased connectivity of the putamen and brainstem in TLE has been noted previously, although the intrinsic cerebellar connectivity was found to be reduced.<sup>36, 37, 47, 48</sup> Increased connectivity of the thalami, brainstem and cerebellum in generalized seizures has also been reported.<sup>38</sup>

**Default mode network (DMN)**—DMN involvement in TLE has also been reported by us and other groups.<sup>8, 9, 20, 33, 36, 49</sup> Our current findings of reduced connectivity between the hippocampi and the precuneus could be related to defects in the structural white matter connections between these integral parts of the DMN.<sup>50, 51</sup> DMN involvement could be related to involvement of subconscious mental processing and the altered consciousness with complex partial seizures.<sup>51</sup>

**Sensory networks**—Strikingly, the areas of reduced connectivity we found in TLE correspond to areas of the sensorimotor cortex including somatosensory, auditory and visual cortex. Reduced connectivity in visual, auditory and sensory networks have been reported in TLE and in generalized epilepsy.<sup>36, 49, 52, 53</sup> Behavioral and neurophysiological studies show deficits in somatosensory and auditory perceptions in TLE although visual perception has been reported to be unaffected.<sup>54–58</sup>

**Motor network**—We also found reductions in pre-central connectivity. The significance of this finding is unclear. Motor abnormalities are not well-documented in TLE although studies in rats show reorganization of the motor cortex with hippocampal seizures.<sup>59</sup>

### Significance of lateralized changes

We find greater connectivity changes in left TLE compared to right TLE. Differences in functional connectivity between left and right TLE have been noted before by us and others.<sup>7, 9, 20, 21, 60</sup> In addition to the pathophysiologic significance of more extensive abnormality in left TLE, this asymmetry also holds the potential for differentiating left from right TLE.

Previous reports have differentiated left and right TLE based on other fMRI connectivity changes. Basal connectivity of the temporal lobes in mesial TLE was found to be decreased in the ipsilesional and increased in the contra-lesional side.<sup>22</sup> A study using simultaneous fcMRI and DTI found areas of reduced connectivity in right TLE that were similar to areas of reduced connectivity we observed including the temporal lobe, posterior DMN, frontal cortex and sensorimotor cortex. Concordant to our findings of greater connectivity increase in left TLE, they found more preserved connectivity in left TLE compared to right TLE.<sup>13</sup>

### Limitations

The two epilepsy groups were homogeneous in their clinical evaluations, but the individual participants differed in the underlying etiologies (Table 1). It is plausible that distinct TLE



subtypes may have different effects on brain networks. However, our data suggest that the uneven distribution of hippocampal sclerosis in the left versus right TLE groups does not account for the lateralized differences as tested by a comparison of patients with MTS versus those without MTS (supplementary Figure 2). Since the functional abnormality, as clinically manifested, was homogeneous within each epilepsy group, a grouping as right and left TLE is reasonable. Another potential confound is the variation in the anti-epileptic drugs (AEDs) used in our epilepsy groups. It is likely that AEDs affect functional connectivity due to their effect on the brain. The large number of available AEDs and the complexity of therapeutic regimens necessary in patients with pharmacoresistant epilepsy make it difficult to disentangle the effects of epilepsy versus AEDs and remain the most significant limitation of this, and other similar studies. Handedness is another possible confound that may influence our results.<sup>19</sup> However, the four left-handed participants had left hemispheric dominance for language, as identified with the intracarotid amobarbital test, which minimizes the likelihood of a handedness effect. Another limitation is the potential for drowsiness or sleep affecting the subject groups disproportionately and affecting connectivity given the duration of the scans.

### Conclusions and future directions

Using functional connectivity MRI, we identify hippocampal network changes in TLE that indicate a broad extent of dysfunction and widespread brain involvement in TLE. The connectivity changes in the right and left hippocampus are similar in both left and right TLE, and the greater changes in hippocampal connectivity seen in left TLE compared to right TLE could be related to the larger network involvement encountered in this TLE subtype.

Connectivity abnormalities have potential for clinical relevance and correlation. They may help characterize TLE, which ultimately may assist with diagnosis, they may provide insights into neurological deficits associated with TLE, such as memory, mood, and executive function, and they may benefit invasive treatments through a more accurate understanding of TLE's functional anatomy.

### Supplementary Material

Refer to Web version on PubMed Central for supplementary material.

### Acknowledgments

Funding for this research was provided by (1) The Epilepsy Foundation of America (ZH); (2) NIH-NINDS K23 Grant NS044936 (JMS); and (3) The Leff Family Foundation (JMS).

Data acquisition was assisted by Elizabeth Pierce (UCLA).

### References

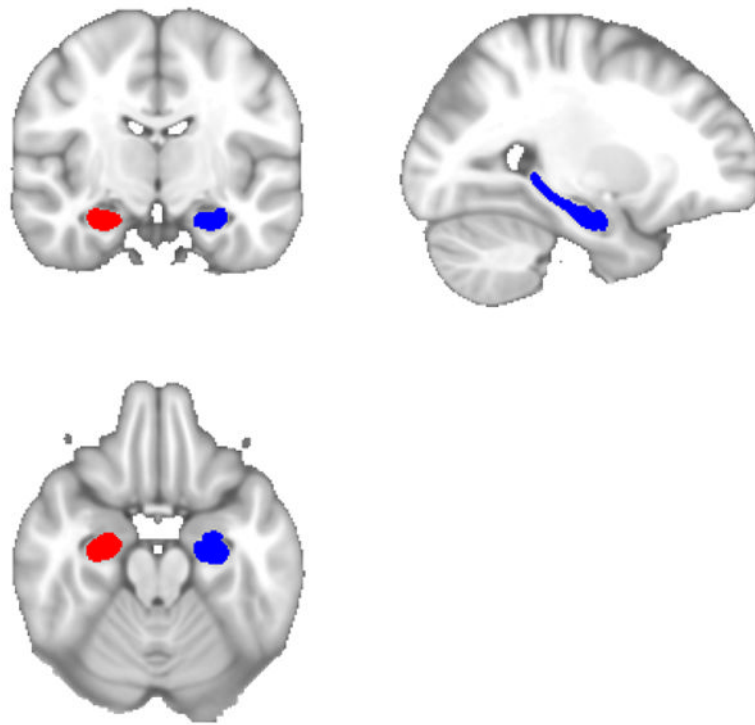
1. Hermann BP, Seidenberg M, Haltiner A, et al. Mood state in unilateral temporal lobe epilepsy. *Biol Psychiatry*. 1991; 30:1205–18. [PubMed: 1790262]
2. Giovagnoli AR. Relation of sorting impairment to hippocampal damage in temporal lobe epilepsy. *Neuropsychologia*. 2001; 39:140–50. [PubMed: 11163372]
3. Spencer SS. Neural networks in human epilepsy: evidence of and implications for treatment. *Epilepsia*. 2002; 43:219–27. [PubMed: 11906505]
4. Lin JJ, Salamon N, Lee AD, et al. Reduced neocortical thickness and complexity mapped in mesial temporal lobe epilepsy with hippocampal sclerosis. *Cereb Cortex*. 2007; 17:2007–18. [PubMed: 17088374]



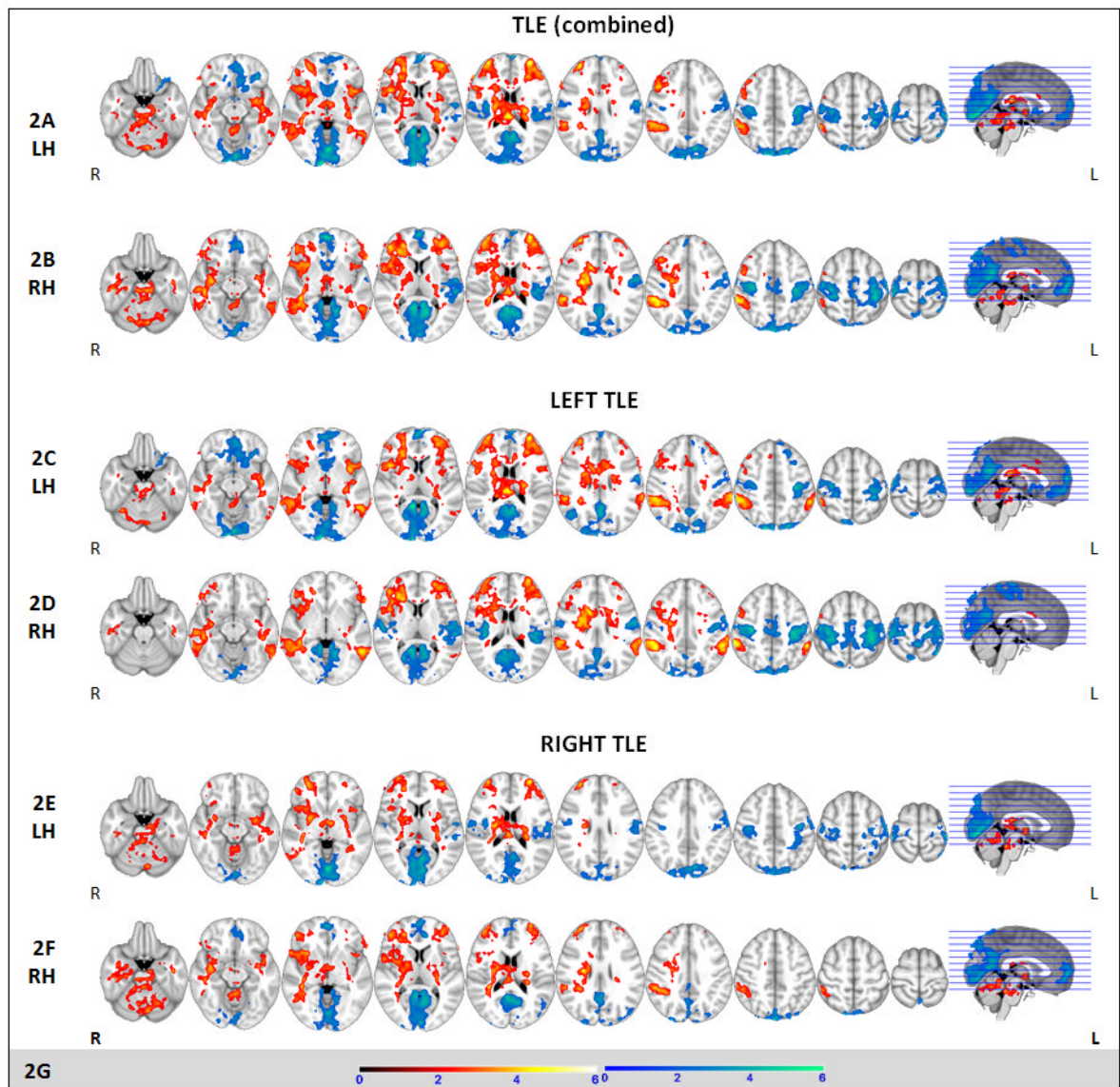
5. Bonilha L, Rorden C, Halford JJ, et al. Asymmetrical extra-hippocampal grey matter loss related to hippocampal atrophy in patients with medial temporal lobe epilepsy. *J Neurol Neurosurg Psychiatry*. 2007; 78:286–94. [PubMed: 17012334]
6. Bartolomei F, Wendling F, Regis J, et al. Pre-ictal synchronicity in limbic networks of mesial temporal lobe epilepsy. *Epilepsy Res*. 2004; 61:89–104. [PubMed: 15451011]
7. Bettus G, Ranjeva JP, Wendling F, et al. Interictal Functional Connectivity of Human Epileptic Networks Assessed by Intracerebral EEG and BOLD Signal Fluctuations. *PloS one*. 2011; 6:e20071. [PubMed: 21625517]
8. Laufs H, Hamandi K, Salek Haddadi A, et al. Temporal lobe interictal epileptic discharges affect cerebral activity in “default mode” brain regions. *Hum Brain Mapp*. 2007; 28:1023–32. [PubMed: 17133385]
9. Haneef Z, Lenartowicz A, Yeh HJ, et al. Effect of lateralized temporal lobe epilepsy on the default mode network. *Epilepsy Behav*. 2012; 25:350–7. [PubMed: 23103309]
10. Liao W, Zhang Z, Pan Z, et al. Altered functional connectivity and small-world in mesial temporal lobe epilepsy. *PloS one*. 2010; 5:e8525. [PubMed: 20072616]
11. Blumenfeld H, McNally KA, Vanderhill SD, et al. Positive and negative network correlations in temporal lobe epilepsy. *Cereb Cortex*. 2004; 14:892–902. [PubMed: 15084494]
12. Nelissen N, Van Paesschen W, Baete K, et al. Correlations of interictal FDG-PET metabolism and ictal SPECT perfusion changes in human temporal lobe epilepsy with hippocampal sclerosis. *Neuroimage*. 2006; 32:684–95. [PubMed: 16762567]
13. Voets NL, Beckmann CF, Cole DM, et al. Structural substrates for resting network disruption in temporal lobe epilepsy. *Brain*. 2012; 135:2350–7. [PubMed: 22669081]
14. Focke NK, Yogarajah M, Bonelli SB, et al. Voxel-based diffusion tensor imaging in patients with mesial temporal lobe epilepsy and hippocampal sclerosis. *Neuroimage*. 2008; 40:728–37. [PubMed: 18261930]
15. Surges R, Schulze-Bonhage A, Altenmueller DM. Hippocampal involvement in secondarily generalised seizures of extrahippocampal origin. *J Neurol Neurosurg Psychiatry*. 2008; 79:924–9. [PubMed: 18096679]
16. Schevon CA, Cappell J, Emerson R, et al. Cortical abnormalities in epilepsy revealed by local EEG synchrony. *Neuroimage*. 2007; 35:140–8. [PubMed: 17224281]
17. Bettus G, Wendling F, Guye M, et al. Enhanced EEG functional connectivity in mesial temporal lobe epilepsy. *Epilepsy Res*. 2008; 81:58–68. [PubMed: 18547787]
18. Fox MD, Greicius M. Clinical applications of resting state functional connectivity. *Front Syst Neurosci*. 2010; 4:1–13. [PubMed: 20204156]
19. Biswal BB, Mennes M, Zuo XN, et al. Toward discovery science of human brain function. *Proc Natl Acad Sci U S A*. 2010; 107:4734–9. [PubMed: 20176931]
20. Pittau F, Grova C, Moeller F, et al. Patterns of altered functional connectivity in mesial temporal lobe epilepsy. *Epilepsia*. 2012; 53:1013–23. [PubMed: 22578020]
21. Pereira FR, Alessio A, Sercheli MS, et al. Asymmetrical hippocampal connectivity in mesial temporal lobe epilepsy: evidence from resting state fMRI. *BMC neuroscience*. 2010; 11:1–13.
22. Bettus G, Bartolomei F, Confort-Gouny S, et al. Role of resting state functional connectivity MRI in presurgical investigation of mesial temporal lobe epilepsy. *J Neurol Neurosurg Psychiatry*. 2010; 81:1147–54. [PubMed: 20547611]
23. Frings L, Schulze-Bonhage A, Spreer J, et al. Remote effects of hippocampal damage on default network connectivity in the human brain. *J Neurol*. 2009; 256:2021–9. [PubMed: 19603243]
24. Stern JM, Caporro M, Haneef Z, et al. Functional imaging of sleep vertex sharp transients. *Clin Neurophysiol*. 2011; 122:1382–6. [PubMed: 21310653]
25. Woolrich MW, Ripley BD, Brady M, et al. Temporal autocorrelation in univariate linear modeling of FMRI data. *Neuroimage*. 2001; 14:1370–86. [PubMed: 11707093]
26. Forman SD, Cohen JD, Fitzgerald M, et al. Improved assessment of significant activation in functional magnetic resonance imaging (fMRI): use of a cluster size threshold. *Magn Reson Med*. 1995; 33:636–47. [PubMed: 7596267]

27. Jenkinson M, Bannister P, Brady M, et al. Improved optimization for the robust and accurate linear registration and motion correction of brain images. *Neuroimage*. 2002; 17:825–41. [PubMed: 12377157]
28. Smith SM. Fast robust automated brain extraction. *Hum Brain Mapp*. 2002; 17:143–55. [PubMed: 12391568]
29. Fox MD, Snyder AZ, Vincent JL, et al. The human brain is intrinsically organized into dynamic, anticorrelated functional networks. *Proc Natl Acad Sci U S A*. 2005; 102:9673–8. [PubMed: 15976020]
30. Uddin LQ, Clare Kelly A, Biswal BB, et al. Functional connectivity of default mode network components: correlation, anticorrelation, and causality. *Hum Brain Mapp*. 2009; 30:625–37. [PubMed: 18219617]
31. Power JD, Barnes KA, Snyder AZ, et al. Spurious but systematic correlations in functional connectivity MRI networks arise from subject motion. *Neuroimage*. 2012; 59:2142–54. [PubMed: 22019881]
32. Worsley KJ, Evans A, Marrett S, et al. A three-dimensional statistical analysis for CBF activation studies in human brain. *J Cereb Blood Flow Metab*. 1992; 12:900–18. [PubMed: 1400644]
33. Zhang Z, Lu G, Zhong Y, et al. Altered spontaneous neuronal activity of the default-mode network in mesial temporal lobe epilepsy. *Brain Res*. 2010; 1323:152–60. [PubMed: 20132802]
34. Kubota Y, Enatsu R, Gonzalez-Martinez J, et al. In vivo human hippocampal cingulate connectivity: A corticocortical evoked potentials (CCEPs) study. *Clin Neurophysiol*. 2013
35. Rutecki PA, Grossman RG, Armstrong D, et al. Electrophysiological connections between the hippocampus and entorhinal cortex in patients with complex partial seizures. *J Neurosurg*. 1989; 70:667–75. [PubMed: 2709106]
36. Mankinen K, Jalovaara P, Paakki JJ, et al. Connectivity disruptions in resting-state functional brain networks in children with temporal lobe epilepsy. *Epilepsy Res*. 2012; 100:168–78. [PubMed: 22418271]
37. Zeng, H.; Pizarro, R.; Nair, VA., et al. *Epilepsia*. 2013. 2013 Jan 09. Alterations in regional homogeneity of resting-state brain activity in mesial temporal lobe epilepsy.
38. Zhong Y, Lu G, Zhang Z, et al. Altered regional synchronization in epileptic patients with generalized tonic-clonic seizures. *Epilepsy Res*. 2011; 97:83–91. [PubMed: 21856123]
39. Morgan VL, Sonmez Turk HH, Gore JC, et al. Lateralization of temporal lobe epilepsy using resting functional magnetic resonance imaging connectivity of hippocampal networks. *Epilepsia*. 2012; 53:1628–35. [PubMed: 22779926]
40. Veer, IM.; Beckmann, CF.; van Tol, MJ., et al. *Front Syst Neurosci*. 2010. 2010 Oct 14. Whole brain resting-state analysis reveals decreased functional connectivity in major depression.
41. Jokeit H, Seitz RJ, Markowitsch HJ, et al. Prefrontal asymmetric interictal glucose hypometabolism and cognitive impairment in patients with temporal lobe epilepsy. *Brain*. 1997; 120 (Pt 12):2283–94. [PubMed: 9448582]
42. Campo P, Garrido MI, Moran RJ, et al. Network reconfiguration and working memory impairment in mesial temporal lobe epilepsy. *Neuroimage*. 2013; 72C:48–54. [PubMed: 23370058]
43. Strauss E, Hunter M, Wada J. Wisconsin Card Sorting Performance: effects of age of onset of damage and laterality of dysfunction. *J Clin Exp Neuropsychol*. 1993; 15:896–902. [PubMed: 8120126]
44. Vlooswijk M, Jansen J, Majoie H, et al. Functional connectivity and language impairment in cryptogenic localization-related epilepsy. *Neurology*. 2010; 75:395–402. [PubMed: 20679633]
45. Diehl B, Busch RM, Duncan JS, et al. Abnormalities in diffusion tensor imaging of the uncinate fasciculus relate to reduced memory in temporal lobe epilepsy. *Epilepsia*. 2008; 49:1409–18. [PubMed: 18397294]
46. Flugel D, Cercignani M, Symms MR, et al. Diffusion tensor imaging findings and their correlation with neuropsychological deficits in patients with temporal lobe epilepsy and interictal psychosis. *Epilepsia*. 2006; 47:941–4. [PubMed: 16686662]
47. Mankinen K, Long XY, Paakki JJ, et al. Alterations in regional homogeneity of baseline brain activity in pediatric temporal lobe epilepsy. *Brain Res*. 2011; 1373:221–9. [PubMed: 21146507]

48. Rektor I, Tomcik J, Miki M, et al. Association between the Basal Ganglia and large-scale brain networks in epilepsy. *Brain Topogr.* 2013; 26:355–62. [PubMed: 23400553]
49. Luo C, Qiu C, Guo Z, et al. Disrupted functional brain connectivity in partial epilepsy: a resting-state fMRI study. *PLoS One.* 2011; 7:e28196. [PubMed: 22242146]
50. Liao W, Zhang Z, Pan Z, et al. Default mode network abnormalities in mesial temporal lobe epilepsy: a study combining fMRI and DTI. *Hum Brain Mapp.* 2011; 32:883–95. [PubMed: 20533558]
51. Buckner RL, Andrews-Hanna JR, Schacter DL. The brain's default network. *Ann N Y Acad Sci.* 2008; 1124:1–38. [PubMed: 18400922]
52. Zhang Z, Lu G, Zhong Y, et al. Impaired perceptual networks in temporal lobe epilepsy revealed by resting fMRI. *J Neurol.* 2009; 256:1705–13. [PubMed: 19488674]
53. Wang Z, Lu G, Zhang Z, et al. Altered resting state networks in epileptic patients with generalized tonic-clonic seizures. *Brain Res.* 2011; 1374:134–41. [PubMed: 21167825]
54. Grant AC, Donnelly KM, Chubb C, et al. Temporal lobe epilepsy does not impair visual perception. *Epilepsia.* 2008; 49:710–3. [PubMed: 18177359]
55. Beckung E, Uvebrant P. Motor and sensory impairments in children with intractable epilepsy. *Epilepsia.* 1993; 34:924–9. [PubMed: 8404748]
56. Grant AC. Interictal perceptual function in epilepsy. *Epilepsy Behav.* 2005; 6:511–9. [PubMed: 15907746]
57. Ehrle N, Samson S, Baulac M. Processing of rapid auditory information in epileptic patients with left temporal lobe damage. *Neuropsychologia.* 2001; 39:525–31. [PubMed: 11254935]
58. Han MW, Ahn JH, Kang JK, et al. Central auditory processing impairment in patients with temporal lobe epilepsy. *Epilepsy Behav.* 2011; 20:370–4. [PubMed: 21273138]
59. van Rooyen F, Young NA, Larson SE, et al. Hippocampal kindling leads to motor map expansion. *Epilepsia.* 2006; 47:1383–91. [PubMed: 16922885]
60. Morgan VL, Rogers BP, Sonmezturk HH, et al. Cross hippocampal influence in mesial temporal lobe epilepsy measured with high temporal resolution functional magnetic resonance imaging. *Epilepsia.* 2011; 52:1741–9. [PubMed: 21801166]



**Fig 1.** Regions of Interest (ROI/seed) defined in the right and left hippocampi. Each seed involved the full hippocampus.



**Fig 2.** Areas of increased (red) and decreased (blue) connectivity compared to controls with left and right hippocampal seeds respectively in all cases of TLE (2A, 2B), left TLE (2C, 2D) and right TLE (2E, 2F). Color scales for increased (hot colors) and decreased (cold colors) connectivity (2G). Images are in radiological orientation. ( $z > 2.0$ ,  $p < 0.05$ ). *LH- Left Hippocampal seed, RH- Right Hippocampal seed*

**Table 1**

Clinical characteristics of participants

Age	Sex	Handedness	Sz onset age (yr)	Sz duration (yrs)	Sz freq (per mo)	AEDs	MRI	Pathology	Sz free post-surgery	Time since surgery (months)	Neuropsychology memory dysfunction
<b>Right TLE</b>											
34	M	R	15	19	3	LTG	R MTS	Gliosis	Yes	27	NV
34	F	R	14	20	60	LEV, LTG	R temporal hyperintensity	Gliosis	No	20	NV
43	M	R	41	2	1	LEV, LTG	Normal	No surgery	SF	No surgery	Not done
40	M	R	20	20	3	VPA, LCM	R Amygdala hypertrophy	Insuff. sample	Yes	3	NV
39	M	R	8	31	2	LTG, LEV	R MTS	Gliosis	Yes	1.5	Normal
52	M	R	47	5	2	LEV	R Temporal CD	Mild CD	No	17	NV > V
53	F	R	45	8	3	OXC	Normal	Mild cortical disorganization	Yes	18	NV
45	F	R	36	9	2	VPA, LCM	Hippocampal malformation	Gliosis	Yes	7	Not done
20	M	R	1	19	2	OXC, LCM	Bilateral hippocampal atrophy	Gliosis	Yes	3	NV
47	M	R	10	37	2	VPA, LEV	R MTS	HS	Yes	12	NV
37	M	R	4	33	3	TPM, LTG, LEV, CBZ	R MTS	HS, CD	Yes	2	NV
<b>Left TLE</b>											
40	F	R	38	2	3	OXC	L Amygdala CD/glioma	-	Yes	23	Inconclusive
40	M	R	20	20	1	LTG, OXC	Normal	Normal	TBD	18	Normal
40	M	R	4	36	3	LEV, LTG	L MTS	MTS + CD	Yes	18	V > NV
35	F	R	6	29	2	CBZ, LEV, LTG	L MTS	Gliosis	Yes	4	B (L>R) TL dysfunction
36	F	R	3	33	10	PHT, PB, LEV	L MTS	No surgery	No surgery	No surgery	Normal
23	F	R	17	6	7	PHT	L MTS	CD	Yes	23	V
20	F	R	12	8	7	VPA, PGB	Normal	CD	Yes	17	Normal
27	F	L	9	18	1	PHT, LTG, LEV	L MTS	CD	Yes	15	V
46	F	L	1	45	5	LTG, LCM	L MTS	CD	Yes	8	NV + V
45	M	L	40	5	2	LEV	L MTS	Normal	Yes	5	NV + V
30	M	R	14	16	5	LEV, CBZ, LCM	L anterior temporal signal abnormality	CD	Yes	2	V
52	M	R	46	6	60	PHT, LMG	L MTS + anterior temporal CD	HS	Yes	12	V
21	F	L	15	6	2	OXC, LCM	L ant temporal encephalocele	Gliosis	Yes	3	Normal

Age	Sex	Handedness	Sz onset age (yr)	Sz duration (yrs)	Sz freq (per mo)	AEDs	MRI	Pathology	Sz free post-surgery	Time since surgery (months)	Neuropsychology/ memory dysfunction
36	F	R	32	4	1	LEV, LTG, TPM	L hippocampal CD	Insuff. Sample	Yes	1	VM

CBZ-Carbamazepine, CD-Cortical Dysplasia, L=left, LEV-L-evetiracetam, LTG-Lamotrigine, MTS-Mesial Temporal Sclerosis, NV-non-verbal, OXC-Oxcarbazepine, PB-Phenobarbital, PGB-Pregabalin, PHT-Phenytoin, R=right, SF-Seizure free (without surgery), Sz-seizure, TBD-to be determined-(these are patients with surgery who have not returned for follow up visits), VPA-Valproate, V-verbal.



**Table 2**

Comparison of demographic and epilepsy-related characteristics between the subjects

	Right TLE (n=12)	Left TLE (n=14)	Healthy Controls (n=16)	Significant differences (p value)
Gender (male/female)	8/4	5/9	11/5	0.14 (NS)
Handedness (right/left)	12/0	10/4	16/0	0.01*
Age (mean $\pm$ SD yrs)	39.9 $\pm$ 9.1	35.1 $\pm$ 9.8	32.1 $\pm$ 11.1	0.06
Age at epilepsy onset (mean $\pm$ SD yrs)	21.1 $\pm$ 16.6	18.4 $\pm$ 14.8	NA	0.68 (NS)
Epilepsy duration (mean $\pm$ SD yrs)	18.8 $\pm$ 11.2	16.7 $\pm$ 14.0	NA	0.44 (NS)
Seizure frequency range (inter-quartile)	2–3	2–7	NA	0.77 (NS)

NA-Not Applicable; NS-Not Significant;

\* Significant

**Table 3**

Areas of increased and decreased (red and blue respectively in corresponding Fig 2) connectivity compared to controls with left hippocampal (LH) and right hippocampal (RH) seeds in TLE. Changes are bilateral unless specified as R or L (R-right, L-left). Areas not underlined are congruent between left and right seeds. Labels 2A–2F represent corresponding image series in Fig 2. Numbers in parentheses represent the cluster numbers associated. Voxel size, peak z scores (z max) and x, y, z coordinates for peak z score of significant clusters are also shown.

Anatomic area	Increased Connectivity (red)						Decreased Connectivity (blue)						
	Cluster #	Voxels	Z max	x (mm)	y (mm)	z (mm)	Anatomic area	Cluster #	Voxels	Z max	x (mm)	y (mm)	z (mm)
<b>TLE (combined)</b>													
2A LH	4	100624	5.24	24	45	4	Occipital pole (4), calcarine (4), lingual, precuneus (4), sensorimotor (1, 2), medial frontal cortex, paracingulate, frontal pole, superior frontal (3)	4	70738	5.48	6	-72	64
	3	26610	3.79	-20	-64	-24		3	19263	4.43	-37	37	-12
	2	10849	4.24	-30	52	6		2	17245	4.63	-35	-37	55
	1	10739	4.23	60	-37	46		1	14820	3.95	30	-21	54
2B RH	1	133459	4.85	38	-9	-16	Occipital pole (1), calcarine (1), lingual (1), precuneus (1), sensorimotor (1), left planum temporale (1), Heschl's (1)	1	148275	5.42	-35	-35	55
<b>Left TLE</b>													
2C LH	4	71196	4.26	24	46	3	Occipital pole (3), lateral occipital (3), calcarine (3), lingual (3), precuneus (3), orbito-frontal (2), medial frontal (2), sensorimotor (1)	3	68174	5.15	6	-72	64
	3	20365	3.95	29	-69	-30		2	29056	4.33	-28	29	-13
	2	10831	4.15	-35	57	14		1	16741	4.37	-34	-37	54
	1	10231	4.45	60	-37	46		1	154288	5.05	-35	-35	55
2D RH	3	54714	4.6	26	43	6	Occipital pole (1), calcarine (1), lingual (1), precuneus (1), planum temporale/Heschl's (1), sensorimotor (1)	1	154288	5.05	-35	-35	55
	2	15647	4.14	29	-65	-29							
	1	9143	4.78	-33	29	28							

		Increased Connectivity (red)					Decreased Connectivity (blue)						
Anatomic area	Cluster #	Voxels	Z max	x (mm)	y (mm)	z (mm)	Anatomic area	Cluster #	Voxels	Z max	x (mm)	y (mm)	z (mm)
<u>Right TLE</u>													
LH	2	74537	5.02	24	45	4		1	38827	4.57	6	-72	64
Temporal white matter (2), insula/planum polare (2), fornix (2), R frontal pole (2), R putamen (2), caudate (2), thalamus (2), cerebellum (1), brainstem (1)							Occipital pole (1), calcarine (1), lingual (1), precuneus (1)						
2F RH	1	14126	4.15	-16	-53	-20		2	39412	4.81	3	-87	46
Temporal white matter (1), R insula/planum polare (1), fornix (1), R frontal pole (1), R lateral frontal, R putamen (1), caudate (1), thalamus (1), cerebellum (1), brainstem							Occipital pole (2), calcarine (2), lingual (2), precuneus (2), L planum temporale (1), L sensorimotor (1)	1	16922	4.39	-48	-19	26