

Functional potential in chronic stroke patients depends on corticospinal tract integrity

Cathy M. Stinear,¹ P. Alan Barber,² Peter R. Smale,^{1,3} James P. Coxon,¹ Melanie K. Fleming¹ and Winston D. Byblow¹

¹Human Motor Control Laboratory, University of Auckland, ²Neurology Department and ³Radiology Department, Auckland City Hospital, Auckland, New Zealand

Corresponding author: Winston Byblow, Human Motor Control Laboratory, Department of Sport and Exercise Science, University of Auckland, Private Bag 92019, Auckland, New Zealand

E-mail: w.byblow@auckland.ac.nz

Determining whether a person with stroke has reached their full potential for recovery is difficult. While techniques such as transcranial magnetic stimulation (TMS) and MRI have some prognostic value, their role in rehabilitation is undefined. This study used TMS and MRI to determine which factors predict functional potential, defined as an individual's capacity for further functional improvement at least 6 months following stroke. We studied 21 chronic stroke patients with upper limb impairment. The functional integrity of the corticospinal tracts (CSTs) was assessed using TMS and functional MRI. The presence or absence of motor-evoked responses (MEPs) to TMS in the affected upper limb, and the lateralization of cortical activity during affected hand use were determined. The structural integrity of the CST was assessed using MRI, and diffusion tensor imaging was used to measure the asymmetry in fractional anisotropy (FA) of the internal capsules. A multiple linear regression analysis was performed, to predict both clinical score at inception and change in clinical score for 17 patients who completed a 30 day programme of motor practice with the affected upper limb. The main findings were that in patients with MEPs, meaningful gains were still possible 3 years after stroke, although the capacity for improvement declined with time. In patients without MEPs, functional potential declines with increasing CST disruption, with no meaningful gains possible if FA asymmetry exceeds a value of 0.25. This study is the first to demonstrate the complementary nature of TMS and MRI techniques in predicting functional potential in chronic stroke patients. An algorithm is proposed for the selection of individualized rehabilitation strategies, based on the prediction of functional potential. These strategies could include neuro-modulation using a range of emerging techniques, to prime the motor system for a plastic response to rehabilitation.

Keywords: rehabilitation outcomes; MRI/fMRI; motor performance; transcranial magnetic stimulation; diffusion tensor

Abbreviations: CST = corticospinal tract; DTI = diffusion tensor imaging; FA = fractional anisotropy; fMRI = functional MRI; MEP = motor-evoked potential; M1 = primary motor cortex; TMS = transcranial magnetic stimulation

Received July 11, 2006. Revised October 17, 2006. Accepted October 24, 2006. Advance Access publication December 4, 2006.

Introduction

Stroke is the third leading cause of death and the most common cause of long-term adult disability. Better strategies to improve function in people with chronic disability from stroke are required (Dobkin, 2004). Choosing the type and duration of rehabilitation, and determining whether an individual has reached their full potential for recovery, can be difficult. Techniques such as transcranial magnetic stimulation (TMS) and MRI may be used as prognostic indicators, but their role in rehabilitation has yet to be

defined (Guadagno *et al.*, 2003; Kobayashi and Pascual-Leone, 2003).

TMS can be used to evaluate the functional integrity of the corticospinal tract (CST) following stroke (Talelli *et al.*, 2006). In general, patients in whom TMS over primary motor cortex (M1) elicits motor-evoked potentials (MEPs) in the paretic upper limb muscles within 30 days of stroke make a better functional recovery than those patients without MEPs (Heald *et al.*, 1993; Rapisarda *et al.*, 1996;

Pennisi *et al.*, 1999; Dachy *et al.*, 2003). However, some authors have found that the presence or absence of MEPs has prognostic value at 4 weeks post-stroke, but not in the first 7 days (Binkofski *et al.*, 1996; Catano *et al.*, 1996). Furthermore, some patients without MEPs also make a good recovery (Arac *et al.*, 1994; Catano *et al.*, 1996; Escudero *et al.*, 1998; Trompetto *et al.*, 2000), which indicates that TMS cannot always detect the potential for significant functional improvement.

TMS can also be used to map the M1 representations of upper limb muscles following stroke. Patients in whom MEPs can be elicited bilaterally exhibit asymmetric corticomotor maps. The ipsilesional representations have higher stimulation thresholds, lower excitability and delayed MEP latencies, compared with contralesional representations (Catano *et al.*, 1996; Rossini and Pauri, 2000; Traversa *et al.*, 2000; Koski *et al.*, 2004; Talelli *et al.*, 2006). The balance of interhemispheric inhibition is also asymmetric. The contralesional hemisphere has a greater inhibitory effect on the ipsilesional hemisphere than vice versa (Shimizu *et al.*, 2002; Murase *et al.*, 2004). Recovery of motor function is associated with a decrease in ipsilesional stimulation threshold and changes in the size and position of ipsilesional motor maps, most likely as a consequence of plastic reorganization within M1 (Byrnes *et al.*, 1999; Rossini and Pauri, 2000; Koski *et al.*, 2004; Talelli *et al.*, 2006).

Imaging techniques, such as positron emission tomography and functional MRI (fMRI), can be used to assess cortical activity during affected upper limb use. In general, ipsilesional premotor and supplementary motor areas (SMAs) are more likely to be active following stroke, particularly when the M1 is damaged (Rossini *et al.*, 2003; Ward *et al.*, 2003a; Carey *et al.*, 2006; Hamzei *et al.*, 2006). Contralesional motor areas are also more likely to be engaged by affected upper limb use, producing a more bilateral pattern of activity (Feydy *et al.*, 2002; Ward, 2004; Butefisch *et al.*, 2005; Lotze *et al.*, 2006). Those patients who make meaningful gains in motor function with physical therapy exhibit a return towards contralateral cortical control of the affected upper limb, with an increase in ipsilesional cortical activity (Marshall *et al.*, 2000; Carey *et al.*, 2002; Johansen-Berg *et al.*, 2002a; Nelles, 2004; Carey *et al.*, 2005). In those with the poorest clinical outcomes cortical activity remains bilateral, and in some cases weighted towards the contralesional hemisphere (Loubinoux *et al.*, 2003; Ward *et al.*, 2003b). However, recent evidence has emerged demonstrating a higher-order function for contralesional motor areas during complex task performance with the affected hand, in patients with near-complete motor recovery (Gerloff *et al.*, 2006; Lotze *et al.*, 2006).

Magnetic resonance imaging can be used to determine the structural integrity of the CST. Diffusion weighted imaging can be used to visualize ischaemic regions within the CST, at a time when other forms of imaging may be inconclusive (Thomalla *et al.*, 2004; Yamada *et al.*, 2004; Thomalla *et al.*, 2005). Diffusion tensor imaging (DTI) can be used to

construct three-dimensional images of white matter tracts (Conturo *et al.*, 1999; Mori and van Zijl, 2002) and visualize their proximity to the infarct (Kunimatsu *et al.*, 2003; Konishi *et al.*, 2005; Lee *et al.*, 2005; Mukherjee, 2005). DTI can also be used to quantify CST integrity, by calculating the fractional anisotropy (FA) within a region of interest, such as the posterior limb of the internal capsule (PLIC). Following stroke, unilateral reductions in CST integrity give rise to interhemispheric asymmetries in FA values (Werring *et al.*, 2000), due to local tissue damage or Wallerian degeneration. Studies that have examined small homogeneous samples of subcortical stroke patients have found that larger asymmetries in FA are associated with poorer motor recovery (Watanabe *et al.*, 2001; Thomalla *et al.*, 2004; Jang *et al.*, 2005).

This study aims to predict an individual's capacity for further functional improvement at the chronic stage, which we have termed 'functional potential'. We explored the relationships between functional and structural measures of CST integrity, and their ability to predict both current impairment and improvement in upper limb function following a programme of motor practice. The general premise was that asymmetries in the structure of the CSTs are associated with poorer clinical outcomes. Conversely, highly asymmetric cortical activation during affected upper limb use, lateralized to the ipsilesional hemisphere, is associated with better outcomes.

Material and methods

We recruited patients who experienced a first-ever stroke at least 6 months prior to enrolment that resulted in persisting upper limb disability, from three hospitals and one rehabilitation facility in our region (Table 1). Exclusion criteria included any neurological or other condition that would prevent informed consent or hamper the acquisition or interpretation of the clinical or other data. Patients with ataxia, impaired kinaesthesia or an upper limb rating of 2 or more on the Modified Ashworth Scale (Bohannon and Smith, 1987) were excluded. Patients with contraindications to MRI or TMS, including those with metallic implants, a history of seizures and medications known to alter central nervous system excitability, were also excluded. Written informed consent was obtained from all participants in accordance with the Declaration of Helsinki, and the study was approved by the New Zealand Health and Disability Ethics Committees.

Clinical assessment

A blinded clinical assessor rated each participant using the National Institutes of Health Stroke Scale (NIHSS) and the upper limb movement section of the Fugl-Meyer (FM) scale (Fugl-Meyer *et al.*, 1975). The NIHSS is a measure of neurological functioning, with higher scores reflecting greater deficit (maximum 42). The FM is a measure of upper limb function, with higher scores reflecting greater function (maximum 32). Each tested movement is given a score of 0 (movement cannot be performed), 1 (reduced strength, speed, amplitude or precision) or 2 (normal). Maximal grip force was measured using a custom-built force transducer, calculated as the average of two trials for each hand. Hand grip asymmetry was

Table 1 Participant characteristics

Patient	Sex	Age	Time since stroke	NIHSS	FM	FM Δ	Hemi	Sense loss	Affected structures	Motor Cx	MEPs	FA
1	M	43	24	0	24	4	R	–	GP, Put, ICp	–	+	0.06
2	M	55	24	5	23	4	R	+	Insular, GP, Put, ICp	–	+	0.21
3	M	59	11	6	17	x	L	+	Occipital lobe	–	+	–0.01
4	F	58	53	4	17	0	L	+	Extracapsular	–	+	0.18
5	M	74	6	6	23	x	L	+	MCA territory	+	+	0.06
6	M	68	144	4	24	0	R	+	MCA territory	+	+	0.27
7	M	64	48	7	24	2	L	+	MCA territory	+	+	0.05
8	F	64	6	2	25	5	L	+	MCA territory	+	+	0.05
9	M	67	9	1	24	4	R	+	Frontal lobe	+	+	–0.01
10	M	38	6	3	18	3	R	+	Put, ICp	–	–	0.12
11	F	41	15	1	9	4	R	–	ICa, ICg, Caud, Put, GP	–	–	0.15
12	F	49	7	4	13	0	R	+	ICp, Put, GP	–	–	0.15
13	F	62	7	3	10	1	L	+	Insular, ICp, Put, GP, Thal	–	–	0.17
14	M	49	6	1	22	x	R	+	ICp, Thal	–	–	0.10
15	M	43	12	5	10	5	L	+	Parietal lobe	–	–	0.07
16	M	59	14	5	4	1	L	+	MCA territory	+	–	0.35
17	M	64	116	5	5	0	L	–	MCA territory	+	–	0.42
18	M	25	7	6	11	1	L	+	MCA territory	+	–	0.30
19	M	56	73	3	4	0	L	–	MCA territory	+	–	0.33
20	M	59	17	4	10	6	L	–	MCA territory	+	–	0.16
21	F	45	6	2	17	x	R	–	Parietal lobe	+	–	0.07
Mean		54	29	4	16	2						0.15
SD		12	38	2.0	7.3	2.1						0.12
Max		74	144	7	25	6						0.42
Min		25	6	0	4	0						–0.01

Age (years). Time since stroke (months). NIHSS score (maximum 42). FM = Fugl-Meyer upper limb score (maximum 32). Hemi = hemisphere affected by stroke. Sense loss = mild loss of cutaneous sensation of affected upper limb. Affected structures: GP = globus pallidus; Put = putamen; ICp = posterior limb of the internal capsule; ICa = anterior limb of the anterior capsule; ICg = genu of the internal capsule; Caud = caudate; Thal = thalamus; MCA territory = extensive involvement of middle cerebral artery territory; Motor Cx = motor cortex damage; MEPs = motor-evoked potentials elicited from ECR of the affected upper limb, using TMS; FA = fractional anisotropy asymmetry, calculated at the level of the PLIC.

calculated as $(\text{Grip}_{\text{unaff}} - \text{Grip}_{\text{aff}}) / (\text{Grip}_{\text{unaff}} + \text{Grip}_{\text{aff}})$. Values can range between -1.0 and $+1.0$, with positive values indicating greater grip force in the unaffected hand, and a value of zero indicating symmetrical grip force.

All patients were assessed twice, separated by 1 month, to confirm that their upper limb function was clinically stable prior to the programme of motor practice. At the second assessment, neurophysiological data were collected. Clinical assessment was repeated after patients completed a 30 day programme of motor practice, using their affected limb. This programme required patients to practice picking up and moving small wooden blocks for 10 min at a time, on three occasions spread over the course of each day. For some patients, motor practice was preceded by 10 min of passive flexion and extension of the affected wrist. For each patient, functional potential was defined as the change in their FM score.

TMS

Single pulse TMS was delivered using a MagStim 200 stimulator (MagStim Company, Dyfed, UK), via a figure-of-eight coil. Motor-evoked potentials were recorded from the extensor carpi radialis (ECR) muscles of each forearm, using standard techniques described previously (Stinear and Byblow, 2004b). Rest motor threshold (RMT) of each target muscle (ECR) was determined (Rossini *et al.*, 1994). If MEPs could not be elicited in the affected limb while it remained at rest, using maximal stimulator output (100% MSO), the patient was instructed to voluntarily extend their

wrist to activate the target muscle. If MEPs could not be elicited during voluntary activity, using 100% MSO, the patient was classified as having no MEP responses in the affected target muscle.

When MEPs could be elicited, mapping of the target muscle cortical representation was carried out by delivering 6 stimuli at each of 18 pre-determined grid points, centred 5 cm lateral to the vertex on the inter-aural line. A tight-fitting cloth cap marked with a 1 cm \times 1 cm grid was centred on the patient's vertex. For each patient, the grid points were stimulated in a different pseudo-randomized order. Trials were rejected online if pre-trigger EMG in either target muscle exceeded 0.01 mV (root mean square, calculated over 85 ms prior to the trigger). MEP latency was calculated by averaging the latencies of the six MEPs collected at the site that produced the largest amplitude MEPs. For the construction of corticomotor maps, MEP area (mV·s) was calculated for each response over a 15 ms window, starting at MEP onset. The number of active sites within each map was defined as the number of sites with a mean MEP area exceeding 0.075 mV·s. Map volume was calculated by summing the mean MEP area at each active grid site. Map density (MD) was calculated by dividing the map volume by the number of active sites, to give an average MEP area per active site. The lateralization of map density across the two hemispheres was calculated by MD asymmetry = $(\text{MD}_{\text{unaff}} - \text{MD}_{\text{aff}}) / (\text{MD}_{\text{unaff}} + \text{MD}_{\text{aff}})$. This yields a value between $+1.0$ and -1.0 , with positive values indicating greater map density in the contralesional hemisphere.

MRI

Scanning was performed using a Siemens Magnetom Avanto 1.5 T MRI system. T_1 -weighted images were acquired with a 3D MPRAGE sequence [TR = 11 ms, TE = 4.94 ms, field of view (FOV) 256 mm and voxel dimensions of $1.0 \times 1.0 \times 1.0$ mm]. T_2 -weighted 2D axial images were also acquired (TR = 3860 mm, TE = 89 mm, FOV = 230 mm, voxel dimensions = $0.6 \text{ mm} \times 0.4 \text{ mm} \times 5.0 \text{ mm}$). Blood oxygen level-dependent contrast images were acquired using a T_2^* -weighted single-shot gradient echo EPI sequence (TR = 2570 ms, TE = 50 ms, FOV = 192 mm, voxel dimension = $3.0 \times 3.0 \times 3.0$ mm). DTI was conducted with a single shot spin echo EPI pulse sequence (TR = 4800 ms, TE = 88 ms) with 12 uniformly distributed Stejskal–Tanner (Stejskal and Tanner, 1965) motion-probing gradient orientations ($b = 1000 \text{ s/mm}^2$). The FOV was 230 mm, with voxel dimensions of $1.8 \times 1.8 \times 3.0$ mm. Both fMRI and DTI sequences were obtained in the same session, taking ~ 40 min.

The T_1 - and T_2 -weighted images were evaluated by a neurologist and neuroradiologist, who were blinded to the clinical and TMS data, to determine which structures were affected by the stroke. Motor cortex damage was defined as loss of white and/or grey matter in the pre-central gyrus (BA4). MRI and TMS experiments were performed as close together as possible (mean 8, range 1–20 days).

To examine the lateralization of cortical activity during affected hand use, an fMRI experiment was performed that involved brisk, self-paced hand opening and closing. Cues were presented on a semi-transparent screen at the end of the scanner bed, viewed via a mirror located in the head coil. Cues were presented in a block design with four different hand movement conditions (left, right, bimanual, rest). Each task condition was carried out for 30 s, once per block in a pseudorandom order. There were 4 scanning runs, each of 2 min duration. Patients were trained on the task prior to scanning. To verify accurate task performance and check for mirror movements, a saline drip bag connected to a pressure transducer was placed in each hand, and signals were monitored online. No mirror movements were detected, and patients responded correctly to all cues.

Functional images were slice-time corrected, realigned and co-registered to the T_1 -weighted image, and smoothed (FWHM = 8 mm) using SPM2. Stroke lesions were masked by creating individual ROIs in MRICro prior to spatial normalization of all images to the MNI template brain (Brett *et al.*, 2001). Conditions were modelled as a fixed response (boxcar) convolved with the haemodynamic response function. The activation of six ROIs was determined bilaterally: Brodmann's areas 4, 4a and 4p, primary sensory cortex (S1), SMA, and premotor cortex (PMC). These ROIs were based on probabilistic cytoarchitectonic maps (Eickhoff *et al.*, 2005), identified using the SPM2 Anatomy Toolbox and the MarsBaR analysis toolbox (Wellcome Department of Imaging Neuroscience, University College, London), with an activation threshold of $t > 2.9$.

The lateralization of cortical activity during affected hand use was calculated from the number of active voxels in each ROI bilaterally, expressed as a percentage active voxels (PAVs). For each patient, cortical activity lateralization was calculated as $(PAV_{\text{unaff}} - PAV_{\text{aff}}) / (PAV_{\text{unaff}} + PAV_{\text{aff}})$. Values range between -1.0 and $+1.0$, where -1.0 indicates that all of the cortical activity during affected hand use occurred within the ipsilesional ROI. Conversely, a value of $+1.0$ indicates that all of the cortical activity during affected hand use occurred within the contralesional ROI. A study of 10 healthy adults performing this task (mean age 58 years, range 36–77 years)

showed that cortical activity is almost completely lateralized to sensorimotor areas contralateral to the moving hand. The mean (min, max) lateralization values for each ROI were: BA4 0.97 (0.87, 1.0); BA4a 0.95 (0.78, 1.0); BA4p 1.0 (1.0, 1.0); S1 0.94 (0.73, 1.0); SMA 0.51 (0.26, 1.0); PMC 0.86 (0.73, 1.0), in agreement with previous studies of simple hand movements (Rao *et al.*, 1993; Gordon *et al.*, 1998; Newton *et al.*, 2005).

For the DTI data, the diffusion tensor at each voxel was calculated as the least-squares best fit to a single 3D Gaussian distribution. Eigenvalue decomposition of the diffusion tensors permitted calculation of FA maps (Basser and Pierpaoli, 1996). FA is a unitless measure, where values approaching 1 indicate strongly isodirectional water molecule diffusion, such as that which occurs in densely packed white matter tracts (Le Bihan *et al.*, 2001). If the structural integrity of a tract is disrupted, FA decreases (Werring *et al.*, 2000; Le Bihan *et al.*, 2001; Sotak, 2002). Tractography was performed using DTI Track 2005 software (Pierre Fillard, INRIA, Sophia-Antipolis Research Unit).

The PLIC was delineated bilaterally, from the level of the anterior commissure to the base of the corona radiata, for each participant using the ROI feature from MRICro, with reference to FA RGB images and the MRI Atlas of Human White Matter (Mori *et al.*, 2005). FA was computed for the affected and unaffected PLICs, and used to calculate the asymmetry of PLIC integrity: $FA \text{ asymmetry} = (FA_{\text{unaff}} - FA_{\text{aff}}) / (FA_{\text{unaff}} + FA_{\text{aff}})$. This yields a value between -1.0 and $+1.0$, where positive values indicate reduced FA in the affected PLIC, and a value of 0 indicates symmetrical FA in the PLICs. In subjects with complete destruction of the affected PLIC, the volume of interest was estimated as a mirror image of the unaffected PLIC. Increased use of the contralesional hemisphere may produce a decrease in contralesional internal capsule FA (Schmithorst and Wilke, 2002), which would lead to a decrease in FA asymmetry. It is also unlikely that FA asymmetry in the PLIC is affected by handedness (Buchel *et al.*, 2004).

Data analysis

Stepwise multiple linear regression analyses were conducted using SPSS software (SPSS Inc, Chicago, USA), to determine the variables that predict clinical score at inception, and change in clinical score following a programme of motor practice by the affected hand (30 min per day for 30 days). The variables predicting the lateralization of cortical activity during affected hand use were also determined. Age, hemisphere affected, time since stroke, hand grip asymmetry, MD asymmetry, FA asymmetry, lateralization of cortical activity, and the presence or absence of motor cortex damage and MEPs in the affected target muscle were included in the analysis. The adopted level of statistical significance was $\alpha = 0.05$.

Results

Clinical assessment

We studied 21 patients (6 female, mean age 54 years), with a mean FM score prior to practice of 16 (range 4–25), and mean NIHSS score of 4 (range 0–7). Patient characteristics are presented in Table 1. We assessed 17 patients before and after a programme of motor practice (follow-up data are not available on four patients). Data from two representative patients are presented in Fig. 1. Upper limb function was clinically stable, with no significant difference between the two baseline FM scores (paired t -test, $P = 0.89$). Mean grip

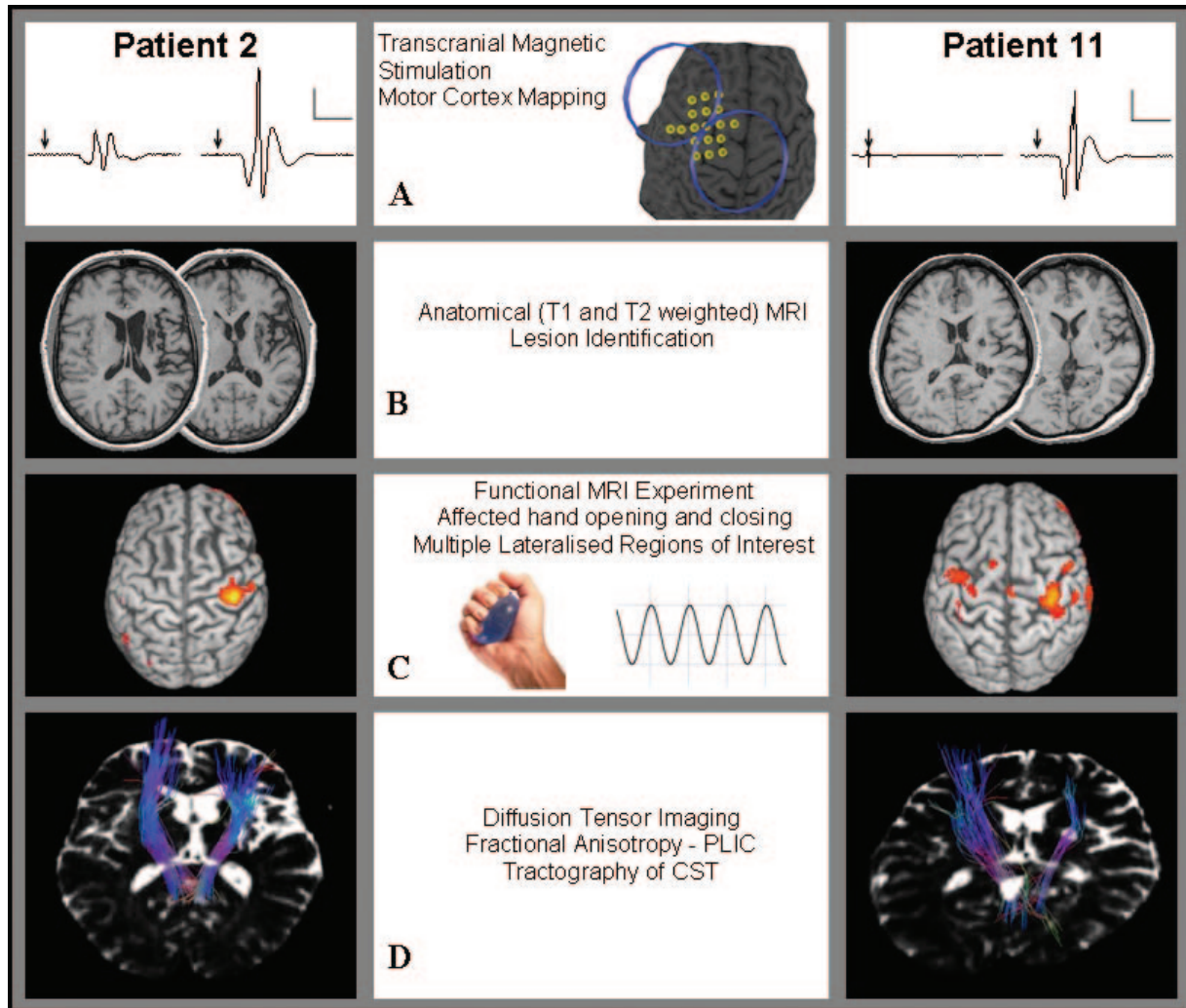


Fig. 1 Functional and structural data from Patients 2 and 11. FM upper limb scores: Patient 2 = 23; Patient 11 = 9. **(A)** For each pair of traces, the affected ECR is presented on the left, and unaffected ECR on the right. TMS elicited MEPs in the affected upper limb of Patient 2, but not Patient 11. Arrows indicate time of magnetic stimulus. Calibration bars: 0.2 mV and 25 ms. **(B)** Both patients had a right hemisphere stroke. **(C)** During affected hand use functional MRI revealed ipsilesional cortical activity for Patient 2, and bilateral cortical activity for Patient 11. Patients squeezed and released saline bags connected to pressure transducers, which allowed monitoring of behavioural performance. **(D)** Superior–posterior view of an axial T₂ image, overlaid at the level of the PLIC by CST fibres. The CST fibres depicted are those that originate in the hand area of the precentral gyrus. Diffusion tensor imaging was used to calculate FA in the PLIC. The FA asymmetry values were 0.21 for Patient 2, and 0.15 for Patient 11. Both patients had improvements in FM scores of 4 points, following one month of motor practice with the affected upper limb.

force was 87.1 N (SD 47.1 N) for the affected hand, and 243.4 N (SD 70.5 N) for the unaffected hand. Hand grip strength asymmetry was 0.48 (SD 0.24). The median increase in FM score following a programme of motor practice was 2 points (range 0–6 points).

TMS

For the unaffected target muscle, the mean RMT was 47.8% MSO (SD 9.6% MSO), and the mean MEP latency was 18.7 ms (SD 1.6 ms). EMG was monitored bilaterally and ipsilateral MEPs were never observed. For the nine patients in whom MEPs were elicited in the affected limb, the mean

RMT for the target muscle was 64.7% MSO (SD 22.0% MSO), and the mean latency was 20.9 ms (SD 3.1 ms). For these patients, mean map density (MD) asymmetry was 0.22 (SD 0.46), indicating that the motor cortex excitability was weakly lateralized towards the contralesional hemisphere.

MRI

FA asymmetry values for each patient are presented in Table 1. Cortical activation during affected hand use was found to be lateralized towards the ipsilesional hemisphere. The mean (min, max) lateralization values for each ROI were: BA4 −0.36 (−1.0, 0.56); BA4a −0.34 (−1.0, 0.55);

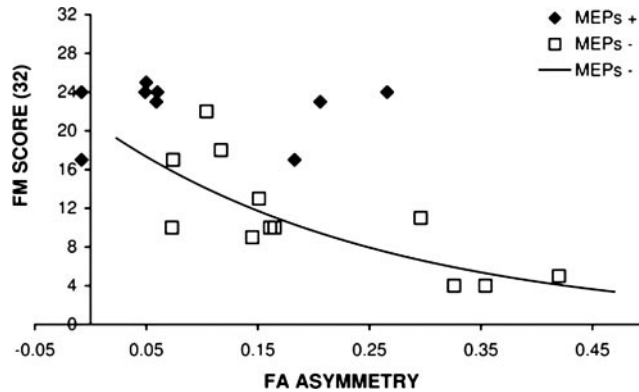


Fig. 2 The relationship between FA asymmetry and FM score, in patients with (MEPs+) and without (MEPs-) responses to TMS in the affected upper limb. Higher values of FA asymmetry are associated with greater asymmetry in PLIC integrity. There is a significant exponential relationship between FA asymmetry and FM score ($R^2 = 0.67$, $P = 0.001$). In the absence of MEPs, FA asymmetry > 0.25 is associated with poor recovery of upper limb function.

BA4p -0.40 (-1.0 , 1.0); S1 -0.21 (-1.0 , 1.0); SMA -0.19 (-1.0 , 0.33); PMC -0.34 (-1.0 , 0.99). Given that symmetrical activity yields a value of zero, and purely ipsilesional activity yields a value of -1.0 , these values indicate bilateral cortical activity that is weakly lateralized towards the ipsilesional hemisphere during affected hand use. Lateralization of BA4 activity towards the ipsilesional hemisphere was more likely in patients whose motor cortex was intact [$R^2 = 0.23$, $F(1,19) = 6.9$, $P = 0.017$]. The presence or absence of MEPs and FA asymmetry did not predict the lateralization of cortical activity in BA4.

Prediction of clinical score at inception

The presence or absence of MEPs in the affected limb was found to strongly predict FM score at inception [$R^2 = 0.58$, $F(1,19) = 29.0$, $P < 0.001$]. The predictive power of the model significantly increased when FA asymmetry was added [$R^2 = 0.70$, $F(2,17) = 23.5$, $P < 0.001$]. Motor cortex damage, left or right hemisphere affected, time since stroke, age and grip force asymmetry had no predictive power (all $P > 0.4$).

When patients without MEPs were analysed separately, increasing FA asymmetry predicted lower FM scores [$R^2 = 0.51$, $F(1,10) = 12.6$, $P = 0.005$]. This relationship was found to be more accurately modelled with an exponential function [$R^2 = 0.67$, $F(1,9) = 20.3$, $P = 0.001$] (Fig. 2). For this subgroup, a relationship was also found between the lateralization of cortical activity in area BA4p (M1) during affected hand use and clinical score. Higher FM scores were predicted by stronger lateralization of cortical activity towards the ipsilesional M1 [$R^2 = 0.32$, $F(1,10) = 6.1$, $P = 0.03$].

When patients with MEPs were analysed separately, no variables had any predictive power, including FA and MD asymmetry, and lateralization of cortical activity during affected hand use (all $P > 0.3$) (Fig. 2).

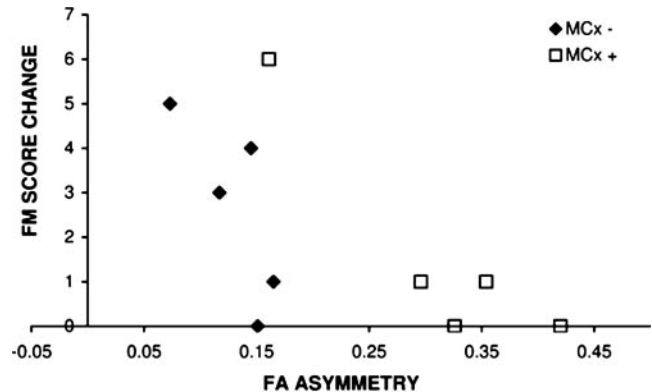


Fig. 3 The relationship between FA asymmetry and change in FM score, in patients with MEPS in the affected upper limb, and with MI damage (MCx+) or without (MCx-). Higher values of FA asymmetry are associated with greater asymmetry in PLIC integrity. Increasing FA asymmetry and motor cortex damage predict lower functional potential ($R^2 = 0.71$, $P = 0.014$).

Prediction of response to motor practice

FA asymmetry was found to predict the change in FM score following motor practice [$R^2 = 0.38$, $F(1,15) = 10.7$, $P = 0.005$]. Age, hemisphere affected, grip force asymmetry and clinical score at inception did not predict the extent of functional improvement following the programme of motor practice (all $P > 0.3$).

When patients without MEPs were analysed separately, increasing FA asymmetry and motor cortex damage predicted less functional potential [$R^2 = 0.71$, $F(2,7) = 8.6$, $P = 0.013$] (Fig. 3). When patients with MEPs were analysed separately, functional improvement was no longer predicted by FA asymmetry. Rather, time since stroke was the strongest predictor, with greater time elapsed predicting less improvement in upper limb function [$R^2 = 0.61$, $F(1,5) = 10.3$, $P = 0.02$]. The predictive power of the model significantly increased when clinical score at inception was added [$R^2 = 0.91$, $F(2,4) = 30.5$, $P = 0.004$]. Higher clinical score at inception predicted greater improvement in upper limb function.

The lateralization of cortical activity across the ipsilesional and contralesional hemispheres did not predict functional improvement following motor practice. Neither lateralization calculated from the per cent active voxels during affected hand use in the fMRI study, nor calculated from MD asymmetry at rest in the TMS study, had any relationship with the change in FM score following motor practice.

Discussion

This is the first study to demonstrate that measures of CST integrity predict the potential for clinical improvement in chronic stroke patients. It is also the first to demonstrate the complementary nature of neurophysiological and imaging techniques in the prediction of functional potential and clinical outcomes. These findings have implications for

clinical decision-making. Evaluation of CST integrity, using a combination of neurophysiological measures and imaging, can inform the setting of therapeutic goals, and the selection of patients for particular rehabilitation programmes.

Prediction of current upper limb function

Clinical score at inception was strongly predicted by the presence or absence of MEPs in the affected upper limb, where those with MEPs had better upper limb function than those without, consistent with previous reports (Rapisarda *et al.*, 1996; Escudero *et al.*, 1998; Trompetto *et al.*, 2000; Dachy *et al.*, 2003). In patients with MEPs, FA asymmetry had no predictive power for current clinical score. This implies that FA asymmetry is not critical if the integrity of the corticospinal pathway is sufficient for MEP transmission.

For patients without MEPs, current clinical score was strongly predicted by FA asymmetry, where greater asymmetry was associated with poorer upper limb function. This relationship was exponential, with a sharp decrease in clinical score as FA asymmetry increased above 0.25. This finding fits with the general idea that descending pathways from non-primary motor areas may play a role in affected limb function when pathways from M1 are damaged (Fries *et al.*, 1993; Johansen-Berg *et al.*, 2002b; Fridman *et al.*, 2004; Stinear and Byblow, 2004a; Ward *et al.*, 2006). When M1 pathways are damaged to the point where MEPs cannot be elicited, a small additional loss of PLIC integrity may produce a large reduction in upper limb function. This may reflect damage to descending pathways from non-primary motor areas, reducing the capacity for functional reorganization in the ipsilesional motor system.

The fMRI study demonstrated that in patients with intact ipsilesional motor cortex, cortical activity during affected hand use tended to be lateralized towards the ipsilesional hemisphere. Conversely, patients with motor cortex damage were more likely to lateralize cortical activity towards the contralesional hemisphere. For patients without MEPs, ipsilesional activity was associated with better upper limb function, whereas cortical activity was lateralized to the contralesional hemisphere in those patients with the poorest clinical outcomes. These findings are in keeping with previous reports (Loubinoux *et al.*, 2003; Ward *et al.*, 2006), and suggest that while contralesional motor cortex can become more engaged when ipsilesional motor cortex is damaged, functional outcomes remain poor.

Prediction of functional potential

For patients with MEPs, functional potential declined with increasing time since stroke. Our data suggest that meaningful functional improvements can occur within the first 3 years following stroke—a considerably longer interval than commonly accepted (Bonita and Beaglehole, 1988; Duncan *et al.*, 1992). This may have been due to the motor practice programme counteracting learned non-use of the affected

upper limb (Andre *et al.*, 2004). In this subgroup of patients with MEPs, functional potential was also greater in those with FM scores of more than 20 at inception. This suggests that even those with good recovery can make further functional gains within the first 3 years post-stroke.

For patients without MEPs, functional potential depended on FA asymmetry, and whether motor cortex was affected by the stroke. Patients with motor cortex damage, and greater asymmetry in PLIC integrity, were unable to make meaningful functional gains. Our data suggest that an FA asymmetry of 0.25 is a ‘point of no return’, beyond which functional potential is severely limited, consistent with previous reports (Jang *et al.*, 2005; Thomalla *et al.*, 2004).

For patients both with and without MEPs the lateralization of cortical activity assessed by fMRI, and the asymmetry of corticomotor maps assessed by TMS, did not predict functional potential. Improvements in upper limb function, in response to physical therapy, are associated with a shift in the balance of cortical activity towards the ipsilesional hemisphere (Marshall *et al.*, 2000; Carey *et al.*, 2002, 2005; Johansen-Berg *et al.*, 2002a; Rossini *et al.*, 2003; Nelles, 2004; Serrien *et al.*, 2004). However, the present data suggest that the lateralization of cortical activity prior to therapy cannot predict the degree of functional improvement following therapy.

Time since stroke and current clinical score were not predictors of functional potential in isolation, and had to be combined with neurophysiological and imaging data in order to gain any predictive power. Therefore, a clinician cannot accurately predict an individual’s capacity for further recovery by evaluating current clinical status alone. For stroke patients with some level of upper limb disability, an assessment of CST integrity using neurophysiological and imaging techniques could play an important role in the setting of rehabilitation goals. This study shows that TMS and MRI are complementary techniques. TMS can identify those patients likely to have a good clinical outcome. However, it is unable to detect which patients without MEPs in the affected limb have good functional potential, and are also likely to respond well to rehabilitation. MRI techniques may be required to identify these patients, by determining the degree of motor cortex damage and asymmetry in PLIC integrity.

Evaluation of functional potential to guide individualized rehabilitation

Functional potential can be similar in patients with disparate clinical presentations. Figure 1 provides an example of this, illustrating key variables for two patients, both of whom had FM score increases of 4 points following the programme of motor practice. In Patient 2 the subcortical stroke has spared the hand area CST fibres, affecting other elements of the PLIC. This may account for Patient 2’s high initial FM score of 23, and the presence of MEPs in the affected limb. In Patient 11 the stroke damaged the hand area CST fibres, but

Evaluation of functional potential to guide individualised upper limb rehabilitation

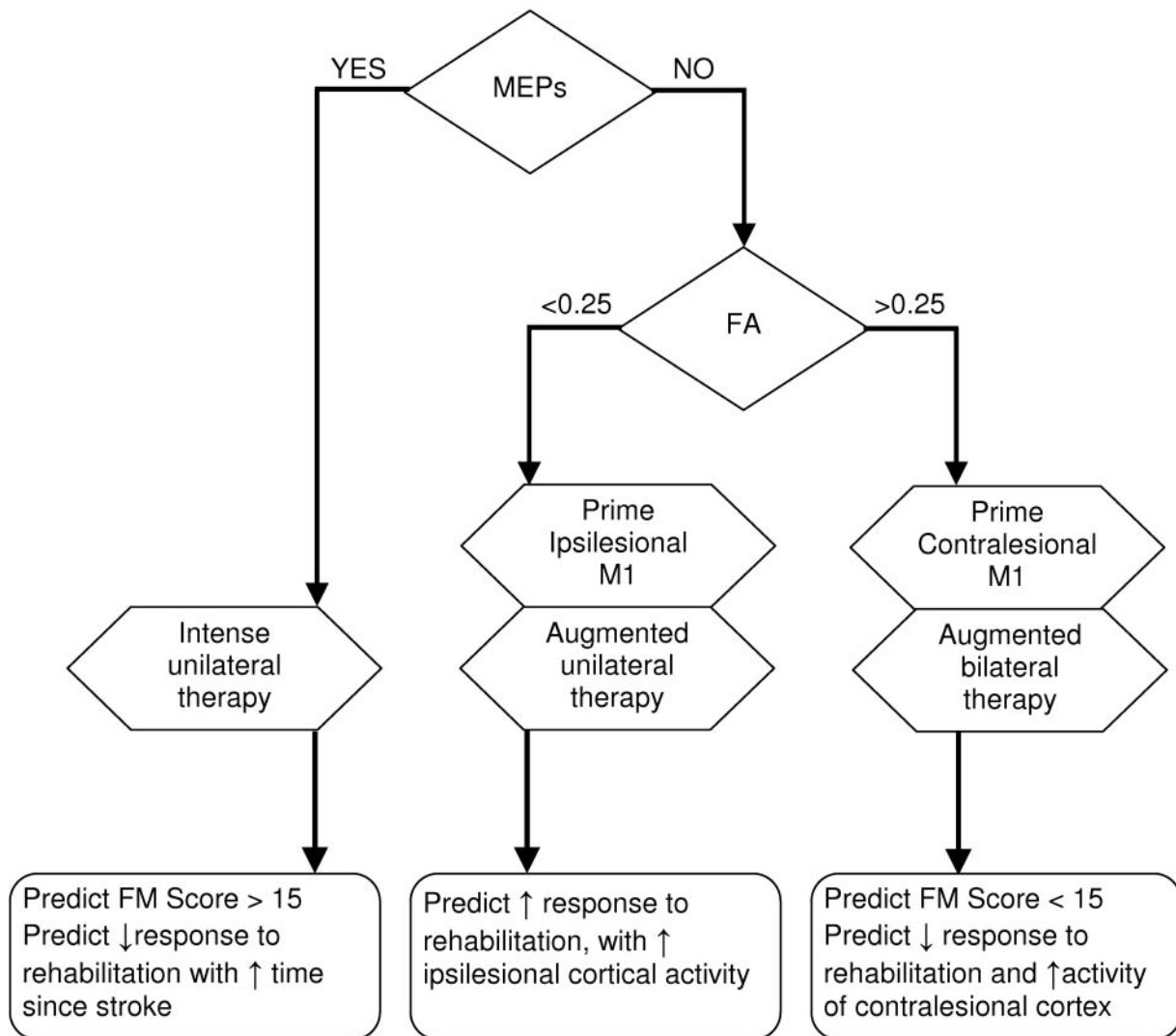


Fig. 4 An algorithm to predict functional potential for upper limb recovery, and provide targeted rehabilitation, following stroke. The presence or absence of motor-evoked potentials (MEPs) elicited by TMS over motor cortex, and the integrity of the corticospinal pathway as derived from measures of FA using diffusion tensor imaging, predict functional potential and determine which hemisphere to target during therapy. Neuromodulation techniques which ‘prime’ the appropriate hemisphere to be maximally responsive to therapeutic inputs could serve as an adjuvant to targeted physical therapy (Hummel and Cohen, 2006).

spared CST fibres projecting from other cortical areas. This may account for Patient 11’s lower initial FM score of 9, and the absence of MEPs in the affected limb. For both patients, functional potential depended on the preservation of some descending pathways, evidenced by the presence of MEPs in Patient 2, and FA asymmetry below 0.25 (the ‘point of no return’) for Patient 11. Importantly, in the case of Patient 11, TMS alone (absence of MEPs) is not sufficient to predict recovery of upper limb function.

We propose an algorithm to predict the functional potential for upper limb recovery, presented in Fig. 4. The algorithm can also be used to identify potential rehabilitation

strategies. Patients in whom TMS elicits MEPs in the affected upper limb are expected to make a moderate to complete functional recovery. This could be enhanced by rehabilitation strategies that include intense use of the affected limb, such as constraint therapy (van der Lee, 2003; Dettmers *et al.*, 2005; Taub *et al.*, 2006). While functional potential declines with increasing time since stroke in this group, meaningful functional gains may still be made in the first 3 years. This implies that selected patients may benefit from extended rehabilitation, which could take the form of intermittent periods of self-directed physical therapy. Further investigation of this hypothesis is warranted.

For patients in whom TMS fails to elicit responses in the affected upper limb, DTI provides a useful measure of CST integrity. Those patients with FA asymmetry of <0.25 have greater functional potential, and are more likely to lateralize cortical activity towards the ipsilesional motor cortex during affected upper limb use. This ipsilesional lateralization may be enhanced by interventions designed to increase the excitability and plasticity of the ipsilesional cortex. Priming the ipsilesional cortex, as an adjuvant therapy, may improve functional outcomes in this group (Stefan *et al.*, 2000; Stinear and Byblow, 2004b; Fregni *et al.*, 2005; Huang *et al.*, 2005; Hummel *et al.*, 2005; Khedr *et al.*, 2005; Mansur *et al.*, 2005; Takeuchi *et al.*, 2005; Smith and Staines, 2006; Ziemann *et al.*, 2006).

Finally, patients without MEP responses to TMS in the affected upper limb, and FA asymmetry of >0.25 , are likely to have low functional potential and poor recovery of upper limb function. They are also more likely to engage the contralesional motor cortex during affected upper limb use. This suggests that once damage to the CST exceeds a ‘point of no return’, the limited control that can be assumed by the contralesional hemisphere is responsible for the small functional gains made. Compensatory activity in the contralesional hemisphere could be enhanced by neuromodulatory interventions that increase its excitability, which may be possible with augmented forms of therapy that engage both hemispheres (Cauraugh *et al.*, 2005; Cauraugh and Summers, 2005; Hesse *et al.*, 2005).

Evaluating functional potential using the proposed algorithm may be useful in selecting individualized rehabilitation strategies for upper limb recovery, as part of the patient’s overall management. While the proposed algorithm is based on the present data, it also unifies and resolves the occasionally contradictory findings of studies that have examined the predictive power of these techniques individually (Arac *et al.*, 1994; Escudero *et al.*, 1998; Trompetto *et al.*, 2000; Thomalla *et al.*, 2004; Jang *et al.*, 2005). This algorithm could be used to tailor rehabilitation strategies for the individual, incorporating emerging neuromodulation techniques (Hummel and Cohen, 2006). Future studies will examine how measures of CST integrity can be used to select rehabilitation strategies for individuals recovering from stroke.

Acknowledgements

The authors wish to thank Toby Verryt, Patricia Bennett, Linda Ross, Yvette Baker, Dr Samir Anwar, Dr Timothy Verstynen, Dr Nicole Wenderoth, the Centre for Advanced MRI, and the Stroke Foundation of New Zealand. This research was funded by the Health Research Council of New Zealand.

References

Andre JM, Didier JP, Paysant J. ‘Functional motor amnesia’ in stroke (1904) and ‘learned non-use phenomenon’ (1966). *J Rehabil Med* 2004; 36: 138–40.

Arac N, Sagduyu A, Binai S, Ertekin C. Prognostic value of transcranial magnetic stimulation in acute stroke. *Stroke* 1994; 25: 2183–6.

Basser PJ, Pierpaoli C. Microstructural and physiological features of tissues elucidated by quantitative-diffusion-tensor MRI. *J Magn Reson B* 1996; 111: 209–19.

Binkofski F, Seitz RJ, Arnold S, Classen J, Benecke R, Freund HJ. Thalamic metabolism and corticospinal tract integrity determine motor recovery in stroke. *Ann Neurol* 1996; 39: 460–70.

Bohannon RW, Smith MB. Interrater reliability of a modified Ashworth scale of muscle spasticity. *Phys Ther* 1987; 67: 206–7.

Bonita R, Beaglehole R. Recovery of motor function after stroke. *Stroke* 1988; 19: 1497–500.

Brett M, Leff AP, Rorden C, Ashburner J. Spatial normalization of brain images with focal lesions using cost function masking. *Neuroimage* 2001; 14: 486–500.

Buchel C, Raedler T, Sommer M, Sach M, Weiller C, Koch MA. White matter asymmetry in the human brain: a diffusion tensor MRI study. *Cereb Cortex* 2004; 14: 945–51.

Butefisch CM, Kleiser R, Korber B, Muller K, Wittsack HJ, Homberg V, et al. Recruitment of contralesional motor cortex in stroke patients with recovery of hand function. *Neurology* 2005; 64: 1067–9.

Byrnes ML, Thickbroom GW, Phillips BA, Wilson SA, Mastaglia FL. Physiological studies of the corticomotor projection to the hand after subcortical stroke. *Clin Neurophysiol* 1999; 110: 487–98.

Carey JR, Kimberley TJ, Lewis SM, Auerbach EJ, Dorsey L, Rundquist P, et al. Analysis of fMRI and finger tracking training in subjects with chronic stroke. *Brain* 2002; 125: 773–88.

Carey LM, Abbott DF, Egan GF, Bernhardt J, Donnan GA. Motor impairment and recovery in the upper limb after stroke: behavioral and neuroanatomical correlates. *Stroke* 2005; 36: 625–9.

Carey LM, Abbott DF, Egan GF, O’Keefe GJ, Jackson GD, Bernhardt J, et al. Evolution of brain activation with good and poor motor recovery after stroke. *Neurorehabil Neural Repair* 2006; 20: 24–41.

Catano A, Houa M, Caroyer JM, Ducarne H, Noel P. Magnetic transcranial stimulation in acute stroke: early excitation threshold and functional prognosis. *Electroencephalogr Clin Neurophysiol* 1996; 101: 233–9.

Cauraugh JH, Summers JJ. Neural plasticity and bilateral movements: a rehabilitation approach for chronic stroke. *Prog Neurobiol* 2005; 75: 309–20.

Cauraugh JH, Kim SB, Duley A. Coupled bilateral movements and active neuromuscular stimulation: Intralimb transfer evidence during bimanual aiming. *Neurosci Lett* 2005; 382: 39–44.

Conturo TE, Lori NF, Cull TS, Akbudak E, Snyder AZ, Shimony JS, et al. Tracking neuronal fiber pathways in the living human brain. *Proc Natl Acad Sci USA* 1999; 96: 10422–7.

Dachy B, Biltiau E, Bouillot E, Dan B, Deltenre P. Facilitation of motor evoked potentials in ischemic stroke patients: prognostic value and neurophysiologic correlations. *Clin Neurophysiol* 2003; 114: 2370–5.

Dettmers C, Teske U, Hamzei F, Uswatte G, Taub E, Weiller C. Distributed form of constraint-induced movement therapy improves functional outcome and quality of life after stroke. *Arch Phys Med Rehabil* 2005; 86: 204–9.

Dobkin BH. Strategies for stroke rehabilitation. *Lancet Neurol* 2004; 3: 528–36.

Duncan PW, Goldstein LB, Matchar D, Divine GW, Feussner J. Measurement of motor recovery after stroke. Outcome assessment and sample size requirements. *Stroke* 1992; 23: 1084–9.

Eickhoff SB, Stephan KE, Mohlberg H, Grefkes C, Fink GR, Amunts K, et al. A new SPM toolbox for combining probabilistic cytoarchitectonic maps and functional imaging data. *Neuroimage* 2005; 25: 1325–35.

Escudero JV, Sancho J, Bautista D, Escudero M, Lopez-Trigo J. Prognostic value of motor evoked potential obtained by transcranial magnetic brain stimulation in motor function recovery in patients with acute ischemic stroke. *Stroke* 1998; 29: 1854–9.

Feydy A, Carlier R, Roby-Brami A, Bussel B, Cazalis F, Pierot L, et al. Longitudinal study of motor recovery after stroke: recruitment and focusing of brain activation. *Stroke* 2002; 33: 1610–7.

- Fregni F, Boggio PS, Mansur CG, Wagner T, Ferreira MJ, Lima MC, et al. Transcranial direct current stimulation of the unaffected hemisphere in stroke patients. *Neuroreport* 2005; 16: 1551–5.
- Fridman EA, Hanakawa T, Chung M, Hummel F, Leiguarda RC, Cohen LG. Reorganization of the human ipsilesional premotor cortex after stroke. *Brain* 2004; 127: 747–58.
- Fries W, Danek A, Scheidtmann K, Hamburger C. Motor recovery following capsular stroke. Role of descending pathways from multiple motor areas. *Brain* 1993; 116: 369–82.
- Fugl-Meyer AR, Jaasko L, Leyman I, Olsson S, Steglind S. The post-stroke hemiplegic patient I. A method for evaluation of physical performance. *Scand J Rehabil Med* 1975; 7: 13–31.
- Gerloff C, Bushara K, Sailer A, Wassermann EM, Chen R, Matsuoka T, et al. Multimodal imaging of brain reorganization in motor areas of the contralesional hemisphere of well recovered patients after capsular stroke. *Brain* 2006; 129: 791–808.
- Gordon AM, Lee JH, Flament D, Ugurbil K, Ebner TJ. Functional magnetic resonance imaging of motor, sensory, and posterior parietal cortical areas during performance of sequential typing movements. *Exp Brain Res* 1998; 121: 153–66.
- Guadagno JV, Calautti C, Baron JC. Progress in imaging stroke: emerging clinical applications. *Br Med Bull* 2003; 65: 145–57.
- Hamzei F, Liepert J, Dettmers C, Weiller C, Rijntjes M. Two different reorganization patterns after rehabilitative therapy: an exploratory study with fMRI and TMS. *Neuroimage* 2006; 31: 710–20.
- Heald A, Bates D, Cartlidge NE, French JM, Miller S. Longitudinal study of central motor conduction time following stroke. 2. Central motor conduction measured within 72 h after stroke as a predictor of functional outcome at 12 months. *Brain* 1993; 116: 1371–85.
- Hesse S, Werner C, Pohl M, Rueckriem S, Mehrholz J, Lingnau ML. Computerized arm training improves the motor control of the severely affected arm after stroke: a single-blinded randomized trial in two centers. *Stroke* 2005; 36: 1960–6.
- Huang YZ, Edwards MJ, Rounis E, Bhatia KP, Rothwell JC. Theta burst stimulation of the human motor cortex. *Neuron* 2005; 45: 201–6.
- Hummel F, Celnik P, Giraux P, Floel A, Wu WH, Gerloff C, et al. Effects of non-invasive cortical stimulation on skilled motor function in chronic stroke. *Brain* 2005; 128: 490–9.
- Hummel FC, Cohen LG. Non-invasive brain stimulation: a new strategy to improve neurorehabilitation after stroke? *Lancet Neurol* 2006; 5: 708–12.
- Jang SH, Cho SH, Kim YH, Han BS, Byun WM, Son SM, et al. Diffusion anisotropy in the early stages of stroke can predict motor outcome. *Restor Neurol Neurosci* 2005; 23: 11–7.
- Johansen-Berg H, Dawes H, Guy C, Smith SM, Wade DT, Matthews PM. Correlation between motor improvements and altered fMRI activity after rehabilitative therapy. *Brain* 2002a; 125: 2731–42.
- Johansen-Berg H, Rushworth MF, Bogdanovic MD, Kischka U, Wimalaratna S, Matthews PM. The role of ipsilateral premotor cortex in hand movement after stroke. *Proc Natl Acad Sci USA* 2002b; 99: 14518–23.
- Khedr EM, Ahmed MA, Fathy N, Rothwell JC. Therapeutic trial of repetitive transcranial magnetic stimulation after acute ischemic stroke. *Neurology* 2005; 65: 466–8.
- Kobayashi M, Pascual-Leone A. Transcranial magnetic stimulation in neurology. *Lancet Neurol* 2003; 2: 145–56.
- Konishi J, Yamada K, Kizu O, Ito H, Sugimura K, Yoshikawa K, et al. MR tractography for the evaluation of functional recovery from lenticulostriate infarcts. *Neurology* 2005; 64: 108–13.
- Koski L, Mernar TJ, Dobkin BH. Immediate and long-term changes in corticomotor output in response to rehabilitation: correlation with functional improvements in chronic stroke. *Neurorehabil Neural Repair* 2004; 18: 230–49.
- Kunimatsu A, Aoki S, Masutani Y, Abe O, Mori H, Ohtomo K. Three-dimensional white matter tractography by diffusion tensor imaging in ischaemic stroke involving the corticospinal tract. *Neuroradiology* 2003; 45: 532–5.
- Le Bihan D, Mangin JF, Poupon C, Clark CA, Pappata S, Molko N, et al. Diffusion tensor imaging: concepts and applications. *J Magn Reson Imaging* 2001; 13: 534–46.
- Lee JS, Han MK, Kim SH, Kwon OK, Kim JH. Fiber tracking by diffusion tensor imaging in corticospinal tract stroke: topographical correlation with clinical symptoms. *Neuroimage* 2005; 26: 771–6.
- Lotze M, Markert J, Sauseng P, Hoppe J, Plewnia C, Gerloff C. The role of multiple contralesional motor areas for complex hand movements after internal capsular lesion. *J Neurosci* 2006; 26: 6096–102.
- Loubinoux I, Carel C, Pariente J, Dechaumont S, Albuher JF, Marque P, et al. Correlation between cerebral reorganization and motor recovery after subcortical infarcts. *Neuroimage* 2003; 20: 2166–80.
- Mansur CG, Fregni F, Boggio PS, Riberto M, Gallucci-Neto J, Santos CM, et al. A sham stimulation-controlled trial of rTMS of the unaffected hemisphere in stroke patients. *Neurology* 2005; 64: 1802–4.
- Marshall RS, Perera GM, Lazar RM, Krakauer JW, Constantine RC, DeLaPaz RL. Evolution of cortical activation during recovery from corticospinal tract infarction. *Stroke* 2000; 31: 656–61.
- Mori S, van Zijl PC. Fiber tracking: principles and strategies—a technical review. *NMR Biomed* 2002; 15: 468–80.
- Mori S, Wakana S, van Zijl PC, Nagae-Poetscher LM. MRI atlas of human white matter. Amsterdam: Elsevier; 2005.
- Mukherjee P. Diffusion tensor imaging and fiber tractography in acute stroke. *Neuroimaging Clin N Am* 2005; 15: 655–65.
- Murase N, Duque J, Mazzocchio R, Cohen LG. Influence of interhemispheric interactions on motor function in chronic stroke. *Ann Neurol* 2004; 55: 400–9.
- Nelles G. Cortical reorganization—effects of intensive therapy. *Restor Neurol Neurosci* 2004; 22: 239–44.
- Newton JM, Sunderland A, Gowland PA. fMRI signal decreases in ipsilateral primary motor cortex during unilateral hand movements are related to duration and side of movement. *Neuroimage* 2005; 24: 1080–7.
- Pennisi G, Rapisarda G, Bella R, Calabrese V, Maertens De Noordhout A, Delwaide PJ. Absence of response to early transcranial magnetic stimulation in ischemic stroke patients: prognostic value for hand motor recovery. *Stroke* 1999; 30: 2666–70.
- Rao SM, Binder JR, Bandettini PA, Hammeke TA, Yetkin FZ, Jesmanowicz A, et al. Functional magnetic resonance imaging of complex human movements. *Neurology* 1993; 43: 2311–8.
- Rapisarda G, Bastings E, de Noordhout AM, Pennisi G, Delwaide PJ. Can motor recovery in stroke patients be predicted by early transcranial magnetic stimulation? *Stroke* 1996; 27: 2191–6.
- Rossini PM, Pauri F. Neuromagnetic integrated methods tracking human brain mechanisms of sensorimotor areas ‘plastic’ reorganisation. *Brain Res Rev* 2000; 33: 131–54.
- Rossini PM, Barker AT, Berardelli A, Caramia MD, Caruso G, Cracco RQ, et al. Non-invasive electrical and magnetic stimulation of the brain, spinal cord and roots: basic principles and procedures for routine clinical application. Report of an IFCN committee. *Electroencephalogr Clin Neurophysiol* 1994; 91: 79–92.
- Rossini PM, Calautti C, Pauri F, Baron JC. Post-stroke plastic reorganisation in the adult brain. *Lancet Neurol* 2003; 2: 493–502.
- Schmithorst VJ, Wilke M. Differences in white matter architecture between musicians and non-musicians: a diffusion tensor imaging study. *Neurosci Lett* 2002; 321: 57–60.
- Serrien DJ, Strens LH, Cassidy MJ, Thompson AJ, Brown P. Functional significance of the ipsilateral hemisphere during movement of the affected hand after stroke. *Exp Neurol* 2004; 190: 425–32.
- Shimizu T, Hosaki A, Hino T, Sato M, Komori T, Hirai S, et al. Motor cortical disinhibition in the unaffected hemisphere after unilateral cortical stroke. *Brain* 2002; 125: 1896–907.
- Smith AL, Staines WR. Cortical adaptations and motor performance improvements associated with short-term bimanual training. *Brain Res* 2006; 1071: 165–74.
- Sotak CH. The role of diffusion tensor imaging in the evaluation of ischemic brain injury—a review. *NMR Biomed* 2002; 15: 561–9.

- Stefan K, Kunesch E, Cohen LG, Benecke R, Classen J. Induction of plasticity in the human motor cortex by paired associative stimulation. *Brain* 2000; 123: 572–84.
- Stejskal EO, Tanner JE. Spin diffusion measurements: spin echoes in the presence of a time-dependent field gradient. *J Chem Phys* 1965; 42: 288–92.
- Stinear JW, Byblow WD. The contribution of cervical propriospinal premotoneurons in recovering hemiparetic stroke patients. *J Clin Neurophysiol* 2004a; 21: 426–34.
- Stinear JW, Byblow WD. Rhythmic bilateral movement training modulates corticomotor excitability and enhances upper limb motricity poststroke: a pilot study. *J Clin Neurophysiol* 2004b; 21: 124–31.
- Takeuchi N, Chuma T, Matsuo Y, Watanabe I, Ikoma K. Repetitive transcranial magnetic stimulation of contralesional primary motor cortex improves hand function after stroke. *Stroke* 2005; 36: 2681–6.
- Tallesi P, Greenwood RJ, Rothwell JC. Arm function after stroke: neurophysiological correlates and recovery mechanisms assessed by transcranial magnetic stimulation. *Clin Neurophysiol* 2006; 117: 1641–59.
- Taub E, Uswatte G, King DK, Morris D, Crago JE, Chatterjee A. A placebo-controlled trial of constraint-induced movement therapy for upper extremity after stroke. *Stroke* 2006; 37: 1045–9.
- Thomalla G, Glauche V, Koch MA, Beaulieu C, Weiller C, Rother J. Diffusion tensor imaging detects early Wallerian degeneration of the pyramidal tract after ischemic stroke. *Neuroimage* 2004; 22: 1767–74.
- Thomalla G, Glauche V, Weiller C, Rother J. Time course of wallerian degeneration after ischaemic stroke revealed by diffusion tensor imaging. *J Neurol Neurosurg Psychiatry* 2005; 76: 266–8.
- Traversa R, Cicinelli P, Oliveri M, Giuseppina Palmieri M, Filippi MM, Pasqualetti P, *et al.* Neurophysiological follow-up of motor cortical output in stroke patients. *Clin Neurophysiol* 2000; 111: 1695–703.
- Trompetto C, Assini A, Buccolieri A, Marchese R, Abbruzzese G. Motor recovery following stroke: a transcranial magnetic stimulation study. *Clin Neurophysiol* 2000; 111: 1860–7.
- van der Lee JH. Constraint-induced movement therapy: some thoughts about theories and evidence. *J Rehabil Med* 2003; 41–5.
- Ward NS. Functional reorganization of the cerebral motor system after stroke. *Curr Opin Neurol* 2004; 17: 725–30.
- Ward NS, Brown MM, Thompson AJ, Frackowiak RS. Neural correlates of motor recovery after stroke: a longitudinal fMRI study. *Brain* 2003a; 126: 2476–96.
- Ward NS, Brown MM, Thompson AJ, Frackowiak RS. Neural correlates of outcome after stroke: a cross-sectional fMRI study. *Brain* 2003b; 126: 1430–48.
- Ward NS, Newton JM, Swayne OB, Lee L, Thompson AJ, Greenwood RJ, *et al.* Motor system activation after subcortical stroke depends on corticospinal system integrity. *Brain* 2006; 129: 809–19.
- Watanabe T, Honda Y, Fujii Y, Koyama M, Matsuzawa H, Tanaka R. Three-dimensional anisotropy contrast magnetic resonance axonography to predict the prognosis for motor function in patients suffering from stroke. *J Neurosurg* 2001; 94: 955–60.
- Werring DJ, Toosy AT, Clark CA, Parker GJ, Barker GJ, Miller DH, *et al.* Diffusion tensor imaging can detect and quantify corticospinal tract degeneration after stroke. *J Neurol Neurosurg Psychiatry* 2000; 69: 269–72.
- Yamada K, Ito H, Nakamura H, Kizu O, Akada W, Kubota T, *et al.* Stroke patients' evolving symptoms assessed by tractography. *J Magn Reson Imaging* 2004; 20: 923–9.
- Ziemann U, Meintzschel F, Korchounov A, Ilic TV. Pharmacological modulation of plasticity in the human motor cortex. *Neurorehabil Neural Repair* 2006; 20: 243–51.