

# Genes in Thoracic Aortic Aneurysms and Dissections – Do they Matter?

## Translation and Integration of Research and Modern Genetic Techniques into Daily Clinical Practice

Julie De Backer, MD, PhD<sup>1,2\*</sup>, Marjolijn Renard, PhD<sup>1</sup>, Laurence Campens, MD<sup>1,2</sup>, Katrien François, MD, PhD<sup>3</sup>, Bert Callewaert, MD, PhD<sup>1</sup>, Paul Coucke, PhD<sup>1</sup>, Anne De Paepe, MD, PhD<sup>1</sup>

<sup>1</sup>Centre for Medical Genetics, University Hospital Ghent, Ghent, Belgium; <sup>2</sup>Department of Cardiology, University Hospital Ghent, Ghent, Belgium; and <sup>3</sup>Department of Cardiovascular Surgery, University Hospital Ghent, Ghent, Belgium

### Abstract

**Since the identification of the fibrillin-1 gene as the causal gene for Marfan syndrome, our knowledge of molecular genetics and the applicability of genetic testing in clinical practice have expanded dramatically. Several new syndromes related to thoracic aortic aneurysms and dissections (TAAD) have been described and the list of underlying genes in syndromal and nonsyndromal TAAD already includes more than 10 different genes and is rapidly expanding. Based on this knowledge, our insights into the underlying pathophysiology of TAAD have improved significantly, and new opportunities for targeted treatment have emerged. Clinicians involved in the care of TAAD patients require a basic knowledge of the disease entities and need to be informed on the applicability of genetic testing in their patients and families. Gene-tailored treatment and management is indeed no science fiction anymore and should now be considered as part of good clinical practice. We provide a systematic overview of genetic TAAD entities and practical recommendations for genetic testing and patient management.**

Copyright © 2013 Science International Corp.

### Key Words

**Thoracic aortic aneurysms and dissections · Molecular genetic testing · Aneurysm syndrome**

### Introduction

Over the past decade, expanding knowledge of the genetic basis of Thoracic Aortic Aneurysms and Dissections (TAAD) significantly improved our understanding of the pathogenesis of the disease and improved our ability for risk stratification and medical guidance of patients and their families. Strategies for molecular genetic testing have reached a hinge point with the introduction in routine diagnostics of high-throughput next generation sequencing techniques. It is therefore extremely important that clinicians in the field know the indications and limitations of molecular genetic testing. These will be reviewed in this manuscript.

### *Etiology and Classification*

The etiology of TAAD is complex and heterogeneous. Degenerative aortic disease related to classical cardiovascular risk factors such as smoking, arterial hypertension, and hyperlipidemia are the main cause of TAAD in older patients. In younger patients with no risk factors, other causes, including genetic disease, should be considered. Genetic aneurysmal disease



can be categorized in three main groups: (i) inherited syndromes predisposing to early onset TAAD (<5% of all TAAD) such as Marfan syndrome (MFS), Loeys-Dietz syndrome (LDS), and Aneurysm-Osteoarthritis syndrome [1–3]; (ii) familial forms of TAAD (FTAAD - 20% of all TAAD) including patients with confirmed disease in first-degree relatives and evidence for an autosomal dominant inheritance pattern; these patients may sometimes present with associated cardiovascular lesions such as bicuspid aortic valve (BAV), patent ductus arteriosus (PDA), or cerebrovascular disease [4–6]; and (iii) isolated or sporadic forms of TAAD (80%) including patients with no family history or clinical features of a syndromic TAAD disorder. The latter two categories are the so-called nonsyndromic forms of TAAD as opposed to the syndromic forms of the first category.

**Table 1** provides an overview of syndromic and nonsyndromic forms of TAAD with their corresponding genes and clinical features. Discriminative features are in bold.

The paradigm disease for genetically determined syndromic TAAD is Marfan syndrome (MFS), caused by mutations in the fibrillin-1 gene (*FBN1*). The diagnosis of MFS is based on the identification of clinical manifestations and may be supplemented with *FBN1* gene sequencing. Cardinal manifestations include dilatation of the aortic sinus, lens luxation, and a combination of additional features defined by the “systemic score.” Dilatation of more distal parts of the aorta occurs in a minority of MFS patients [7–9]; patients who underwent previous surgery of the ascending aorta seem at increased risk. A recent study from Mimoun and colleagues demonstrated that dissection in the descending part of the aorta may occur whatever the diameter of the ascending aorta [10].

In 2004, Mizuguchi et al. identified mutations in the Transforming Growth Factor Beta Receptor 2 gene (*TGFBR2*) in a large family and four additional probands presenting with aortic dilatation and variable additional clinical features reminiscent of a connective tissue disorder, referred to as Marfan syndrome type2 [11]. In 2005, Loeys et al. published their findings on a large series of patients presenting with widespread aggressive aortic disease with rapid growth and early dissections. They observed an increased prevalence of dysmorphic features including hypertelorism and cleft palate/bifid uvula. Patients harbored mutations in either the *TGFBR1* or *TGFBR2* gene and the disorder was

named after the authors (Loeys-Dietz syndrome, LDS) [12]. Patients with LDS may also present with arterial tortuosity/aneurysms/dissections outside the aorta necessitating extensive vascular imaging at regular time intervals. With the identification of mutations in genes involved in the TGF $\beta$  pathway, a new era with regards to our understanding of the pathophysiology and treatment of TAAD emerged. Other gene mutations have been identified including the *SMAD3* gene causing Aneurysm-Osteoarthritis syndrome and mutations in the TGF $\beta$  ligand. In view of the important clinical overlap between these disorders, the term “TGF $\beta$  associated vasculopathies” may be preferred over individual syndrome names.

The genetic background of nonsyndromic TAAD is even more complex and heterogeneous. Genes involved in syndromic forms may also be encountered in patients with isolated aortic disease, emphasizing the fact that the clinical spectrum of these disorders is very broad. Other genes involved in nonsyndromic TAAD include the *ACTA2* gene (encoding smooth muscle  $\alpha$ -actin), the *MYLK* gene, encoding myosin light chain kinase and the *MYH 11* gene encoding the myosine heavy chain subunit [4,13–15]. The proteins encoded by these genes are involved in the vascular smooth muscle cell apparatus. Patients present with TAAD, sometimes in association with other features such as livedo reticularis, iris flocculi, and cardiovascular disease in the case of *ACTA2*, patent ductus arteriosus in the case of *MYH11*, and gastro-intestinal disease in the case of *MYLK*.

Establishing a correct diagnosis of TAAD in an individual patient primarily requires detailed clinical evaluation of the proband and family members (see below). It should be noted, however, that substantial clinical overlap exists between these subgroups. Therefore, additional molecular genetic testing may be helpful and sometimes even required for confirmation of the specific diagnosis.

#### *Strategy for Clinical Evaluation and Genetic Testing*

The absolute prerequisite for further clinical/genetic investigations in TAAD patients is a correct diagnosis of the aneurysm itself, based on careful measurement of the diameter of the aorta according to appropriate guidelines [35]. The measurements obtained need to be correlated to values in normal subjects matched for age, body surface area, and gender [36]. To correlate with normal values, nomograms

**Table 1. Schematic Overview of Syndromic and Nonsyndromic TAA (Thoracic Aortic Aneurysm and Dissections)**

Disorder	Gene(s)	Main Cardiovascular Features	Additional Clinical Features
Marfan (1, 16, 17)	<i>FBN1</i>	<b>Syndromic TAA</b> Aortic Root Aneurysm, Aortic Dissection, Mitral Valve Prolapse, Main Pulmonary Artery Dilatation, Left Ventricular Dysfunction	<b>Lens luxation</b> , skeletal features (arachnodactyilia, pectus deformity, scoliosis, flat feet, increased armspan, dolichocephalia)
Ehlers-Danlos (18–20) (vascular, valvular)	<i>COL3A1</i> , <i>COL1A2</i>	Arterial Rupture and dissection without preceding dilatation/aneurysm, severe valvular insufficiency	<b>Thin, translucent skin, dystrophic scars, facial characteristics</b> (Madonna face, thin lips, deep set eyes)
TGFβ-related vasculopathies	<i>TGFBR1/2</i>	Aortic Root Aneurysm, Aortic Dissection, Arterial Aneurysms and Dissections, Arterial Tortuosity, Mitral Valve Prolapse, Congenital Cardiac Malformations*	<b>Bifid uvula/cleft palate, hypertelorism</b> , pectus abnormalities, scoliosis, club feet
Loeys-Dietz (2, 12)	<i>SMAD3</i>	Aortic Root Aneurysm, Aortic Dissection, Arterial Aneurysms and Dissections, Arterial Tortuosity, Mitral Valve Prolapse, Congenital Cardiac Malformations*	<b>Osteoarthritis</b> , soft skin, flat feet, scoliosis, recurrent hernia's, hypertelorism, pectus abnormalities
Aneurysm-Osteoarthritis (21–23)	<i>TGFβ2</i> (24, 25)	Aortic Root Aneurysm, Aortic Dissection, Arterial Aneurysms and Dissections, Arterial Tortuosity, <b>Mitral Valve Prolapse</b> , Congenital Cardiac Malformations*	Club feet; soft translucent skin
Shprintzen-Goldberg syndrome (26, 27)	<i>SKI</i>	Mild aortic root dilatation, mitral valve prolapse	
Arterial Tortuosity Syndrome (28)	<i>SLC2A10</i>	Arterial Tortuosity, Arterial Stenoses and Aneurysms	<b>Craniosynostosis, distinctive craniofacial features</b> , skeletal changes, neurologic disability
Cutis Laxa Syndromes (29)	<i>FBLN4</i>	Aortic Root Aneurysm, Arterial Tortuosity	Hyperlax skin and -joints, mild emphysema
Familial thoracic aortic aneurysm syndrome (FTAA) (30–32)	<i>TGFBR1/2</i> (3–5%) <i>ACTA2</i> (10–14%)	<b>Non Syndromic TAA</b> Thoracic Aortic Aneurysm/Dissection Thoracic Aortic Aneurysm/Dissection, cerebrovascular disease, coronary artery disease	Lack of syndromal features Lack of Marfanoid skeletal features, livedo reticularis, iris flocculi, coronary artery/cerebrovascular disease) Gastro-intestinal abnormalities
FTAA with bicuspid aortic valve (BAV) (33, 34)	<i>MYLK</i> <i>SMAD3</i> (2%) <i>TGFβ2</i> <i>ACTA2</i>	Thoracic Aortic Aneurysm/Dissection Intracranial and other arterial aneurysms Mitral valve prolapse	Lack of Marfanoid skeletal features, livedo reticularis, iris flocculi
FTAA with patent ductus arteriosus (PDA) (6)	<i>NOTCH1</i> <i>MYH11</i>	Highly calcified Valve Patent ductus arteriosus	

Overview of syndromic and nonsyndromic forms of TAA with their corresponding genes and clinical features. Discriminative features are in bold.

can be used or z-scores can be calculated, the latter method being more convenient for reporting. Aortic dilatation is confirmed if the z-score exceeds 2, corresponding to an observed value  $>1.96$  standard deviations above the predicted value for age, gender, and body size. In children, growth needs to be taken into account and z-scores  $>3$  have been suggested [37]. Further investigations will depend on the age and cardiovascular risk profile of the patient.

Consideration of a genetic entity is especially of interest in young subjects with no additional risk factors. Detailed family history taking, including pedigree drawing and clinical assessment of first degree relatives, is required to differentiate between familial and isolated forms of TAA. Next, careful multidisciplinary clinical evaluation of the proband is undertaken, which will help us in the identification of specific syndromes as reported in Table 1.

Since TAA is a genetically heterogeneous disease with important clinical overlap between the known genetic entities, there is a clear need for simultaneous testing of multiple genes. Until recently, strategies for genetic testing were limited as only one gene at the time could be analyzed, and both the time required as well as the costs for screening of multiple genes were substantial. The need for high-throughput techniques enabling simultaneous testing of several genes was met by the recent development and progress made in the field of Next Generation Sequencing. Previously, our Center reported a mutation detection strategy using massive parallel sequencing of the *FBN1* and *TGFBR1* and *-2* genes for the molecular diagnosis of MFS and LDS [38]. In a next stage, we implemented a novel screening strategy that allows simultaneous sequencing of 16 TAA-associated genes. To this purpose, two complementary panels of genes were designed, of which all coding regions and flanking sequences can be amplified in a fully automated fashion followed by sequencing on an Illumina MiSeq sequencer (Illumina, San Diego, California). The first gene panel comprises *FBN1*, *TGFBR1/2*, *SMAD3*, *TGFB2*, *ACTA2*, and *COL3A1*. The second gene panel comprises *MYH11*, *MYLK*, *SLC2A10*, *NOTCH1*, *FBN2*, *ADAMTS10*, *FBLN4*, *FLNA*, and *ELN*.

Correct interpretation of the results obtained by molecular genetic testing requires basic knowledge of these different genes and clinical entities - all the more since medical and surgical management may differ according to the underlying diagnosis.

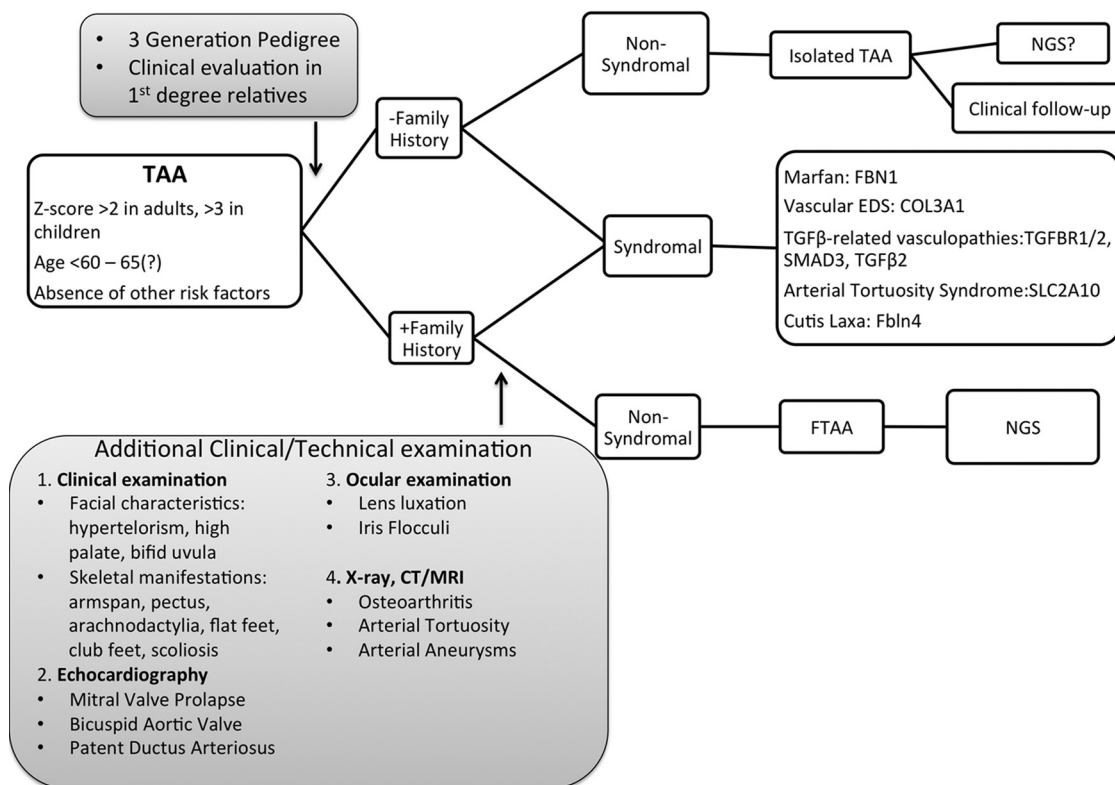
Importantly, the simultaneous sequencing of multiple TAA-associated genes is not always justified. In patients presenting with a thoracic aortic aneurysm in combination with lens luxation for instance, Marfan syndrome is very likely and molecular genetics can be restricted to the *FBN1* gene. Or, from a cardiovascular perspective, extensive vascular disease such as aortic aneurysms at different locations and/or involvement of side branches makes a diagnosis of Marfan syndrome much less likely and in these cases, TGF $\beta$ -associated disease should be excluded first. A flow chart illustrating the diagnostic process (clinical and genetic evaluation) is provided in Figure 1.

#### *Genes and Pathogenesis*

In addition to its usefulness in a diagnostic setting, molecular genetics have been very useful in unraveling the complex pathogenesis of TAA formation. One of the most inspiring findings over recent years was the observation of the involvement of the Transforming Growth Factor  $\beta$  (TGF $\beta$ ) pathway in several connective tissue disorders. The TGF $\beta$  superfamily consists of a number of cytokines that regulate diverse cellular functions, including proliferation, differentiation, and synthesis of a wide array of gene products.

The first heritable connective tissue disorder linked to the TGF $\beta$  pathway was Marfan syndrome (MFS). The underlying pathogenesis of aneurysm formation in MFS was initially considered to be a consequence of inherent structural weakness of the tissues due to structurally abnormal fibrillin-1 fibers. Prospects for causal treatment were pessimistic in this view since this would require a means to alter the structural composition of inherently weak tissues.

Fortunately, recent developments have changed this insight and it is now recognized that fibrillin-1 containing microfibrils also play an important functional role in the complex TGF $\beta$  pathway. Although it is clear that the TGF $\beta$  pathway plays a role in the pathogenesis of MFS, the mechanism of TGF $\beta$  activation remains controversial. On the one hand, it has been suggested that TGF $\beta$  is activated as a consequence of improper sequestration of the latent TGF $\beta$  complex, which is the result of a reduction of fibrillin-1 below a certain threshold [39]. On the other hand, Charbonneau and colleagues demonstrated that an *Fbn1* mouse in which the latent TGF $\beta$  binding protein site (LTBPs) was deleted (*Fbn1*<sup>H1 $\Delta$</sup> ) did not present



**Figure 1.** Flow chart illustrating the diagnostic process (clinical and genetic evaluation). NGS: Next Generation Sequencing.

features of MFS [40]. Hence, instead of reduced TGFβ sequestration, mutant microfibrils probably influence TGFβ activation in a different way. Sakai and coworkers demonstrated that fibrillin-1 was homologous to the family of LTBP which serve to hold TGFβ in an inactive complex in various tissues, including the extracellular matrix [41]. Fibrillin-1 binds TGFβ and LTBP [41–44].

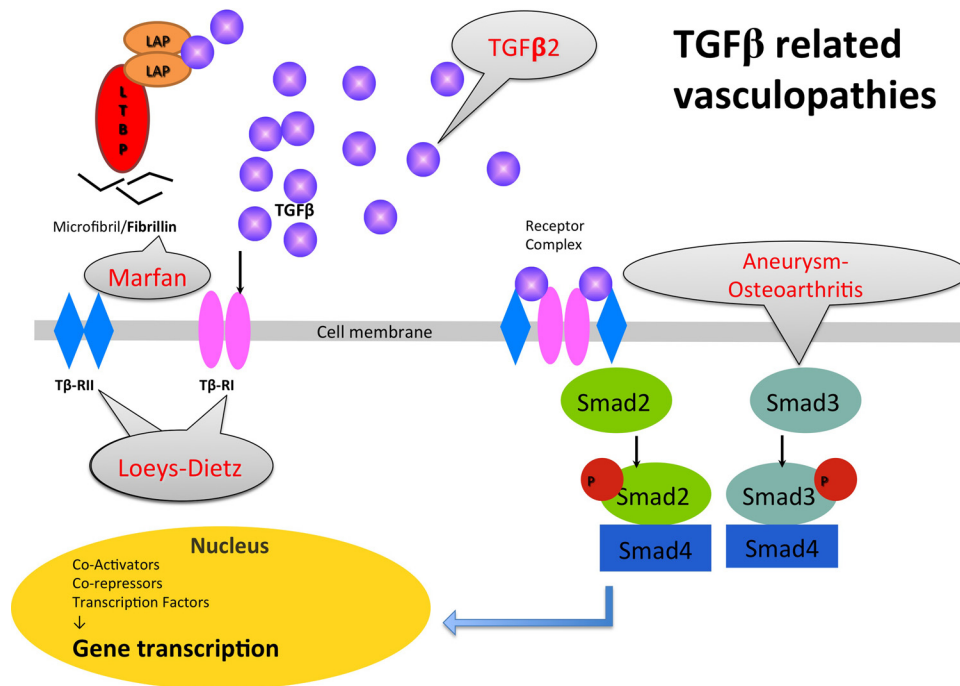
Since the large latent complex binds TGFβ, abnormal fibrillin-1 fibers will lead to failed matrix sequestration of the latent TGFβ complex and hence to increased amounts of active TGFβ, which is in turn at the basis of the pleiotropic manifestations in MFS [39]. Indeed, increased TGFβ signaling has been demonstrated in aortic tissue samples and in mitral valve tissue from patients with MFS. These findings have opened new perspectives for treatment through inhibition of TGFβ-signaling (see below).

Additional evidence for the involvement of the TGFβ pathway in aneurismal disease came from the findings that mutations in several genes that encode different components of the pathway result in aneurysm conditions that have undeniable clinical overlap

with MFS. Initially, these disorders were given names, the first one being the Loey-Dietz syndrome (LDS), caused by mutations in the TGFBR1 and TGFBR2 genes. In 2011, mutations in the SMAD3 gene were identified in patients with a very similar phenotype but also presenting with osteoarthritis, hence the name “Aneurysm-Osteoarthritis syndrome (AOS).” Soon thereafter a family with juvenile polyposis associated with aortopathy and mitral valve disease caused by SMAD4 mutations was reported [45]; and finally, mutations in the TGFβ-2 ligand were very recently identified in several families displaying a very similar phenotype [25,46,47]. It is clear that these disorders are all part of a broad spectrum and it may be more convenient to group them under the term “TGFβ-related vasculopathies.” Figure 2 provides a schematic and abbreviated overview of the TGFβ signalling pathway with indication of aneurismal diseases linked to it.

Increased TGFβ signaling has also been reported in human aortic specimens of patients with familial TAAD and underlying ACTA2 or MYH11 mutations [48]. The exact link is not yet fully understood but links





**Figure 2.** Provides a schematic and abbreviated overview of the TGFβ signaling pathway with indication of aneurismal diseases linked to it. The TGFβ pathway and related vasculopathies. Following its release from the Extracellular Matrix, TGFβ binds to its type II cell surface receptor (TβRII), which recruits and phosphorylates the type I receptor (TβRI). TβRI then recruits and phosphorylates SMAD2 and/or SMAD3. These P-SMADs then bind to the common SMAD (co-SMAD) SMAD4 to form a heterodimeric complex. This complex enters the cell nucleus where it acts as a transcription factor for various TGFβ-dependent genes, such as connective tissue growth factor (CTGF), plasminogen activator inhibitor-1 (PAI-1) and multiple collagens.

between the contractile cytoskeleton and many aspects of the TGFβ signaling pathway have been established, including trafficking and activity of TGFβ receptors and signaling effectors [49,50].

#### *Gene-Tailored Follow-up and Management in TAAD*

A schematic overview of the medical management is provided in [Table 2](#).

#### *Imaging Studies*

Confirmation of the exact diagnosis in the proband facilitates the set-up of a personalized strategy for follow-up and treatment in the patient and his/her family. Since the clinical manifestation of the disease is age dependent and may progress subclinically until later in life, lifelong follow-up is required in all mutation-carriers, even if aortic diameters are normal on repeated measurements. The frequency and modality for follow-up and treatment may differ according to the underlying diagnosis as summarized in [Table 2](#). Importantly, clinical monitoring and follow-up with

cardiovascular imaging is also warranted in family members of TAAD patients in whom no causal mutation was identified since familial clustering is observed in more than 20% of TAAD cases [51,52].

Echocardiography is the primary imaging tool for evaluation and follow-up of the diameters of the aortic root and ascending aorta. CT or MRI can be used in case of insufficient visualization of the ascending aorta by echocardiography. The imaging study should be repeated in all patients six months after the initial diagnosis to assess evolutionary changes. Further follow-up is guided by the diameter, evolution, underlying diagnosis, and family history. Stable diameters <45 mm in patients with Marfan syndrome or isolated TAA and no family history for dissection require yearly follow-up. Biannual controls are recommended in all other cases.

On initial diagnosis, imaging of the entire aorta and side branches (“head-to-pelvis” study) should be performed in order to detect aneurysms at other sites

**Table 2.** Overview of Suggested Treatment and Follow-up in TAAD

Disorder	Treatment	Follow-up
Marfan (1, 16, 17)	<p>β-blocking agents, losartan?</p> <p>surgery when AoD &gt;50 mm or &gt;46 mm in case of familial history of dissection or rapid growth (&gt;2 mm/y) or severe AR or MR</p> <p>Celiprolol</p> <p>Surgery uncertain</p> <p>No trials yet — adopt medical treatment from Marfan syndrome</p>	<p>echocardiography q1y when diameter &lt;45 mm q6m in all other cases</p> <p>MRAq5y when aortic diameters outside the sinuses of Valsalva are normal, MRAq1y in all other cases</p> <p>Unclear (dissection/rupture often at normal diameters)</p> <p>Echocardiography q6mo</p>
Ehlers-Danlos (18-20) (vascular, valvular)		
TGFβ-related vasculopathies	<p>Loeys-Dietz (2, 12)</p> <p>Aneurysm-Osteoarthritis (21–23)</p> <p>TGFβ2 (24, 25)</p>	
Arterial Tortuosity Syndrome (28)		
Cutis Laxa Syndromes (29)		
Familial thoracic aortic aneurysm syndrome (FTAA) (30–32)	<p>Surgery when AoD &gt;43-45 mm</p> <p>No trials yet — adopt from Marfan syndrome</p>	<p>CT/MRI head to pelvis q6mo-1y</p> <p>Same as in Marfan syndrome</p> <p>Consider coronary/cerebrovascular imaging in ACTA2 mutation carriers</p> <p>Echocardiography q6mo-1y (also related to valvular function)</p> <p>Same as in Marfan syndrome</p>
FTAA with bicuspid aortic valve (33, 34)	No trials yet — adopt from Marfan syndrome	
FTAA with patent ductus arteriosus (6)	No trials yet — adopt from Marfan syndrome	

AoD: Aortic Root Diameter; AR: Aortic Regurgitation; MR: Mitral Regurgitation; MRA: Magnetic Resonance Angiography.

and/or arterial tortuosity. Regular extensive vascular imaging from head to pelvis is recommended in patients with a *TGFBR1/2*, *SMAD3*, and *TGF $\beta$ 2* mutation and for rare diseases such as cutis laxa and arterial tortuosity syndrome (ATS). In vascular Ehlers-Danlos syndrome (EDS) where dissections often occur at normal diameters, the modality and frequency of vascular imaging is debatable. Evaluation for coronary artery and cerebrovascular disease can be considered in patients with an *ACTA2* mutation [53].

#### Medical Treatment

The initial medical approach of TAAAD patients should include reduction of cardiovascular risk factors, such as blood pressure control, smoking cessation, and optimization of the lipid profile. Central stimulating drugs, such as cocaine, amphetamine and derivatives are known triggers for aortic dissection and should therefore be avoided [54,55].

Medical treatment with a  $\beta$ -blocking agent in MFS reduces the progression of aortic dilatation in most patients through reduction of wall shear stress in the aorta and is used as a standard therapy in MFS patients [56]. As already mentioned, it has been clearly demonstrated that the TGF $\beta$  pathway plays an important role in aneurysmal disease. This knowledge has led the search for strategies to interfere with TGF $\beta$  signaling. From studies in nephrology, it was documented that losartan, an angiotensin receptor blocking agent, inhibits TGF $\beta$  signaling. An initial experiment with TGF $\beta$  neutralizing antibodies in a mouse model for MFS showed a dramatic decrease in aortic root growth as well as restoration of aortic wall architecture [57]. A trial with losartan in MFS mice showed significant rescue of aortic root aneurysm progression as well as aortic wall architecture, compared to treatment with either placebo or propranolol [57]. A subsequent small study in children with severe MFS showed similar very promising results [58]. Large-scale trials in MFS patients are currently underway [59] and need to be awaited prior to large-scale prescription.

In patients with vascular EDS, reduction of fatal vascular events was observed with treatment with celiprolol, a  $\beta$ -blocker with  $\beta$ 2 mimetic action [60]. The possible role of medical treatment in other TAAAD diseases is not well studied but pragmatically, treatment as for MFS is adopted.

#### Surgery

It is beyond any doubt that elective surgical aortic root replacement leads to better survival in patients with genetic aortic disease. Modalities for surgical intervention are beyond the scope of this contribution. We do want to spend some words on the timing of surgery taking the underlying diagnosis into account.

It has been demonstrated that the risk for dissection or rupture for thoracic aortic aneurysms of non-degenerative origin rises at lower diameters when compared to degenerative aortic disease. Accordingly, the threshold for surgery of the aortic root is lower than the conventional 55 mm. Indeed if conforming to the European Society of Cardiology guidelines on Grown-up Congenital Heart Disease, the conventional surgical indication for MFS is an aortic diameter-measured at the sinuses of Valsalva at 50mm or more. This threshold is reduced to 46 mm in the case of a positive family history of aortic dissection or rapid growth of the aorta ( $>2$  mm/yr). When there is a desire of pregnancy, aortic repair at 45 mm is recommended [61]. In certain other syndromic and nonsyndromic TAAAD entities such as LDS or AOS, aortic dissection can occur at smaller diameters, therefore requiring an adjusted treatment policy. Results of surgical intervention in LDS and AOS are good [3,62]. Taking these data into account, the current guidelines of the American College of Cardiology recommend prophylactic surgery in the following cases [63,64]: (i) patients with a mutation in *TGFBR1* or *TGFBR2* (as well as patients with LDS as familial TAAAD), when the diameter of the ascending aorta reaches 42mm measured by echocardiography or 44–46 mm on CT or MR imaging; (ii) patients with familial TAAAD and/or mutation in *MYH11* or *ACTA2*, when the diameter of the ascending aorta measures between 45 and 50 mm; (iii) patients with familial TAAAD with relatives with an aortic dissection at minimal dilatation of the thoracic aorta ( $<50$  mm); (iv) for all other TAAAD patients when the ascending aorta or aortic root reaches a diameter of 50 mm, in case of rapid growth of the aorta ( $\geq 5$  mm/y) and/or in the presence of severe aortic stenosis or regurgitation. Patients with a mutation in the MYLK gene can have an aortic dissection at small diameters of the aorta, as indicated by the study of Wang et al. [15]. Guidelines regarding the role of prophylactic surgery in this group of patients are lacking. In contrast to patients with a *TGFBR2* mutation, aortic dissection in patients with a *TGFBR1* mutation would



rather occur at larger diameters (>50 mm) [65]. In view of these data, early referral for surgery may be questioned.

## Conclusion

In the current era of improved availability of high-throughput molecular genetic techniques, knowledge of the indications and limitations for these tests in daily clinical practice is increasingly important. In the case of TAAD, additional genetic testing may be helpful for confirmation of the correct diagnosis. Since follow-up and treatment of patients may be adapted according to the underlying condition, clinicians dealing with these patients should acquire

this knowledge. Close collaboration between cardiovascular surgeons, cardiologists, and clinical geneticists is strongly recommended in the care of these patients and families.

## Acknowledgments

Julie De Backer is supported by a grant as Senior Clinical Investigator from the Fund for Scientific Research, Flanders (Belgium). Bert Callewaert is supported as a postdoctoral fellow by the Fund for Scientific Research, Flanders (Belgium). Anne De Paepe is holder of a Methusalem grant from the Flemish government.

### Comment on this Article or Ask a Question

## References

- Judge DP, Dietz HC. Marfan's syndrome. *Lancet*. 2005;366:1965–1976. 10.1016/S0140-6736(05)67789-6
- Loeys BL, Schwarze U, Holm T, Callewaert BL, Thomas GH, Pannu H, et al. Aneurysm syndromes caused by mutations in the TGF-beta receptor. *N Engl J Med*. 2006;355:788–798. 10.1056/NEJMoa055695
- van der Linde D, van de Laar IM, Bertoli-Avella AM, Oldenburg RA, Bekkers JA, Matice-Raso FU, et al. Aggressive cardiovascular phenotype of aneurysms-osteoarthritis syndrome caused by pathogenic SMAD3 variants. *J Am Coll Cardiol*. 2012;60:397–403. 10.1016/j.jacc.2011.12.052
- Guo DC, Papke CL, Tran-Fadulu V, Regalado ES, Avidan N, Johnson RJ, et al. Mutations in smooth muscle alpha-actin (ACTA2) cause coronary artery disease, stroke, and Moyamoya disease, along with thoracic aortic dissection. *Am J Hum Genet*. 2009;84:617–627. 10.1016/j.ajhg.2009.04.007
- Regalado E, Medrek S, Tran-Fadulu V, Guo DC, Pannu H, Golabbakhsh H, et al. Autosomal dominant inheritance of a predisposition to thoracic aortic aneurysms and dissections and intracranial saccular aneurysms. *Am J Med Genet A*. 2011;155A:2125–2130.
- Khau Van Kien P, Wolf JE, Mathieu F, Zhu L, Salve N, Lalonde A, et al. Familial thoracic aortic aneurysm/dissection with patent ductus arteriosus: genetic arguments for a particular pathophysiological entity. *Eur J Hum Genet*. 2004;12:173–180. 10.1038/sj.ejhg.5201119
- Finkbohner R, Johnston D, Crawford ES, Coselli J, Milewicz DM. Marfan syndrome. Long-term survival and complications after aortic aneurysm repair. *Circulation*. 1995;91:728–733. 10.1161/01.CIR.91.3.728
- Nollen GJ, Groenink M, Tijssen JG, Van Der Wall EE, Mulder BJ. Aortic stiffness and diameter predict progressive aortic dilatation in patients with Marfan syndrome. *Eur Heart J*. 2004;25:1146–1152. 10.1016/j.ehj.2004.04.033
- Kawamoto S, Bluemke DA, Traill TA, Zerhouni EA. Thoracoabdominal aorta in Marfan syndrome: MR imaging findings of progression of vasculopathy after surgical repair. *Radiology*. 1997;203:727–732.
- Mimoun L, Detaint D, Hamroun D, Arnoult F, Delorme G, Gautier M, et al. Dissection in Marfan syndrome: the importance of the descending aorta. *Eur Heart J*. 2011;32:443–449. 10.1093/eurheartj/ehq434
- Mizuguchi T, Collod-Beroud G, Akiyama T, Abifadel M, Harada N, Morisaki T, et al. Heterozygous TGFBR2 mutations in Marfan syndrome. *Nat Genet*. 2004;36:855–860. 10.1038/ng1392
- Loeys BL, Chen J, Neptune ER, Judge DP, Podowski M, Holm T, et al. A syndrome of altered cardiovascular, craniofacial, neurocognitive and skeletal development caused by mutations in TGFBR1 or TGFBR2. *Nat Genet*. 2005;37:275–281. 10.1038/ng1511
- Hasham S, Milewicz DM. Familial thoracic aortic aneurysms and dissections. In: Robinson and P Godfrey, ed. *Marfan syndrome: a primer for clinicians and scientists*. New York, NY: Kluwer Academic; 2004.
- Renard M, Callewaert B, Baetens M, Campens L, Macdermot K, Fryns JP, et al. Novel MYH11 and ACTA2 mutations reveal a role for enhanced TGFβ signaling in FTAAD. *Int J Cardiol*. 2013;165:314–321. 10.1016/j.ijcard.2011.08.079
- Wang L, Guo DC, Cao J, Gong L, Kamm KE, Regalado E, et al. Mutations in myosin light chain kinase cause familial aortic dissections. *Am J Hum Genet*. 2010;87:701–707. 10.1016/j.ajhg.2010.10.006
- Loeys BL, Dietz HC, Braverman AC, Callewaert BL, De Backer J, Devreux RB, et al. The revised Ghent nosology for the Marfan syndrome. *J Med Genet*. 2010;47:476–485. 10.1136/jmg.2009.072785
- Dietz HC, Cutting CR, Pyeritz RE, Maslen CL, Sakai LY, Corson GM, et al. Marfan syndrome caused by a recurrent de novo missense mutation in the fibrillin gene. *Nature*. 1991;352:337–339. 10.1038/352337a0
- Pepin M, Schwarze U, Superti-Furga A, Byers PH. Clinical and genetic features of Ehlers-Danlos syndrome type IV, the vascular type. *N Engl J Med*. 2000;342:673–680. 10.1056/NEJM200003093421001
- Malfait F, Symoens S, De Backer J, Hermans-Lé T, Sakalihan N, Lapiere CM, et al. Three arginine to cysteine substitutions in the pro-alpha (I)-collagen chain cause Ehlers-Danlos syndrome with a propensity to arterial rupture in early adulthood. *Hum Mutat*. 2007;28:387–395. 10.1002/humu.20455
- Malfait F, Symoens S, Coucke P, Nunes L, De Almeida S, De Paepe A. Total absence of the alpha2(I) chain of collagen type I causes a rare form of Ehlers-Danlos syndrome with hypermobility and propensity to cardiac valvular problems. *J Med Genet*. 2006;43:e36.
- van de Laar IM, van der Linde D, Oei EH, Bos PK, Bessems JH, Bierma-Zeinstra SM, et al. Phenotypic spectrum of the SMAD3-related

- aneurysms-osteoarthritis syndrome. *J Med Genet.* 2012;49:47–57. 10.1136/jmedgenet-2011-100382
22. van der Linde D, van de Laar IM, Bertoli-Avella AM, Oldenburg RA, Bekkers JA, Matlace-Raso FU, et al. Aggressive cardiovascular phenotype of aneurysms-osteoarthritis syndrome caused by pathogenic SMAD3 variants. *J Am Coll Cardiol.* 2012;60:397–403. 10.1016/j.jacc.2011.12.052
  23. van de Laar IM, Oldenburg RA, Pals G, Roos-Hesselink JW, de Graaf BM, Verhagen JM, et al. Mutations in SMAD3 cause a syndromic form of aortic aneurysms and dissections with early-onset osteoarthritis. *Nat Genet.* 2011;43:121–126. 10.1038/ng.744
  24. Lindsay ME, Schepers D, Bolar NA, Doyle JJ, Gallo E, Fert-Bober J, et al. Loss-of-function mutations in TGF $\beta$ 2 cause a syndromic presentation of thoracic aortic aneurysm. *Nat Genet.* 2012;44:922–927. 10.1038/ng.2349
  25. Boileau C, Guo DC, Hanna N, Regalado ES, Detaint D, Gong L, et al. TGF $\beta$ 2 mutations cause familial thoracic aortic aneurysms and dissections associated with mild systemic features of Marfan syndrome. *Nat Genet.* 2012;44:916–921. 10.1038/ng.2348
  26. ÓCarmignac V, Thevenon J, Adès L, Callewaert B, Julia S, Thauvin-Robinet C, et al. In-frame mutations in exon 1 of SKI cause dominant Shprintzen-Goldberg syndrome. *Am J Hum Genet.* 2012;91:950–957. 10.1016/j.ajhg.2012.10.002
  27. Doyle AJ, Doyle JJ, Bessling SL, Maragh S, Lindsay ME, Schepers D, et al. Mutations in the TGF- $\beta$  repressor SKI cause Shprintzen-Goldberg syndrome with aortic aneurysm. *Nat Genet.* 2012;44:1249–1254. 10.1038/ng.2421
  28. Coucke PJ, Willaert A, Wessels MW, Callewaert B, Zoppi N, De Backer J, et al. Mutations in the facilitative glucose transporter GLUT10 alter angiogenesis and cause arterial tortuosity syndrome. *Nat Genet.* 2006;38:452–457. 10.1038/ng1764
  29. Renard M, Holm T, Veith R, Callewaert BL, Adès LC, Baspinar O, et al. Altered TGF $\beta$  signaling and cardiovascular manifestations in patients with autosomal recessive cutis laxa type I caused by fibulin-4 deficiency. *Eur J Hum Genet.* 2010;18:895–901. 10.1038/ejhg.2010.45
  30. Guo DC, Pannu H, Tran-Fadulu V, Papke CL, Yu RK, Avidan N, et al. Mutations in smooth muscle alpha-actin (ACTA2) lead to thoracic aortic aneurysms and dissections. *Nat Genet.* 2007;39:1488–1493. 10.1038/ng.2007.6
  31. Milewicz DM, Grossfield J, Cao SN, Kilty C, Covitz W, Jewett T. A mutation in FBN1 disrupts profibrillin processing and results in isolated skeletal features of the Marfan syndrome. *J Clin Invest.* 1995;95:2373–2378. 10.1172/JCI117930
  32. Hasham SN, Guo DC, Milewicz DM. Genetic basis of thoracic aortic aneurysms and dissections. *Curr Opin Cardiol.* 2002;17:677–683. 10.1097/00001573-200211000-00015
  33. Garg V, Muth AN, Ransom JF, Schluterman MK, Barnes R, King IN, et al. Mutations in NOTCH1 cause aortic valve disease. *Nature.* 2005;437:270–274. 10.1038/nature03940
  34. McKellar SH, Tester DJ, Yagubyan M, Majumdar R, Ackerman MJ, Sundt TM, III. Novel NOTCH1 mutations in patients with bicuspid aortic valve disease and thoracic aortic aneurysms. *J Thorac Cardiovasc Surg.* 2007;134:290–296. 10.1016/j.jtcvs.2007.02.041
  35. Lang RM, Bierig M, Devereux RB, Flachskampf FA, Foster E, Pellikka PA, et al. Recommendations for chamber quantification: a report from the American Society of Echocardiography's Guidelines and Standards Committee and the Chamber Quantification Writing Group, developed in conjunction with the European Association of Echocardiography, a branch of the European Society of Cardiology. *J Am Soc Echocardiogr.* 2005;18:1440–1463. 10.1016/j.echo.2005.10.005
  36. Devereux RB, de Simone G, Arnett DK, Best LG, Boerwinkle E, Howard BV, et al. Normal limits in relation to age, body size and gender of two-dimensional echocardiographic aortic root dimensions in persons  $\geq$ 15 years of age. *Am J Cardiol.* 2012;110:1189–1194. 10.1016/j.amjcard.2012.05.063
  37. Loeys BL, Dietz HC, Braverman AC, Callewaert BL, De Backer J, Devereux RB, et al. The revised Ghent nosology for the Marfan syndrome. *J Med Genet.* 2010;47:476–485. 10.1136/jmg.2009.072785.
  38. Baetens M, Van Laer L, De Leeneer K, Hellemans J, De Schrijver J, Van De Voorde H, et al. Applying massive parallel sequencing to molecular diagnosis of Marfan and Loeys-Dietz syndromes. *Hum Mutat.* 2011;32:1053–1062. 10.1002/humu.21525
  39. Neptune ER, Frischmeyer PA, Arking DE, Myers L, Bunton TE, Gayraud B, et al. Dysregulation of TGF-beta activation contributes to pathogenesis in Marfan syndrome. *Nat Genet.* 2003;33:407–411. 10.1038/ng1116
  40. Charbonneau NL, Carlson EJ, Tufa S, Sengle G, Manalo EC, Carlberg VM, et al. In vivo studies of mutant fibrillin-1 microfibrils. *J Biol Chem.* 2010;285:24943–24955. 10.1074/jbc.M110.130021
  41. Isogai Z, Ono RN, Ushiro S, Keene DR, Chen Y, Mazzei R, et al. Latent transforming growth factor beta-binding protein 1 interacts with fibrillin and is a microfibril-associated protein. *J Biol Chem.* 2003;278:2750–2757. 10.1074/jbc.M209256200
  42. Dallas SL, Keene DR, Bruder SP, Saharinen J, Sakai LY, Mundy GR, et al. Role of the latent transforming growth factor beta binding protein 1 in fibrillin-containing microfibrils in bone cells in vitro and in vivo. *J Bone Miner Res.* 2000;15:68–81. 10.1359/jbmr.2000.15.1.68
  43. Dallas SL, Miyazono K, Skerry TM, Mundy GR, Bonewald LF. Dual role for the latent transforming growth factor-beta binding protein in storage of latent TGF-beta in the extracellular matrix and as a structural matrix protein. *J Cell Biol.* 1995;131:539–549. 10.1083/jcb.131.2.539
  44. Saharinen J, Hyytiainen M, Taipale J, Keski-Oja J. Latent transforming growth factor-beta binding proteins (LTBPs)—structural extracellular matrix proteins for targeting TGF-beta action. *Cytokine & growth factor reviews.* 1999;10:99–117.
  45. Andrabi S, Bekheirnia MR, Robbins-Furman P, Lewis RA, Prior TW, Potocki L. SMAD4 mutation segregating in a family with juvenile polyposis, aortopathy, and mitral valve dysfunction. *Am J Med. Genet A.* 2011;155A:1165–1169. 10.1002/ajmg.a.33968
  46. Lindsay ME, Schepers D, Bolar NA, Doyle JJ, Gallo E, Fert-Bober J, et al. Loss-of-function mutations in TGF $\beta$ 2 cause a syndromic presentation of thoracic aortic aneurysm. *Nat Genet.* 2012;44:922–927. 10.1038/ng.2349
  47. Renard M, Callewaert B, Malfait F, Sharif S, del Campo M, William C, et al. Thoracic aortic aneurysm and dissection in association with significant mitral valve disease caused by mutations in TGF $\beta$ 2. *Int J Cardiol.* 2013;165:584–587. 10.1016/j.ijcard.2012.09.029
  48. Renard M, Callewaert B, Baetens M, Campens L, MacDermot K, Fryns JP, et al. Novel MYH11 and ACTA2 mutations reveal a role for enhanced TGF $\beta$  signaling in FTAAD. *Int J Cardiol.* 2013;165:314–321. 10.1016/j.ijcard.2011.08.079
  49. Moustakas A, Heldin CH. The regulation of TGFbeta signal transduction. *Development.* 2009;136:3699–3714. 10.1242/dev.030338
  50. Lindsay ME, Dietz HC. Lessons on the pathogenesis of aneurysm from heritable conditions. *Nature.* 2011;473:308–316. 10.1038/nature10145
  51. Coady MA, Davies RR, Roberts M, Goldstein LJ, Rogalski MJ, Rizzo JA, et al. Familial patterns of thoracic aortic aneurysms. *Arch Surg.* 1999;134:361–367. 10.1001/archsurg.134.4.361
  52. Albornoz G, Coady MA, Roberts M, Davies RR, Tranquilli M, Rizzo JA, et al. Familial thoracic aortic aneurysms and dissections—incidence, modes of inheritance, and phenotypic patterns. *Ann Thorac Surg.* 2006;82:1400–1405. 10.1016/j.athoracsur.2006.04.098
  53. Hiratzka LF, Bakris GL, Beckman JA, Bersin RM, Carr VF, Casey DE, Jr., et al. 2010 ACCF/AHA/AATS/ACR/ASA/SCA/SCAI/SIR/STS/SVM Guidelines for the diagnosis and management of patients with thoracic aortic disease. A report of the American College of

- Cardiology Foundation/American Heart Association Task Force on Practice Guidelines, American Association for Thoracic Surgery, American College of Radiology, American Stroke Association, Society of Cardiovascular Anesthesiologists, Society for Cardiovascular Angiography and Interventions, Society of Interventional Radiology, Society of Thoracic Surgeons, and Society for Vascular Medicine. *J Am Coll Cardiol*. 2010;55:e27–e129. 10.1016/j.jacc.2010.02.015
54. Westover AN, Nakonezny PA. Aortic dissection in young adults who abuse amphetamines. *Am Heart J*. 2010;160:315–321. 10.1016/j.ahj.2010.05.021
55. Daniel JC, Huynh TT, Zhou W, Kougiaris P, El Sayed HF, Huh J, et al. Acute aortic dissection associated with use of cocaine. *J Vasc Surg*. 2007;46:427–433. 10.1016/j.jvs.2007.05.040
56. Shores J, Berger KR, Murphy EA, Pyeritz RE. Progression of aortic dilatation and the benefit of long-term beta-adrenergic blockade in Marfan's syndrome. *N Engl J Med*. 1994;330:1335–1341. 10.1056/NEJM199405123301902
57. Habashi JP, Judge DP, Holm TM, Cohn RD, Loeys BL, Cooper TK, et al. Losartan, an AT1 antagonist, prevents aortic aneurysm in a mouse model of Marfan syndrome. *Science*. 2006;312:117–221. 10.1126/science.1124287
58. Brooke BS, Habashi JP, Judge DP, Patel N, Loeys B, Dietz HC, 3rd. Angiotensin II blockade and aortic-root dilation in Marfan's syndrome. *N Engl J Med*. 2008;358:2787–2795. 10.1056/NEJMoa0706585
59. Lacro RV, Dietz HC, Wruck LM, Bradley TJ, Colan SD, Devereux RB, et al. Rationale and design of a randomized clinical trial of beta-blocker therapy (atenolol) versus angiotensin II receptor blocker therapy (losartan) in individuals with Marfan syndrome. *Am Heart J*. 2007;154:624–631. 10.1016/j.ahj.2007.06.024
60. Ong KT, Perdu J, De Backer J, Bozec E, Collignon P, Emmerich J, et al. Effect of celiprolol on prevention of cardiovascular events in vascular Ehlers-Danlos syndrome: a prospective randomised, open, blinded-endpoints trial. *Lancet*. 2010;376:1476–1484. 10.1016/S0140-6736(10)60960-9
61. Baumgartner H, Bonhoeffer P, DeGroot NM, de Haan F, Deanfield JE, Galie N, et al. ESC Guidelines for the management of grown-up congenital heart disease (new version 2010). *Eur Heart J*. 2010;31:2915–2957. 10.1093/eurheartj/ehq249
62. Williams JA, Loeys BL, Nwakanma LU, Dietz HC, Spevak PJ, Patel ND, et al. Early surgical experience with Loeys-Dietz: a new syndrome of aggressive thoracic aortic aneurysm disease. *Ann Thorac Surg*. 2007;83: S757–763; discussion S785–790.
63. Hiratzka LF, Bakris GL, Beckman JA, Bersin RM, Carr VF, Casey DE, Jr., et al. 2010 ACCF/AHA/AATS/ACR/ASA/SCA/SCAI/SIR/STS/SVM guidelines for the diagnosis and management of patients with Thoracic Aortic Disease: a report of the American College of Cardiology Foundation/American Heart Association Task Force on Practice Guidelines, American Association for Thoracic Surgery, American College of Radiology, American Stroke Association, Society of Cardiovascular Anesthesiologists, Society for Cardiovascular Angiography and Interventions, Society of Interventional Radiology, Society of Thoracic Surgeons, and Society for Vascular Medicine. *Circulation*. 2010;121:e266–e369. 10.1161/CIR.0b013e3181d4739e
64. Milewicz DM, Regalado E. Thoracic Aortic Aneurysms and Aortic Dissections. 2003 Feb 13 [Updated 2012 Jan 12]. In: Pagon RA, Adam MP, Bird TD, Dolan CR, Fong C-T, Stephens K editors. *GeneReviews™* [Internet]. Seattle (WA): University of Washington, Seattle; 1993–2013. Available from: <http://www.ncbi.nlm.nih.gov/books/NBK1120/>. Last Accessed: March 2, 2013.
65. Tran-Fadulu V, Pannu H, Kim DH, Vick GW, 3rd, Lonsford CM, Lafont AL, et al. Analysis of multigenerational families with thoracic aortic aneurysms and dissections due to TGFBR1 or TGFBR2 mutations. *J Med Genet*. 2009;46:607–613. 10.1136/jmg.2008.062844

**Cite this article as:** De Backer J, Renard M, Campens L, François K, Callewaert B, Coucke P, De Paepe A, Genes in Thoracic Aortic Aneurysms and Dissections – Do they Matter? Translation and Integration of Research and Modern Genetic Techniques into Daily Clinical Practice. *Aorta* 2013;1(2):135–145. DOI:<http://dx.doi.org/10.12945/j.aorta.2013.13-024>

## EDITOR'S COMMENTS

Dr. De Backer and colleagues, from the distinguished Ghent group, provide a clinically oriented primer on the current state of knowledge regarding the genetics of thoracic aortic aneurysm. They tell us just how to use genetic testing in the present era. As well, they provide useful management and clinical guidelines that take into account the emerging knowledge of aneurysm behavior in specific genetic syndromes. They usher us into the era of personal-

ized aortic management based on molecular genetics.

The Editors only point of difference concerns frequency of imaging. Since the aorta grows very slowly in the vast majority of thoracic aneurysm patients (about 1 mm per year), after the first yearly ECHO, CT, or MRI are done, we decrease frequency of imaging to every two to three years. (ECHOs can be done frequently, if desired, because of low cost and zero toxicity. We use restraint in CT and MRI.)