

56. Ohtori S, Isogai E, Hasue F *et al.* Reduced inflammatory pain in mice deficient in the differential screening-selected gene aberrative in neuroblastoma. *Mol Cell Neurosci* 2004; 25: 504–514
57. Chi L, Saarela U, Railo A *et al.* A secreted BMP antagonist, Cerl1, fine tunes the spatial organization of the ureteric bud tree during mouse kidney development. *PLoS One* 2011; 6: e27676
58. Marques S, Borges AC, Silva AC *et al.* The activity of the Nodal antagonist Cerl-2 in the mouse node is required for correct L/R body axis. *Genes Dev* 2004; 18: 2342–2347
59. Dolan V, Murphy M, Sadlier D *et al.* Expression of gremlin, a bone morphogenetic protein antagonist, in human diabetic nephropathy. *Am J Kidney Dis* 2005; 45: 1034–1039
60. Mezzano S, Droguett A, Burgos ME *et al.* Expression of gremlin, a bone morphogenetic protein antagonist, in glomerular crescents of pauci-immune glomerulonephritis. *Nephrol Dial Transplant* 2007; 22: 1882–1890
61. Michos O, Panman L, Vintersten K *et al.* Gremlin-mediated BMP antagonism induces the epithelial-mesenchymal feedback signaling controlling metanephric kidney and limb organogenesis. *Development* 2004; 131: 3401–3410
62. Kassai Y, Munne P, Hotta Y *et al.* Regulation of mammalian tooth cusp patterning by ectodin. *Science* 2005; 309: 2067–2070
63. Kramer I, Loots GG, Studer A *et al.* Parathyroid hormone (PTH)-induced bone gain is blunted in SOST overexpressing and deficient mice. *J Bone Miner Res* 2010; 25: 178–189
64. Bachiller D, Klingensmith J, Kemp C *et al.* The organizer factors Chordin and Noggin are required for mouse forebrain development. *Nature* 2000; 403: 658–661
65. Larman BW, Karolak MJ, Adams DC *et al.* Chordin-like 1 and twisted gastrulation 1 regulate BMP signaling following kidney injury. *J Am Soc Nephrol* 2009; 20: 1020–1031
66. Villanueva S, Cespedes C, Gonzalez AA *et al.* Inhibition of bFGF-receptor type 2 increases kidney damage and suppresses nephrogenic protein expression after ischemic acute renal failure. *Am J Physiol Regul Integr Comp Physiol* 2008; 294: R819–R828
67. Brunet LJ, McMahon JA, McMahon AP *et al.* Noggin, cartilage morphogenesis, and joint formation in the mammalian skeleton. *Science* 1998; 280: 1455–1457
68. McMahon JA, Takada S, Zimmerman LB *et al.* Noggin-mediated antagonism of BMP signaling is required for growth and patterning of the neural tube and somite. *Genes Dev* 1998; 12: 1438–1452
69. Zakin L, De Robertis EM. Inactivation of mouse Twisted gastrulation reveals its role in promoting Bmp4 activity during forebrain development. *Development* 2004; 131: 413–424
70. Nosaka T, Morita S, Kitamura H *et al.* Mammalian twisted gastrulation is essential for skeleto-lymphogenesis. *Mol Cell Biol* 2003; 23: 2969–2980
71. Ikeya M, Fukushima K, Kawada M *et al.* Cv2, functioning as a pro-BMP factor via twisted gastrulation, is required for early development of nephron precursors. *Dev Biol* 2010; 337: 405–414
72. Ikeya M, Kawada M, Kiyonari H *et al.* Essential pro-Bmp roles of crossveinless 2 in mouse organogenesis. *Development* 2006; 133: 4463–4473
73. Lin J, Patel SR, Cheng X *et al.* Kielin/chordin-like protein, a novel enhancer of BMP signaling, attenuates renal fibrotic disease. *Nat Med* 2005; 11: 387–393

Received for publication: 5.5.2012; Accepted in revised form: 12.7.2012

Nephrol Dial Transplant (2012) 27: 3691–3704
doi: 10.1093/ndt/gfs442

Genetic causes and mechanisms of distal renal tubular acidosis

Daniel Batlle and Syed K. Haque

Division of Nephrology/Hypertension, Northwestern University Feinberg School of Medicine, Chicago, IL, USA

Correspondence and offprint requests to: Daniel Batlle; E-mail: d-batlle@northwestern.edu

Abstract

The primary or hereditary forms of distal renal tubular acidosis (dRTA) have received increased attention because of advances in the understanding of the molecular mechanism, whereby mutations in the main proteins involved in acid–base transport result in impaired acid excretion. Dysfunction of intercalated cells in the collecting tubules accounts for all the known genetic causes of dRTA. These cells secrete protons into the tubular lumen through H⁺-ATPases functionally coupled to the basolateral anion exchanger 1 (AE1). The substrate for both transporters is provided by the catalytic activity of the cytosolic carbonic anhydrase II (CA II), an enzyme which is also present in the proximal tubular cells and osteoclasts. Mutations in ATP6V1B1, encoding the

B-subtype unit of the apical H(+) ATPase, and ATP6V0A4, encoding the a-subtype unit, lead to the loss of function of the apical H(+) ATPase and are usually responsible for patients with autosomal recessive dRTA often associated with early or late sensorineural deafness. Mutations in the gene encoding the cytosolic CA II are associated with the autosomal recessive syndrome of osteopetrosis, mixed distal and proximal RTA and cerebral calcification. Mutations in the AE1, the gene that encodes the Cl⁻/HCO₃⁻ exchanger, usually present as dominant dRTA, but a recessive pattern has been recently described. Several studies have shown trafficking defects in the mutant protein rather than the lack of function as the major mechanism underlying the pathogenesis of dRTA from AE1 mutations.

Keywords: acidosis; AE1; carbonic anhydrase; distal RTA; H⁺-ATPase

Introduction

The renal tubular acidosis (RTA) syndromes encompass a disparate group of tubular transport defects that have in common the inability to secrete hydrogen ions (H⁺), a defect that is disproportionately large in relation to any reduction in the glomerular filtration rate (GFR) [1–3]. This inability results in failure to excrete acid in the form of ammonium (NH₄⁺) ion and titratable acids or to reabsorb some of the filtered bicarbonate (HCO₃⁻) load. In either situation, there is a fall in plasma bicarbonate leading to chronic metabolic acidosis. Much of the morbidity in the RTA syndromes is attributable to the systemic consequences of chronic metabolic acidosis namely growth retardation, bone disease and kidney stones [2–4].

The initial classification of tubular defects in urinary acidification was designed to separate those involving the distal nephron from those affecting the proximal nephron [4]. Clinical and functional studies allow classification into four types, historically numbered in the order of discovery: proximal (Type 2), classic distal (Type 1), hyperkalemic distal (Type 4) and combined proximal and distal (Type 3). dRTA was the first RTA recognized, and thus, the terms ‘Type 1’ or ‘classic RTA’ have been used to describe this form of RTA. dRTA is characterized by an inability to lower urine pH despite severe acidemia and minimal HCO₃⁻ wastage. Proximal RTA (Type 2), by contrast, is characterized by marked HCO₃⁻ wastage, but preserved ability to lower urine pH when plasma HCO₃⁻ (and therefore filtered HCO₃⁻) is below a certain level. The term ‘Type 3 RTA’ is used to describe patients, in whom HCO₃⁻ wastage coexists with failure to lower urine pH despite profound acidemia, thus demonstrating a mixed pattern of tubular dysfunction [4].

Patients with RTA are often growth retarded because of the chronic metabolic acidosis unless alkaline therapy is initiated earlier in life. Associated features are nephrocalcinosis, nephrolithiasis, hypercalciuria and hypocitraturia. Polyuria is often encountered, and may be related, at least in part, to the associated hypokalemia [5]. Other extrarenal manifestations depend on the gene mutated and the type of mutation [6–8]. Hemolytic anemia may be seen in some types of hereditary RTA associated with AE1 mutations, whereas deafness is an important feature in some H⁺-ATPase mutations.

Hypokalemia is a striking feature of dRTA or Type 1 RTA, but it is also frequently seen with proximal RTA or Type 2 RTA [9]. Hyperkalemic forms of distal RTA, however, were later recognized. The first type described was attributable to aldosterone deficiency, and the term Type 4 RTA was coined to describe it [10]. In addition, hyperkalemic distal renal tubular acidosis (dRTA) due to a combined tubular defect in hydrogen (H⁺) and potassium (K⁺) ion secretion possibly resulting from a voltage-dependent defect was also described in the early 1980s [11–13]. In this review, we will limit the discussion to the non-hyperkalemic types of RTA and focus only on

hereditary distal RTA. Many of the acquired causes of RTA, particularly the distal form, are due to the immune mechanism or drug-induced kidney damage and will not be discussed here. The purpose of this review is to provide an update on recent studies on hereditary distal RTA and particularly the mechanisms involved in the causation of distal RTA at the molecular level.

Causes of hereditary dRTA

Acid-base transport within the distal nephron is primarily effected by specific transporters located in intercalated cells [8, 14–17]. Distal RTA can be attributed to failure of the kidney-intercalated cells to acidify the urine normally as a result of dysfunction in any of the transporters involved in the overall process of acidifying the urine maximally (Figure 1). As a result of decreased distal H⁺-ion secretion, there is a failure to lower urine pH maximally and excrete acid as ammonium and other titratable buffers which with time results in the development of hyperchloremic metabolic acidosis, the hallmark of classic or Type 1 dRTA. The incomplete form of distal RTA, like complete dRTA, presents with failure to maximally lower urine pH, but blood pH and plasma bicarbonate are normal [2]. Acid load with ammonium chloride reveals the defect by showing that urine pH could not be maximally lowered, and remains above 5.3.

The currently known mutations resulting in inherited dRTA have been identified in transporters present in intercalated cells such as the anion exchanger 1 (AE1), the B1 and a4 subunits of H⁺-ATPase and the cytosolic carbonic anhydrase II (CA II) [18–37]. It should be noted, however, that the rate of H⁺-ion secretion by α -intercalated cells is importantly influenced by the rate of Na⁺ transport in the neighboring principal cells that are involved in Na⁺ reabsorption and K⁺ secretion, but not in H⁺ secretion [9].

The various mutations in the acid–base transporters involved in the causation of dRTA involve complex mechanisms that are specific for each transporter and some of the specific mutations involved. It has been long recognized that cytosolic CA, by catalyzing the hydration of CO₂ to H⁺ and HCO₃⁻, plays a key role in the intracellular generation of these ions from CO₂ that enters the tubular cells (Figure 1). In fact, the first type of hereditary distal RTA described was that caused by CA deficiency [38]. A key requirement for proper acidification of the urine by the α -intercalated cells is that the secretion of protons in the apical membrane (largely a function of the H⁺-ATPase) be coupled to extrusion of bicarbonate in the basolateral membrane, a process carried out by the AE1 exchanger (Figure 1).

Failure of H⁺-ATPase-driven H⁺-ion secretion has been the main mechanism long postulated to account for the inability to lower urine pH maximally in patients with dRTA [1, 39]. The importance of the exit step for bicarbonate for optimal distal acidification of the urine, however, is also evident from physiologic studies and confirmed by the clinical phenotype of dRTA seen in

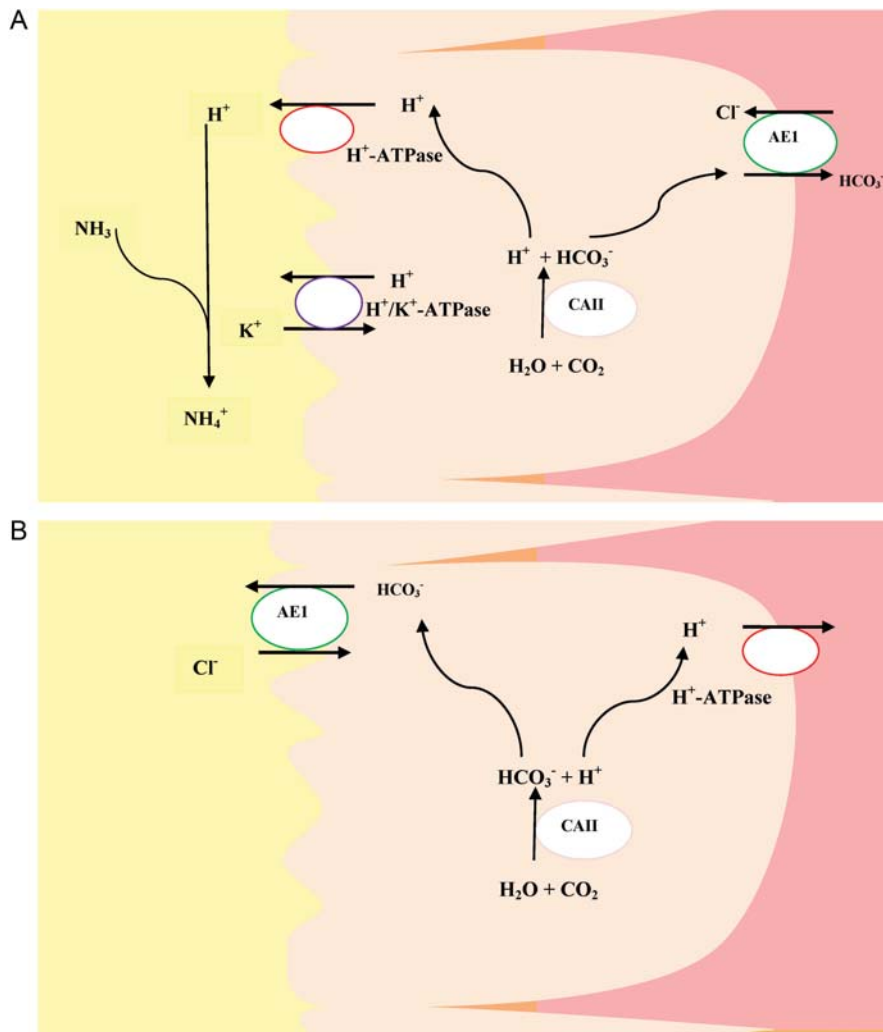


Fig. 1. Collecting tubule acid–base transporters involved in H^+ secretion and HCO_3^- reabsorption by α -intercalated cells (A) and β -intercalated cells (B). CA II, carbonic anhydrase II; AE1, anion exchanger 1.

patients with mutations in the AE1 exchanger as discussed in detail below.

AE1 mutations

The AE1 gene belongs to the SLC4 family of genes and is present on chromosome 17 q21-22 [8, 14]. AE1 proteins encoded by this gene are expressed on the erythrocyte plasma membrane and the basolateral membrane of the kidney α -intercalated cells in the connecting tubules, the cortical collecting duct and also medullary collecting duct [15, 16]. AE1 proteins bring about an exchange of intracellular bicarbonate (HCO_3^-) for extracellular chloride (Cl^-) ions [14]. In the α -intercalated cells, this exchanger provides the exit step for bicarbonate (Figure 1A). This exchanger is distinct from other chloride–bicarbonate exchanger in the kidney, such as the pendrin, which is located in the apical membrane of β -intercalated cells (Figure 1B) and non-A-, non-B-intercalated cells [17].

AE1 mutations causing dRTA were initially described by Bruce *et al.* [18], and later by Karet *et al.* [19]. Some AE1 mutations are associated with hemolytic diseases such as hereditary spherocytosis (HS) without any evidence of dRTA [6]. Others cause dRTA but without hemolytic disease or only mild asymptomatic red cell fragility [6]. In very rare instances, mostly from Southeast Asia, dRTA and hemolytic disease have been reported to occur together [6, 20, 22]. In the following sections, we discuss AE1 mutations grouped as those associated with autosomal dominant (AD) and those associated with recessive RTA.

The AD AE1 mutations were first described in several affected families from Southeast England [18]. Missense mutations in codon Arg589 of the AE1 gene, resulting in substitution of arginine by histidine (R589H) or cysteine (R589C), and in codon Ser613, resulting in substitution of serine by phenylalanine, were identified [18]. No mutations were found in the unaffected members of the families [18]. A subsequent study revealed new AD

mutations: R901X and R589S [19]. Mutation R901X was found to cause premature termination of protein at codon position 901 leading to a truncated AE1 protein by 11 amino acids, whereas R589S was a missense mutation in codon Arg589 which caused substitution of arginine by serine [19]. In these early studies, AE1 mutations were not found in any of the families with autosomal recessive dRTA [19]. This led to the initial belief that AE1 mutations always cause AD dRTA. However, mutations in association with recessive dRTA were later identified as discussed below [6, 21].

Dominant AE1 mutation cases can present as complete or incomplete dRTA [18, 23]. Bruce *et al.* [18] reported incomplete dRTA in 8 of 18 patients investigated and, interestingly, over the course of 10 years, two of the eight went on to develop acidosis. Incomplete dRTA was also found in the father of two affected children from Brazil [23]. AD A888L mutation was later identified in this family.

AD cases are usually diagnosed at a later age than recessive ones [2, 5]. Karet *et al.* [19] reported some cases of AD dRTA at 10 years of age or later. However, Bruce *et al.* [18] reported four patients diagnosed below 10 years of age and one was diagnosed as early as 2 years. In Bruce *et al.*'s study, most patients, at the time of diagnosis, had plasma bicarbonate near the lower normal range. Plasma potassium ranged from 3.0 to 4.2 mmol/L with most being in the normal range. In general, patients with AE1 mutations seem to have less severe hypokalemia than those with recessive dRTA due to H⁺-ATPase mutations [9]. Maximal urine osmolality was below normal, and eight patients had both nephrocalcinosis and kidney stones, while five had only nephrocalcinosis and two had only kidney stones [18]. Nephrolithiasis and nephrocalcinosis are uncommon at a younger age. Karet *et al.* [19] reported that three of the six patients had milder acidosis; all had plasma bicarbonate ≥ 17.4 mmol/L and were hyperchloremic, but none of these patients had developed nephrocalcinosis although two had presented with kidney stones at an older age.

Although AE1 is abundantly present on erythrocytes and helps maintain cytoskeleton structure as well as ion transport, hemolytic anemia is rarely associated with mutations that cause dRTA. Dominant mutant proteins have been shown to retain normal chloride/bicarbonate exchange function in erythrocytes [18]. In contrast to the kidney cells, erythrocytes express mutant proteins on the surface, thus suggesting no traffic abnormality to the erythrocyte membrane [18, 24]. This might explain the absence of hemolytic anemia in AD cases. The only AD AE1 mutation causing hemolytic anemia with dRTA has been reported with A858D mutation from Malaysia and India [20, 25].

As noted above, it was initially thought that AE1 mutations were always associated with AD dRTA. Autosomal recessive AE1 mutation was first reported in a family from northeast Thailand [21]. Interestingly, unlike AD cases, the affected members had hemolytic anemia and dRTA. Subsequently, cases were reported from Malaysia and Papua New Guinea [20], Madagascar [26], Taiwan [27], Portugal [28] and Algeria [29]. Most cases have been seen in Southeast Asia especially Thailand.

Recently, the only case in a Caucasian family was reported from Scandinavia [30].

In contrast to AD dRTA, autosomal recessive patients always present as complete dRTA. In the first reported case (G701D/G701D mutation), the male patient (age = 3.5 years) presented with lethargy, anorexia and delayed growth [21]. Biochemical analysis showed hypokalemia, hyperchloremic acidosis, an alkaline urinary pH, bilateral nephrocalcinosis, rachitic bone changes and hemolytic anemia. Their parents and other unaffected siblings were normal, and incomplete dRTA was not identified in them [21]. Choo *et al.* [31] reported a Q759H mutation in two children from Malaysia.

Most autosomal recessive AE1 mutations reported so far have been seen associated with hemolytic anemia as a result of Southeast Asia ovalocytosis [21] or HS [28]. Hemolytic anemia, however, is not always present in autosomal recessive AE1 mutations. A dRTA patient from northeast Thailand was reported with rickets and bilateral nephrocalcinosis without anemia [22]. A compound heterozygous recessive mutation (S773P/G701D) was identified in this patient [22].

Mechanisms of dRTA in AE1 mutants

The molecular mechanisms that render a mutated protein dysfunctional are complex and may involve an array of defects spanning from internal sequestration of a given transporter to its mistargeting to the plasma membrane. A scheme of AE1 mutations resulting in non-function, internal sequestration in endoplasmic reticulum or Golgi apparatus, or mistargeting to the apical membrane is shown in Figure 2. Next are reviewed studies that have shown various mutations in patients with dRTA and cell biology studies aimed at exploring the potential mechanism that result in impaired function of the various acid-base transporters involved.

Initial studies used chloride transport in *Xenopus* oocytes as a way to study AE1 exchange activity *in vitro* [18]. Expression of erythroid and kidney mutant protein (R589C, S613F and R589H) revealed normal chloride transport activity with all mutant proteins except R589H mutant which had reduced chloride activity in erythrocytes [18]. Mutant proteins were also found to be expressed on erythrocytes and oocyte cell membranes [18, 24]. This suggested that these proteins might traffic normally to the surface of the α -intercalated cells of human kidney. Later studies with the R589H mutation expressed on human embryonic kidney cells, however, showed a severe trafficking defect of the kidney kAE1 but not of erythrocyte anion exchanger [32]. A schematic overview of mechanisms leading to AE1 dysfunction at the cellular level is summarized in Figure 2. The mutated protein appears to be sequestered in the endoplasmic reticulum, and although functional, it does not traffic to the basolateral membrane and therefore bicarbonate cannot exit the cell (Figure 2B) [32]. Recessive kAE1 G701D and S773P mutants, unlike dominant R589H mutants, traffic to the basolateral membrane when co-expressed with kAE1 wild-type (WT) [33]. This has been suggested

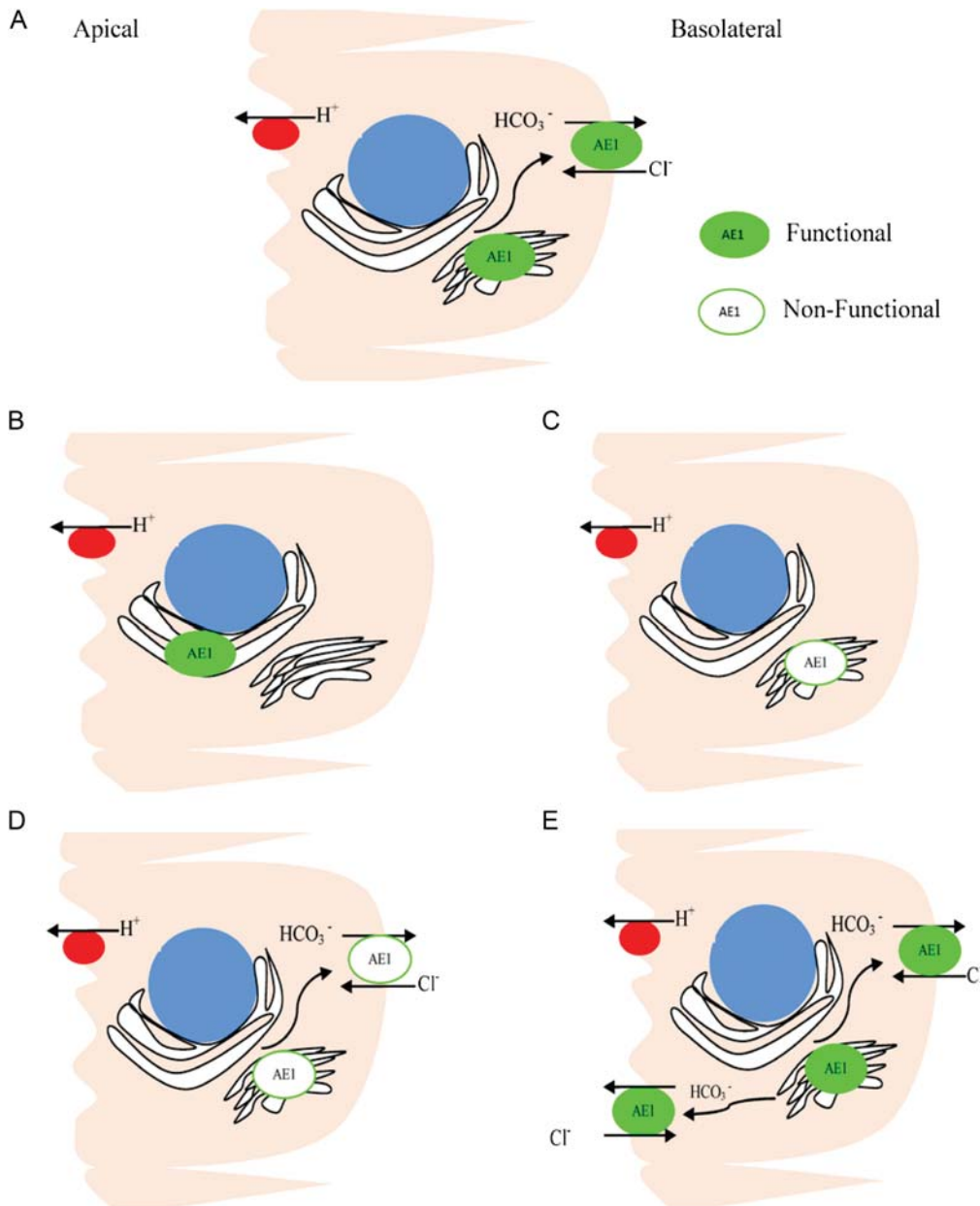


Fig. 2. Schematic model of various mechanisms, whereby kAE1 mutations result in abnormal Cl^-/HCO_3^- in dRTA. (A) Normal, (B) internal sequestration in the endoplasmic reticulum (R589H, S613F, S667P) [29, 32, 33], (C) internal sequestration in the golgi apparatus (G701D) [33], (D) non-functional/partially functional (S773P) [22], (E) mistargeting to both the apical membrane and basolateral (G609R, R901X, M909T) [35–37].

as an explanation for the absence of dRTA in heterozygous recessive patients.

Glycophorin A has been studied for its role in increasing surface expression of AE1 mutant proteins [29]. Studies on *Xenopus* oocytes showed increased surface expression of autosomal recessive G701D resulting in 100% return of transport activity to normal [20]. AD A858D and autosomal recessive $\Delta V850$ mutant AE1 showed lesser increase in surface expression and resulted in only $64 \pm 5\%$ and $43 \pm 3\%$ return of chloride transport activity, respectively [20]. A similar glycophorin rescue pattern was observed with the recessive mutation S667P

[29]. Glycophorin A is present in red blood cells but absent from kidney cells [34]. It has, therefore, been suggested that this could be the reason why kAE1 mutation rarely leads to a red blood cell defect [34].

The underlying defect caused by AE1 mutation leading to dRTA has also been studied on Madin-Darby Canine Kidney (MDCK) cells [33]. Studies on mutations known to cause dRTA have revealed several mechanisms that could lead to reduced chloride–bicarbonate exchange and thus lead to dRTA [33]. This has been the subject of recent excellent reviews [5, 6]. Polarized MDCK cells as opposed to non-polarized MDCK have been shown to be

more representative of the α -intercalated cells in the kidney [35]. While AE1 expression is diffuse in non-polarized MDCK cells, it is expressed exclusively in the basolateral membrane of polarized MDCK cells, a finding that is similar to α -intercalated cells in the kidney [35].

Using this cell model, Cordat *et al.* [33] studied two dominant (R589H and S613F) and two recessive (S773P and G701D) AE1 mutations in MDCK cells. In polarized MDCK cells, they found that dominant R589H and S613F mutants were retained in the endoplasmic reticulum (Figure 2B). Two hours later, these mutant proteins were barely detectable suggesting rapid degradation [33]. In some cells, mutant protein was mistargeted to the apical membrane [33].

Recessive mutant protein was sequestered in the Golgi apparatus (G701D; Figure 2C) or trafficked to the basolateral membrane to a lesser extent than the kAE1 WT (S773P; Figure 2D) [33]. A previous MDCK study with recessive S667P mutation has shown sequestration in the endoplasmic reticulum [29]. Misfolding leading to impaired function and decreased half-life has been described with S773P-recessive mutant proteins causing dRTA [22].

An AE1 mutation (M909T) that affects the C-terminal of AE1, found in a family with dominant dRTA, was recently demonstrated in polarized MDCK cells to be localized both in the apical and basolateral membrane [37]. This pattern of abnormal mistargeting is illustrated in Figure 2E. It was also elucidated for the first time that the kidney AE1 wild-type traffics directly to the basolateral membrane without any transient traffic to the apical membrane and then retrieval to the basolateral membrane as with other proteins [37].

Another study on another dominant mutation (G609R) found mistargeting to both the apical membrane and the basolateral membrane in polarized MDCK cells [36]. The same mutant proteins have been shown to retain normal chloride/bicarbonate exchange function in erythrocytes and *Xenopus* oocytes [18, 24]. Mistargeting to the apical membrane would cause bicarbonate secretion and thus a highly alkaline urine, and this was suggested in a patient with G609R mutation [36] (Figure 2E). Mistargeting to the apical membrane alone has been reported in R901X mutants in stably transfected cells [35].

Recent studies have documented reasonably well the interconversion of α -intercalated cells and β -intercalated cells [40, 41]. Exposure to acid in the basolateral medium identified a significant conversion of β -intercalated cells to α -intercalated cells [40]. This conversion was attributed to the deposition of hensin in the extracellular matrix. This has been studied in hensin knock-out mice that develop acidosis and have only β -intercalated cells expressing pendrin, the apical Cl^- - HCO_3^- exchanger [42]. In another study, bicarbonate (HCO_3^-) exposure initiated the conversion of β -intercalated cells to α -intercalated cells [41]. Whether this conversion depends on hensin degradation remains to be shown. Hensin mutation as one of the possibilities of hereditary dRTA in humans should be considered, but remains to be documented [42].

CA II gene mutations

The CA II gene is located at q22 on chromosome 8 [2]. CAs are zinc metalloenzymes that catalyze the reversible hydration of CO_2 to form HCO_3^- and H^+ [43]. There are 15 known CAs. CA II is the most widespread and has the highest catalytic activity [44].

CA II, CA IV and CA XII are expressed by the human kidney [45]. A total of 95% of renal CA consists of cytoplasmic CA II, and the rest are membrane-associated CA IV and CA XII [46]. In the kidney, CA II is present in the proximal tubule, thin descending limb, thick ascending limb and intercalated cells of the cortical collecting duct, outer medullary collecting duct and inner medullary collecting duct (IMCD) [46].

Twenty-three different mutations causing RTA were identified in several families [6]. These had an autosomal recessive inheritance pattern [38]. Mutations in CA II lead to CA II deficiency, which is measurable in circulating erythrocytes [38, 47]. CA II deficiency has been reported in several ethnic backgrounds, including Arabic, Italian, German, French, Hispanic and African American [2, 38]. Later novel mutations were identified in other ethnic groups, which included an Irish family, a Turkish family of non-Arabic descent, an Asian Indian and British origin family [48]. Consanguinity is a common feature in families with CA II mutations [2, 48].

CA II deficiency is particularly common in the Middle East [49]. More than 70% of the cases have been described from the Arabian Peninsula [49, 50]. Patients of Arabic origin have a unique splice junction mutation at the junction of exon 2–intron 2 of the CA II gene (c.232 +1 G > A) [51]. A study done in patients from Tunisia and Algeria traced the ancestry of all affected patients studied to an old Arab tribe of Helal that had settled there in the 10th century. Clinically, Arabic patients have a very severe phenotype. Unlike American and Belgian patients (H107Y mutations), severe cognitive impairment is a consistent feature [50]. This was suggested to be because missense mutations are phenotypically less severe than splice site mutations, and frameshift mutations [48, 49]. However, later studies found a frameshift mutation in an American patient with only mild learning disabilities [48].

The lack of cognitive impairment has been reported from several patients with missense mutations. Shah *et al.* [48] reported two affected male children in a Canadian family with compound heterozygote mutation H94Y/G145R. Both patients had presented with osteopetrosis, RTA, cerebral calcification and developmental delay, but cognitive impairment was absent. Further investigation revealed the complete absence of CA II activity in G145R mutant, but some residual activity was present in H94Y mutant. This residual activity might explain the absence of severe cognitive impairment [48].

CA II deficiency is recessive mixed proximal–distal (Type 3) RTA [52]. A predominance of the dRTA has been reported in some cases [53, 54]. The characteristic biochemical findings are bicarbonate wasting, inability to lower urine pH below 5.5, a low urine-to-blood pCO_2

difference in an alkaline urine and decreased NH_4 excretion [6].

An autosomal recessive syndrome of osteopetrosis, RTA and cerebral calcification was initially reported in 1972 [55, 56]. The cause was not known until in 1983 when CA II deficiency was identified as the main defect by Sly *et al.* [38]. Whyte *et al.* investigated three sisters who had presented with osteopetrosis in infancy [53]. Although osteopetrosis resolved spontaneously, during adolescence two of them developed basal ganglia calcification. Later RTA was diagnosed. Whyte *et al.* suggested that acidosis might have led to spontaneous resolution of osteopetrosis [53]. Hemolysates from the sisters, their unaffected siblings and parents were examined for CA II activity [38]. CA II activity was completely absent in the erythrocytes of the affected sisters, while it was half normal in parents.

In 2004, Shah *et al.* studied 20 families referred for CA II deficiency. All patients studied had osteopetrosis, RTA and developmental delay. Skeletal fractures were reported in an American, a Turkish and an Ecuadorian patient. Cerebral calcification was present in most of the patients. Other studies have reported facial dysmorphism with low set ears, hypertelorism and a depressed nasal bridge [57, 58]. There have been very few reports of nephrocalcinosis and renal stones [59]. A link between primary pulmonary hypertension and CA II deficiency has also been suggested [60]. Lotan *et al.* [60] reported the development of pulmonary hypertension in an affected member of an Arabic family carrying CA II mutation (H64fsX). They hypothesized that as both conditions are rare, the probability of occurrence of both conditions by chance alone was unlikely.

Mild conductive hearing loss has been reported from Saudi Arabia [58, 61]. Middle ear effusion and ossicle ankylosis as a result of osteopetrosis was found to be the cause.

Mechanism of dRTA in CA II deficiency

Almost all bicarbonate filtered by the kidney is reabsorbed. Eighty percent of it is reabsorbed by the proximal tubules, 15% by the thick ascending limb and the rest by collecting tubules [47]. In the proximal tubule lumen, H_2CO_3 is catalyzed by membrane-anchored CA IV to H_2O and CO_2 . Conversion to CO_2 facilitates reabsorption as HCO_3^- is relatively impermeable to the apical membrane of proximal tubule. In contrast, CO_2 freely diffuses across the apical membrane into the cytosol. In the cytosol, the CA II catalyzes the hydration of CO_2 to H^+ and HCO_3^- . HCO_3^- is transported across into the peritubular space by the sodium-bicarbonate cotransporter (NBCe1), while H^+ reenters the tubular lumen via sodium-hydrogen exchanger (NHE3) forming H_2CO_3 with the filtered HCO_3^- . CA II deficiency fails to regenerate H^+ ion intracellularly, which is required for apical H^+ secretion and thus bicarbonate reabsorption in the proximal tubule [47].

CA II deficiency also affects H^+ secretion and HCO_3^- reabsorption in the distal nephron causing distal RTA. H^+ is secreted by H^+ -ATPase in the tubular lumen, while bicarbonate is reabsorbed by sodium-bicarbonate AE1. The H^+ ion and HCO_3^- are generated in the cytosol by the

catalytic action of CA II on CO_2 and H_2O (Figure 1). Thus, CA II deficiency aside from bicarbonate wasting (proximal component) leads to inability to maximally acidify urine (distal component) [47]. A mixed pattern of proximal and distal RTA, therefore, ensues with cytosolic CA II deficiency.

Bone resorption occurs by osteoclasts through an acidification process in the extracellular bone resorptive lacunae [47, 62]. This is achieved by H^+ -ion secretion into the lacunae by H^+ -ATPase [62]. H^+ is generated by the action of CA II, the only CA isoenzyme present in osteoclasts, through its action on H_2O and CO_2 in the cytosol of osteoclasts. This way CA II deficiency reduces bone resorption causing osteopetrosis, a consistent feature of CA II deficiency [47].

V-ATPase gene mutations

Vacuolar (H^+)-ATPases are multisubunit enzymatic proton pumps with two domains: the cytoplasmic V1 domain and the transmembrane V0 domain [63, 64]. The cytoplasmic V1 domain hydrolyzes ATP, while the transmembrane V0 translocates protons. The vacuolar (H^+)-ATPase is an ATP-dependent proton pump that acidifies intracellular compartments or transports protons (H^+) across the plasma membrane. It is found on the plasma membrane or in association with various intracellular organelles. The V1 domain is composed of eight types of subunits (A–H), whereas the V0 domain consists of six subunits (a, c, c, d, e and Ac45) [63]. V-ATPase subunits have a spatiotemporal gene expression pattern and are tissue and cell type specific [65]. V-ATPases have been identified in the plasma membranes of various cells, including renal intercalated cells, osteoclasts and macrophages [66]. The subunits reported to be involved in human diseases are the subunit B and subunit a of the V1 and V0 domain, respectively. Subunit a has four isoforms (a1–a4) and subunit B has two (B1 and B2) [66]. The isoforms that are present in a limited number of tissues such as the kidneys are B1 (ATP6V1B1), a4 (ATP6V0A4), G3, C2 and d2 [66]. Besides the kidney, B1 subunits are also present in epididymis, ciliary body of the eye and inner ear. The subunits a4 is present only in epididymis, inner ear and kidney. In the kidney, V-ATPases are localized in the apical membrane of Type A-intercalated cells and in the basolateral membrane of Type B-intercalated cells [66].

V-ATPases have remarkably diverse functions in different cells [63, 66]. Inside the cells, V-ATPases help in normal cell processes of receptor-mediated endocytosis, intracellular membrane trafficking, pro-hormone synthesis, protein degradation and neurotransmitter uptake [67]. They also facilitate cellular entry of various viruses and toxins. In the cellular plasma membrane, they help in renal H^+ secretion, bone resorption and sperm maturation.

Mutations in specific subunits have been described to cause RTA, osteopetrosis and tumor metastasis [63, 68]. Mutations in ATP6V0A4 and ATP6V0B1 gene encoding a4 and B1 subunits have been linked to human inherited dRTA as discussed below [19, 69–71].

V-ATPase: ATP6V1B1 mutations

In 1999, Karet *et al.* [71] first studied the genetic basis of recessive dRTA in a subset of patients with associated sensorineural hearing loss (SNHL). Through genome-wide linkage analysis, they identified the locus of suspected mutations at chromosome 2p13 that was later identified as the ATP6V1B1 gene encoding B1 subunit. They studied 31 unrelated kindred with recessive dRTA. Twenty-seven of them had family history of consanguineous marriage. All reported cases were diagnosed at an early age with the majority diagnosed by age 1. Nineteen cases were identified with ATP6V1B1 mutation. A total of 87% of the cases had hearing impairment. Mean blood pH was 7.2; bicarbonate was 10.9 mmol/L and K⁺ was 3.1 mmol/L. Mean urinary pH was 7.3 consistent with inability to acidify urine. Since blood samples for genetic analysis for most of these patients were collected from all over the world, there was limited information on other tests of urinary acidification but the diagnosis of dRTA on clinical grounds seemed firm.

Joshua *et al.* [72] studied hearing loss in five children with dRTA from three unrelated families. All families had different ATP6V1B1 mutations. Hearing loss was diagnosed between 3 months and 2 years. Audiometric and imaging techniques were used to characterize the hearing loss. The hearing loss was bilateral, asymmetrical, progressive and sometimes had a conductive component. High resolution computed tomography, performed in four patients, showed as the only radiological abnormality, a bilaterally enlarged vestibular aqueduct [72].

Rotatory vertigo has also been described in dRTA. In 2010, Yashima *et al.* [73] reported a patient in whom renal calcification was found at the first month medical screening. Further investigation had led to the diagnosis of distal RTA. The patient had developed bilateral hearing loss by age 3 and had started using hearing aids. Since the age of 4, he had several attacks of rotating vertigo. Fluctuating hearing loss and vertigo were detected during the follow-up.

V-ATPase: ATP6V0A4 mutations

Karet *et al.* [70] studied a subset of recessive dRTA patients with normal hearing and identified a different locus of suspected mutation at chromosome 7q33–34. Through the positional cloning approach, the ATP6V0A1 gene encoding a4 subunit was identified at that locus [70]. Thirteen kindred with normal hearing were studied. All except one had a family history of consanguinity. All of them had presented in early childhood. All had severe metabolic acidosis and hypokalemia with normal renal function. Urinary pH was reported to be >6.5. All had nephrocalcinosis, and with the exception of two, they all had elevated urine calcium. Rickets was present in seven of them. Audiometric evaluation revealed normal hearing prompting the conclusion that the a4 gene mutations may not cause hearing impairment. Saito *et al.* [74] described a 2-month-old Japanese male infant who had presented with vomiting and failure to thrive. The patient had hyperchloremic metabolic acidosis, hypokalemia, a normal serum anion gap, a positive urine anion gap,

nephrocalcinosis and high urine pH. Auditory brain stem response test also revealed normal hearing bilaterally.

Stover *et al.* [75] later described several novel mutations in the ATP6V0A4 gene causing autosomal recessive dRTA. The clinical and biochemical parameters were similar to those described earlier (Table 1). A follow-up of these patients, however, found hearing loss in some at a later age, including one at 33 years and another at 22 [75].

Urinary acidification is primarily controlled in the distal nephron. H⁺-ion secretion is coupled to bicarbonate absorption in the polarized Type A intercalated cells [69]. The V-ATPase present on the apical membrane of these cells are the main H⁺ ion secretory protein [69]. In response to a fall in the blood pH, ATP-powered V-ATPase can increase H⁺-ion secretion by several thousand fold. This secretion is coupled to bicarbonate absorption by the AE1 at the basolateral membrane of these cells (Figure 1). A defect in V-ATPase, therefore, disrupts the ability of the kidney to correct acidosis through acidifying urine [69, 70].

Immunoreactivity has localized B1 and a4 subunits at the apical membrane of Type A intercalated cells [66]. Several mutations causing dRTA have been located to the gene encoding these subunits. Premature termination codons, frameshift mutations and splice site mutations have been described in some, while in others missense mutations were identified.

V-ATPase gene mutations have been shown to display diminished pump activity in the setting of intact pump assembly [6, 76]. In their study of a4 subunit mutation R807Q and G820R, Su *et al.* [77] found that G820R mutation caused a complete loss of phosphofructokinase-1 (PFK-1) binding to a4 subunit without affecting PFK-1 activity, whereas R807Q mutation reduced a4 subunit production rendering V-ATPase inactive. They also found that G820R resulted in the loss of proton transport by 78%, but caused only 36% loss in ATPase activity, which suggested the importance of a4/PFK-1 binding to couple the ATPase activity to proton transport [77].

A study on rat IMCD cells has revealed another possible mechanism, whereby the mutated subunit did

Table 1. Clinical differences between genetic causes of dRTA

| Clinical features | Autosomal dominant (AE1) | Autosomal recessive (AE1) | V-ATPase mutation |
|--------------------|--------------------------|---------------------------|-------------------|
| Types of dRTA | Complete or incomplete | Always complete | Complete |
| Age of onset | Usually late | Usually early | Early |
| Severity of dRTA | Mild | Severe | Severe |
| Hemolytic anemia | Rare | Common | Absent |
| Hypokalemia | Mild | Severe | Severe |
| Polyuria | | Common | Common |
| Plasma bicarbonate | Near normal | Low | Low |
| Nephrocalcinosis | Usually late | Common | Common |
| Hearing loss | Absent | Absent | Early/late onset |
| Urinary pH | >6.5 | >6.5 | >6.5 |

not combine with partially active V-ATPase complexes, but trafficked to the apical membrane in response to cellular acidification and inhibited proton pump activity [78]. It has been suggested that this mechanism might be involved in B1 missense mutation R394Q wherein, unlike the usual autosomal recessive pattern of V-ATPase mutations, a dominant inheritance pattern was described and is extremely rare [6]. Interestingly, two patients were reported with dRTA and SNHL associated with mutations of ATP6V1B1 and ATP6V0A4 who both had medullary sponge kidney, a congenital disease characterized by diffuse ectasia or dilation of precalyceal collecting tubules [79]. The occurrence of dRTA in patients with medullary sponge kidney is generally felt to be an acquired defect in distal acidification that is usually mild. The possibility that a primary inherited defect in ATP6V1B1 and ATP6V0A4 in intercalated cells of the kidney may be involved in some cases deserves consideration based on the two cases reported by Carboni *et al.* [79].

Mouse models of dRTA

In mouse models of genetic ablation of various acid–base transporters, the phenotypic features resemble some of the features of human hereditary distal RTA. Many of the features of patients with AE1 mutation are similar to AE1^{-/-} mutant mice. These mice were noted to have stunted growth and hemolytic anemia with high mortality [80]. Stehberger *et al.* [81] reported that AE1^{-/-} mice developed hyperchloremic metabolic acidosis and produced alkaline urine without bicarbonaturia. Furthermore, nephrocalcinosis, hypercalciuria, hyperphosphaturia and hypocitraturia were also noted. Immunofluorescence microscopy revealed reduced apical localization of aquaporin-2 in the inner medulla of the mutant mice kidney [81]. This was reflected in elevated blood osmolality and low urine osmolality in these mice. Finberg *et al.* [82] generated ATP6V1B1^{-/-} mutant mice and reported that these mice produced alkaline urine. Phenotypically, the mutant mice, however, grew normally and did not develop systemic acidosis on a normal rodent diet. Apical expression of the B2 subunit was increased suggesting compensation, although it failed to correct acidosis when challenged with oral acid [82]. Unlike humans, hypercalciuria, nephrocalcinosis and any skeletal abnormality were absent possibly because metabolic acidosis had not developed. Mice also express the a4 subunit, but knockout mice (ATP6V0A4^{-/-}), to our knowledge, has not been reported yet.

Lewis *et al.* [83] induced null mutation of CA II in a male mouse using *N*-ethyl-*N*-Nitrosourea. The mutation was at the CA II locus on chromosome 3 and was heritable. Several progenies were produced for further study. The mutant mice were significantly smaller. They had lost the ability to acidify urine following NH₄Cl ingestion. Blood bicarbonate was significantly lower than controls. Unlike human cases, osteopetrosis was characteristically absent on skeletal X-rays follow-up. The lack of the Haversian system in rats has been suggested as the reason for

this [83, 84]. Brain and renal calcification were also not identified during the follow-up [83].

Hearing loss and genetic screening considerations

Hearing loss is often seen in autosomal recessive dRTA. Based on the type of hearing loss, the type of mutations can be suspected. Conductive deafness is seen with CA II mutations, whereas SNHL is seen with ATP6V1B1 and ATP6V0A4 mutations. AE1 mutations, by contrast, usually do not have any associated deafness. This is a useful clinical distinguishing feature.

The kidney-specific a4 and B1 subunits of H⁺-ATPase have been identified in the inner ear as well. It is known that pH of endolymph plays an important role in hearing [85]. In the inner ear, endolymphatic pH is maintained by H⁺-ATPase and Cl⁻-HCO₃⁻ exchanger including pendrin. Disruption of their function, such as through mutations, lead to hearing loss [85]. Studies have reported that early SNHL (before the age of 10) occurs in most patients with ATP6V1B1 mutations, whereas late-onset SNHL is seen with ATP6V0A4 mutations [75, 86, 87]. There have been exceptions as noted by Vargas-Poussou *et al.* [88] who studied 39 families with autosomal recessive dRTA and identified V-ATPase mutations in 31 families. Twenty-one of them had ATP6V0A4 mutations, while only 10 had ATP6V1B1 mutations. In eight cases, these two mutations were not identified. Early-onset SNHL was observed in 70% of cases with ATP6V1B1 gene mutations and in 39% of cases with ATP6V0A4 gene mutations. Overall, 53.8% of the cases had ATP6V0A4 mutations and 25.6% of them had ATP6V1B1 mutations. Only 41% had hearing loss at the time of diagnosis. Based on these findings, Vargas-Poussou *et al.* [88] suggested that a genetic screening strategy based only on early or late-onset hearing loss would be misleading and proposed an algorithm for the genetic screening of autosomal recessive dRTA [88]. They suggested that the gene be investigated based on the presence or absence of consanguinity rather than hearing loss. In consanguineous families, homozygous mapping using microsatellite markers at the ATP6V1B1 and ATP6V0A4 loci could identify the mutations, and if inconclusive then ATP6V0A4 gene should be analyzed for mutation as it accounts for most cases of autosomal recessive dRTA [88]. For practical purposes, we think that sensorineural deafness is a useful feature for the clinician to suspect dRTA associated with ATP6V1B1 and ATP6V0A4 mutations. Although the presence of deafness and the type was suggested as an important clue to the genetic lesion underlying hereditary dRTA, it is now becoming more clear that this is only useful as an initial diagnostic impression. The findings that less than 50% of the hereditary RTA cases develop deafness and that most of them might develop deafness later on in life leaves genetic tests as the only definitive approach in identifying the defect accurately and early on in life. This is not to say, however, that deafness is not an important clue to the presence and the type of hereditary distal RTA. Faced with the presence of sensorineural

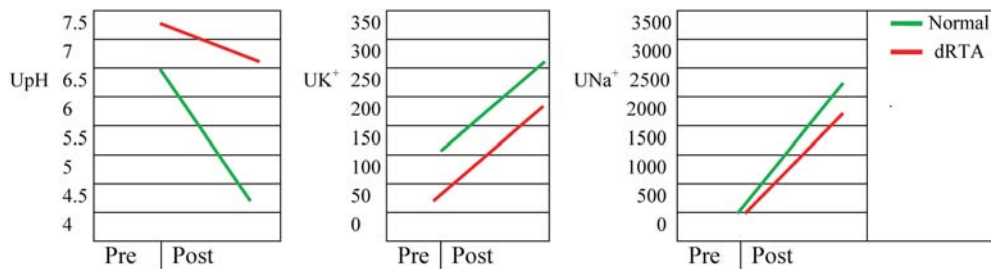


Fig. 3. Furosemide test result in normal and patients with dRTA. Adapted from Batlle [39].

deafness, the genetic diagnosis should focus on ATP6V1B1 and ATP6V0A4 mutations in this order or both.

Diagnostic evaluation of distal RTA

The diagnosis of distal RTA should be suspected whenever a hyperchloremic metabolic acidosis is present without any obvious cause (i.e. diarrhea) in the setting of relatively normal GFR [2]. All that is usually needed for confirmation is an inappropriately low rate of acid excretion and information on urine pH. The urine pH is typically inappropriately high in the classic form (distal or Type 1 RTA), whereas it is low in Type 4 distal RTA (not discussed in this review).

Ammonium is the most important component of acid excretion in the presence of metabolic acidosis, and thus one has either to measure it directly or estimate it by calculating the urine anion gap [89]. In patients with a hyperchloremic acidosis, the urine anion gap is helpful in determining whether the acidosis is due to a renal or extrarenal etiology, with the caveats discussed below [89]. The principle is similar to that of the plasma anion gap, namely, that the sum of all cations and anions must be equal. Thus,

$$\begin{aligned} [\text{Cl}^-] + [\text{HCO}_3^-] + [\text{unmeasured anions}] \\ = [\text{Na}^+] + [\text{K}^+] + [\text{unmeasured cations}] \end{aligned}$$

The unmeasured anions include sulfate, phosphate and organic anions. Cations not routinely measured include NH_4^+ , Ca^{2+} and Mg^{2+} .

The urine anion gap will be low (usually a negative value) if there is a decrease in unmeasured anions or an increase in unmeasured cations (e.g. NH_4^+). The urine anion gap will be increased (usually a positive value) if there is an increase in unmeasured anions or a decrease in unmeasured cations. Because the concentrations of unmeasured anions in the urine do not change notably and because NH_4^+ is the major unmeasured cation in the presence of metabolic acidosis, the urine anion gap is a useful estimate of urine $[\text{NH}_4^+]$ in this setting. Patients with an acidification defect typically have a positive gap (because NH_4^+ excretion is inappropriately low), whereas in diarrheal states (provided that distal Na^+ delivery is adequate)

the gap is negative, reflecting the fact that NH_4^+ excretion is not impaired [89]. In proximal RTA, the urine anion gap is negative (provided plasma $[\text{HCO}_3^-]$ is low) because distal acidification is normal.

Along with measurement of urine electrolytes and calculation of the anion gap, urine pH should be measured to assess the ability of the collecting duct to acidify the urine. Urine pH can be evaluated during spontaneous metabolic acidosis or after administration of an acidifying salt. It can also be assessed by the infusion of sodium sulfate or after giving furosemide (Figure 3). Therefore, provocative tests assess Na^+ -dependent acidification and can provide additional useful mechanistic information [39, 90]. These agents increase distal Na^+ delivery, thereby enhancing the negative transepithelial potential in the collecting duct and stimulating H^+ and K^+ secretion. The role of furosemide can be more clearly exemplified by reversing its sodium delivery effect through the concomitant use of amiloride as shown in Figure 4. A reduction in urine pH and an increase in K^+ excretion after the administration of either of the above agents indicate a normal response to this enhanced electronegativity. It must be recognized, however, that the evidence obtained from these maneuvers is indirect and may be sometimes subject to different interpretations.

The theoretical features of urine acidification associated with the different types of transporter defects leading to

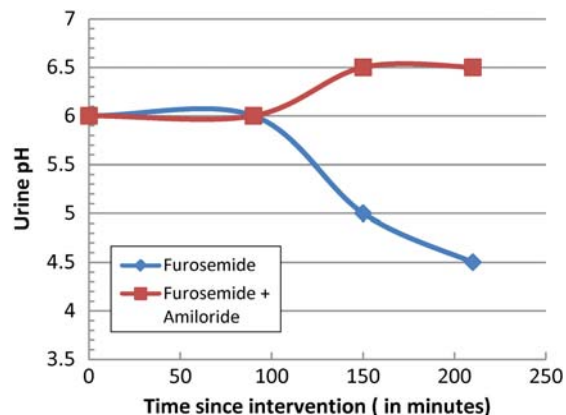


Fig. 4. The effects of furosemide and furosemide + amiloride on urinary acidification in four normal subjects. Adapted from Batlle [39].

dRTA are shown in Figures 5 and 6. There is very limited information in this regard and, therefore, some of these features are theoretical.

Therapy of distal RTA

The aims of treatment of classic RTA are not only to correct the biochemical abnormalities, but also to improve growth in children, and to prevent kidney stones and the skeletal abnormalities associated with the disease. Another aim is to prevent the progression of nephrocalcinosis, which, in rare cases, leads to chronic renal failure. Alkali therapy should provide an adequate base to balance daily acid production.

Because children have a higher rate of acid production, they require higher doses of alkali. A mixture of sodium and potassium citrate salts is recommended. All patients with classic distal RTA have associated hypocitraturia, but children with this disorder also have

calcium oxalate and calcium phosphate excretion rates that approach saturation, which makes them more susceptible to nephrolithiasis. Citrate salts correct the hypocitraturia and prevent nephrolithiasis [91]. This organic anion also corrects the metabolic acidosis, thereby decreasing urine calcium excretion. Infants require as much as 5–8 mEq per kg of citrate or HCO_3^- per kg body weight, whereas adults require only about 0.5–1 mEq per kg body weight. Patients with hereditary distal RTA require lifetime treatment. The prognosis is excellent if the diagnosis is made early and appropriate amounts of alkali are continuously administered. However, alkali therapy has no effect on hearing impairment in those patients who have either sensorineural or conductive deafness [92]. Potassium supplementation is needed in the majority of patient with hypokalemic hereditary distal RTA. While systemic studies are not available, the use of amiloride 10 mg once a day, in our experience, is very useful to conserve potassium and, therefore, reduces the amount of potassium supplementation.

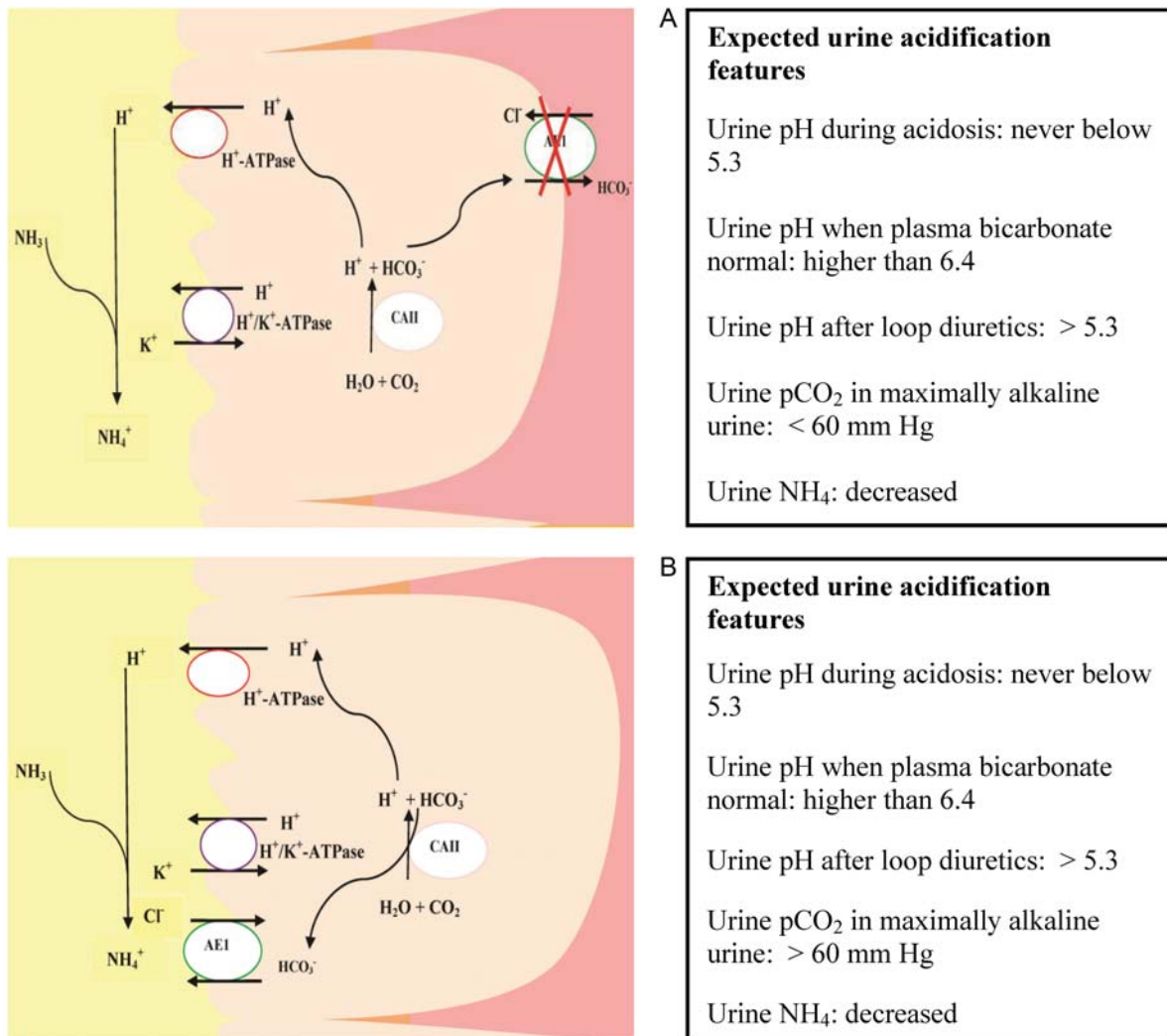


Fig. 5. Expected urine acidification features in the case of (A) the lack of function of kAE1 transporter and (B) mistargeting of kAE1 transporter to the apical membrane.

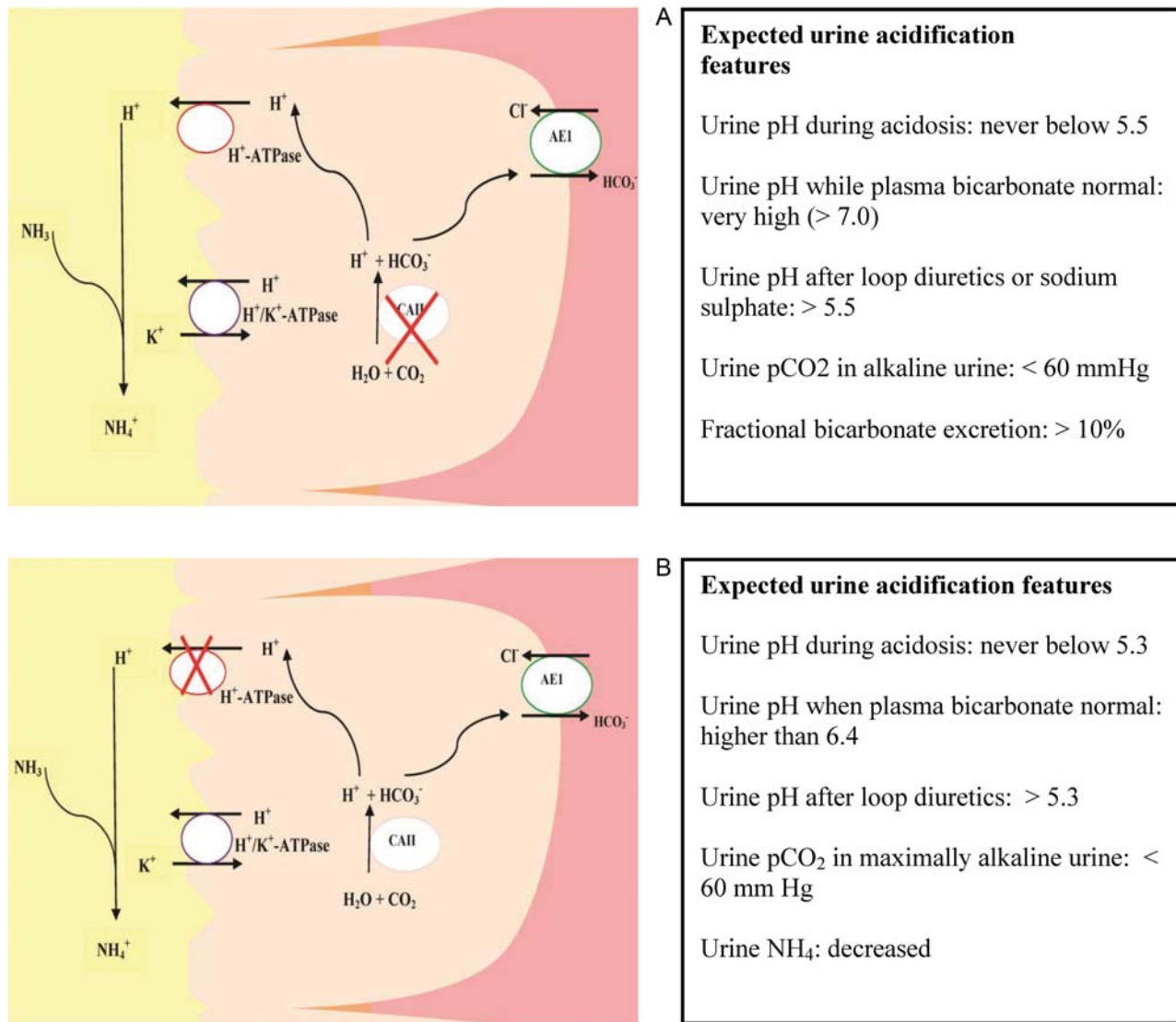


Fig. 6. Expected urine acidification features in the case of (A) the lack of function of CA II in the α -intercalated cells and (B) the lack of function of H⁺-ATPase in the α -intercalated cells.

Conflict of interest statement. None declared.

References

- Battle D, Kurtzman NA. Distal renal tubular acidosis: pathogenesis and classification. *Am J Kidney Dis* 1982; 1: 328–344
- Battle D, Ghanekar H, Jain S *et al*. Hereditary distal renal tubular acidosis: new understandings. *Annu Rev Med* 2001; 52: 471–484
- Rodriguez Soriano J. Renal tubular acidosis: the clinical entity. *J Am Soc Nephrol* 2002; 13: 2160–2170
- McSherry E, Sebastian A, Morris RC, Jr. Renal tubular acidosis in infants: the several kinds, including bicarbonate-wasting, classic renal tubular acidosis. *J Clin Invest* 1972; 51: 499–514
- Fry AC, Karet FE. Inherited renal acidoses. *Physiology (Bethesda)* 2007; 22: 202–211
- Alper SL. Familial renal tubular acidosis. *J Nephrol* 2010; 23(Suppl 16): S57–S76
- Rubini ME. Water excretion in potassium-deficient man. *J Clin Invest* 1961; 40: 2215–2224
- Alper SL. Molecular physiology and genetics of Na⁺-independent SLC4 anion exchangers. *J Exp Biol* 2009; 212: 1672–1683
- Battle D, Moorthi KM, Schlueter W *et al*. Distal renal tubular acidosis and the potassium enigma. *Semin Nephrol* 2006; 26: 471–478
- Sebastian A, Schambelan M, Lindenfeld S *et al*. Amelioration of metabolic acidosis with fludrocortisone therapy in hyporeninemic hypoaldosteronism. *N Engl J Med* 1977; 297: 576–583
- Battle DC, Arruda JA, Kurtzman NA. Hyperkalemic distal renal tubular acidosis associated with obstructive uropathy. *N Engl J Med* 1981; 304: 373–380
- Battle D, Itsarayoungyuen K, Arruda JA *et al*. Hyperkalemic hyperchloremic metabolic acidosis in sickle cell hemoglobinopathies. *Am J Med* 1982; 72: 188–192
- Battle DC. Hyperkalemic hyperchloremic metabolic acidosis associated with selective aldosterone deficiency and distal renal tubular acidosis. *Semin Nephrol* 1981; 1: 260–273
- Alper SL, Darman RB, Chernova MN *et al*. The AE gene family of Cl/HCO₃⁻ exchangers. *J Nephrol* 2002; 15(Suppl 5):S41–S53
- Wagner S, Vogel R, Lietzke R *et al*. Immunohistochemical characterization of a band 3-like anion exchanger in collecting duct of human kidney. *Am J Physiol* 1987; 253: F213–F221

16. Schuster VL. Function and regulation of collecting duct intercalated cells. *Annu Rev Physiol* 1993; 55: 267–288
17. Alper SL, Natale J, Gluck S *et al.* Subtypes of intercalated cells in rat kidney collecting duct defined by antibodies against erythroid band 3 and renal vacuolar H⁺-ATPase. *Proc Natl Acad Sci USA* 1989; 86: 5429–5433
18. Bruce LJ, Cope DL, Jones GK *et al.* Familial distal renal tubular acidosis is associated with mutations in the red cell anion exchanger (Band 3, AE1) gene. *J Clin Invest* 1997; 100: 1693–1707
19. Karet FE, Gainza FJ, Gyory AZ *et al.* Mutations in the chloride-bicarbonate exchanger gene AE1 cause autosomal dominant but not autosomal recessive distal renal tubular acidosis. *Proc Natl Acad Sci USA* 1998; 95: 6337–6342
20. Bruce LJ, Wrong O, Toye AM *et al.* Band 3 mutations, renal tubular acidosis and South-East Asian ovalocytosis in Malaysia and Papua New Guinea: loss of up to 95% band 3 transport in red cells. *Biochem J* 2000; 350(Pt 1): 41–51
21. Tanphaichitr VS, Sumboonnanonda A, Ideguchi H *et al.* Novel AE1 mutations in recessive distal renal tubular acidosis. Loss-of-function is rescued by glycophorin A. *J Clin Invest* 1998; 102: 2173–2179
22. Kittanakom S, Cordat E, Akkarapatumwong V *et al.* Trafficking defects of a novel autosomal recessive distal renal tubular acidosis mutant (S773P) of the human kidney anion exchanger (kAE1). *J Biol Chem* 2004; 279: 40960–40971
23. Cheidde L, Vieira TC, Lima PR *et al.* A novel mutation in the anion exchanger 1 gene is associated with familial distal renal tubular acidosis and nephrocalcinosis. *Pediatrics* 2003; 112: 1361–1367
24. Jarolim P, Shayakul C, Prabakaran D *et al.* Autosomal dominant distal renal tubular acidosis is associated in three families with heterozygosity for the R589H mutation in the AE1 (band 3) Cl⁻/HCO₃⁻ exchanger. *J Biol Chem* 1998; 273: 6380–6388
25. Shmukler BE, Kedar PS, Warang P *et al.* Hemolytic anemia and distal renal tubular acidosis in two Indian patients homozygous for SLC4A1/AE1 mutation A858D. *Am J Hematol* 2010; 85: 824–828
26. Jamard B, Allard J, Caron P *et al.* Distal renal tubular acidosis and ovalocytosis: a case report. *Osteoporos Int* 2008; 19: 119–122
27. Chang YH, Shaw CF, Jian SH *et al.* Compound mutations in human anion exchanger 1 are associated with complete distal renal tubular acidosis and hereditary spherocytosis. *Kidney Int* 2009; 76: 774–783
28. Ribeiro ML, Alloisio N, Almeida H *et al.* Severe hereditary spherocytosis and distal renal tubular acidosis associated with the total absence of band 3. *Blood* 2000; 96: 1602–1604
29. Toye AM, Williamson RC, Khanfar M *et al.* Band 3 Courcouronnes (Ser667Phe): a trafficking mutant differentially rescued by wild-type band 3 and glycophorin A. *Blood* 2008; 111: 5380–5389
30. Chu C, Woods N, Sawasdee N *et al.* Band 3 Edmonton I, a novel mutant of the anion exchanger 1 causing spherocytosis and distal renal tubular acidosis. *Biochem J* 2009; 426: 379–388
31. Choo KE, Nicoli TK, Bruce LJ *et al.* Recessive distal renal tubular acidosis in Sarawak caused by AE1 mutations. *Pediatr Nephrol* 2006; 21: 212–217
32. Quilty JA, Li J, Reithmeier RA. Impaired trafficking of distal renal tubular acidosis mutants of the human kidney anion exchanger kAE1. *Am J Physiol Renal Physiol* 2002; 282: F810–F820
33. Cordat E, Kittanakom S, Yenchitsomanus PT *et al.* Dominant and recessive distal renal tubular acidosis mutations of kidney anion exchanger 1 induce distinct trafficking defects in MDCK cells. *Traffic* 2006; 7: 117–128
34. Williamson RC, Toye AM. Glycophorin A: Band 3 aid. *Blood Cells Mol Dis* 2008; 41: 35–43
35. Toye AM, Banting G, Tanner MJ. Regions of human kidney anion exchanger 1 (kAE1) required for basolateral targeting of kAE1 in polarized kidney cells: mis-targeting explains dominant renal tubular acidosis (dRTA). *J Cell Sci* 2004; 117: 1399–1410
36. Rungroj N, Devonald MA, Cuthbert AW *et al.* A novel missense mutation in AE1 causing autosomal dominant distal renal tubular acidosis retains normal transport function but is mistargeted in polarized epithelial cells. *J Biol Chem* 2004; 279: 13833–13838
37. Fry AC, Su Y, Yiu V *et al.* Mutation conferring apical-targeting motif on AE1 exchanger causes autosomal dominant distal RTA. *J Am Soc Nephrol* 2012; 23: 1238–1249
38. Sly WS, Hewett-Emmett D, Whyte MP *et al.* Carbonic anhydrase II deficiency identified as the primary defect in the autosomal recessive syndrome of osteopetrosis with renal tubular acidosis and cerebral calcification. *Proc Natl Acad Sci USA* 1983; 80: 2752–2756
39. Battle DC. Segmental characterization of defects in collecting tubule acidification. *Kidney Int* 1986; 30: 546–554
40. Schwartz GJ, Tsuruoka S, Vijayakumar S *et al.* Acid incubation reverses the polarity of intercalated cell transporters, an effect mediated by hensin. *J Clin Invest* 2002; 109: 89–99
41. Purkerson JM, Tsuruoka S, Suter DZ *et al.* Adaptation to metabolic acidosis and its recovery are associated with changes in anion exchanger distribution and expression in the cortical collecting duct. *Kidney Int* 2010; 78: 993–1005
42. Gao X, Eladari D, Leviel F *et al.* Deletion of hensin/DMBT1 blocks conversion of beta- to alpha-intercalated cells and induces distal renal tubular acidosis. *Proc Natl Acad Sci USA* 2010; 107: 21872–21837
43. Breton S. The cellular physiology of carbonic anhydrases. *JOP* 2001; 2: 159–164
44. Baird TT, Jr, Waheed A, Okuyama T *et al.* Catalysis and inhibition of human carbonic anhydrase IV. *Biochemistry* 1997; 36: 2669–2678
45. Schwartz GJ. Physiology and molecular biology of renal carbonic anhydrase. *J Nephrol* 2002; 15(Suppl 5): S61–S74
46. Purkerson JM, Schwartz GJ. The role of carbonic anhydrases in renal physiology. *Kidney Int* 2007; 71: 103–115
47. Sly WS, Sato S, Zhu XL. Evaluation of carbonic anhydrase isozymes in disorders involving osteopetrosis and/or renal tubular acidosis. *Clin Biochem* 1991; 24: 311–318
48. Shah GN, Bonapace G, Hu PY *et al.* Carbonic anhydrase II deficiency syndrome (osteopetrosis with renal tubular acidosis and brain calcification): novel mutations in CA2 identified by direct sequencing expand the opportunity for genotype-phenotype correlation. *Hum Mutat* 2004; 24: 272
49. Fathallah DM, Bejaoui M, Lepaslier D *et al.* Carbonic anhydrase II (CA II) deficiency in Maghrebian patients: evidence for founder effect and genomic recombination at the CA II locus. *Hum Genet* 1997; 99: 634–637
50. Hu PY, Roth DE, Skaggs LA *et al.* A splice junction mutation in intron 2 of the carbonic anhydrase II gene of osteopetrosis patients from Arabic countries. *Hum Mutat* 1992; 1: 288–292
51. Fathallah DM, Bejaoui M, Sly WS *et al.* A unique mutation underlying carbonic anhydrase II deficiency syndrome in patients of Arab descent. *Hum Genet* 1994; 94: 581–582
52. Bolt RJ, Wennink JM, Verbeke JI *et al.* Carbonic anhydrase type II deficiency. *Am J Kidney Dis* 2005; 46: A50, e71–e73
53. Whyte MP, Murphy WA, Fallon MD *et al.* Osteopetrosis, renal tubular acidosis and basal ganglia calcification in three sisters. *Am J Med* 1980; 69: 64–74
54. Strisciuglio P, Hu PY, Lim EJ *et al.* Clinical and molecular heterogeneity in carbonic anhydrase II deficiency and prenatal diagnosis in an Italian family. *J Pediatr* 1998; 132: 717–720
55. Guibaud P, Larbre F, Freycon MT *et al.* Osteopetrosis and renal tubular acidosis. 2 cases of this association in a sibship. *Arch Fr Pediatr* 1972; 29: 269–286
56. Vainsel M, Fondou P, Cadranel S *et al.* Osteopetrosis associated with proximal and distal tubular acidosis. *Acta Paediatr Scand* 1972; 61: 429–434
57. Borthwick KJ, Kandemir N, Topaloglu R *et al.* A phenocopy of CAII deficiency: a novel genetic explanation for inherited infantile osteopetrosis with distal renal tubular acidosis. *J Med Genet* 2003; 40: 115–121
58. Muzalef A, Alshehri M, Al-Abidi A *et al.* Marble brain disease in two Saudi Arabian siblings. *Ann Trop Paediatr* 2005; 25: 213–218
59. Ismail EA, Abul Saad S, Sabry MA. Nephrocalcinosis and urolithiasis in carbonic anhydrase II deficiency syndrome. *Eur J Pediatr* 1997; 156: 957–962

60. Lotan D, Eisenkraft A, Jacobsson JM *et al.* Clinical and molecular findings in a family with the carbonic anhydrase II deficiency syndrome. *Pediatr Nephrol* 2006; 21: 423–426
61. Zakzouk SM, Sobki SH, Mansour F *et al.* Hearing impairment in association with distal renal tubular acidosis among Saudi children. *J Laryngol Otol* 1995; 109: 930–934
62. Blair HC, Teitelbaum SL, Ghiselli R *et al.* Osteoclastic bone resorption by a polarized vacuolar proton pump. *Science* 1989; 245: 855–857
63. Toei M, Saum R, Forgac M. Regulation and isoform function of the V-ATPases. *Biochemistry* 2010; 49: 4715–4723
64. Valles P, Batlle D. Kidney vacuolar H⁺-ATPase: physiology and regulation. H⁺-ATPase activated by glucose; a possible link to diabetic complications. Pan Stanford Publishing, 2012
65. Miranda KC, Karet FE, Brown D. An extended nomenclature for mammalian V-ATPase subunit genes and splice variants. *PLoS One* 2010; 5: e9531
66. Nishi T, Forgac M. The vacuolar (H⁺)-ATPases—nature's most versatile proton pumps. *Nat Rev Mol Cell Biol* 2002; 3: 94–103
67. Gu F, Gruenberg J. ARF1 regulates pH-dependent COP functions in the early endocytic pathway. *J Biol Chem* 2000; 275: 8154–8160
68. Hinton A, Sennoune SR, Bond S *et al.* Function of a subunit isoforms of the V-ATPase in pH homeostasis and *in vitro* invasion of MDA-MB231 human breast cancer cells. *J Biol Chem* 2009; 284: 16400–16408
69. Wagner CA, Finberg KE, Breton S *et al.* Renal vacuolar H⁺-ATPase. *Physiol Rev* 2004; 84: 1263–1314
70. Karet FE, Finberg KE, Nayir A *et al.* Localization of a gene for autosomal recessive distal renal tubular acidosis with normal hearing (rdRTA2) to 7q33–34. *Am J Hum Genet* 1999; 65: 1656–1665
71. Karet FE, Finberg KE, Nelson RD *et al.* Mutations in the gene encoding B1 subunit of H⁺-ATPase cause renal tubular acidosis with sensorineural deafness. *Nat Genet* 1999; 21: 84–90
72. Joshua B, Kaplan DM, Raveh E *et al.* Audiometric and imaging characteristics of distal renal tubular acidosis and deafness. *J Laryngol Otol* 2008; 122: 193–198
73. Yashima T, Noguchi Y, Kawashima Y *et al.* Novel ATP6V1B1 mutations in distal renal tubular acidosis and hearing loss. *Acta Otolaryngol* 2010; 130: 1002–1008
74. Saito T, Hayashi D, Shibata S *et al.* Novel compound heterozygous ATP6V0A4 mutations in an infant with distal renal tubular acidosis. *Eur J Pediatr* 2010; 169: 1271–1273
75. Stover EH, Borthwick KJ, Bavalia C *et al.* Novel ATP6V1B1 and ATP6V0A4 mutations in autosomal recessive distal renal tubular acidosis with new evidence for hearing loss. *J Med Genet* 2002; 39: 796–803
76. Fuster DG, Zhang J, Xie XS *et al.* The vacuolar-ATPase B1 subunit in distal tubular acidosis: novel mutations and mechanisms for dysfunction. *Kidney Int* 2008; 73: 1151–1158
77. Su Y, Blake-Palmer KG, Sorrell S *et al.* Human H⁺ ATPase a4 subunit mutations causing renal tubular acidosis reveal a role for interaction with phosphofruktokinase-1. *Am J Physiol Renal Physiol* 2008; 295: F950–F958
78. Yang Q, Li G, Singh SK *et al.* Vacuolar H⁺-ATPase B1 subunit mutations that cause inherited distal renal tubular acidosis affect proton pump assembly and trafficking in inner medullary collecting duct cells. *J Am Soc Nephrol* 2006; 17: 1858–1866
79. Carboni I, Andreucci E, Caruso MR *et al.* Medullary sponge kidney associated with primary distal renal tubular acidosis and mutations of the H⁺-ATPase genes. *Nephrol Dial Transplant* 2009; 24: 2734–2738
80. Southgate CD, Chishti AH, Mitchell B *et al.* Targeted disruption of the murine erythroid band 3 gene results in spherocytosis and severe haemolytic anaemia despite a normal membrane skeleton. *Nat Genet* 1996; 14: 227–230
81. Stehberger PA, Shmukler BE, Stuart-Tilley AK *et al.* Distal renal tubular acidosis in mice lacking the AE1 (band3) Cl⁻/HCO₃⁻ exchanger (slc4a1). *J Am Soc Nephrol* 2007; 18: 1408–1418
82. Finberg KE, Wagner CA, Bailey MA *et al.* The B1-subunit of the H⁽⁺⁾ ATPase is required for maximal urinary acidification. *Proc Natl Acad Sci USA* 2005; 102: 13616–13621
83. Lewis SE, Erickson RP, Barnett LB *et al.* N-ethyl-N-nitrosourea-induced null mutation at the mouse Car-2 locus: an animal model for human carbonic anhydrase II deficiency syndrome. *Proc Natl Acad Sci USA* 1988; 85: 1962–1966
84. Marks SC, Jr. Pathogenesis of osteopetrosis in the microphthalmic mouse: reduced bone resorption. *Am J Anat* 1977; 149: 269–275
85. Lang F, Vallon V, Knipper M *et al.* Functional significance of channels and transporters expressed in the inner ear and kidney. *Am J Physiol Cell Physiol* 2007; 293: C1187–C1208
86. Ruf R, Rensing C, Topaloglu R *et al.* Confirmation of the ATP6B1 gene as responsible for distal renal tubular acidosis. *Pediatr Nephrol* 2003; 18: 105–109
87. Smith AN, Skaug J, Choate KA *et al.* Mutations in ATP6N1B, encoding a new kidney vacuolar proton pump 116-kD subunit, cause recessive distal renal tubular acidosis with preserved hearing. *Nat Genet* 2000; 26: 71–75
88. Vargas-Poussou R, Houillier P, Le Pottier N *et al.* Genetic investigation of autosomal recessive distal renal tubular acidosis: evidence for early sensorineural hearing loss associated with mutations in the ATP6V0A4 gene. *J Am Soc Nephrol* 2006; 17: 1437–1443
89. Batlle DC, Hizon M, Cohen E *et al.* The use of the urinary anion gap in the diagnosis of hyperchloremic metabolic acidosis. *N Engl J Med* 1988; 318: 594–599
90. Schlueter W, Keilani T, Hizon M *et al.* On the mechanism of impaired distal acidification in hyperkalemic renal tubular acidosis: evaluation with amiloride and bumetanide. *J Am Soc Nephrol* 1992; 3: 953–964
91. Domrongkitchaiporn S, Khositseth S, Stitchantrakul W *et al.* Dosage of potassium citrate in the correction of urinary abnormalities in pediatric distal renal tubular acidosis patients. *Am J Kidney Dis* 2002; 39: 383–391
92. Bajaj G, Quan A. Renal tubular acidosis and deafness: report of a large family. *Am J Kidney Dis* 1996; 27: 880–882

Received for publication: 26.6.2012; Accepted in revised form: 14.8.2012