

 Open access • Journal Article • DOI:10.1259/BJR.72.860.10624337

Geometry of proximal femur in the prediction of hip fracture in osteoporotic women

— [Source link](#) 

S Gnudi, [Claudio Ripamonti](#), [G Gualtieri](#), [N. Malavolta](#)

Published on: 01 Aug 1999 - [British Journal of Radiology](#) (Br J Radiol)

Topics: [Femoral neck](#), [Hip fracture](#), [Femur](#), [Photon absorptiometry](#) and [Hip bone](#)

Related papers:

- [Simple measurement of femoral geometry predicts hip fracture: The study of osteoporotic fractures](#)
- [Femoral Bone Mineral Density, Neck-Shaft Angle and Mean Femoral Neck Width as Predictors of Hip Fracture in Men and Women.](#)
- [Femoral neck geometry and radiographic signs of osteoporosis as predictors of hip fracture](#)
- [Proximal femur geometry to detect and distinguish femoral neck fractures from trochanteric fractures in postmenopausal women](#)
- [Improving risk assessment: hip geometry, bone mineral distribution and bone strength in hip fracture cases and controls. The EPOS study. European Prospective Osteoporosis Study](#)

Share this paper:    

View more about this paper here: <https://typeset.io/papers/geometry-of-proximal-femur-in-the-prediction-of-hip-fracture-10au7ujbv3>

THE GEOMETRY OF THE PROXIMAL FEMUR

Zoltán Csernátony, Sándor Manó, László Kiss

Department of Orthopaedic Surgery, Medical and Health Science Center,
University of Debrecen

csz@med.unideb.hu

Abstract

The authors performed radiological and morphological examinations on 86 femurs from fresh cadavers, and present their results to aid the planning of companies manufacturing hip endoprosthesis.

Keywords: geometry, femur, Singh index, Barnett–Nordin index

Introduction

Total hip replacement began its conquest with the low friction arthroplasty principle and implant developed in 1961 by Sir John Charnley. From then on orthopedic surgery, besides numerous other beneficial surgeries, gave such an advantageous solution to patients suffering from hip pain that the prestige of the specialty was greatly increased. It is presently estimated that there are about 3-4.5 million patients benefitting from total hip replacement yearly. In the past 50 years, various implants appeared on the market. During this half century, there were enormous developments in metallurgy and in the chemical industry especially in plastics, material, and machinery, not to mention the advances in surgery itself. Nowadays many basic concepts are used in replacement surgery thus patients are operated along similar trends worldwide. At the same time, the further development of prosthetic replacement has not ended.

About two decades ago, industrial technology offered a new opportunity with the manufacture of custom made prostheses. For a few years, the specialty was unable to come to terms with what the future will bring. The problem was soon answered. The solution

was to use off-the-shelf prostheses in routine cases, thereby shaping the patient to the implant and not shaping the implant to the patient. For this the size differential between the implants became more refined. However, it must be kept in mind that within certain limits the geometry can vary in different populations.

Methods and Materials

In our present work, we performed direct and radiological examination of 86 proximal femurs from 43 cadavers from Hajdú-Bihar County. The femurs were removed with the permission of the University of Debrecen, Medical Health and Science Center Regional and Institutional Ethics Committee. The deceased were all Caucasian. The measurement points and characteristics are shown in *Figure 1*. The Singh⁵ and Barnett-Nordin indices^{1,3} were also measured, the latter one in an extended form, 10, 20 and 30 centimeters below the lesser trochanter in both the AP and lateral views².

In *Figure 1.*, for the sake of simplicity, the calculation method used to calculate the index 20 centimeters from the tip of the greater

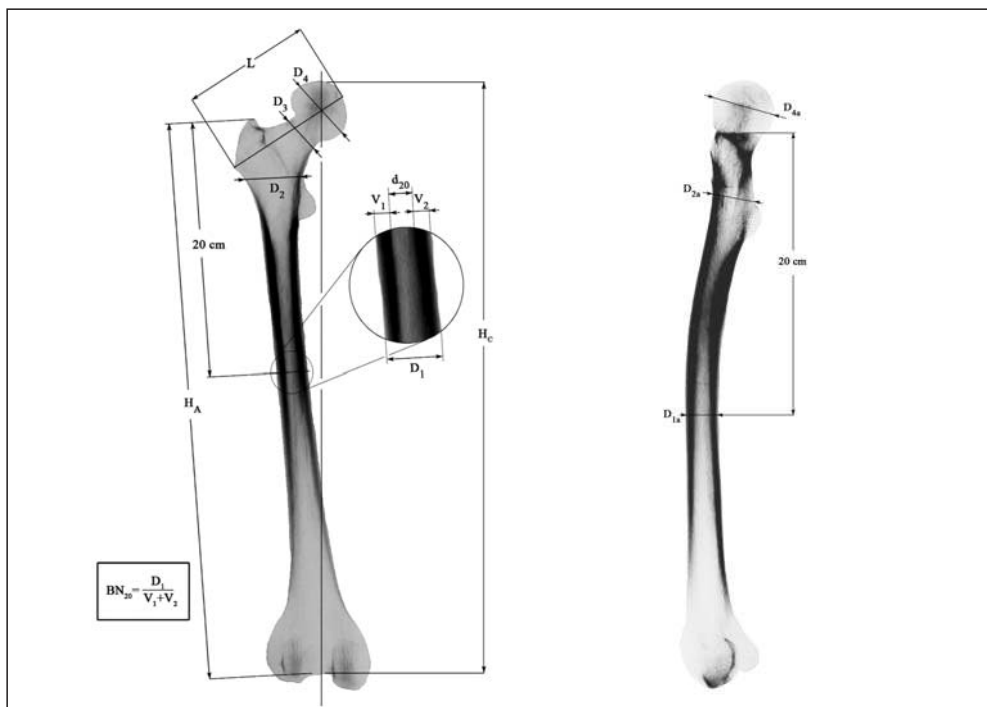


Figure 1. The measurement points and characteristics with the Barnett–Nordin index

trochanter (BN_{20}) is demonstrated. We divided the diameter of the femur with the sum of the thickness of the outer and inner cortical bone.

The Singh index is a less exact, but practically useful radiological method to determine the level of osteoporosis which is based on the progressive disappearance of the bone scaffolds in the proximal femur (Figure 2).

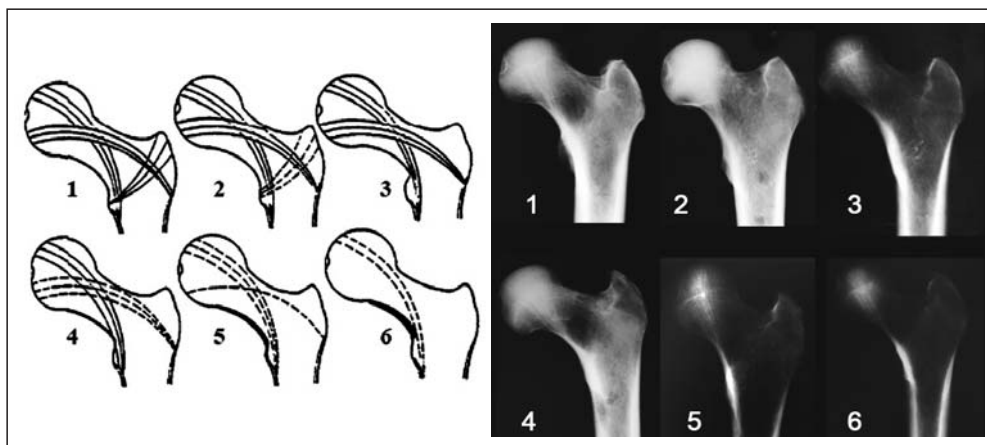


Figure 2. The interpretation of the Singh index

Results

The measurement data are shown in Table I.

No	Age (year)	L (mm)	D ₁ (mm)	D _{1a} (mm)	D ₂ (mm)	D _{2a} (mm)	D ₃ (mm)	D ₄ (mm)	D _{4a} (mm)	d ₁₀ (mm)	d ₂₀ (mm)	S	BN ₁₀	BN ₂₀	BN ₃₀
1.	49	116	34	30	41	44	37	57	59	25	14	6	0.39	0.59	0.39
2.	49	117	38	31	45	43	38	57	59	19	18	6	0.45	0.57	0.37
3.	73	95	24	27	39	30	30	44	45	15	10	4	0.50	0.58	0.26
4.	73	93	25	28	37	30	32	44	45	17	19	5	0.61	0.56	0.37
5.	86	98	31	20	40	34	31	46	48	23	12	4	0.34	0.61	0.27
6.	86	96	32	22	42	37	32	47	48	19	15	4	0.44	0.53	0.33
7.	81	95	24	23	39	32	31	48	48	12	12	5	0.54	0.58	0.35
8.	81	93	23	23	41	31	30	46	38	11	10	3	0.58	0.57	0.22
9.	83	100	26	27	49	38	37	53	55	20	11	5	0.41	0.58	0.14
10.	83	98	26	27	46	42	37	54	54	24	15	5	0.33	0.42	0.11
11.	83	106	30	30	47	48	37	55	53	21	15	4	0.42	0.50	0.28
12.	83	103	30	29	48	47	34	53	54	20	15	5	0.41	0.50	0.24
13.	46	101	28	25	43	34	27	46	47	20	13	4	0.39	0.54	0.37
14.	46	101	28	24	44	35	28	46	47	23	9	4	0.49	0.61	0.30
15.	82	110	33	32	52	42	39	53	56	27	17	2	0.36	0.49	0.20
16.	82	113	32	34	52	46	38	54	56	24	16	2	0.39	0.50	0.19
17.	55	104	31	31	43	40	37	49	52	19	15	4	0.47	0.52	0.27
18.	55	101	31	32	47	38	34	50	50	20	13	3	0.47	0.58	0.26
19.	41	103	35	30	42	37	31	47	49	13	8	4	0.54	0.68	0.30
20.	41	102	24	30	39	36	31	48	49	13	7	4	0.54	0.63	0.29
21.	60	102	29	26	44	41	33	50	51	20	16	4	0.39	0.45	0.15
22.	60	100	27	26	44	41	34	51	53	21	16	4	0.36	0.41	0.13
23.	78	102	29	28	43	38	32	49	50	17	13	5	0.46	0.55	0.25
24.	78	100	28	29	43	37	33	48	52	19	12	5	0.42	0.57	0.36
25.		89	29	24	43	37	34	–	–	16	11	5	0.48	0.62	0.22
26.		90	31	25	40	38	32	45	45	17	14	5	0.50	0.55	0.23
27.	61	113	28	28	45	30	34	52	55	17	9	4	0.50	0.68	0.35
28.	61	110	29	30	44	36	33	52	54	18	10	4	0.47	0.66	0.28
29.	72	106	35	25	47	39	33	53	53	18	13	4	0.51	0.63	0.30
30.	72	102	32	26	47	40	30	50	51	20	13	4	0.46	0.59	0.28
31.	64	87	25	26	38	32	29	44	44	16	10	2	0.39	0.60	0.13
32.	64	85	27	25	40	34	30	43	43	15	12	1	0.44	0.56	0.16
33.	46	89	24	24	38	28	28	43	44	13	11	3	0.54	0.54	0.13
34.	46	89	25	26	38	28	29	42	43	14	12	3	0.50	0.52	0.16
35.	71	106	30	26	44	35	31	49	50	22	12	4	0.37	0.60	0.30
36.	71	108	30	23	42	34	34	50	50	18	13	4	0.51	0.57	0.41
37.	53	105	34	28	50	40	45	53	53	18	11	6	0.50	0.57	0.42
38.	53	104	34	27	49	33	35	53	53	18	14	5	0.49	0.59	0.36
39.	42	106	33	30	47	40	35	54	55	24	18	4	0.35	0.46	0.45
40.	42	103	33	29	48	39	34	53	54	25	20	4	0.34	0.39	0.40
41.	74	107	28	28	48	40	35	50	53	15	11	4	0.53	0.61	0.32
42.	74	106	28	29	48	42	34	51	52	15	11	4	0.53	0.61	0.26
43.	42	101	29	29	46	35	37	49	51	18	14	6	0.46	0.52	0.27
44.	42	98	28	29	48	37	34	49	51	20	13	6	0.38	0.54	0.29
45.	69	96	29	26	41	37	27	44	45	23	17	4	0.30	0.41	0.32
46.	69	96	28	28	41	38	26	44	45	24	15	4	0.29	0.46	0.29
47.	88	88	25	29	40	37	28	42	44	18	13	4	0.36	0.46	0.13
48.	88	88	25	27	38	40	30	42	42	21	14	4	0.30	0.44	0.13
49.	62	104	27	26	47	38	29	56	58	18	12	5	0.44	0.56	0.18
50.	62	104	28	26	45	40	30	55	55	18	12	4	0.46	0.57	0.17
51.	83	110	30	29	48	37	–	–	–	20	10	5	0.46	0.67	0.36
52.	83	109	27	28	42	43	39	56	60	22	12	5	0.37	0.56	0.29
53.	69	97	30	26	47	43	–	–	–	19	15	3	0.40	0.50	0.31
54.	69	100	28	27	45	38	35	49	49	22	14	5	0.34	0.50	0.29

No	Age (year)	L (mm)	D ₁ (mm)	D _{1a} (mm)	D ₂ (mm)	D _{2a} (mm)	D ₃ (mm)	D ₄ (mm)	D _{4a} (mm)	d ₁₀ (mm)	d ₂₀ (mm)	S	BN ₁₀	BN ₂₀	BN ₃₀
55.	49	109	31	29	57	40	38	58	57	18	11	4	0.41	0.65	0.18
56.	49	108	30	28	52	42	34	57	56	20	15	4	0.38	0.50	0.19
57.	77	105	27	26	45	37	32	52	54	15	9	4	0.55	0.67	0.25
58.	77	107	27	26	46	36	31	53	54	16	8	4	0.48	0.70	0.24
59.	68	—	26	21	41	33	29	43	44	13	11	4	0.55	0.58	0.17
60.	68	92	27	20	40	30	30	43	44	14	12	4	0.46	0.56	0.20
61.	85	93	26	28	44	44	31	47	48	18	10	4	0.42	0.62	0.31
62.	85	95	26	32	43	40	34	49	48	19	10	4	0.37	0.62	0.43
63.	70	105	28	27	43	39	33	50	52	23	12	4	0.30	0.57	0.30
64.	70	107	30	27	46	42	33	50	52	22	12	4	0.33	0.60	0.33
65.	78	86	23	24	40	37	31	44	44	22	17	4	0.21	0.26	0.18
66.	78	89	26	28	39	34	32	44	46	22	16	4	0.31	0.39	0.21
67.	56	96	30	26	40	36	31	51	51	20	14	4	0.43	0.53	0.32
68.	56	96	29	26	42	35	30	51	52	17	11	4	0.49	0.62	0.32
69.	72	103	27	27	45	36	32	50	52	21	12	4	0.35	0.56	0.36
70.	72	103	27	29	44	37	32	51	52	19	12	4	0.42	0.56	0.36
71.	46	107	27	30	46	38	35	55	56	21	13	2	0.38	0.52	0.21
72.	46	105	29	30	50	40	37	55	56	24	15	2	0.31	0.48	0.27
73.	82	109	28	28	42	40	35	52	51	16	13	5	0.52	0.54	0.22
74.	82	103	28	27	48	38	36	50	51	17	12	5	0.49	0.57	0.25
75.	39	116	26	31	46	38	33	58	58	19	12	4	0.44	0.54	0.28
76.	39	114	27	33	48	39	34	58	58	21	12	4	0.40	0.56	0.31
77.	55	114	31	31	46	42	36	54	56	21	16	5	0.42	0.48	0.24
78.	55	108	30	—	47	—	35	54	—	19	10	5	0.49	0.67	0.28
79.	76	95	25	24	42	32	28	46	47	14	10	4	0.48	0.60	0.17
80.	76	97	23	23	40	33	28	44	46	14	10	4	0.48	0.57	0.18
81.	36	94	25	30	48	40	34	49	51	18	9	3	0.42	0.64	0.26
82.	36	95	26	28	44	42	33	49	49	18	10	2	0.44	0.62	0.25
83.	80	88	27	29	40	36	29	44	46	18	12	3	0.36	0.56	0.25
84.	80	88	28	28	41	37	33	45	46	20	13	4	0.33	0.54	0.24
85.	76	104	27	30	47	41	34	53	57	21	10	5	0.38	0.63	0.36
86.	76	106	26	28	44	43	32	62	53	21	10	2	0.36	0.62	0.29

Key

male	female
------	--------

K age (year)

L femoral neck-head length (mm)

D₁ the outer diameter of the femur in the frontal plane 20 cm from the tip of the greater trochanter (mm)D_{1a} the outer diameter of the femur in the sagittal plane 20 cm from the tip of the greater trochanter (mm)D₂ the outer diameter of the femur in the frontal plane at the top of the lesser trochanter (mm)D_{2a} the outer diameter of the femur in the sagittal plane at the top of the lesser trochanter (mm)D₃ the diameter of the femoral neck in the frontal plane (mm)D₄ the diameter of the femoral head in the frontal plane (mm)D_{4a} the diameter of the femoral head in the sagittal plane (mm)d₁₀ the diameter of the femoral canal 10 cm from the greater trochanter (mm)d₂₀ the diameter of the femoral canal 20 cm from the greater trochanter (mm)

S Singh index

BN₁₀ Barnett–Nordin index (10 cm from the tip of the greater trochanter)BN₂₀ Barnett–Nordin index (20 cm from the tip of the greater trochanter)BN₃₀ Barnett–Nordin index (30 cm from the tip of the greater trochanter)V₁ the lateral thickness of the cortical boneV₂ the medial thickness of the cortical bone

Table I. The geometrical data of the femur measurements

The higher the value of the Barnett–Nordin index the wider the medullary canal. The index has the lowest value at 20 centimeters from the tip of the greater trochanter when determined at 10, 20, and 30 centimeters; the reason for this can be explained on the lateral view of the femur, because at this level the posterior cortex is thickened in the concavity of the physiological anterior bowing of the femur. At 30 centimeters from the tip of the greater trochanter we are below the narrow-

ing of the medullary canal of the femur, where the canal is wider compared to the cortical bone (*Figure 1 and Diagram 1*).

The Singh index shows a Gaussian distribution (*Diagram 2*).

The difference in the frontal and sagittal diameter of the femoral head has a greater distribution with increased age. The highest values were observed at around 80 years of

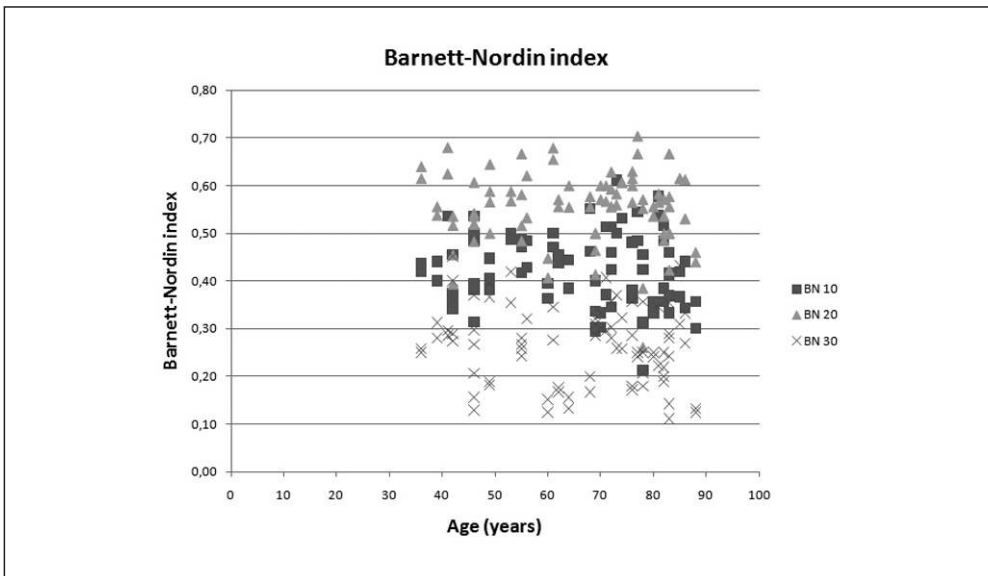


Diagram 1. The relation between the Barnett–Nordin index and age

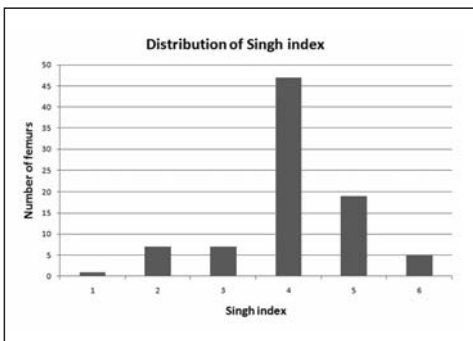


Diagram 2. The distribution of the Singh index

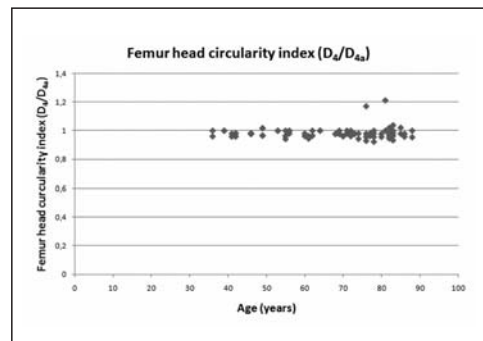


Diagram 3. The relation between the ratio of the frontal and sagittal diameter of the femur and age

age. This can be explained by the deformities caused by arthrosis and osteophytes usually present by this age (*Diagram 3*).

Discussion

One of the key steps in successful total hip replacement is the selection of the right size of femoral stem from a surgical point of view, and the geometry of the femoral stem from the manufacturer's perspective. Data bases that can provide help with this are limited in the literature⁴. It is typical that most manufactured femoral stems possess the same geometry throughout all available sizes; for this reason it would be interesting to compare population statistics during the planning phase. We hoped to assist this research and development phase with our present work.

We performed femoral head measurements, because the size of the bony acetabulum can be estimated from this information, and we find that this is also important during prosthesis manufacturing.

Nowadays hip replacement is not exclusively a surgical technique for the older age group, due to the expansion of the indication criteria more and more middle-aged patients, and in some cases even very young individuals require surgery.

The decision to use cemented or non-cemented prosthesis greatly depends on geometrical changes seen in osteoporosis, and the type of prosthesis used depends ideally on the geometry of the femur.

REFERENCES

1. *Barnett E, Nordin BEC.* I. The Clinical and radiological problem of thin bones. The British journal of radiology 1961;407:683–92.
2. *Csernátóy Z.* Diplôme d'Etudes Approfondies (DEA) en Biomécanique et Biomatériaux. Ecole Nationale Supérieure d' Arts et Metiers, Paris; 1993.
3. *Grampp S, Steiner E, Imhof H.* Radiological diagnosis of osteoporosis. European Radiology. 1997(Suppl 2):11–9.
4. *Józsa L.* A proximális femur-vég geometriája. Magyar Traumatológia, Ortopédia, Kézsebészet, Plasztikai Sebészet 1999;42:250–6.
5. *Koot VCM, Kesselaer SMMJ, Clevers GJ, de Hooge P, Weits T, van der Werken Chr.* Evaluation of the Singh index for measuring osteoporosis. J Bone Joint Surg Br 1996;78-B:831–4.

Zoltán Csernátóy

Department of Orthopaedic Surgery, Medical and Health Science Center, University of Debrecen H-4032 Debrecen, Nagyerdei krt. 98.
Tel.: (+36) 52 255-815