

CLINICAL PICTURE

Giant cell arteritis presenting with chronic cough and headache after BNT162b2 mRNA COVID-19 vaccination

A 74-year-old Japanese man presented with cough and headache following the Coronavirus disease 2019 (COVID-19) vaccination. Two months before, the day after the third dose of BNT162b2 mRNA COVID-19 vaccination, he presented with a left temporal headache. One month ago, he developed a right temporal headache and cough. His medical history revealed hypertension, for which he was prescribed amlodipine (2.5 mg/day). Physical examination was unremarkable. Auscultation and chest radiograph were normal. His C-reactive protein (6.32 mg/dl) levels and erythrocyte sedimentation rate (79 mm/h) were elevated. Neck and chest contrast-enhanced computed tomography (CT) showed no abnormalities of the lung, thoracic aorta, its branches or pulmonary arteries. Positron emission tomography/CT (PET/CT) showed hyperaccumulation in the thoracic aorta, subclavian, axillary, brachial and temporal arteries (Figure 1a and b). Giant cell arteritis (GCA) was diagnosed. Symptoms improved with oral administration of prednisolone (30 mg/day).

GCA is the most common form of vasculitis in older adults, affecting people >50 years of age.¹ Common symptoms of GCA include headache, scalp tenderness, jaw claudication, ocular ischemic manifestations and inflammatory arthralgia.¹ Cough is a rare initial manifestation of GCA and is often overlooked.² The mechanism of cough formation is unclear; however, inflammation of the artery adjacent to the cough reflex pathway is thought to cause cough.³ GCA pathophysiology is not fully understood but environmental factors and infections are likely to play a role.⁴ Additionally, it has been reported that GCA can occur after influenza vaccination and COVID-19 vaccination, which could act as an inflammatory trigger.⁵ With advances in diagnostic imaging, the identification of macrovascular lesions in GCA patients has improved; PET/CT can identify inflammatory vessels metabolically.⁶ In conclusion, GCA should be considered in patients with prolonged cough with high inflammatory markers and no pulmonary changes on radiological imaging, which can occur after COVID-19 vaccination.

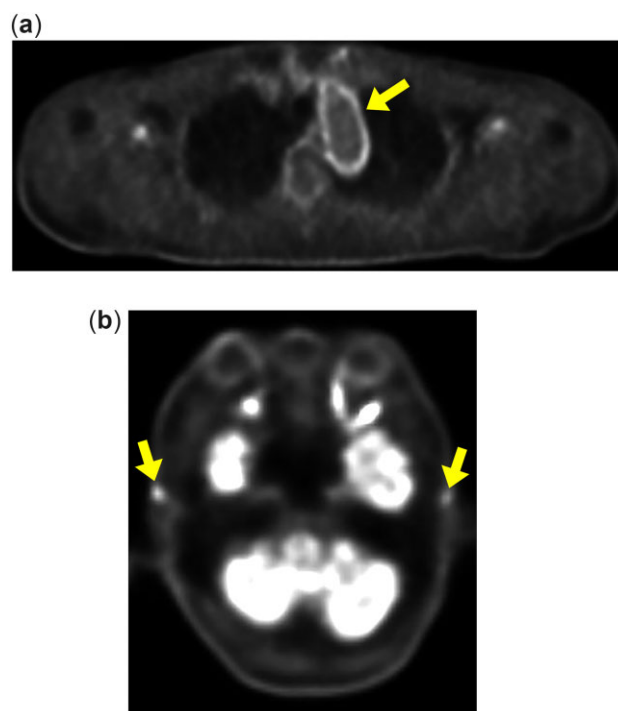




Figure 1. (a) PET/CT showed hyperaccumulation in the thoracic aorta (yellow arrow). (b) PET/CT showed hyperaccumulation in the bilateral temporal arteries (yellow arrows).

Conflict of interest: None declared.

Photographs and text from: Drs K. Ishizuka , K. Katayama  and Y. Ohira, Division of General Internal Medicine, Department of Internal Medicine, St. Marianna University School of Medicine, 2-16-1, Sugao, Miyamae, Kawasaki, Kanagawa 216-8511, Japan. email: e103007c@yokohama-cu.ac.jp

Submitted: 8 July 2022

© The Author(s) 2022. Published by Oxford University Press on behalf of the Association of Physicians. All rights reserved.

For permissions, please email: journals.permissions@oup.com

References

1. Muratore F, Kermani TA, Crowson CS, Green AB, Salvarani C, Matteson EL, et al. Large-vessel giant cell arteritis: a cohort study. *Rheumatology (Oxford)* 2015; **54**:463–70.
2. Zenone T, Puget M. Dry cough is a frequent manifestation of giant cell arteritis. *Rheumatol Int* 2013; **33**:2165–8.
3. Larson TS, Hall S, Hepper NG, Hunder GG. Respiratory tract symptoms as a clue to giant cell arteritis. *Ann Intern Med* 1984; **101**:594–7.
4. Nordborg E, Nordborg C. Giant cell arteritis: epidemiological clues to its pathogenesis and an update on its treatment. *Rheumatology (Oxford)* 2003; **42**:413–21.
5. Mettler C, Jonville-Bera AP, Grandvuillemin A, Treluyer JM, Terrier B, Chouchana L. Risk of giant cell arteritis and polymyalgia rheumatica following COVID-19 vaccination: a global pharmacovigilance study. *Rheumatology (Oxford)* 2022; **61**:865–7.
6. Koster MJ, Matteson EL, Warrington KJ. Large-vessel giant cell arteritis: diagnosis, monitoring and management. *Rheumatology (Oxford)* 2018; **57**:ii32–42.