

## Giant intracranial lipoma

---

R. Shane Tubbs<sup>1,2</sup>, Robert G. Louis Jr.<sup>3</sup>, Marios Loukas<sup>4</sup>, Mohammadali M. Shoja<sup>5</sup>, Jeffrey P. Blount<sup>1</sup>

<sup>1</sup>Section of Pediatric Neurosurgery, Children's Hospital, Birmingham, Alabama, USA; <sup>2</sup>Department of Cell Biology, University of Alabama at Birmingham, Alabama, USA; <sup>3</sup>University of Virginia, Department of Neurosurgery, Charlottesville, Virginia, USA; <sup>4</sup>Department of Anatomical Sciences, St. George's University, Grenada and Department of Education, Harvard Medical School Boston, Massachusetts, USA; <sup>5</sup>Tuberculosis and Lung Disease Institute, Tabriz University, Tabriz, Iran

*Folia Neuropathol* 2007; 45 (4): 247-249

### Abstract

*Intracranial lipomas are rare and usually benign in their course. We report a case of a giant intracranial lipoma presenting with raised intracranial pressure. Additionally, this patient was found to have a large lipoma of the anterior fontanelle. The clinical course and outcome of this patient is presented and relevant literature reviewed.*

**Key words:** intracranial lipoma, brain neoplasm, pediatric neurosurgery

### Introduction

An intracranial lipoma was first described by Meckel in 1818 [13]. Intracranial lipomas, particularly those large enough to cause symptoms, are exceedingly rare and the treatment of such is controversial [5,9,13,14]. Most intracranial lipomas are small and found incidentally during neuroradiological investigations and approximately one half are asymptomatic [8]. These usually benign tumors are found generally in the midline and have been reported to comprise 0.5-1% of all intracranial neoplasms [2,5,7,8]. Although the majority are found within the corpus callosum, cases have also been reported involving the brain stem, cerebellum, lateral ventricles, Sylvian fissure, interpeduncular cistern, quadrigeminal plate and pineal region and cerebellopontine angle [6,12,15]. We report an unusual case of a giant intracranial lipoma.

### Case report

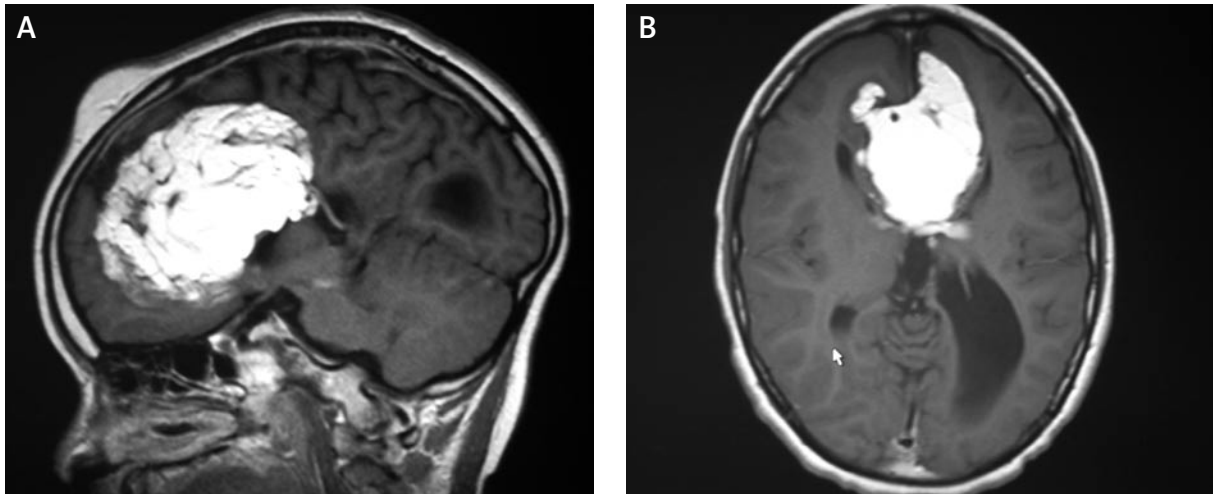
Our case is that of a previously healthy 10-year-old male who presented with a several week history of severe headache, seizures and hydrocephalus. Imaging revealed a large (10×7×4.5 cm) interhemispheric lipoma compressing the ventricular system (Fig. 1). Physical exam was normal other than a palpable mass within the anterior fontanelle. An extraventricular drain was placed and this alleviated his headaches. After a discussion with the parents, it was decided to debulk the mass in an effort to primarily treat the obstructive hydrocephalus. An interhemispheric approach was used to debulk (Fig. 2) the mass. The lipoma of the anterior fontanelle was debulked and found not to communicate with the intracranial lipoma. Both masses were histologically normal adipose tissue. Some but not all of the tumor could be safely removed. At the most recent follow-up, the child is unshunted and without headaches.

---

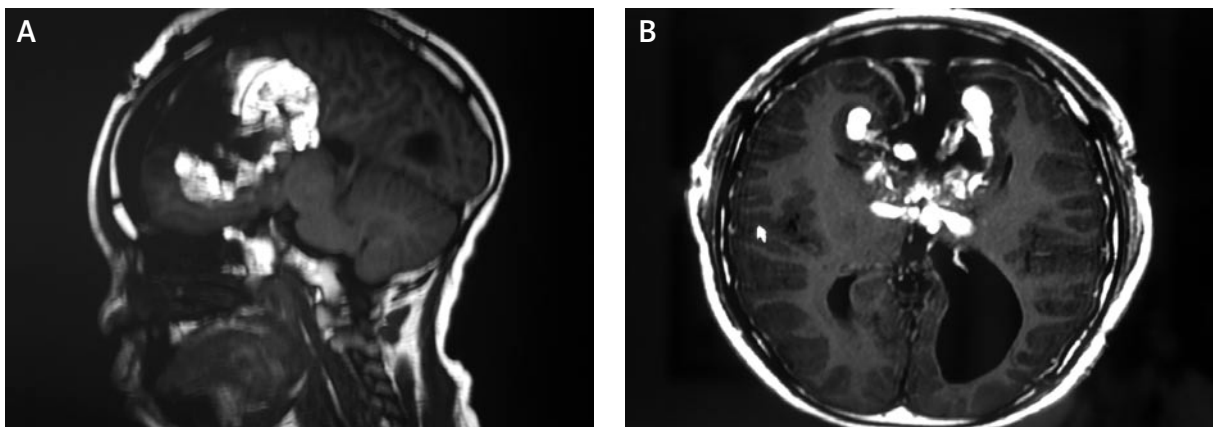
### Communicating author:

R. Shane Tubbs, PhD, Pediatric Neurosurgery, Children's Hospital, 1600 7<sup>th</sup> Avenue South ACC 400, Birmingham, AL 35233, tel. 205 939 99 14, fax 205 939 99 72, Email: rstubbs@uab.edu

---



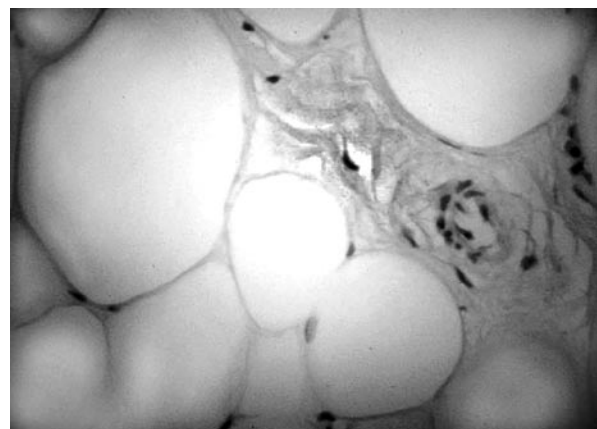**Fig. 1.** Preoperative sagittal (A) and axial (B) MRI of the head. Note the lipoma of the anterior fontanelle on the sagittal image that did not communicate with the intracranial lipoma



**Fig. 2.** Postoperative sagittal (A) and axial (B) MRI of the head

## Discussion

Yilmaz et al. [15] reported that the most frequent reasons for admission of patients with intracranial lipomas were: headache, trauma and epilepsy. Fandino [3] added to this and stated that mental dysfunction is also a common symptom at clinical presentation. Imaging characteristics of these entities are reflective of their lipid content [4,14]. Considering that intracranial lipomas are often associated with other congenital abnormalities, including spina bifida and agenesis of the corpus callosum, some authors have speculated that they are caused by neural tube derangement [4,14]. Truwit and Barkovich [13] found that 55% of their patients with intracranial lipomas



**Fig. 3.** Histology of the intracranial lipoma reported herein (H&E  $\times$  33) noting normal adipose cells

had an associated brain malformation. Hayashi et al. [6] in their review of six cases of intracranial lipomas found that four patients had an associated agenesis of the corpus callosum and one patient was identified as having an associated interhemispheric cyst. Although controversial and yet to be proven, embryologically, some have posited that such tumors are due to inclusion of pluripotent mesoderm within the closing neural tube [13] and as such do not represent hamartomas or true neoplasms but rather true congenital malformations.

Generally, intracranial lipomas are benign masses that do not require surgery. Hydrocephalus is considered to be a rare consequence of such tumors and is usually due to obstruction at the cerebral aqueduct [13]. Our case is unusual due to its size and compression of the foramina of Monro resulting in hydrocephalus. Additionally, our case was found to also have an extracranial lipoma of the anterior fontanelle. Martins et al. [10] found in their review of the literature regarding intracranial lipomas only eight cases of intracranial lipoma (all involving the corpus callosum) that also had an associated extracranial component. Similar to our case, Sari et al. [11] described a child with an interhemispheric lipoma that extended into the choroid plexus of the lateral ventricles that was also associated with an extension of lipoma into the anterior fontanelle. Martins et al. [10] stressed that resection of the intracranial portions of these tumors all had catastrophic results and should not be dealt with surgically. Truwit and Barkovich [13] found that of intracranial lipomas, 36% had intracranial vessels and nerves that coursed through the mass, making surgery dangerous. Contrarily, Shinozaki et al. [12] reported five cases of intracranial lipoma and in two patients with symptoms, subtotal resecting resulted in complete reversal of their preoperative symptoms. These authors stressed that even subtotal resection can be beneficial in such patients [12].

## Conclusions

Although rare, intracranial lipomas may result in hydrocephalus. Debulking of such mass effect may result in resolution of symptoms of raised intracranial pressure.

## References

1. Carmel PW. Lipomas. In: Youmans JR (ed.). *Neurological Surgery*. Vol. 5. SB Saunders, Philadelphia 1990; pp. 3244-3247.
2. Donati F, Vassella F, Kaiser G, Blumberg A. Intracranial lipomas. *Neuropediatrics* 1992; 23: 32-38.
3. Fandiño J. [Intracranial lipomas]. *Rev Neurol* 2001; 32: 644-650.
4. Friedman RB, Segal R, Latchaw RE. Computerized tomographic and magnetic resonance imaging of intracranial lipoma. Case report. *J Neurosurg* 1986; 65: 407-410.
5. Gerber SS, Plotkin R. Lipoma of the corpus callosum. Case report. *J Neurosurg* 1982; 57: 281-285.
6. Hayashi T, Shojima K, Yamamoto M, Hashimoto T, Fukuzumi A, Honda E. [Intracranial lipomas – report of six cases]. *No To Shinkei* 1983; 35: 257-268.
7. Kazner E, Stochdorph O, Wende S, Grumme T. Intracranial lipoma. Diagnostic and therapeutic considerations. *J Neurosurg* 1980; 52: 234-245.
8. Kiyamaz N, Cirak B. Central nervous system lipomas. *Tohoku J Exp Med* 2002; 198: 203-206.
9. Loddenkemper T, Morris HH 3rd, Diehl B, Lachhwani DK. Intracranial lipomas and epilepsy. *J Neurol* 2006; 253: 590-593.
10. Martins RS, Ciquini Júnior O, Matushita H, Plese JP. [Lipoma of the corpus callosum with extracranial extension through frontal bone defect]. *Arq Neuropsiquiatr* 1995; 53: 671-675.
11. Sari A, Dinç H, Gümele HR. Interhemispheric lipoma associated with subcutaneous lipoma. *Eur Radiol* 1998; 8: 628-630.
12. Shinozaki N, Sekiya T, Suzuki S, Iwabuchi T, Suzuki M. [Five cases of intracranial lipoma; CT and magnetic resonance images]. *No Shinkei Geka* 1992; 20: 289-293.
13. Truwit CL, Barkovich AJ. Pathogenesis of intracranial lipoma: an MR study in 42 patients. *AJR Am J Roentgenol* 1990; 155: 855-864.
14. Yildiz H, Hakyemez B, Koroglu M, Yesildag A, Baykal B. Intracranial lipomas: importance of localization. *Neuroradiology* 2006; 48: 1-7.
15. Yilmaz N, Unal O, Kiyamaz N, Yilmaz C, Etlik O. Intracranial lipomas – a clinical study. *Clin Neurol Neurosurg* 2006; 108: 363-368.