

Rare disease

Giant placental chorioangioma: a rare cause of fetal hydrops

Andreia Barros, Ana Cristina Freitas, António Jorge Cabral, Maria Carmo Camacho, Edite Costa, Henrique Leitão, José Luis Nunes

Department of Pediatrics, Funchal Central Hospital, Funchal, Portugal

Correspondence to Dr Andreia Barros, asofiarbarros@gmail.com

Summary

Giant chorioangiomas are rare placental tumours, associated with a high prevalence of pregnancy complications and a poor perinatal outcome. Neonatal consequences include severe microangiopathic haemolytic anaemia, thrombocytopenia and hydrops. The associated high perinatal death rate (30–40%) has led to a number of prenatal therapeutic interventions with limited success in most cases. The authors present a case of non-immune fetal hydrops caused by a giant chorioangioma, diagnosed at 27 weeks of gestational age. Despite tocolytic therapy, the baby was born prematurely (28 weeks of gestational age) and required transfusion of blood derivatives, intensive phototherapy and exchange transfusion. She had an uncomplicated recovery and was discharged home in the second month of life. The authors emphasise the need to consider chorioangioma as a cause of non-immune fetal hydrops and microangiopathic haemolytic anaemia.

BACKGROUND

Chorioangioma is a benign placental tumour, defined by the abnormal proliferation of vessels arising from chorionic tissue.^{1 2} Described for the first time in 1798 by John Clarke, chorioangiomas are the most frequent placental tumours, occurring in 1% of pregnancies.^{1–4} Usually small in size, they are frequently overlooked and discovered upon histological examination, if the placenta is carefully sectioned.^{5 6} Small chorioangiomas tend to remain asymptomatic and rarely complicate the course of the pregnancy.^{5–7} On the opposite side, giant chorioangiomas (> 4 cm in diameter) are rare tumours, with a prevalence ranging from 1:9.000 to 1:50.000 pregnancies.⁵ These large chorioangiomas are associated with pregnancy complications: premature labour, placental abruption, polyhydramnios and fetal hydrops, growth restriction, hepatosplenomegaly, cardiomegaly, congestive heart failure and death.^{7–9} Neonatal consequences include severe microangiopathic haemolytic anaemia, thrombocytopenia and hydrops.^{3 5 10}

Prenatal diagnosis is presumed through sonographic studies with colour Doppler, a useful tool in the differentiation of placental tumours.^{11–13}

The associated high perinatal death rate (30–40%) has led to a number of prenatal therapeutic interventions with limited success in most cases.^{5 14}

We present a case of non-immune fetal hydrops caused by a giant placental chorioangioma, born at 28 weeks of gestational age. The baby required exchange transfusion, an infrequent procedure at the present time.

CASE PRESENTATION

The authors report the case of a newborn, female, second daughter of unrelated parents, with a previously healthy son. The mother was 28 years old, O Rh positive, with obstetric index: 2002. The pregnancy had been uneventful and the fetal sonograms were reported as normal until 27 weeks of gestational age. At this time, she was

admitted to an antenatal obstetric unit due to preterm labour. Cardiotocography revealed a normal fetal heart rate. Pulmonary maturation was accelerated by the administration of two doses of betamethasone. Ultrasound examination revealed polyhydramnios and fetal hydrops (skin oedema, pleural effusion and ascites). A heterogeneous placental mass measuring 100×74 mm was observed arising from the chorionic plate (figure 1). When using colour Doppler, the appearance was consistent with a highly vascularised mass.

At 28 weeks postconceptional age, labour progressed very rapidly, despite tocolytic therapy. She was born by normal vaginal delivery. Apgar score was 4/8 (1'/5'). She was immediately intubated (orotracheal) and required invasive mechanical ventilation. At birth, her weight was 1660 g (97th percentile), length: 35.5 cm (10th percentile) and head circumference: 26 cm (50th percentile). Physical examination of the neonate revealed pale mucous membranes and generalised skin oedema. Neither dysmorphic features nor cutaneous haemangiomas were observed. A systolic heart murmur was detected. Macroscopic examination of the placenta confirmed a multilobulated and hypervascularised mass, sent for pathological examination (figure 2). The preterm neonate was admitted to a neonatal intensive care unit.

INVESTIGATIONS

Blood tests revealed a microangiopathic haemolytic anaemia: haemoglobin 9.5 g/dl, haematocrit 31% and reticulocytosis 14.9% (reticulocyte index 6.8%). Blood smear disclosed anisocytosis, spherocytosis and red cell fragmentation. Direct Coombs test was negative and blood group O Rh positive. Thrombocytopenia was detected (30.000/μl). Biochemical markers of haemolysis were also elevated: lactate dehydrogenase 1390 U/l, aspartate aminotransferase 131 U/l with normal alanine aminotransferase and indirect bilirubin 33 μmol/l. Despite intensive phototherapy, throughout the first 24 h of life, total bilirubin levels

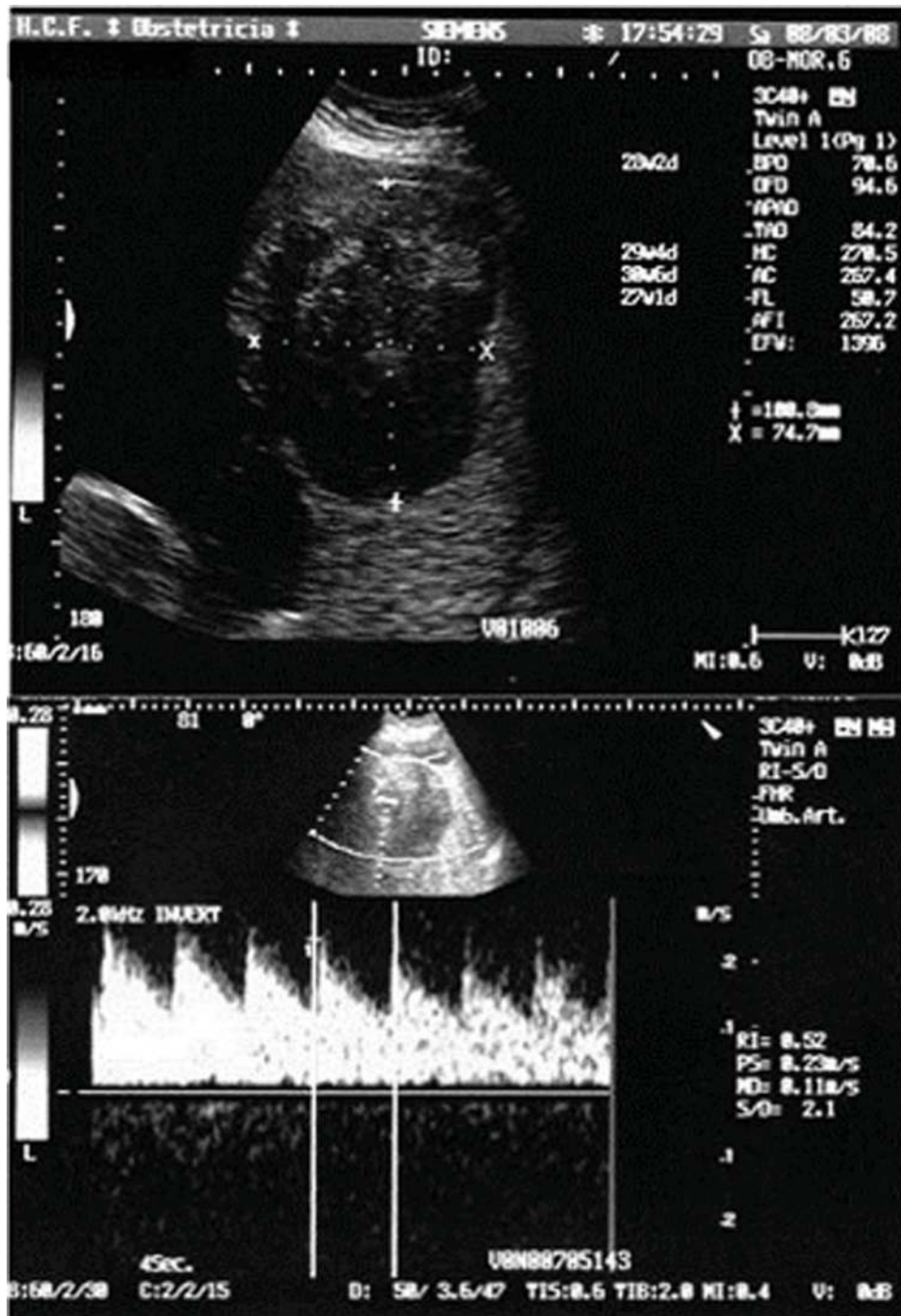


Figure 1 Ultrasonography showing a placental heterogeneous mass and flow velocity waveforms of vessels inside the placental tumour.

were progressively increasing (186.4 $\mu\text{mol/l}$) and serum albumin decreasing (1.2 g/dl). Radiographs showed small bilateral pleural effusion. A fontanellar ultrasound detected excessive amount of extraxial fluid without intraventricular haemorrhage.

Infectious screening was negative and the karyotype was 46XX, without chromosomal anomalies. Echocardiography revealed a structurally normal heart, with mild to moderate mitral regurgitation and a haemodynamically significant patent ductus arteriosus (PDA). Abdominal ultrasound excluded the presence of haematomas or tumours.

Histopathological examination of the placenta confirmed the hypothesis of placental chorioangioma, measuring 19×7×6 cm.

DIFFERENTIAL DIAGNOSIS

Other aetiologies for non-immune fetal hydrops, such as infectious diseases, cardiac malformations and chromosomal anomalies, were excluded. Differential diagnosis of solid placental masses should be addressed, including placental haematoma, teratoma, partial hydatiform mole and maternal tumour metastatic to the placenta.

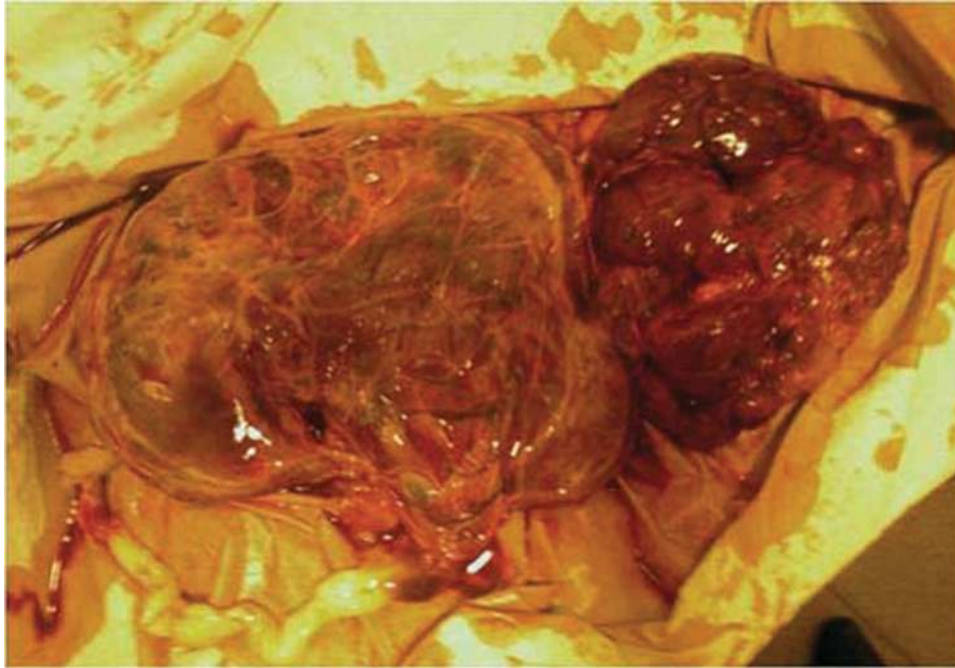


Figure 2 Amniotic side of the placenta, appearing as a bright and oedematous surface. Large multi-lobulated and vascularised mass suggestive of placental chorioangioma.

TREATMENT

One dose of surfactant was given in the first 30 min of life. Invasive ventilation support was needed in the first 4 days and non-invasive ventilation until day 6 of life.

Thrombocytopenia associated with umbilical cord haemorrhage required platelet transfusion. Packed red cells were given in the first 2 days of life. Intensive phototherapy was initiated at 3 h of life. Nonetheless, on day 3, she fulfilled criteria for exchange transfusion: total bilirubin 252 $\mu\text{mol/l}$ and serum albumin/total bilirubin ratio of 8.4. During the procedure, the neonate remained haemodynamically stable and no complications occurred. Thereafter, bilirubin levels dropped progressively and phototherapy was discontinued at day 9 of life.

PDA was closed with one dose of intravenous indomethacin, once platelet count was 89.000/ μl (day 3 of life). It was well tolerated.

OUTCOME AND FOLLOW-UP

Skin oedema, pleural effusion and ascites resolved spontaneously. She was discharged home at 65 days of life, without any respiratory support and with full enteral feeding with breast milk. Echocardiography at day 6 of life was normal. Cranial ultrasound at term age was normal. She is currently 2 years old. Follow-up until present time showed an adequate psychomotor development and growth.

DISCUSSION

Giant chorioangiomas are rare placental tumours, associated with a high prevalence of pregnancy complications and a poor perinatal outcome.⁵ Prenatal diagnosis of chorioangioma is achieved by ultrasonography with colour Doppler.¹¹ The typical appearance is of a vascularised tumour, differentiated from placental haematoma by pulsed doppler and colour flow mapping.^{11 12}

The approach and treatment in case of prenatal diagnosis is dictated by fetal maturation and complications detected in the mother and fetus. These tumours act as large arteriovenous shunts within the placenta, diverting blood away from the fetus.⁹ Polyhydramnios, as presented in this case, has been linked to increased urine production, associated with fetal hyperdynamic circulation related to shunting of blood or fetal anaemia.^{5 9} It has also been proposed that transudation of fluid from the tumour surface contributes to accumulation of amniotic fluid.⁵ Microangiopathic haemolytic anaemia with thrombocytopenia, also present in our case, is related to injury in erythrocytes and trapped platelets by circulation through tortuous and partially thrombosed vascular networks.^{5 9 10} Growth restriction is due to utero-placental insufficiency from increased functional dead space by the presence of the tumour.^{5 7-9}

Fetal treatment of chorioangioma and related complications is controversial. Amniocentesis for relief of polyhydramnios and intrauterine blood transfusion for fetal anaemia are currently used therapies to treat the effects of chorioangioma.^{5 8-10} Treatment of the underlying cause, the tumour itself, has been attempted with injection of alcohol, endoscopic laser coagulation and suture ligation, microcoil embolisation and bipolar electrosurgery.^{3 5 15} All of these options are non risk-free interventions and have a highly variable success rate.^{3 5 6} In our case, with established hydrops at time of presentation, none of these interventions was performed. Transfer to a referral obstetrical unit with experience in performing prenatal intervention was not possible due to preterm labour.

Fetuses who develop hydrops are at the highest risk for perinatal death.³ In preparing for delivery of an infant who has known fetal hydrops, a skilled neonatal resuscitation team is essential.¹⁶ In our case, management of the preterm baby was closely addressed, particularly respiratory,

cardiovascular and nutritional care. Management of microangiopathic haemolytic anaemia included administration of blood derivatives.¹⁷ Despite intensive phototherapy, exchange transfusion was necessary, as previously described by Bauer *et al.*¹⁷ Prematurity may also have contributed to a prolonged course of hyper-bilirubinaemia.

Learning points

- ▶ Chorioangiomas greater than 4 cm in diameter carry a high risk for fetal morbidity.
- ▶ Whenever a chorioangioma is suspected, fetal ultrasound examinations with colour doppler should be performed weekly, with special attention to hepatosplenomegaly and increased blood flow velocities.
- ▶ If fetal anaemia is assumed, chordocentesis should be performed and intrauterine transfusion considered, particularly in the preterm fetus.
- ▶ After birth, in a Coombs' test negative infant and evidence of fetal hydrops, macroscopic examination of the placenta is crucial to exclude the presence of chorioangiomas.

Competing interests None.

Patient consent Obtained.

REFERENCES

1. **Wallenburg HC**. Chorioangioma of the placenta. Thirteen new cases and a review of the literature from 1939 to 1970 with special reference to the clinical complications. *Obstet Gynecol Surv* 1971;**26**:411–25.
2. **Benson PF**, Joseph MC. Cardiomegaly in a Newborn Due to Placental Chorioangioma. *Br Med J* 1961;**1**:102–5.
3. **Sepulveda W**, Alcalde JL, Schnapp C, *et al.* Perinatal outcome after prenatal diagnosis of placental chorioangioma. *Obstet Gynecol* 2003;**102**(5 Pt 1):1028–33.
4. **Durin L**, Barjot P, Herlicoviez M. [Placental chorioangioma, value of ultrasonography: report of two cases]. *J Radiol* 2002;**83**(6 Pt 1):739–41.
5. **Zanardini C**, Papageorgiou A, Bhide A, *et al.* Giant placental chorioangioma: natural history and pregnancy outcome. *Ultrasound Obstet Gynecol* 2010;**35**:332–6.
6. **Mubiayi N**, Cordonnier C, Le Goueff F, *et al.* [Placental chorioangiomas diagnosed during the second trimester of pregnancy: four cases]. *J Gynecol Obstet Biol Reprod (Paris)* 2002;**31**(2 Pt 1):187–92.
7. **Froehlich LA**, Fujikura T, Fisher P. Chorioangiomas and their clinical implications. *Obstet Gynecol* 1971;**37**:51–9.
8. **Haak MC**, Oosterhof H, Mouw RJ, *et al.* Pathophysiology and treatment of fetal anemia due to placental chorioangioma. *Ultrasound Obstet Gynecol* 1999;**14**:68–70.
9. **Isaacs H Jr.** Fetal hydrops associated with tumors. *Am J Perinatal* 2008;**25**:43–68.
10. **Tonkin IL**, Setzer ES, Ermocilla R. Placental chorioangioma: a rare cause of congestive heart failure and hydrops fetalis in the newborn. *AJR Am J Roentgenol* 1980;**134**:181–3.
11. **Prapas N**, Liang RI, Hunter D, *et al.* Color Doppler imaging of placental masses: differential diagnosis and fetal outcome. *Ultrasound Obstet Gynecol* 2000;**16**:559–63.
12. **Chou MM**, Ho ES, Hwang SF, *et al.* Prenatal diagnosis of placental chorioangioma: contribution of color Doppler ultrasound. *Ultrasound Obstet Gynecol* 1994;**4**:332–4.
13. **Hirata GI**, Masaki DI, O'Toole M, *et al.* Color flow mapping and Doppler velocimetry in the diagnosis and management of a placental chorioangioma associated with nonimmune fetal hydrops. *Obstet Gynecol* 1993;**81**(5 Pt 2):850–2.
14. **Batukan C**, Holzgreve W, Danzer E, *et al.* Large placental chorioangioma as a cause of sudden intrauterine fetal death. A case report. *Fetal Diagn Ther* 2001;**16**:394–7.
15. **Bhide A**, Prefumo F, Sairam S, *et al.* Ultrasound-guided interstitial laser therapy for the treatment of placental chorioangioma. *Obstet Gynecol* 2003;**102**(5 Pt 2):1189–91.
16. **Murphy J**. Nonimmune hydrops foetalis. *Neoreviews* 2004;**5**:e5–15.
17. **Bauer CR**, Fojaco RM, Bancalari E, *et al.* Microangiopathic hemolytic anemia and thrombocytopenia in a neonate associated with a large placental chorioangioma. *Pediatrics* 1978;**62**:574–7.

This pdf has been created automatically from the final edited text and images.

Copyright 2011 BMJ Publishing Group. All rights reserved. For permission to reuse any of this content visit <http://group.bmj.com/group/rights-licensing/permissions>.
BMJ Case Report Fellows may re-use this article for personal use and teaching without any further permission.

Please cite this article as follows (you will need to access the article online to obtain the date of publication).

Barros A, Freitas AC, Cabral AJ, Camacho MC, Costa E, Leitão H, Nunes JL. Giant placental chorioangioma: a rare cause of fetal hydrops. *BMJ Case Reports* 2011;10.1136/bcr.02.2011.3880, date of publication

Become a Fellow of BMJ Case Reports today and you can:

- ▶ Submit as many cases as you like
- ▶ Enjoy fast sympathetic peer review and rapid publication of accepted articles
- ▶ Access all the published articles
- ▶ Re-use any of the published material for personal use and teaching without further permission

For information on Institutional Fellowships contact consortiasales@bmjgroup.com

Visit casereports.bmj.com for more articles like this and to become a Fellow