

# Gigantic tongue lipoma: A case report

Midion Mapfumo Chidzonga <sup>1</sup>, Leonard Mahomva <sup>1</sup>, Clemence Marimo <sup>1</sup>

(1) Department of Dentistry. College of Health Sciences. University of Zimbabwe. Avondale. Harare

*Correspondence:*

Prof. Midion Mapfumo Chidzonga

Department of Dentistry

College of Health Sciences

University of Zimbabwe

Avondale

Harare

E-mail: mmchidzonga@medsch.uz.ac.zw

Received: 19-06-2005

Accepted: 25-02-2006

**Indexed in:**

-Index Medicus / MEDLINE / PubMed  
-EMBASE, Excerpta Medica  
-Indice Médico Español  
-IBCS

Chidzonga MM, Mahomva L, Marimo C. Gigantic tongue lipoma: A case report. *Med Oral Patol Oral Cir Bucal* 2006;11:E437-9.

© Medicina Oral S. L. C.I.F. B 96689336 - ISSN 1698-6946

## ABSTRACT

Lipomas are among the most common tumors of the human body. However, they are uncommon in the oral cavity. In the oral cavity they present as a slow growing, painless, and asymptomatic yellowish submucosal mass. Surgical excision is the treatment of choice with recurrence not expected. They have been known to grow to large sizes causing mastication and speech difficulties. The usual lesions consist of a well circumscribed, lobulated mass of mature fat cells. In other situations the covering mucosa becomes ulcerated and presents difficulties in diagnosis.

The present report is of a patient who presented with a gigantic lipoma on the tip of the tongue which had been present for 3 years. She now had difficulty with speech and mastication as the tongue tumor now completely filled the oral cavity. An incision biopsy confirmed the tumor as lipoma. The tumor was surgically excised with restoration of normal tongue function, speech and masticatory capacity. Histopathologic examination of the excised tumor confirmed that it was a lipoma

**Key words:** Oral lipoma, oral tumors, lingual tumor, lingual lipoma .

## INTRODUCTION

Lipomas are among the most frequent tumors in the human body, however, they are not common in the oral cavity (1), (2). Oral cavity lipomas usually present as slow-growing, painless and asymptomatic lumps. It is known that with continued growth their size may interfere with speech and mastication(1), (3). The buccal mucosa and tongue are commonly the predominant sites in adults with some studies showing a female preponderance while others show no gender preference (4), (5), (6). The tumors are either encapsulated or non encapsulated or present in an infiltrating manner.

The present report is of a 58-year old female who presented with a large lipoma of the tip of the tongue.

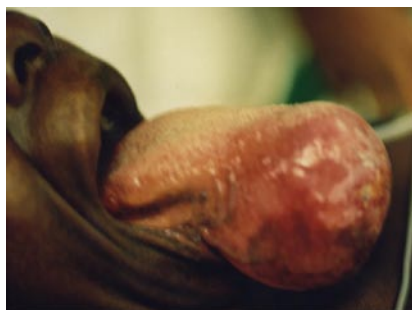## CASE REPORT

A 58-year old female presented at our Oral and Maxillo-facial Surgery clinic with a large tumor on the tip of the tongue (Figure 1). She alleged that the tumor had been present for the past 3 years. The rest of her medical history was non-contributory. Examination showed a soft,

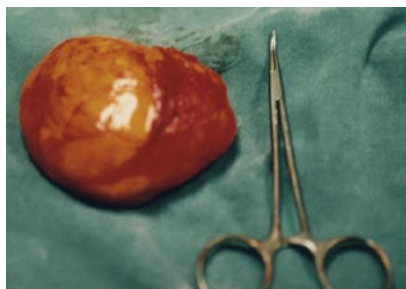
yellowish doughy lesion 11cm in diameter on the tip of the tongue. The tumor was attached under the mucosa of the tip of the tongue and to the underlying tongue tissue. It was smooth, with intact mucosa soft and elastic in consistency and non tender. There were superficial blood vessels over the tumor (Figure 1). The patient could literally “spit out” and “swallow” the tumor which stretched the tongue to dangle outside the mouth. She was edentulous in the anterior maxilla. The mandibular incisor/canine teeth were splayed out by the pressure of the tumor. The mandible was in an “open mouth” position from the weight of the tumor pushing it down. She had a large “anterior open bite”. She had a slurred speech with the tumor bobbing up and down and in and out of the mouth when speaking. She could not breathe through the mouth as the tumor completely filled the mouth. She claimed she managed to eat with difficulty with the tongue bobbing in and out. Despite the feeding and breathing difficulties, she was well nourished and not in any particular distress. Among the differential diagnoses were granular cell tumor, neurofibroma, traumatic fibroma and salivary gland tumors.

An incision biopsy report noted that there were lobules of mature adipose tissue consistent with a lipoma.

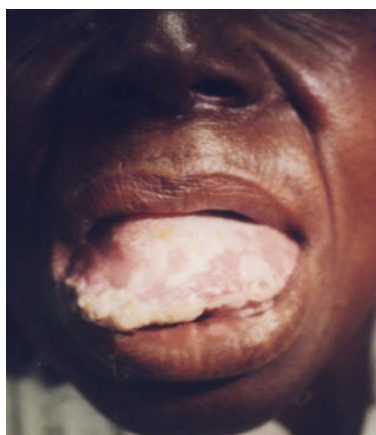Under general anesthesia a longitudinal incision was made over the mucosa covering the tumor at the tip of the tongue. Blunt dissection was used throughout. The tumor literally popped out from underneath the mucosa, reminiscent of popping out of the buccal fat pad after breach of its capsule (Figure 2). There was no involvement of the tongue musculature. The tumor was yellowish in color and well encapsulated (Figure 2). The mucosal layers were closed together with absorbable sutures obliterating the dead space. She made an uneventful recovery from the surgery (Figure 3).



**Fig. 1.** Profile view of patient showing tumor at the tip of the tongue and uninvolved tongue.



**Fig. 2.** Surgical Specimen.



**Fig. 3.** Appearance of tongue 4 days postoperatively.

Macroscopic examination showed a single mass of tissue covered with adipose tissue, 80mm x 80mm x 50mm and weighing 38 grams. The cut surface showed fatty tissue.

Microscopically the sections showed sheets of mature adipocytes and extravasated red blood cells. The tumor cells were arranged in lobules. The features were consistent with a lipoma.

The patient has since regained normal speech and feeding capacity with no loss of sensory or motor functions of the tongue. The tongue now fits comfortably in the mouth.

## DISCUSSION

Lipomas are common tumors in the human body, but are less frequent in the oral cavity, comprising no more than 1-5% of all the neoplasms(1) to (4). They commonly present as slow growing asymptomatic lesions with a characteristic yellowish colour and soft, doughy feel, in the buccal mucosa, floor of the mouth and tongue in the fourth and fifth decade generally without gender predilection(2),(3),(5) to (8). Some studies, however, have shown a male preponderance(8). They may present as solitary or multiple lesions, for instance as in Gardner's or Bournville's syndrome(2),(9) or as macroglossia (9) to (13), or lipomatosis (14). Their clinical course is usually asymptomatic until they grow to large sizes (2),(9). The majority remain un ulcerated. When they are ulcerated they present diagnostic problems(2). This was noted by a report of a lipoma that presented as a non-healing ulcer (2). In the present case the large size interfered with speech and mastication, similar to a case reported by Gray and Baker (9). Large tumors have been shown to cause dentofacial deformities, anterior open bite(5),(6). The present case had an anterior open bite due to flaring out of the mandibular incisors and canines. The average duration of the lipoma before excision is 3.2 years with a range of 6 weeks to 15 years(8). The usual range in size is 0,5 to 8 centimeters(8). The present case was 11 centimeters in diameter.

The differential diagnosis includes ranula, dermoid cyst, thyroglossal duct cyst, ectopic thyroid tissue, pleomorphic adenoma and mucoepidermoid carcinoma angiolipoma, fibrolipoma and malignant lymphoma(2),(10) to (13). The definitive diagnosis is by microscopic examination which shows adult fat tissue cells embedded in a stroma of connective tissue and surrounded by a fibrous capsule (13).

Lipoma has a characteristic radiographic appearance. On CT scan it shows a high density from 83 to 143 Hounsfield units with well or poorly defined margins depending on the capsule (2). Ultrasonography shows a lesion which is round or elliptical in shape with intact or mostly intact capsule(16). Most lipomas are hypoechoic with echogenic lines or spots(2),(16).

Surgical excision is the mainstay of treatment(2),(8). Recurrence is reduced by wide surgical excision at the same time preserving the surrounding structures. Well encapsulated lipomas, as the present case, easily shell out with no possibility of recurrence or damage to the surrounding

structures. It is still advisable to excise them with a little cuff of surrounding normal tissue to prevent recurrence but still conserving surrounding structures(7). Infiltrating lipomas are difficult to extirpate and when multiple are liable to recurrence due to difficulty in adequate excision. Recurrence rate of as high as 62.5% has been recorded(5). Simple lipomas regardless of their size are easily extirpated without recurrence. This unusually large tongue lipoma was surgically excised uneventfully.

The present case demonstrates the size lipomas can grow to if untreated.

## REFERENCES

1. Dattilo DJ, Ige J T, Nwana E J C. Intraoral lipoma of the tongue and submandibular space. *J Oral Maxillofac Surg* 1996; 54: 915-7
2. Del Castillo- Pando De Vera J L, Cebrian – Carretero J L, Gomez-Garan E. Chronic lingual ulceration caused by lipoma of the oral cavity. *Med Oral* 2004; 9: 163-7
3. Keskin G, Ustundag E, Ercin C. Multiple infiltrating lipomas of the tongue. *J Laryngol Otol* 2002; 116: 395-7
4. Epivatianos A, Markopoulos A K, Papanayonou P. Benign tumors of adipose tissue of the oral cavity: a clinicopathologic study of 13 cases. *J Oral Maxillofac Surg* 2000; 58: 1113-17.
5. Fregnani E R, Pires F R, Falzoni R, Lopes M A, Vargas P A. Lipomas of the oral cavity: clinical findings, Histological classification and proliferative activity of 46 cases. *Int J Oral Maxillofac Surg* 2003; 32: 49-53.
6. Lawoyin J O, Akande O O, Kolude B, Agbaje J O. Lipoma of the oral cavity: clinicopathological review of seven cases form Ibadan. *Niger J Med* 2001;10:189-91.
7. Moore P L, Goede A, Phillips D E, Carr R. Atypical lipoma of the tongue. *J Laryngol Otol* 2001;10:859-61.
8. Furlong M A, Fanburg-Smith J C, Childers E L. Lipoma of the oral and Maxillofacial region: Site and subclassifications of 125 cases. *Oral Surg Oral Med Oral Pathol Oral Rad Endod* 2004;98:441-50.
9. Gray A R, Barker G R. Sublingual lipoma. Report of an unusually large lesion. *J Oral Maxillofac Surg* 1991;49: 747-50.
10. Capodiferro S, Scully C, Maiorano E, Lo Muzio L, Favia G. Liposarcoma circumscriptum (lipoma-like) of the tongue: report of a case. *Oral Dis* 2004;10:398-400.
11. Favia G, Maiorano E, Orsini G, Piatelli A. Myxoid liposarcoma of the oral cavity with involvement of the periodontal tissues. *J Clin Periodontol* 2004;28:109-12.
12. Nunes F D, Loduca S V L, de Oliveira E M F, de Araujo V C. Well-differentiated liposarcoma of the tongue. *Oral Oncol* 2002;38:117-19.
13. Piattelli A, Rubies C, Fioroni M, Steches G. Spindle-cell lipoma of the cheek: a case report. *Oral Oncol* 2000; 3:495-6.
14. Katou F, Shirai N, Moategi K, Satoh R, Satoh S. Symmetrical lipomatosis of the tongue presenting as macroglossia. Report of two cases. *J Craniomaxillofac* 1993; 21:298-301.
15. Calvo-Garcia N, Prieto-Prado M, Alonso-Orcajo N, Junquera-Gutierrez L M. Symmetric lipomatosis of the tongue: report of a case and review of the literature. *Oral Surg Oral Me Oral Pathol Oral Radiol Endod* 1999;87:610-2.
16. Zhong L P, Zhao S F, Chen G F, Ping F Y. Ultrasonographic appearance of lipoma in the oral and maxillofacial region. *Oral Surg Oral Med Oral Pathol Oral Radiol Endod* 2004;98:738-40.