

## Glomerular Size and Structure in Diabetes Mellitus

### I. Early Abnormalities

R. Østerby and H. J. G. Gundersen

University Institute of Pathology and the Second University Clinic of Internal Medicine, Kommunehospitalet, Aarhus, Denmark

Received: December 9, 1974, and in revised form: March 19, 1975

*Summary.* The volume of the glomerular tuft and its components was estimated in juvenile diabetics at onset and after one to six years' duration of the disease. An enlargement of the glomerular tuft was demonstrated in the newly diagnosed diabetics. In these patients the volume of both the individual capillary lumina and of the individual glomerular cells was enlarged, whereas the number of cells was unchanged. Although a partial normalization is seen in diabetics after a few years' disease, such patients still have an elevated capillary volume. The possible relationship between

these findings and the well-documented elevation of the glomerular filtration rate in diabetics is discussed. It is suggested that the mechanism behind the morphological and functional changes is either a pressure-induced unfolding of the capillary wall or an increase of the capillary wall area, but the present study permits no distinction between these possibilities.

*Key words:* Juvenile diabetes, early diabetes, glomerular hypertrophy, glomerular morphology.

The glomerular filtration rate (GFR) is increased in juvenile diabetics at the very beginning of the disease [6], and the elevation of the GFR persists during the first decade [3, 7, 14].

The mechanisms behind this functional abnormality are poorly understood, but it seems most likely that the functional defect is localized in the glomerulus and not in the ensuing part of the nephron [8]. The present investigation was therefore undertaken in order to study the size and morphology of the renal glomerulus in early diabetes.

### Material

The control group consists of 8 subjects (see Table 1) without clinical and laboratory evidence of diabetes or renal disease.

Two groups of juvenile diabetics were investigated, one group at the acute onset of disease or within three to six weeks of treatment with insulin and diet (referred to as newly diagnosed diabetics), the other group after one to six years of treatment (referred to as short-term diabetics), see Table 1. A quantitative study of the glomerular ultrastructure in the same patients has been presented elsewhere [16].

From the newly diagnosed diabetics material for light microscopy was available from biopsies obtained both before and a few weeks after initiation of treatment. It was decided to carry out all of the investigations on the first biopsy, if possible, but the

quantitation of glomerular structures described below requires sections that are of high quality concerning fixation, staining and sectioning. Consequently, if the biopsy obtained before treatment was not useful, the biopsy obtained after initiation of treatment was used. The studies mentioned above [16] indicated that the ultrastructure of the renal glomerulus is the same in the untreated state and after three to six weeks of treatment.

### Methods<sup>1</sup>

Percutaneous needle biopsies of the kidney were obtained with the technique introduced by Brun and Raaschou [1]. The biopsies were performed over a period of four years in random order in the three groups considered. A small piece of tissue was cut from either end of the biopsy and was fixed for electron microscopy. The rest of the cylinder was fixed in either phosphate-buffered formalin or in Helly's fluid, embedded in paraffin and cut parallel to the long axis into serial sections at 3  $\mu$ . The measurements were performed on PAS-stained sections, spaced more than 200  $\mu$  apart. For the determination of glomerular size additional sections were used in some cases.

In the following 'glomerulus' means the glomerular tuft, and therefore does not include the capsule of Bowman and the capsular space.

<sup>1</sup> Detailed surveys of the employed morphometric methods and stereological principles are given in references numbers 5 and 15.

All measurements were performed in one run by the same technician who was unaware of the identity of the specimens.

Preliminary studies had shown that the glomeruli obtained from percutaneous needle biopsies fitted best to rotational ellipsoids with a linear excentricity of 0.8 and with the long axis parallel to the needle-biopsy.

sectional areas from a rotational ellipsoid, which has been cut parallel to the long axis, equals that of a sphere. The calculation of the mean glomerular volume was based on an average of 66 glomerular cross sections from each biopsy.

The nuclei within the glomerular tuft were counted and the relative areas of the lumina, the nuclei and the remaining solid part of the glomerulus, (i.e. glo-

Table 1. *Clinical data and the number and mean area of glomerular nuclei (adjusted to a body surface of 1.73 m<sup>2</sup>) in the controls and the two groups of diabetics*

	Age	Sex	Body surface, m <sup>2</sup>	Duration of diabetes years	Nuclei per mean glomerular cross-section	Mean nuclear area μ <sup>2</sup>
Controls	16	F	1.49		117	39
	17	F	1.83		50	25
	20	F	1.77		82	38
	28	F	1.73		100	26
	31	F	1.32		103	35
	12	M	1.44		116	24
	19	M	2.04		98	41
	22	M	1.86		83	15
	Mean	21		1.69		94
SD	6		0.24		22	9
Newly diagnosed diabetics	14	F	1.38	0	120	33
	16	F	1.49	0	116	52
	18	M	1.84	0	84	28
	19	M	1.76	0	83	26
	26	M	1.80	0	75	40
	32	M	1.81	0	130	42
	Mean	21		1.68		101
SD	7		0.19		23	10
Short-term diabetics	20	F	1.66	4.5	99	30
	17	M	1.83	5.0	112	26
	17	M	2.04	5.0	107	25
	22	M	1.72	1.5	123	31
	23	M	1.66	6.0	94	31
	27	M	1.85	4.0	74	23
	28	M	2.08	1.0	71	29
	28	M	1.80	3.5	60	19
	31	M	1.98	4.5	63	23
	32	M	1.57	1.0	—	—
	Mean	25		1.82	3.6	89
SD	6		0.17	1.8	23	4

From all slides each of the glomerular cross-sections was projected onto a drawing of a series of concentric ellipses, thereby permitting a decision of the class into which it fitted best. From the class-distribution of these random cross-sectional areas the distribution of true glomerular volume and its mean value were calculated according to Saltikov [12], taking into consideration that the distribution of cross-

merular cells of all types and the extracellular material), were estimated by point-counting. A total of approximately 1000 points was counted in each biopsy. This was done at a magnification of 900 ×, employing a grid with a point density of 16 points/10 000 μ<sup>2</sup> and a Leitz apochromatic, aplanatic 40/0.74 objective.

Since the relative volume of a structure in space equals its relative area on section, the absolute volume

of a structure in an average glomerulus was obtained by multiplying the relative area of the structure by the mean glomerular volume.

Finally, all lumina larger than  $10 \mu^2$  on section were counted, employing a grid with a point density of 2 points per  $\mu^2$ . The number of such large capillaries in an equatorial cross section of a spherical, imaginary glomerulus of average size (termed 'mean glomerular cross section') was then calculated for each biopsy.

The body surface of each subject was read off in a nomogram based on weight and height [2]. All individual values for absolute volumes or areas of the glomerulus and its structures were then adjusted to a standard body surface of  $1.73 \text{ m}^2$ . Since distributions of volumes generally are lognormal the comparisons of volumes between groups have been carried out on the logarithmically transformed values. The mean values calculated from these distributions equal the geometric means of the original values.

Student's t-test was employed in the statistical treatment, using a 5% limit of significance.

**Results**

The volume of the glomerular tuft in the controls and the two groups of diabetics is shown in Fig. 1. The geometric mean glomerular volume in the newly diagnosed diabetics was  $1.41 \text{ M}\mu^3$  (million  $\mu^3$ ) whereas the controls had a geometric mean of  $0.83 \text{ M}\mu^3$ . The difference between these two values is statistically significant,  $2 p = 0.014$ . The diabetics with one to six years' duration of disease had a geometric mean of  $1.05 \text{ M}\mu^3$ . This value was not significantly different from either that of the normals or that of the newly diagnosed diabetics. (The cross-sectional diameters corresponding to the glomerular volumes mentioned above are 139, 117 and  $126 \mu$ ).

By the quantitation of the glomerular structures (capillary lumina, solid parts, nuclei) it was possible to determine which part of the glomerulus that was involved in the changes just mentioned.

The volume of capillary lumen per glomerulus in the newly diagnosed diabetics was almost twice that of the controls, the geometric mean values were  $0.38 \text{ M}\mu^3$  and  $0.20 \text{ M}\mu^3$  respectively,  $2 p = 0.0086$  (Fig. 1). Likewise, the number of large capillaries per mean glomerular cross section was doubled in the newly diagnosed diabetics, who showed a geometric mean value of 5.21 compared to 2.82 in the controls,  $2 p = 0.014$  (Fig. 2).

The solid volume per glomerulus was also enlarged in the newly diagnosed diabetics,  $0.84 \text{ M}\mu^3$  versus the control value of  $0.51 \text{ M}\mu^3$ ,  $2 p = 0.021$  (Fig. 1).

On the other hand, the number of cells per glomerulus was the same in the two groups, expressed as the number of nuclei per mean glomerular cross section, see Table 1.

It is noteworthy that within the group of newly diagnosed diabetics a statistically significant relationship existed between the individual mean nuclear area

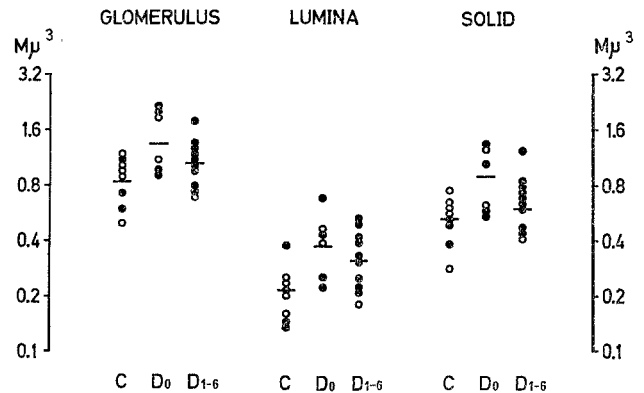


Fig. 1. Volumes of the total glomerular tuft, of the capillary lumen and of the solid part of the glomerulus. The volumes are given on a log scale in millions of  $\mu^3$  per  $1.73 \text{ m}^2$  body surface. C: controls,  $D_0$ : newly diagnosed diabetics,  $D_{1-6}$ : patients with 1-6 years' duration of diabetes. Open circles: females, filled circles: males. The horizontal bars indicate mean values

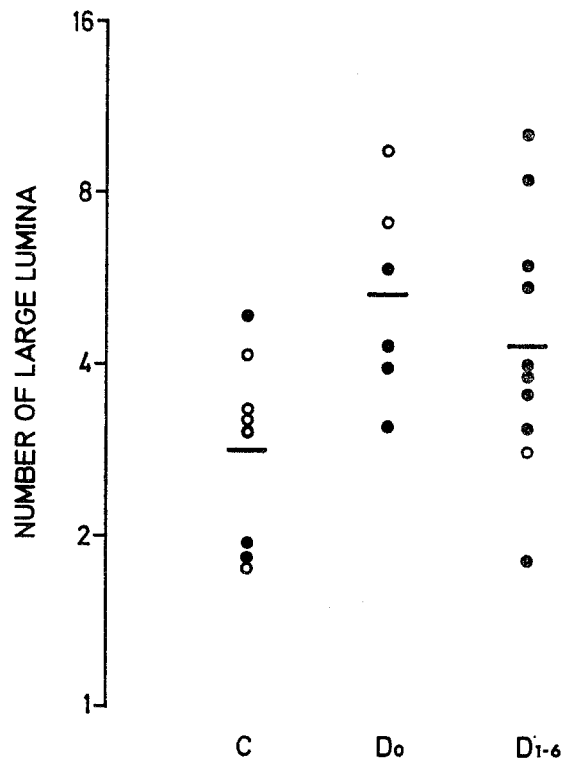


Fig. 2. Capillary lumina larger than  $10 \mu^2$  on section. The number per mean glomerular cross section is shown on a log scale. Symbols as in Fig. 1

on the one hand and the volume of the whole glomerulus ( $r = 0.87$ ,  $2 p = 0.025$ ) and that of the solid part ( $r = 0.86$ ,  $2 p = 0.027$ ) on the other hand (Fig. 3), whereas none of these relationships were present in the control group or the group of short-term diabetics. The mean nuclear area in the newly diagnosed diabetics, however, was only slightly and statistically insignificantly greater than that of the controls, see Table 1.

The study of individual glomerular structures in the short-term diabetics revealed that only slight and statistically insignificant regression of the changes found in the newly diagnosed diabetics had occurred (see Fig. 1 and 2). It is of special interest that the volume of glomerular capillary lumen in the short-term diabetics was still increased compared to that of the normals,  $0.31 M\mu^3$  and  $0.20 M\mu^3$ , respectively,  $2 p = 0.021$ .

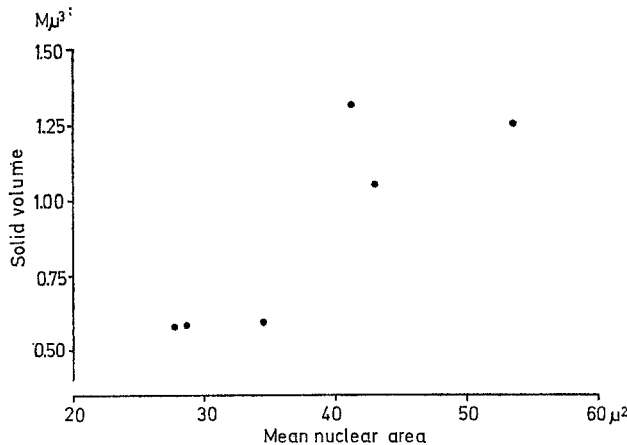


Fig. 3. The relationship between the mean nuclear area and the volume of the solid part of the glomerulus in the newly diagnosed diabetics ( $r = 0.86$ ,  $2 p = 0.027$ )

As in the newly diagnosed diabetics both the number of cells per glomerulus and the nuclear area were normal in the short-term diabetics (see Table 1), but a comparison between the two groups of diabetics did demonstrate a decrease in nuclear area,  $36.9 \mu^2$  versus  $26.3 \mu^2$ ,  $2 p = 0.046$ .

### Discussion

The demonstrated deviations from the normal of the various measures of the glomerular tuft in newly diagnosed diabetics mean that morphological changes of the first part of the nephron are present concomitant with the acute functional changes of the same part of the nephron, i.e. the increased glomerular fil-

tration rate. The roentgenographic demonstration of a 20% enlargement of the whole kidney in early diabetes [10] furthermore indicates that changes are simultaneously present in other segments of the nephron, since the glomeruli constitute only about 2% of the total volume of the kidney [4].

The measurements of the individual glomerular structures showed that both the solid part and the capillary lumen was enlarged. In a light microscopic study it is not possible to distinguish between the cytoplasm and the basement membrane material in the solid part of the tuft. However, quantitative electron microscopic studies [16] have indicated that both the amount of mesangial basement membrane material and the thickness of the peripheral basement membrane are normal in newly diagnosed diabetics.

The increased volume of the solid part of the glomerular tuft in combination with the unchanged number of nuclei per glomerulus means that the volume of the individual cell is increased, i.e. hypertrophy is present in diabetics.

The same conclusion can be drawn from the positive correlation between solid volume and mean nuclear area in the individual newly diagnosed diabetics (Fig. 3). Furthermore, results from studies of acute diabetes in rats show that both the RNA/DNA-ratio [13] and the total protein content [11] are increased in the kidney as a whole. It is not known to which extent these findings are valid for the glomerulus.

The increased capillary volume per glomerulus found in both groups of diabetics in the present study could well be the morphological change underlying the elevated glomerular filtration rate (GFR) in these patients. This elevation of the GFR, which has consistently been demonstrated in diabetics, both at onset and during the first decade of the disease [8], has furthermore been shown to be most pronounced in newly diagnosed patients, who also showed the largest capillary volumes.

The mechanism behind this enlargement could either be a) increased pressure within the capillaries leading to an unfolding of the capillary wall or b) cellular hypertrophy resulting in an increase of the capillary wall area.

Theoretically, an increase in the total capillary volume could be due either to an increase in the cross-sectional area of the individual capillaries of the glomerulus or to an increase in the number of capillaries per glomerulus. However, the finding of an unchanged number of nuclei, but an increase in number of capillaries with large cross-sectional areas, shows that the increase in total capillary volume in newly diagnosed diabetics is due to an increase in the size of individual capillaries.

Both of the mechanisms proposed above for the increase in capillary volume would result in an increased GFR, due either to the elevated pressure gradient across the filtration barrier or to the enlargement of the total filtration surface.

However, the distinction between the two possibilities — either a pressure-induced unfolding or an enlargement of the capillary wall area — as the cause of the increase in capillary volume is only possible by direct morphometric determination of the total capillary surface.

Such measurements (the number of intersections between the surface and a test-line) require a very sharp demarcation of the luminal border of the capillary wall, which is only obtainable in plastic-embedded biopsy specimens. The material available consisted of sections from paraffin-embedded biopsies, and thus the requirement mentioned above could not be fulfilled.

It therefore remains an open question which mechanism is responsible for the increase in capillary volume (and the increase in GFR).

It is noteworthy that all estimates of volumes in the short-term diabetics are closer to normal than those of the newly diagnosed diabetics, but that the capillary volume is still elevated. This is in good agreement with the finding of a decrease in both the kidney size and GFR during the first few months of insulin-treatment of the metabolic disturbance [9, 6], though the GFR is not completely normalized [6].

It is not known for how long the described morphological changes persist after the first few years considered in the present study. The GFR, however, remains elevated in long-term diabetics, irrespective of the duration of the disease, as long as proteinuria has not occurred [7]. It is, therefore, likely that the enlargement of the glomeruli and of their capillaries and cells, which is present from the beginning of the disease, also persists for many years.

It is, however, difficult to substantiate this proposal in long-term diabetics due to the very composite morphological picture in these patients, which is characterized to a large extent by the advanced basement membrane lesions of diabetic angiopathy. One element of this picture is a pronounced enlargement of the still functioning glomeruli, which is probably related to the simultaneous occlusion of other glomeruli due to the excessive accumulation of basement membrane material (Gundersen, H. J. G., Østerby, R.: unpublished observations).

*Acknowledgements.* We are very much indebted to Drs. G. Gregersen, B. Møller and H. Skjoldborg for the kidney

biopsy material. We wish to thank Mrs. Dorte Eilertsen, Mrs. Grethe Glerup and Mrs. Helen Hou Jørgensen for their skilful assistance. The study was supported by grants from Nordisk Insulinfond.

## References

1. Brun, C., Raaschou, F.: Kidney biopsies. *Amer. J. Med.* **24**, 676–691 (1958)
2. Diem, K., Lentner, C.: *Scientific tables*. Basel: Geigy 1970
3. Ditzel, J., Schwartz, M.: Abnormally increased glomerular filtration rate in short-term insulin-treated diabetic subjects. *Diabetes* **16**, 264–267 (1967)
4. Elias, H., Hennig, A.: Stereology of the human renal glomerulus. In: *Quantitative methods in morphology* (eds. E. Weibel, H. Elias) pp. 130–166. Berlin: Springer Verlag 1967
5. Elias, H., Hennig, A., Schwartz, D. E.: Stereology: Applications to biomedical research. *Physiol. Rev.* **51**, 158–200 (1971)
6. Mogensen, C. E.: Kidney function and glomerular permeability to macromolecules in early juvenile diabetes. *Scand. J. clin. Lab. Invest.* **28**, 79–90 (1971)
7. Mogensen, C. E.: Glomerular filtration rate and renal plasma flow in short-term and long-term juvenile diabetes mellitus. *Scand. J. clin. Lab. Invest.* **28**, 91–100 (1971)
8. Mogensen, C. E.: Kidney function and glomerular permeability to macromolecules in juvenile diabetes. (Thesis). *Dan. med. Bull.* **19**, suppl. 3, 1–38 (1972)
9. Mogensen, C. E., Andersen, M. J. F.: Increased kidney size and glomerular filtration rate in untreated juvenile diabetes: Normalization by insulin treatment. *Diabetologia* **11**, 221–224 (1975)
10. Mogensen, C. E., Andersen, M. J. F.: Increased kidney size and glomerular filtration rate in early juvenile diabetes. *Diabetes* **22**, 706–712 (1973)
11. Ross, J., Goldman, J. K.: Effect of streptozotocin-induced diabetes on kidney weight and compensatory hypertrophy in the rat. *Endocrinology* **88**, 1079–1082 (1971)
12. Saltikov, S. A.: The determination of the size distribution of particles in an opaque material from a measurement of the size distribution of their sections. In: *Stereology* (ed. H. Elias) pp. 163–173. Berlin: Springer Verlag 1967
13. Seyer-Hansen, K.: Renal hypertrophy in experimental diabetes. (Abstract) *Diabetologia* **10**, 386–387 (1974)
14. Stalder, G., Schmid, R., v. Wolff, M.: Funktionelle Mikroangiopathie der Nieren beim behandelten Diabetes mellitus im Kindesalter. *Dtsch. med. Wschr.* **85**, 346–350 (1960)
15. Weibel, E. R.: Stereological principles for morphometry in electron microscopic cytology. *Int. Rev. Cytol.* **26**, 235–302 (1969)
16. Østerby, R.: Early phases in the development of diabetic glomerulopathy. A quantitative electron microscopic study. *Acta med. Scand., suppl.* **574**, 1975

R. Østerby, M.D.  
Dept. of Pathology  
Kommunehospitalet  
DK—8000 Århus C  
Denmark