



## Guidelines on the management of common bile duct stones (CBDS)

E J Williams, J Green, I Beckingham, R Parks, D Martin and M Lombard

*Gut* 2008;57;1004-1021; originally published online 5 Mar 2008;  
doi:10.1136/gut.2007.121657

---

Updated information and services can be found at:

<http://gut.bmj.com/cgi/content/full/57/7/1004>

---

*These include:*

### References

This article cites 235 articles, 38 of which can be accessed free at:

<http://gut.bmj.com/cgi/content/full/57/7/1004#BIBL>

### Open Access

This article is free to access

### Email alerting service

Receive free email alerts when new articles cite this article - sign up in the box at the top right corner of the article

---

### Notes

---

To order reprints of this article go to:

<http://journals.bmj.com/cgi/reprintform>

To subscribe to *Gut* go to:

<http://journals.bmj.com/subscriptions/>

# Guidelines on the management of common bile duct stones (CBDS)

E J Williams, J Green, I Beckingham, R Parks, D Martin, M Lombard

Correspondence to:  
Dr Martin Lombard, Chairman,  
Audit Steering Group,  
Department of Gastroenterology,  
5z Link, Royal Liverpool  
University Hospital, Prescot  
Street, Liverpool L7 8XP, UK;  
[martin.lombard@rlbuht.nhs.uk](mailto:martin.lombard@rlbuht.nhs.uk)

#### Writing group:

Earl Williams, British Society of  
Gastroenterology (BSG) fellow

Jonathan Green, representing  
the BSG Endoscopy Committee  
and ERCP Stakeholder Group

Ian Beckingham, representing  
the Association of Laparoscopic  
Surgeons (ALS) and Association  
of Upper Gastrointestinal  
Surgeons of Great Britain and  
Ireland (AUGIS)

Rowan Parks, representing the  
Association of Upper  
Gastrointestinal Surgeons of  
Great Britain and Ireland (AUGIS)

Derrick Martin, representing the  
Royal College of Radiologists  
(RCR)

Martin Lombard, Chair of the  
ERCP Audit Steering Committee

Revised 4 January 2008  
Accepted 22 January 2008  
Published Online First  
5 March 2008

## ABSTRACT

The last 30 years have seen major developments in the management of gallstone-related disease, which in the United States alone costs over 6 billion dollars per annum to treat. Endoscopic retrograde cholangiopancreatography (ERCP) has become a widely available and routine procedure, whilst open cholecystectomy has largely been replaced by a laparoscopic approach, which may or may not include laparoscopic exploration of the common bile duct (LCBDE). In addition, new imaging techniques such as magnetic resonance cholangiography (MR) and endoscopic ultrasound (EUS) offer the opportunity to accurately visualise the biliary system without instrumentation of the ducts. As a consequence clinicians are now faced with a number of potentially valid options for managing patients with suspected CBDS. It is with this in mind that the following guidelines have been written.

## 1.0 FOREWORD

This document, on the diagnosis and treatment of patients with common bile duct stones (CBDS), was commissioned by the British Society of Gastroenterology (BSG) as part of a wider initiative to develop guidelines for clinicians in several areas of clinical practice.

Guidelines are not rigid protocols and they should not be construed as interfering with local clinical judgment. Hence they do not represent a directive of proscribed routes, but a basis on which clinicians can consider the options available more clearly.

## 2.0 INTRODUCTION AND OBJECTIVES

The last 30 years have seen major developments in the management of gallstone-related disease, which in the United States, alone, costs over 6 billion dollars per annum to treat.<sup>1</sup> Endoscopic retrograde cholangiopancreatography (ERCP) has become a widely available and routine procedure, whilst open cholecystectomy has largely been replaced by a laparoscopic approach, which may or may not include laparoscopic exploration of the common bile duct (LCBDE). In addition new imaging techniques such as magnetic resonance cholangiography (MR) and endoscopic ultrasound (EUS) offer the opportunity to accurately visualise the biliary system without instrumentation of the ducts. As a consequence clinicians are now faced with a number of potentially valid options for managing patients with suspected CBDS. It is with this in mind that the following guidelines have been written.

## 3.0 FORMULATION OF GUIDELINES

Guidelines were commissioned by the British Society of Gastroenterology and have been endorsed by the Clinical Standards and Services Committee (CSSC) of the BSG, the BSG Endoscopy Committee, the ERCP stakeholder group, the Association of Upper Gastrointestinal Surgeons of Great Britain and Ireland (AUGIS), Association of Laparoscopic Surgeons (ALS), and the Royal College of Radiologists (RCR). Contributions from all of these groups have been incorporated into the final version of the guideline document.

The method of formulation can be summarised as follows. In 2004 a preliminary literature search was performed by Earl Williams. Original papers were identified by a search of Pubmed/Medline for articles containing the terms common bile duct stones, gallstones, choledocholithiasis, laparoscopic cholecystectomy or ERCP. Articles were first selected by title. Their relevance was then confirmed by review of the corresponding abstract. This initial enquiry focussed on full length reports of prospective design, though retrospective analyses and case reports were also retrieved if the topic they dealt with had not been addressed by prospective study. Missing articles were identified by manually searching the reference lists of retrieved papers.

A summary of the findings of this search was presented to the BSG Endoscopy Committee in 2004. Additional references were suggested and the principal clinical questions arising from the literature search agreed. Provisional guidelines were subsequently developed by a multi-disciplinary guideline writing group. This was comprised of representatives of the BSG (Earl Williams, Jonathan Green and Martin Lombard), AUGIS (Rowan Parks and Ian Beckingham), and RCR (Derrick Martin). Current British Society of Gastroenterology Guidelines,<sup>2-4</sup> the European Association of Endoscopic Surgeons Guidelines on Common Bile Duct Stones<sup>5</sup> and the National Institute of Health's "State of the Science" conference on ERCP<sup>6</sup> were reviewed as part of this process. In 2006 an ERCP stakeholder group was convened and considered the provisional guidelines, with representatives of the BSG (Jonathan Green and Martin Lombard), AUGIS (Nick Hayes), ALS (Don Menzies) and RCR (Derrick Martin), along with the National Lead for Endoscopy (Roland Valori), all making contributions. Specifically, each recommendation was considered and amendments were suggested to ensure that, for all recommendations, consensus was achieved. The resulting statement

was then forwarded to the CSSC and GUT for comment and international peer review. Thereafter the final wording of the guideline document was agreed at a consensus meeting, held in 2007, where the document was again reviewed by the principal authors (Earl Williams, Jonathan Green, Rowan Parks, Martin Lombard and Derrick Martin), with each recommendation requiring a unanimous vote to be ratified.

### 3.1 Categories of evidence

The strength of the evidence used in these guidelines was that recommended by the North of England evidence-based guidelines development project. This is summarised below:

*Ia*: Evidence from meta-analysis of randomised controlled trials (RCTs).

*Ib*: Evidence from at least one randomised trial.

*Ia*: Evidence from at least one well-designed controlled study without randomisation.

*Ib*: Evidence obtained from at least one other type of well-designed quasi-experimental study.

*III*: Evidence from well-designed non-experimental descriptive studies such as comparative studies, correlation studies, and case studies.

*IV*: Evidence obtained from expert committee reports or opinions, or clinical experiences of respected authorities.

### 3.2 Grading of recommendations

Recommendations are based on the level of evidence presented in support and are graded accordingly.

*Grade A*: Requires at least one randomised controlled trial of good quality addressing the topic of recommendation.

*Grade B*: Requires the availability of clinical studies without randomisation on the topic.

*Grade C*: Requires evidence from category *IV* in the absence of directly applicable clinical studies.

## 4.0 SUMMARY OF RECOMMENDATIONS

### 4.1 General principles

4.1.1 Discussion of hepatobiliary cases in a multidisciplinary setting is to be encouraged. (Evidence grade *IV*. Recommendation grade *C*.)

4.1.2 It is recommended that wherever patients have symptoms, and investigation suggests ductal stones, extraction should be performed if possible. (Evidence grade *III*. Recommendation grade *B*.)

4.1.3 Trans-abdominal ultrasound scanning (USS) is recommended as a preliminary investigation for CBDS and can help identify patients who have a high likelihood of ductal stones. However, clinicians should not consider it a sensitive test for this condition. (Evidence grade *III*. Recommendation grade *B*.)

4.1.4 Where patients with suspected CBDS have not been previously investigated initial assessment should be based on clinical features, liver function tests (LFTs) and USS findings. (Evidence grade *III*. Recommendation grade *B*.)

4.1.5 EUS and MR are both recommended as being highly effective at confirming the presence of CBDS. When selecting between the two modalities patient suitability, accessibility and local expertise are the most important considerations. (Evidence grade *Ib*. Recommendation grade *B*.)

### 4.2 Endoscopic treatment

4.2.1 ERCP training programmes should follow the recommendations contained within current Joint Advisory Group (JAG) Guidelines. (Evidence grade *IV*. Recommendation grade *C*.)

4.2.2 It is important that once formal training is completed endoscopists perform an adequate number of biliary sphincteromies (BS) per year to maintain their performance. As a guide 40–50 BS per endoscopist per annum is suggested. (Evidence grade *III*. Recommendation grade *B*.)

4.2.3 When performing endoscopic stone extraction (ESE) the endoscopist should have the support of a technician or radiologist who can assist in fluoroscopic screening, a nurse to monitor patient safety and an additional endoscopy assistant/nurse to manage guide wires etc. (Evidence grade *IV*. Recommendation grade *C*.)

4.2.4 It is recommended that ERCP be reserved for patients in whom the clinician is confident an intervention will be required. In patients with suspected CBDS it is not recommended for use solely as a diagnostic test. (Evidence grade *Ib*. Recommendation grade *B*.)

4.2.5 When scheduling ERCP the endoscopist needs to be aware of the patient-related factors that increase the risk of an ERCP or BS-related complication. (Evidence grade *III*. Recommendation grade *B*.)

4.2.6 It is recommended that clinicians follow the BSG Guidelines on consent and use Department of Health forms (or their equivalent) to obtain written confirmation of consent. (Evidence grade *IV*. Recommendation grade *C*.)

4.2.7 Patients undergoing BS for ductal stones should have a FBC and PT/INR performed no more than 72 h prior to the procedure. It is recommended that where patients have deranged clotting subsequent management should conform to locally agreed guidelines. (Evidence grade *III*. Recommendation grade *B*.)

4.2.8 In patients established on anticoagulation therapy a local policy should be agreed for managing endoscopic stone extraction. For those at low risk of thromboembolism anticoagulants should be discontinued prior to endoscopic stone extraction if biliary sphincterotomy is planned. (Evidence grade *III*. Recommendation grade *B*.)

4.2.9 Biliary sphincterotomy can be safely performed on patients taking aspirin or non-steroidal anti-inflammatory drugs. Administration of low dose heparin should not be considered a contraindication to biliary sphincterotomy. (Evidence grade *III*. Recommendation grade *B*.)

4.2.10 Where possible, newer anti-platelet agents such as clopidogrel (Plavix) should be stopped 7–10 days prior to biliary sphincterotomy (Evidence grade *IV*. Recommendation grade *C*.)

4.2.11 Prophylactic antibiotics should be given to patients with biliary obstruction or previous features of biliary sepsis. (Evidence grade *Ib*. Recommendation grade *A*.) Patients should be managed in accordance with the BSG Guidelines on antibiotic prophylaxis during endoscopy (Evidence grade *IV*. Recommendation grade *C*.)

4.2.12 No drug is currently recommended for the routine prevention of pancreatitis among patients undergoing endoscopic stone extraction. (Evidence grade *Ia*. Recommendation grade *A*.)

4.2.13 Patients should be sedated and monitored in accordance with BSG Guidelines. (Evidence grade *IV*. Recommendation grade *C*.)

4.2.14 In patients with risk factors for post-ERCP pancreatitis, but not BS-induced haemorrhage, sphincterotomy initiated using pure cut may be preferable. (Evidence grade *Ib*. Recommendation grade *A*.)

4.2.15 Balloon dilation of the papilla (ED) can be an alternative to biliary sphincterotomy in some patients. However, the risk of (severe) post-ERCP pancreatitis is increased in comparison to BS and in the majority of patients undergoing

## Guidelines

stone extraction ED should be avoided (Evidence grade Ia. Recommendation grade A.)

4.2.16 It is important that endoscopists ensure adequate biliary drainage is achieved in patients with CBDS that have not been extracted. The short-term use of a biliary stent followed by further endoscopy or surgery is advocated. (Evidence grade III. Recommendation grade B.) In contrast the use of a biliary stent as sole treatment for CBDS should be restricted to a selected group of patients with limited life expectancy and/or prohibitive surgical risk. (Evidence grade Ib. Recommendation grade A.)

4.2.17 Multi-centre studies indicate pre-cut is a risk factor for complication. Therefore the procedure should be considered an advanced technique, to be employed only by those with appropriate training and experience. Its use should be restricted to those patients for whom subsequent endoscopic treatment is essential (Evidence grade III. Recommendation grade B.)

4.2.18 Patients at high risk of post-ERCP pancreatitis (eg, because of prolonged cannulation and/or pre-cut) may benefit from short-term pancreatic stent placement. (Evidence grade Ib. Recommendation grade A.)

### 4.3 Surgical treatment

4.3.1 An assessment of operative risk needs to be made prior to scheduling intervention. Where this risk is deemed prohibitive endoscopic therapy should be considered as an alternative. (Evidence grade III. Recommendation grade B.)

4.3.2 Intraoperative cholangiography (IOC) or laparoscopic ultrasound (LUS) can be used to detect CBDS in patients who are suitable for surgical exploration or postoperative ERCP. Though not considered mandatory for all such patients, IOC is recommended for those who have an intermediate to high pre-test probability of CBDS and who have not had the diagnosis confirmed pre-operatively by other means. (Evidence grade IIb. Recommendation grade B.)

4.3.3 In patients undergoing laparoscopic cholecystectomy trans-cystic and trans-ductal exploration of the CBD are both recognised as appropriate techniques for removal of CBDS. (Evidence grade Ib. Recommendation grade A.)

4.3.4 When minimally invasive techniques fail to achieve duct clearance (open) surgical exploration remains an important treatment option. (Evidence grade III. Recommendation grade B.)

### 4.4 Supplementary treatments

4.4.1 It is recommended that all endoscopists performing ERCP should be able to supplement standard stone extraction techniques with mechanical lithotripsy when required. (Evidence grade III. Recommendation grade B.)

4.4.2 Where available, extra-corporeal shock wave lithotripsy (ESWL) can be considered for patients with difficult disease who are not fit enough/unwilling to undergo open surgery. Antibiotic prophylaxis during ESWL should be administered. (Evidence grade III. Recommendation grade B.)

4.4.3 Electro-hydraulic lithotripsy (EHL) and laser lithotripsy can effect duct clearance where other forms of lithotripsy have failed. (Evidence grade III. Recommendation grade B.)

4.4.4 Percutaneous treatment has been described as an alternative or adjunct to other forms of stone extraction. It is recommended that if facilities and expertise are available then its use should be considered when standard endoscopic and surgical treatment fails, or is considered inappropriate. (Evidence grade III. Recommendation grade B.)

4.4.5 Contact dissolution therapy is not recommended as treatment for CBDS. (Evidence grade III. Recommendation grade B.)

4.4.6 Where CBD stone size has precluded endoscopic duct clearance oral ursodeoxycholic acid may facilitate subsequent endoscopic retrieval. (Evidence grade IIa. Recommendation grade B.) Following successful duct clearance administration of long-term ursodeoxycholic acid may be considered. (Evidence grade Ib. Recommendation grade B.)

### 4.5 Management of specific clinical scenarios

4.5.1 Biliary sphincterotomy and endoscopic stone extraction (ESE) is recommended as the primary form of treatment for patients with CBDS post-cholecystectomy. (Evidence grade IV. Recommendation grade C.)

4.5.2 Cholecystectomy is recommended for all patients with CBDS and symptomatic gallbladder stones, unless there are specific reasons for considering surgery inappropriate (Evidence grade III. Recommendation grade B.)

4.5.3 Patients with CBDS undergoing laparoscopic cholecystectomy may be managed by laparoscopic common bile duct exploration (LCBDE) at the time of surgery, or undergo peri-operative ERCP. There is no evidence of a difference in efficacy, morbidity or mortality when these approaches are compared, though LCBDE is associated with a shorter hospital stay. It is recommended that the two approaches are considered equally valid treatment options, and that training of surgeons in LCBDE is to be encouraged. (Evidence grade Ib. Recommendation grade A.)

4.5.4 Where appropriate local facilities exist, those patients with (predicted) severe pancreatitis of suspected or proven biliary origin should undergo biliary sphincterotomy +/- endoscopic stone extraction within 72 h of presentation. (Evidence grade Ib. Recommendation grade B.)

4.5.5 It is recommended that non-jaundiced patients with mild biliary pancreatitis require supportive treatment only during the acute stage of their illness. (Evidence grade Ib. Recommendation grade A.) Where such patients undergo cholecystectomy this should be performed within 2 weeks of presentation. In this setting routine pre-operative ERCP is unnecessary, though MR cholangiography, IOC or laparoscopic ultrasound should be considered. (Evidence grade Ib. Recommendation grade A.)

4.5.6 Patients with acute cholangitis who fail to respond to antibiotic therapy or who have signs of septic shock require urgent biliary decompression. Biliary sphincterotomy, supplemented by stenting or stone extraction, is therefore indicated. Percutaneous drainage can be considered as an alternative to ERCP but open surgery should be avoided. (Evidence grade Ib. Recommendation grade A.)

4.5.7 In pregnant patients with symptomatic common bile duct stones, recommended treatment options include ERCP (with biliary sphincterotomy and endoscopic stone extraction) and LCBDE. (Evidence grade III. Recommendation grade B.)

## 5.0 NATURAL HISTORY OF GALLBLADDER STONES

Gallstones are present in approximately 15% of the United States population.<sup>7</sup> Whilst figures quoted vary according to the age, sex and ethnicity of the group examined, the overall prevalence in the United Kingdom is likely to be similar.<sup>8,9</sup>

The majority of people with gallstones are unaware of their presence<sup>10</sup> and over a 10-year period of follow-up only 15–26% of initially asymptomatic individuals will develop biliary

**Table 1** Clinical and trans-abdominal ultrasound scanning (USS) features with a specificity for common bile duct stones (CBDS) >0.95<sup>24,6</sup>

Indicator for CBDS	Specificity	Sensitivity	+ve likelihood ratio	-ve likelihood ratio
CBDS on USS	1.00	0.3	13.6	0.70
Cholangitis	0.99	0.11	18.3	0.93
Pre-operative jaundice	0.97	0.36	10.1	0.69
Dilated CBD on USS	0.96	0.42	6.9	0.77

colic.<sup>11–12</sup> However, the onset of pain heralds the beginning of recurrent symptoms in the majority of patients, and identifies those at risk of more serious complications.<sup>13–14</sup> These include pancreatitis, cholecystitis and biliary obstruction. Over a 10-year period such complications can be expected to occur in 2–3% of patients with initially silent gallbladder stones.<sup>11–12</sup>

It is these observations that provide the rationale for offering cholecystectomy to all patients with symptomatic gallstones, with the exception of those in whom surgical risk is considered prohibitive.

## 6.0 NATURAL HISTORY OF CBDS

*It is recommended that wherever patients have symptoms, and investigation suggests ductal stones, extraction should be performed if possible. (Evidence grade III. Recommendation grade B.)*

In Western countries CBDS typically originate in the gallbladder and migrate. Such secondary stones should be differentiated from primary CBDS that develop *de novo* in the biliary system. Primary stones are more common in south-east Asian populations, have a different composition to secondary stones, and may be a consequence of biliary infection and stasis.<sup>15–16</sup>

The quoted prevalence of CBDS in patients with symptomatic gallstones varies, but probably lies between 10 and 20%.<sup>17–21</sup> However, in non-jaundiced patients with normal ducts on trans-abdominal ultrasound the prevalence of CBDS at the time of cholecystectomy is unlikely to exceed 5%.<sup>22</sup>

Compared to stones in the gallbladder the natural history of secondary CBDS is not well understood. Whilst Collins *et al*<sup>22</sup> have suggested that a third of patients with CBDS at the time of cholecystectomy pass their stones spontaneously within 6 weeks of surgery, it is not known with what frequency stones enter the common bile duct (CBD), or why some stones pass silently into the duodenum and others do not. What is clear is that when ductal stones do become symptomatic the consequences are often serious and can include pain, partial or complete biliary obstruction, cholangitis, hepatic abscesses or pancreatitis. Chronic obstruction may also cause secondary biliary cirrhosis and portal hypertension.

It is therefore recommended that wherever patients have symptoms and investigation suggests ductal stones, extraction should be performed if possible. This applies even in (the rare) cases where cirrhosis has developed, as reversal of hepatic fibrosis has been observed following relief of chronic biliary obstruction.<sup>23–24</sup>

## 7.0 IDENTIFYING PATIENTS WITH PROBABLE CBDS

*Trans-abdominal ultrasound scanning (USS) is recommended as a preliminary investigation for CBDS and can help identify patients who have a high likelihood of ductal stones. However, clinicians should not consider it a sensitive test for this condition. (Evidence grade III. Recommendation grade B.)*

*EUS and MR are both recommended as being highly effective for confirming the presence of CBDS. When selecting between the two modalities patient suitability, accessibility and local expertise are the*

*most important considerations. (Evidence grade IIb. Recommendation grade B.)*

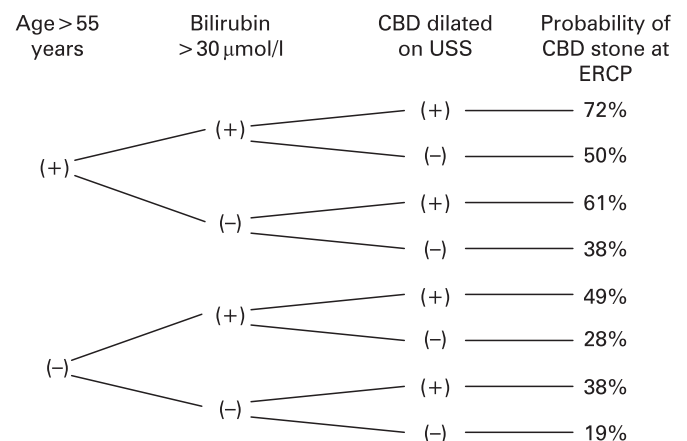
Intraoperative cholangiography (IOC) and ERCP are generally considered to be the reference standards for diagnosis of CBDS. However, a diagnostic strategy based on routine instrumentation of the biliary system, particularly in patients who have a low pre-test probability of disease, is undesirable.

The following section examines the ability of trans-abdominal ultrasound, computed tomography, magnetic resonance imaging and endoscopic ultrasound to select patients with a high probability of CBDS. The role of such imaging prior to ERCP and surgery is discussed in sections 8.3 and 9.3. When comparing imaging modalities it should be borne in mind that even ERCP and IOC can occasionally miss small stones, particularly when non-dilute contrast is used.

## 7.1 Trans-abdominal ultrasound scanning combined with clinical features

A number of specific trans-abdominal ultrasound scan (USS) and clinical findings, when present, have been shown to greatly increase the probability of stones being found in the CBD on further investigation. However, all suffer from low sensitivity, ie, the absence of such a finding does not infer the absence of CBDS (table 1). No one USS, biochemical or clinical finding can therefore be used in isolation as a predictive test for ductal stones. Rather clinicians should consider such variables in combination when deciding on whether a patient needs further investigation.

For example, in patients awaiting laparoscopic cholecystectomy the combination of age greater than 55 years, bilirubin greater than 30 µmol/l, and CBD dilatation on USS has been found to increase the probability of a CBD stone being found at ERCP to over 70% (fig. 1). Other predictive models based on combinations of clinical, biochemical and USS findings can similarly identify those at higher risk of harbouring CBDS.<sup>25–27</sup>



**Figure 1** Prediction of common bile duct stones in patients undergoing laparoscopic cholecystectomy. Derived from Barkun *et al*.<sup>24,7</sup> CBD, common bile duct; ERCP, endoscopic retrograde cholangiopancreatography; USS, ultrasound scanning.

## Guidelines

Conversely, in patients who have not had surgical exploration of the duct, the combination of both normal common bile duct on USS and normal liver function tests (LFTs) indicates a very low probability of bile duct stones (variously quoted as 0 to <5%).<sup>28–30</sup>

### 7.2 Computerised tomography cholangiography

Studies in this area are heterogeneous, both in terms of computerised tomography (CT) technique and reference standard.<sup>31–40</sup> Specificities quoted for detection of CBDS vary between 84% (when performed without biliary contrast)<sup>32</sup> and 100%.<sup>31–35</sup> Sensitivities quoted in the same studies range from 65 to 93%. Where an independent reference standard is employed<sup>33–34</sup> ERCP appears the better of the two investigations. Where CT is compared with EUS (and ERCP or IOC is used as the reference standard) EUS appears a more sensitive test, particularly in patients with normal calibre common bile ducts and ductal stones less than 1 cm in diameter.<sup>38–39</sup> Nonetheless, it should be noted that more recent studies suggest helical CT can diagnose CBDS with sensitivity and specificity that is comparable to MR cholangiography.<sup>37–40</sup>

In conclusion then, the historic performance of CT cholangiography can only be considered fair when compared to ERCP or EUS, though more recent studies comparing CT to MR suggest it is a potentially useful test for CBDS.

### 7.3 Magnetic resonance imaging

Studies examining MR in comparison to ERCP have generally used ERCP as the reference standard. Such study designs do not allow the hypothesis that MR is superior to ERCP to be tested but have allowed researchers to test the level of concordance between the two modalities. In the majority of studies published to date MR has a sensitivity and specificity of 90% or more in relation to ERCP<sup>32–41–46</sup> though a smaller number of studies suggest the sensitivity of MR in relation to ERCP is lower than this.<sup>47–48</sup> In one study, where positive tests were then confirmed by surgical exploration, ERCP was demonstrated to have a sensitivity and specificity of 100% and MR a sensitivity of 91% with a specificity of 100%.<sup>49</sup> This study also demonstrated that the sensitivity of MR fell from 100% for stones over 1 cm in diameter to 71% for stones less than 5 mm in diameter. Subsequent studies, using ERCP as the reference standard, have confirmed that the ability of MR to detect CBD stones, whilst generally good,<sup>40–50–51</sup> is influenced by stone diameter.<sup>40–50</sup> In addition to false negative results false positives are also recognised, particularly as a consequence of aerobilia. In a recent review of prospective studies<sup>40–52–55</sup> Verma *et al*<sup>56</sup> demonstrated MR, when compared to ERCP or IOC, had a sensitivity for CBDS of 0.85, and a specificity of 0.93.

It is likely therefore that MR cholangiography is almost as good as ERCP in the diagnosis of CBDS, though the ability of MR to consistently detect stones of a few millimetres in diameter has yet to be demonstrated. It should also be recognised that the presence of intracranial metallic clips, claustrophobia or morbid obesity might preclude MRCP. Nonetheless, given its increasing availability and accuracy, the European Association of Laparoscopic Surgeons now consider MR cholangiography to be the standard diagnostic test for patients with an intermediate probability of CBDS.<sup>5</sup>

### 7.4 Endoscopic ultrasound scanning

A dedicated echo-endoscope or US catheter probe can, when positioned in the duodenal bulb, give good images of the bile

duct. CBDS appear as hyper-echoic foci when imaged with such a system. Several studies have compared EUS to ERCP as a diagnostic tool. Studies are generally small and involve patients with moderate to high risk of CBDS. Nonetheless, several use a gold standard of sphincterotomy and endoscopic bile duct exploration for positive cases, which allows the performance of ERCP and EUS to be compared.<sup>34–39–57–62</sup>

Taken collectively the sensitivity of ERCP for CBDS in these studies ranges from 79 to 100% compared to 84–100% for EUS, and the specificity from 87 to 100% for ERCP compared to 96–100% for EUS. Neither test is consistently demonstrated to be superior when results of individual studies are examined.

In conclusion then, EUS appears comparable to ERCP as a diagnostic test for CBDS, and performs better than either USS or CT.<sup>38–39</sup> Unlike ERCP, EUS does not require instrumentation of the sphincter of Oddi and does not subject patients to the associated risk of pancreatitis. With regards to MR, systematic review<sup>56</sup> of prospective studies has failed to show a statistically significant difference in performance when the two modalities are compared, though for small CBD stones EUS may still be more sensitive.<sup>53–63</sup> However, it should be noted that, unlike MR, EUS has yet to become widely available. In addition, it requires the patient to undergo endoscopy, does not provide images of the intra-hepatic ducts and may be difficult to perform on patients with altered gastric or duodenal anatomy.

## 8.0 ENDOSCOPIC TREATMENT OF CBDS

Endoscopic retrograde cholangiopancreatography (ERCP) can be used to provide definitive or temporary treatment of CBDS. The following section discusses selection and preparation of patients for ERCP and compares available endoscopic techniques. The role of ERCP as an adjunct to surgery is discussed in section 11.0

### 8.1 Required facilities and personnel

*ERCP training programmes should follow the recommendations contained within current Joint Advisory Group (JAG) Guidelines. (Evidence grade IV. Recommendation grade C.)*

*It is important that once formal training is completed endoscopists perform an adequate number of biliary sphincterotomies (BS) per year to maintain their performance. As a guide, 40–50 BS per endoscopist per annum is suggested. (Evidence grade III. Recommendation grade B.)*

*When performing endoscopic stone extraction (ESE) the endoscopist should have the support of a technician or radiologist who can assist in fluoroscopic screening, a nurse to monitor patient safety and an additional endoscopy assistant/nurse to manage guide wires etc. (Evidence grade IV. Recommendation grade C.)*

North American data suggest at least 200 procedures are required before the average trainee can achieve selective cannulation rates in excess of 80%.<sup>64</sup> For individuals trained in the UK the true figure is probably higher.<sup>65</sup> It is therefore recommended that to both maintain and improve the quality of ERCP services training programmes adhere to current Joint Advisory Group Guidelines.<sup>66</sup> Reports also suggest that complication rates for biliary sphincterotomy (BS) correlate with annual workload.<sup>67–69</sup> As biliary sphincterotomy usually precedes endoscopic stone extraction (ESE) it is important that once formal training is completed endoscopists perform an adequate number of procedures per year to maintain their performance. As a guide a minimum of 40–50 BS per endoscopist per annum is suggested.<sup>67–68</sup>

**Table 2** Recognised complications of endoscopic retrograde cholangiopancreatography (ERCP)

Complication	Incidence (%) reported by large-scale prospective studies*	References	Incidence (%) reported by BSG audit of ERCP <sup>65</sup> †
Post-ERCP pancreatitis	1.3 to 6.7	67, 69, 70, 72, 74	1.5
Gastrointestinal haemorrhage	0.7 to 2	67, 69, 70, 72	0.9 (1.5% of BS patients)
Cholangitis	0.5 to 5	67, 69, 70, 72	1.1
Duodenal perforation	0.3 to 1	67, 69, 70, 72	0.4
Miscellaneous, including cardio-respiratory	0.5 to 2.3	67, 69, 70, 72	1.4

\*Figures derived from consecutive biliary sphincterotomy (BS) patients<sup>67</sup> and unselected series of diagnostic and therapeutic ERCP.<sup>69 70 74</sup>

†Figures derived from all recorded procedures during the study period.  
BSG, British Society of Gastroenterology.

For successful ESE skilled nursing and radiography staff are essential. At a minimum the endoscopist requires the support of a technician or radiologist who can assist in fluoroscopic screening, a nurse to monitor patient safety and an additional endoscopy assistant/nurse to manage guide wires etc.

## 8.2 Selection of patients for ERCP

*Discussion of cases in a multidisciplinary setting is to be encouraged. (Evidence grade IV. Recommendation grade C.)*

*When scheduling ERCP the endoscopist needs to be aware of the patient-related factors that increase the risk of an ERCP or BS related complication. (Evidence grade III. Recommendation grade B.)*

Though a generally safe and effective procedure adverse events resulting from ERCP are well recognised. These are summarised in table 2.

The endoscopist should therefore be aware of the patient related factors that increase the risk of an ERCP or BS related complication. These include age less than 60–70 years,<sup>67–73</sup> female sex<sup>73 74</sup> and a low probability of structural disease (as suggested by normal bilirubin, non-dilated ducts or suspected sphincter of Oddi dysfunction).<sup>67 69 71 73 74</sup> Co-morbid conditions that may increase risk include cirrhosis,<sup>67</sup> previous post-ERCP pancreatitis (PEP)<sup>67 73</sup> and, when sphincterotomy is undertaken, coagulopathy.<sup>67 68 73 75</sup>

The risks for any one patient need also to be balanced against the likelihood of being able to offer treatment at the time of ERCP. Unnecessary biliary instrumentation should be avoided and it is recommended that ERCP be reserved for patients in whom the clinician is confident an intervention will be required. Appropriate investigation as described below is important. Discussion of cases in a multidisciplinary setting is to be encouraged.

## 8.3 Investigation of the CBD prior to ERCP

*Where patients with suspected CBDS have not been previously investigated initial assessment should be based on clinical features, LFTs and USS findings. (Evidence grade III. Recommendation grade B.)*

*It is recommended that ERCP be reserved for patients in whom the clinician is confident an intervention will be required. In patients with suspected CBDS it is not recommended for use solely as a diagnostic test. (Evidence grade IIb. Recommendation grade B.)*

Where patients have not been previously investigated initial assessment should be based on clinical features, LFTs and USS findings. Where initial assessment suggests a high probability of CBDS (see section 7.0), then it is reasonable to proceed directly to ERCP if this is considered the treatment of choice. This strategy is also likely to be cost effective.<sup>76</sup>

Where initial assessment suggests a low or uncertain index of suspicion for CBDS then it is recommended that patients undergo magnetic resonance imaging (MR) or endoscopic ultrasound (EUS), with ERCP reserved for those with abnormal or equivocal results. It should be noted that, in the absence of LFT abnormalities, a dilated CBD on USS does not reliably predict CBDS.<sup>28</sup> In such cases it is more appropriate to perform an EUS or MR than proceed directly to ERCP.

## 8.4 Preparation of patients for ERCP

### 8.4.1 Consent

*It is recommended that clinicians follow the BSG Guidelines on consent and use Department of Health forms (or their equivalent) to obtain written confirmation of consent. (Evidence grade IV. Recommendation grade C.)*

Patients should receive verbal and preferably written information regarding ERCP prior to the procedure. The risks of ERCP and associated intended therapy should be explained. Patients should be aware of the risk of pancreatitis and a smaller risk of perforation or bleeding. Patients with obstructive jaundice and/or CBDS should also be made aware of the risk of cholangitis, which is an under-recognised cause of morbidity and mortality in UK practice.<sup>65 77</sup> Whilst overall risk of pancreatitis is often quoted as approximately 5%, the likelihood of pancreatitis varies widely between different patient groups<sup>74</sup> and as far as possible any discussion of risk should be individualised. Therapeutic alternatives should be discussed where appropriate. It is recommended that clinicians adhere to local policy in obtaining written confirmation of consent, and use the Department of Health Standard Consent Forms (or their equivalent).

### 8.4.2 Clotting and anticoagulation therapy

*Patients undergoing BS for ductal stones should have a full blood count (FBC) and prothrombin time or international normalised ratio (PT/INR) performed no more than 72 h prior to the procedure. Where patients have deranged clotting subsequent management should conform to locally agreed guidelines. (Evidence grade III. Recommendation grade B.)*

*In patients established on anticoagulation therapy a local policy should be agreed for managing endoscopic stone extraction. For those at low risk of thromboembolism anticoagulants should be discontinued prior to ERCP if biliary sphincterotomy is planned. (Evidence grade III. Recommendation grade B.)*

*Biliary sphincterotomy can be safely performed on patients taking aspirin or non-steroidal anti-inflammatory drugs. Administration of*

## Guidelines

low dose heparin should not be considered a contraindication to BS. (Evidence grade III. Recommendation grade B.)

Where possible, newer anti-platelet agents such as clopidogrel (Plavix) should be stopped 7–10 days prior to BS (Evidence grade IV. Recommendation grade C.)

Abnormal clotting is a feature of both biliary obstruction and parenchymal liver disease. In prospective studies coagulopathy (variously defined as a platelet count less than 50 000 to 80 000/mm<sup>3</sup>, prothrombin time >2 s prolonged, or prothrombin test <50%), and conditions that predispose to it, such as ongoing haemodialysis, have been identified as risk factors for post-sphincterotomy haemorrhage.<sup>67 68 73 75</sup> However, some retrospective studies have shown the incidence of post-sphincterotomy bleeding in patients with normal clotting parameters, including the patients with abnormal parameters which have been well corrected, is higher than in patients with abnormal haemostatic screens.<sup>68 78</sup> As with percutaneous liver biopsy<sup>79</sup> the point at which abnormalities in coagulation become an absolute contra-indication to the procedure, and the affect of correcting abnormal laboratory parameters on outcome is difficult to determine from the available evidence.

Nonetheless, it is suggested that patients undergoing BS as part of treatment for CBDS have a full blood count and prothrombin time (or INR) performed within 72 h of the procedure, and that where patients have deranged clotting subsequent management should conform to locally agreed guidelines.

In patients receiving anti-coagulant therapy for a co-morbid condition an assessment of thrombo-embolic risk should be made. Where risk of thrombo-embolism is low (such as in patients with atrial fibrillation) anticoagulants should be discontinued several days before biliary sphincterotomy. Whilst one study has suggested that resumption of anticoagulation within 3 days of ERCP<sup>67</sup> is a risk factor for post-sphincterotomy haemorrhage, data in this area are lacking, with many endoscopists routinely reintroducing anticoagulation earlier than this. In patients at higher risk of thrombo-embolic events the American Society for Gastrointestinal Endoscopy has indicated oral anticoagulation should be discontinued prior to biliary sphincterotomy and introduction of unfractionated IV heparin considered when INR becomes sub-therapeutic.<sup>80</sup> Low molecular weight heparin has been discussed as an alternative to unfractionated heparin but it is important to be aware that data on its efficacy in this setting are lacking.<sup>81</sup> In the absence of robust studies addressing this issue it is recommended that units develop their own locally agreed policy for managing stone extraction in patients on anticoagulation therapy.

ESE with or without biliary sphincterotomy can be safely performed on patients taking aspirin or non-steroidal anti-inflammatory drugs.<sup>67 75 78</sup>

Administration of low dose heparin has been reported to increase the risk of haemorrhage but also to lower post-ERCP pancreatitis (PEP) rates.<sup>68 78</sup> On the basis of the most recent evidence heparin is unlikely to protect against pancreatitis.<sup>82</sup> However, its use in low dose is not considered a contra-indication to ESE. Data on newer anti-platelet therapies are unavailable, but at present it is recommended that, wherever possible, drugs such as clopidogrel (Plavix) are discontinued 7–10 days prior to ESE.<sup>81</sup>

### 8.4.3 Antibiotic administration

Prophylactic antibiotics should be given to patients with biliary obstruction or previous features of biliary sepsis. (Evidence grade Ib. Recommendation grade A.) Patients should be managed in accordance

with the BSG Guidelines on antibiotic prophylaxis during endoscopy (Evidence grade IV. Recommendation grade C.)

Routine administration of antibiotics to all patients undergoing ERCP is considered unnecessary, though this remains a debated issue.<sup>83</sup> However, prophylactic antibiotics do reduce the risk of clinically significant sepsis in patients with biliary obstruction, or previous features of biliary sepsis.<sup>84–86</sup> Antibiotics have also been recommended for patients with moderate to high-risk cardiac lesions, though unequivocal evidence of benefit is lacking. Where antibiotics are used oral ciprofloxacin or parenteral gentamicin, quinolone, cephalosporin or ureidopenicillin are recommended, and the British Society of Gastroenterology Guidelines on antibiotic prophylaxis during endoscopy should be followed.<sup>4</sup>

### 8.4.4 Pancreatitis prophylaxis

No drug is currently recommended for the routine prevention of pancreatitis among patients undergoing endoscopic stone extraction. (Evidence grade Ia. Recommendation grade A.)

More common than post-ERCP sepsis is post-ERCP pancreatitis (PEP). A wide range of drugs has been given to patients in an attempt to reduce the incidence of PEP.<sup>87–96</sup> Results have generally been disappointing. Trans-dermal or sub-lingual glycerol trinitrate (GTN) given prior to ERCP may reduce the incidence of PEP, but further study is required.<sup>92 93</sup> In addition a recent multi-centre trial<sup>97</sup> has generated renewed interest in using octreotide to prevent pancreatitis, but results are yet to be duplicated. Gabexate and somatostatin have also been suggested to reduce the incidence of PEP when administered as prolonged infusions peri-procedure.<sup>88</sup> However, shorter term infusions of either drug, even in patients at high risk of PEP, are ineffective<sup>98 99</sup> and a recently updated meta-analysis suggests no benefit with either agent.<sup>100</sup>

At present therefore no specific agent is recommended for routine PEP prophylaxis in patients undergoing endoscopic stone extraction.

### 8.4.5 Sedation, intravenous access and monitoring

Patients should be sedated and monitored in accordance with BSG Guidelines. (Evidence grade IV. Recommendation grade C.)

It is suggested that patients are sedated and monitored in accordance with BSG Guidelines.<sup>101</sup> During ERCP falls in blood pressure can occur, and a large bore venous cannula is recommended. Patients with obstructive jaundice, who are fasted beforehand and may be drowsy for some hours afterwards, are at risk of dehydration and renal impairment, and should receive intravenous fluids. Their urine output should be monitored.

In many countries the use of propofol for sedation for ERCP is common practice. In addition, evidence from the United States suggests that nurses can be trained to safely deliver and monitor propofol-induced sedation.<sup>102</sup> However, pending further recommendations from professional bodies within the UK propofol should not be used unless specialist anaesthetic support is available.

## 8.5 Biliary sphincterotomy and stone extraction

In patients with risk factors for post-ERCP pancreatitis, but not BS-induced haemorrhage, sphincterotomy initiated using pure cut may be preferable. (Evidence grade Ib. Recommendation grade A.)

Biliary sphincterotomy followed by stone extraction using a basket or balloon catheter represents standard endoscopic therapy for CBDS. Successful endoscopic treatment is possible



in the majority of patients and in skilled hands duct clearance can be achieved in over 90%<sup>103–108</sup> though in up to 25% of patients this requires two or more ERCPs.<sup>103 109 110</sup>

In general, complications are those of ERCP, and in particular include post-sphincterotomy haemorrhage. Reported complication rates vary according to case mix, definitions used, and study design. Some form of adverse event following BS may occur in up to 10% of cases; though the incidence of severe complications is probably nearer 1–2% and rates of post-ERCP pancreatitis following stone extraction are low when compared to other indications for BS, such as sphincter of Oddi dysfunction. Death as a consequence of BS has been reported in 0.4% of cases.<sup>67</sup> Late complications of BS include recurrent stone formation and cholangitis.<sup>111–113</sup> For an individual patient these risks need to be weighed against those of alternative treatment options. Although the very long-term sequelae of BS have not been described the available evidence suggests BS can be safely used for extracting stones in young patients.

Choice of current may be important in patients undergoing BS and stone extraction. Blended current is pulsed and has a wide area of thermal effect. Pure (cutting) current is continuous and has a limited area of thermal effect. Traditionally, a blended current has been recommended to endoscopists performing BS. When compared with use of pure cut alone this reduces the incidence of visible bleeding.<sup>114–118</sup> However, in several studies total complication rate (predominantly accounted for by pancreatitis) appears significantly increased.<sup>114–116</sup> This is probably due to increased ampullary oedema leading to pancreatic duct obstruction, though not all studies support this hypothesis.<sup>119</sup> Similar differences have also been observed when monopolar current is compared to bipolar current.<sup>118</sup> Switching from cutting to blended current towards the end of a sphincterotomy may combine the advantages of both settings but reports are conflicting.<sup>115 116</sup> The newer technology of “endocut” automatically modulates delivery of current to the tissues, and shows promise as a way of reducing the incidence of bleeding.<sup>120</sup> However, to date, “endocut” has not been demonstrated to be superior to blended current with regards to overall complication rate. It is therefore recommended that for a given patient the clinician balances risk of pancreatitis against those of bleeding. In patients with risk factors for pancreatitis but not BS-induced haemorrhage a sphincterotomy initiated using pure cut may be preferable.

### 8.6 Balloon dilation as an alternative to biliary sphincterotomy

*Balloon dilation of the papilla (ED) can be an alternative to biliary sphincterotomy, in some patients. However, the risk of (severe) post-ERCP pancreatitis is increased in comparison to BS and in the majority of patients undergoing stone extraction ED should be avoided (Evidence grade Ia. Recommendation grade A.)*

Endoscopic balloon dilation of the papilla (ED) has been advocated as an alternative to endoscopic sphincterotomy in patients undergoing stone extraction. It is attractive for three reasons. First, bleeding appears to be a risk that is peculiar to sphincterotomy and one that may be minimised by using balloon dilation.<sup>121–123</sup> Second, it disrupts sphincter of Oddi function less than sphincterotomy.<sup>124 125</sup> and may therefore reduce the risk of late complications, such as cholecystitis in patients with gallstones.<sup>121 126</sup> Finally, the procedure can be technically easier to perform in patients with altered anatomy such as after Bilioth II surgery.<sup>127</sup>

However, several studies have suggested that in comparison to biliary sphincterotomy, ED may be a greater risk factor for

PEP,<sup>74 128–130</sup> a finding that has been recently confirmed by meta-analysis.<sup>122 131</sup> Of particular concern is the preponderance of severe complications following ED in two of the published reports.<sup>128 129</sup> In both these studies recruitment was terminated early as a result.

In conclusion, balloon dilation of the papilla can be an alternative to biliary sphincterotomy, and has been advocated in patients with coagulopathy or cirrhosis, where risk of post-sphincterotomy haemorrhage is increased. However, risk of (severe) PEP is increased in comparison to BS and in the majority of patients undergoing stone extraction ED should be avoided.

### 8.7 Biliary stenting for CBDS

*It is important that endoscopists ensure adequate biliary drainage is achieved in patients with CBDS that have not been extracted. The short-term use of a biliary stent followed by further endoscopy or surgery is advocated. (Evidence grade III. Recommendation grade B.) In contrast the use of a biliary stent as sole treatment for CBDS should be restricted to a selected group of patients with limited life expectancy and/or prohibitive surgical risk. (Evidence grade Ib. Recommendation grade A.)*

Bacterial contamination of bile is a common finding in patients with CBDS and incomplete duct clearance may therefore place patients at risk of cholangitis.<sup>132</sup> It is therefore important that endoscopists ensure adequate biliary drainage is achieved in patients with CBDS that cannot be retrieved. The short-term use of an endoscopic biliary stent followed by further ERCP or surgery has been shown to be a safe management option in this setting.<sup>133</sup>

For patients over 70 years of age or with debilitating disease (as defined by the American Society of Anesthesiology) biliary stenting has also been examined as an alternative to ESE.<sup>133 134</sup> The technique compares favourably with ESE in terms of immediate success and complication rate. However, at least a quarter of patients experience recurrent cholangitis during follow-up. Long-term results are probably more favourable in those patients without a gallbladder.<sup>134</sup>

Therefore whilst biliary stenting as a “bridge” to further therapy is recommended, its use as definitive treatment for CBDS should be restricted to patients who have limited life expectancy or are judged by a surgeon to be at prohibitive surgical risk.

### 8.8 Role of pre-cut papillotomy

*Multi-centre studies indicate pre-cut is a risk factor for complication. Therefore the procedure should be considered an advanced technique, to be employed only by those with appropriate training and experience. Its use should be restricted to those patients for whom subsequent endoscopic treatment is essential (Evidence grade III. Recommendation grade B.)*

Deep biliary cannulation can be achieved by insertion of a bare wire or “needle knife” into the papillary orifice or by using a sphincterotome with a cutting wire that extends to the tip. When difficulties in biliary access are encountered “pre-cut” is used routinely by some endoscopists, but not at all by others. Reported complication rates following pre-cut range from 5 to 30%.<sup>67 70 74 135</sup> Even when difficulty of cannulation is controlled for pre-cut remains a risk factor for PEP in most multi-centre studies,<sup>67 69 70 136</sup> and has been shown to be a risk factor for overall complication in the UK.<sup>73</sup> However, data from advanced centres supports the supposition that pre-cut is no riskier than standard biliary sphincterotomy.<sup>137–141</sup> Although the type

## Guidelines

of pre-cut performed may influence outcome<sup>142</sup> operator skill and experience would appear to be the most important determinant in explaining this variability. This underlines the need for selective, well-organised training in advanced endoscopy techniques if risks of ESE are to be minimised.

### 8.9 Role of prophylactic pancreatic stenting

*Patients at high risk of post-ERCP pancreatitis (eg, because of prolonged cannulation and/or pre-cut) may benefit from short-term pancreatic stent placement. (Evidence grade Ib. Recommendation grade A.)*

Post-ERCP pancreatitis may well arise as a result of impaired pancreatic drainage. Mechanical prophylaxis with a temporary pancreatic stent is of clear benefit in patients with suspected sphincter of Oddi dysfunction (SOD)<sup>143–144</sup> and may also have a role in patients undergoing endoscopic stone extraction. In particular it is recognised that difficult cannulation and pre-cut papillotomy are potentially valid indications.<sup>144–146</sup> Pancreatic stenting can cause perforation and ductal injury and where a prophylactic stent is used most authorities recommend early removal if the stent fails to migrate spontaneously.<sup>147–148</sup> This argues for the highest risk patients being referred to centres with appropriate experience in their management.

### 9.0 SURGICAL TREATMENT OF CBDS

Surgical treatment of CBDS occurs in the setting of concurrent laparoscopic cholecystectomy. This offers the opportunity to definitively treat gallstone related disease in a single stage procedure. However, as with ERCP, operator, patient and procedure-related factors all influence outcome. Surgical duct exploration as an alternative to ERCP is discussed in section 10.0

#### 9.1 Required facilities and personnel

Though in a minority of patients there remains an important requirement for open surgical treatment, laparoscopic cholecystectomy (LC) has superseded open cholecystectomy as the operation of choice for symptomatic gallstones.

Whilst over 80% of gallbladders are now removed laparoscopically the more recently developed technique of laparoscopic common bile duct exploration (LCBDE) has yet to become as widely available. LCBDE requires a flexible choledochoscope together with light source and camera, and disposable instrumentation similar to that required for ERCP (eg, baskets, balloons, stents). In contrast, open bile duct exploration can be carried out without a choledochoscope, significantly reducing capital outlay costs. However, blind instrumentation of the bile duct is not encouraged given that it may increase the risk of post-choledochotomy stricture formation.

There is significant learning curve for laparoscopic bile duct surgery both amongst surgeons and nursing staff.<sup>149</sup> Given that the current provision of non-transplant hepatobiliary services in the UK is almost certainly insufficient, manpower issues will need to be addressed to ensure the country has adequate numbers of appropriately trained surgeons in the future.<sup>150</sup>

#### 9.2 Selection of patients for surgical bile duct exploration

*An assessment of operative risk needs to be made prior to scheduling intervention. Where this risk is deemed prohibitive endoscopic therapy should be considered as an alternative. (Evidence grade III. Recommendation grade B.)*

Laparoscopic surgical exploration of the bile duct allows for single stage treatment of gallstone disease with removal of the gallbladder as part of the same procedure. This may reduce

overall hospital stay when compared to the two-stage approach of ERCP and laparoscopic cholecystectomy.<sup>103–151</sup> The additional complications of surgical duct exploration are predominantly related to choledochotomy (bile duct leakage) and T-tube use (bile leakage, tube displacement). Pancreatitis is rare unless there has been ante-grade instrumentation of the papilla.<sup>152</sup>

T-tubes were traditionally inserted in open bile duct exploration because of the risk of bile leakage from the choledochotomy, which arose as a result of uncertainty regarding duct clearance (in the absence of choledochoscopy), or because of the presence of oedema and inflammation as a result of blind instrumentation of the duct. LCBDE with optical magnification, direct visualisation and more delicate instrumentation allows reduced trauma to the bile duct and has resulted in an increasing tendency to close the duct primarily. This avoids the morbidity associated with T-tubes, and necessity for T-tube cholangiograms, though as yet there is no conclusive data favouring one technique over the other.<sup>153</sup>

Systematic review of studies reporting the outcome of LCBDE reveals morbidity rates of between 2 and 17% and mortality rates of 1–5%.<sup>152</sup> This is comparable to ERCP, with a recent Cochrane review<sup>154</sup> of randomised control studies concluding that there was no clear difference in primary success rates, morbidity or mortality between the two approaches. However, it should be noted that populations in such studies have by definition been selected as fit for surgery. Therefore drawing conclusions regarding risks of LCBDE compared to alternative treatment in elderly and frail patients is difficult.

What is known is that in patients over 70–80 years of age mortality rates associated with *open* duct exploration are around 4–10%, and may be as high as 20% where elderly patients are subjected to urgent procedures.<sup>155–158</sup> These findings contrast with ERCP, where advanced age and co-morbidity do not appear to have a significant impact on overall complication rates.<sup>67–70–159–160</sup>

Therefore, as with any surgical intervention, an assessment of operative risk needs to be made. Where this risk is deemed prohibitive endoscopic therapy should be considered as an alternative.

#### 9.3 Investigation of the CBD prior to surgical exploration

*Intraoperative cholangiography (IOC) or laparoscopic ultrasound (LUS) can be used to detect CBDS in patients who are suitable for surgical exploration or postoperative ERCP. Though not considered mandatory for all such patients, IOC is recommended for those patients who have an intermediate to high pre-test probability of CBDS and who have not had the diagnosis confirmed preoperatively by other means. (Evidence grade IIb. Recommendation grade B.)*

The standard way of imaging the CBD intraoperatively is by trans-cystic cannulation of the CBD with a fine catheter and direct injection of non-ionic contrast into the bile duct. Plain x ray plates have largely been superseded by image intensification, which reduces positioning failure, allows real-time imaging of the ducts (aiding the assessment of stones), and reduces procedural time and radiation dosage. As a test for ductal stones laparoscopic IOC has a quoted sensitivity of 80–92.8% and specificity of 76.2–97%.<sup>161–162</sup> More recently intraoperative laparoscopic ultrasound (LUS) has been found to be as sensitive as, and faster than, IOC. It also avoids the hazards of radiation to staff and patients.<sup>163–164</sup>

Whether all patients undergoing cholecystectomy need to undergo IOC has been extensively debated in the literature. Routine IOC has been advocated on two grounds. First, it accurately defines anatomy and may therefore allow surgeons

to minimise the risk of ductal injury, or at a least take prompt remedial action when such injury occurs.<sup>165</sup> Second, it may detect asymptomatic ductal stones.<sup>166–168</sup>

Conversely, a policy of selective IOC has been argued to minimise unnecessary biliary instrumentation. Moreover, recent studies of MRCP and EUS have demonstrated preoperative findings that are concordant with IOC results, suggesting that such tests can also be effective in screening for CBDS.<sup>169–170</sup> However, the cost of performing such preoperative imaging on all patients would be high, and the availability of specialised imaging techniques is very variable throughout the country. The use of preoperative results to select patients for further imaging is therefore considered a permissible strategy, although it is recognised that some clinicians may opt to perform an IOC in all patients undergoing cholecystectomy. As already discussed in section 7.1 patients with normal preoperative LFTs and a normal diameter CHD/CBD on ultrasound have a very low chance of a CBD stone. Further imaging is not considered mandatory in this group. However, patients who are clinically jaundiced should undergo preoperative ERCP or, alternatively, MRCP (to exclude malignant disease) followed by single stage LCBDE/OCBDE. Which strategy should be adopted will largely depend on local availability of surgical and endoscopic skills. In centres not performing LCBDE, non-jaundiced patients with a dilated CBD or abnormal LFTs should undergo a pre-cholecystectomy MRCP or EUS to identify CBD stones, which are present in around 10%. Patients with CBD stones can then be offered preoperative ERCP followed by LC or single stage OCBDE. An alternative to preoperative imaging in this group of patients is to perform IOC with conversion to OCBDE or postoperative ERCP if CBD stones are found. Centres performing high volumes of LCBDE will require very few patients with a low to intermediate probability of CBDS to be imaged preoperatively, instead proceeding directly to laparoscopy with IOC or LUS to identify those patients who require laparoscopic exploration to remove CBDS.

#### 9.4 Technical considerations of CBDS

*It is recommended that in patients undergoing laparoscopic cholecystectomy trans-cystic or trans-ductal exploration of the CBD is an appropriate technique for CBDS removal. (Evidence grade Ib. Recommendation grade A.)*

Laparoscopic cholecystectomy is the treatment of choice for symptomatic gallstones and is associated with short hospital stays and minimal morbidity.<sup>171–172</sup> The uptake of LCBDE has, however, been less rapid as compared to the uptake of LC. In part this is because the technique requires significant capital outlay and is technically difficult, requiring endoscopic skills and laparoscopic suturing skills. It is estimated that only 20% of bile duct explorations are performed laparoscopically at the present time, with findings from a 2005 survey of English hospitals suggesting fewer than one in three units treat patients using this technique.<sup>173</sup> As discussed in section 8.2 use of T-tubes, and increasing age appear to increase risk of complication for LCBDE.<sup>174–175</sup> Nonetheless the procedure compares favourably with an open approach and preserves the benefits associated with LC.<sup>151–176–177</sup>

Laparoscopic exploration may involve a trans-cystic or trans-ductal approach. The trans-cystic approach is more limited allowing retrieval of only small stones and poor access to the CHD. It can be performed under image intensifier control or with the use of an ultra-thin choledochoscope (3 mm). The majority of surgeons use the trans-ductal approach directly

through the CBD. Regardless of exact technique LCBDE has been demonstrated to be an effective treatment for CBDS, with reported rates of duct clearance comparable to those obtained with pre- or postoperative ERCP.<sup>103–151–154–176–179</sup> Long-term results also appear favourable.<sup>180–181</sup> It is therefore recommended that, in patients undergoing laparoscopic cholecystectomy, trans-cystic or trans-ductal exploration of the CBD is an appropriate technique for CBDS removal.

#### 10.0 MANAGEMENT OF "DIFFICULT" STONE DISEASE

*When minimally invasive techniques fail to achieve duct clearance (open) surgical exploration remains an important treatment option. (Evidence grade III. Recommendation grade B.)*

Extraction of ductal stones via an endoscopic biliary sphincterotomy or laparoscopic route may be difficult or inappropriate for a variety of reasons. Most obviously size, shape and number of stones may make extraction difficult, but in addition patients may have stones that lie proximal to a biliary stricture. In addition to open surgical exploration of the duct, which retains an important role in the management of very difficult stone disease, a variety of other techniques may be employed, and these are described below.

##### 10.1 Mechanical lithotripsy

*It is recommended that all endoscopists performing ERCP should be able to supplement standard stone extraction techniques with mechanical lithotripsy when required. (Evidence grade III. Recommendation grade B.)*

Mechanical lithotripsy is an endoscopic technique that involves trapping stones within a reinforced basket, after which a spiral sheath is cranked down onto the ensnared stone to crush and fragment it. Mechanical lithotripsy is successful in over 80% of cases where standard balloon or basket extraction cannot be performed, though duct clearance is less likely to be achieved where a stone is impacted in the bile duct.<sup>182–184</sup> Stone size may also be important in predicting success though reports are conflicting.<sup>183–185</sup>

Because it requires the same basic skills as "standard" endoscopic stone extraction and can be performed as part of the same procedure it is an attractive option for large CBD stones. It is recommended that all endoscopists performing ERCP should be able to supplement biliary sphincterotomy and standard stone extraction techniques with mechanical lithotripsy when required. Emergency "over the basket" lithotripsy is still occasionally required when a standard basket engages a large stone and becomes impacted, and it is therefore essential that units have the equipment available to perform this.

##### 10.2 Extra-corporeal shock wave lithotripsy

*Where available extra-corporeal shock wave lithotripsy (ESWL) can be considered for patients with difficult disease who are not fit enough/unwilling to undergo open surgery. Antibiotic prophylaxis during ESWL should be administered. (Evidence grade III. Recommendation grade B.)*

Extra-corporeal shock wave lithotripsy (ESWL) uses electro-hydraulic or electro-magnetic energy to fragment CBDS. Insertion of a naso-biliary drain is performed to allow fluoroscopic identification and targeting of CBDS. Direct visualisation and/or manipulation of the stone are unnecessary. Patients are usually sedated for treatment, which typically takes up to 90 min to perform. The energy setting and number of discharges delivered varies according to the device used and patient tolerance. Cholangiography the following day identifies

## Guidelines

those patients in whom treatment has been successful. Further courses of ESWL can be administered if necessary and residual fragments may be removed by ERCP. Kidney lithotripters can be used and results using a variety of devices and protocols have been reported, with typical rates of duct clearance ranging between 60 and 90%.<sup>186–191</sup>

The main adverse effects specific to ESWL are pain, local haematoma formation, and haematuria, which usually resolve without specific treatment. More seriously, cholangitis is a recognised sequelae of treatment and may occur more frequently in patients who do not receive antibiotic prophylaxis.<sup>191 192</sup>

It is recognised that very few units have access to ESWL and that it is rarely indicated for CBDS. However, where available its use should be considered when routine endoscopic techniques, including mechanical lithotripsy, fail to achieve duct clearance and the patient is unfit or unwilling to undergo surgery. Antibiotic prophylaxis during treatment should be administered.

### 10.3 Intra-corporeal electro-hydraulic and laser lithotripsy

*Electro-hydraulic lithotripsy (EHL) and laser lithotripsy can effect duct clearance where other forms of lithotripsy have failed. (Evidence grade III. Recommendation grade B.)*

These techniques involve delivering energy directly to a large or impacted stone using a per-oral laser fibre or electro-hydraulic lithotripsy (EHL) probe. Continuous irrigation of the CBD is required and whilst stone recognition systems have been developed which allow laser therapy to be performed under fluoroscopic guidance<sup>193 194</sup> treatment generally involves direct visualisation of the stone using a choledochoscope. Compared to the other forms of lithotripsy described the numbers treated to date using these techniques are small. However, in skilled hands rates of duct clearance are high and in randomised control trials have exceeded those achieved with ESWL.<sup>195 196</sup>

Electro-hydraulic lithotripsy is also used in laparoscopic bile duct exploration to deal with large or impacted stones and can improve duct clearance rates to >95%. It is therefore recognised that EHL and laser lithotripsy can effect duct clearance where other forms of lithotripsy have failed.

### 10.4 Percutaneous radiological treatment

*Percutaneous treatment has been described as an alternative or adjunct to other forms of stone extraction. It is recommended that if appropriate facilities and expertise are available then its use should be considered when standard endoscopic and surgical treatment fails or is considered inappropriate. (Evidence grade III. Recommendation grade B.)*

Percutaneous access to the biliary system can be obtained using an established T-tube tract or introducer sheaths via the liver or gallbladder. Where a preceding ERCP has failed and biliary obstruction persists the immediate imperative will be to provide adequate biliary drainage and this may be temporarily achieved by use of an internal stent or internal/external biliary drain. Percutaneous cholangiography can also provide useful diagnostic information at the same time.

However, the interventional radiologist may also push ductal stones into the duodenum or (rarely) retrieve stones percutaneously. The exact technique employed can vary and may involve use of a basket, electro-hydraulic lithotripsy, laser lithotripsy, ante-grade sphincterotomy or balloon dilation.<sup>197–201</sup> The creation and dilation of a trans-hepatic fistula is more invasive than endoscopy and can be time consuming. Nonetheless high success rates are reported<sup>197 200 202</sup> and the technique may be attractive in situations where a retrograde approach is impossible (eg, CBDS proximal to a tight stricture).

In addition where endoscopic access to the papilla is difficult, eg, in patients who have a long afferent jejunal loop following abdominal surgery, the radiologist may assist the endoscopist in performing a retrograde BS by feeding a guide-wire through the papilla and into the duodenum. Such combined procedures are more likely to result in a complication when compared to BS achieved by ERCP alone, with one multivariate analysis reporting an adjusted odds ratio of 3.4 (confidence interval, 1.04 to 11.13).<sup>67</sup>

Given that percutaneous treatment involves considerable discomfort to the patient it should not be considered a first-line therapy for CBDS. However, it is recommended that when other methods of stone extraction fail or are impossible percutaneous treatment can be considered as an alternative or adjunct to ERCP and surgery. In the absence of comparative trials the choice of percutaneous technique should be decided on the basis of local expertise.

### 10.5 Dissolution therapy

*Contact dissolution therapy is not recommended as treatment for CBDS. (Evidence grade III. Recommendation grade B.)*

*Where CBD stone size has precluded endoscopic duct clearance oral ursodeoxycholic acid may facilitate subsequent endoscopic retrieval. (Evidence grade IIa. Recommendation grade B.) Following successful duct clearance administration of long-term ursodeoxycholic acid may be considered. (Evidence grade Ib. Recommendation grade B.)*

Chemicals infused into the biliary system via a T-tube or naso-biliary drain can cause complete or partial dissolution of stones. In the latter case stones may then be removed by standard endoscopic techniques. Treatments using mono-octanoin, methyl *tert*-butyl ether (MBTE) and 1% EDTA/bile acid solution have been tried. Diarrhoea is a common side effect of mono-octanoin and MBTE may cause drowsiness, biliary strictures, cardiac arrhythmias, LFT abnormalities and duodenitis.<sup>203</sup> Given the seriousness and frequency of complications, and that results to date suggest no more than 50% of patients benefit from such treatment<sup>204 205</sup> contact dissolution therapy has been abandoned as a treatment modality for CBDS. It is not recommended under any circumstance.

In the UK ursodeoxycholic acid at a dose of 8–12 mg/kg daily is licensed as a treatment for gallstones.<sup>206</sup> Whilst there is no evidence that ursodeoxycholic acid reduces biliary symptoms in patients awaiting cholecystectomy<sup>207</sup> it may have a role in reducing the size of CBD stones which would otherwise be irretrievable endoscopically.<sup>208</sup> To be effective treatment usually needs to be administered for several months.

Ursodeoxycholic acid at a dose of 500 mg/day has been shown to reduce the risk of stones forming in the gallbladder when given to patients undergoing obesity surgery.<sup>209</sup> Whether the drug has a role in the prevention of CBDS formation following duct clearance is less clear. In a randomised control trial<sup>210</sup> of patients who had undergone endoscopic stone removal 1 in 22 ursodeoxycholic acid treated patients developed a CBDS after some 19 months of follow-up, whereas four of 26 patients receiving placebo had developed recurrent stones by approximately 16 months. More evidence is required to advocate the routine prescription of ursodeoxycholic acid following stone extraction, though secondary prevention with the drug may be considered in selected cases.

### 11.0 MANAGEMENT OF CBDS IN SPECIFIC CLINICAL SETTINGS

In discussing the management of probable or definite CBDS it is helpful to consider the following clinical settings. In cases of

“difficult” stone disease any of the treatment options described below may need to be supplemented by the techniques described in section 10.0:

### 11.1 CBDS and no gallbladder

*BS and endoscopic stone extraction (ESE) is recommended as the primary form of treatment for patients with CBDS post-cholecystectomy. (Evidence grade IV. Recommendation grade C.)*

The minimally invasive nature of ERCP has ensured that BS in association with endoscopic stone extraction has become the primary form of treatment for this group of patients. This approach is advocated, though it should be noted there are no trials directly comparing endoscopic stone extraction (ESE) with surgical stone extraction in this setting.

### 11.2 CBDS and *in situ* gallbladder

In this setting the clinician needs to consider both stone extraction and gallbladder removal. A number of potentially valid treatment options have evolved and these are described below. The management of gallstone pancreatitis and acute cholangitis are also considered separately in sections 11.3 and 11.4.

#### 11.2.1 Endoscopic stone extraction without subsequent gallbladder removal

*Cholecystectomy is recommended for all patients with CBDS and symptomatic gallbladder stones, unless there are specific reasons for considering surgery inappropriate (Evidence grade III. Recommendation grade B.)*

In patients with CBDS cholecystectomy may be performed routinely or reserved for those who develop recurrent biliary symptoms following ESE. Randomised control studies comparing these two approaches suggest 15–37% of patients whose gallbladder is left *in situ* will develop symptoms that require cholecystectomy during a follow-up period ranging from an average of 17 months to over 5 years.<sup>211–213</sup> Recurrent symptoms following ESE are most likely to be reported by younger, surgically fit patients with radiologically proven gallstones. Deferred laparoscopic cholecystectomy in this group is associated with higher rates of conversion to open surgery and a greater risk of surgical complication.<sup>212</sup>

In addition, whilst gallbladder cancer is rare it should be noted that a policy of routine cholecystectomy for patients with secondary CBDS, particularly in the elderly, would both prevent and treat early disease.<sup>211</sup>

Therefore in patients with CBDS and gallstones ESE as sole treatment should be avoided unless there are patient related factors that make cholecystectomy inappropriate.

It should be noted that the management of CBDS in patients with empty gallbladders is less clear. Large scale prospective follow-up of such patients in Japan suggests that, following successful ESE, there is a low rate of recurrent bile duct stones, a low risk of cholecystitis and no occurrence of gallbladder cancer.<sup>214</sup> Such a study has yet to be performed in a European population. However, it is likely that, regardless of race, gallstones form an independent risk factor for recurrent symptoms following ESE.<sup>215</sup>

#### 11.2.2 Open cholecystectomy and common bile duct exploration

In the pre-laparoscopic era routine ERCP prior to open surgery was found to be broadly comparable to a single stage approach of open cholecystectomy and bile duct exploration.<sup>216–219</sup> However, for the reasons discussed in section 9.0, laparoscopic

cholecystectomy (LC) has replaced open cholecystectomy as the reference standard for treatment of gallbladder stones. As a first line, open surgical management of common bile duct stones has therefore been largely superseded by the minimally invasive management options described below. Nonetheless, as recommended in section 10.0, OCBDE remains an important technique for managing bile duct stones that are unsuitable for endoscopic treatment or that are unable to be removed at ERCP. Open exploration may be superseded by LCBDE as this technique becomes more widely available, even in the absence of RCTs showing a major benefit.

#### 11.2.3 Laparoscopic cholecystectomy with endoscopic stone extraction (ESE) or laparoscopic common bile duct exploration (LCBDE)

*Patients with CBDS undergoing laparoscopic cholecystectomy may be managed by laparoscopic common bile duct exploration (LCBDE) at the time of surgery, or undergo peri-operative ERCP. There is no evidence of a difference in efficacy, morbidity or mortality when these approaches are compared, though LCBDE is associated with a shorter hospital stay. It is recommended that the two approaches are considered equally valid treatment options, and that training of surgeons in LCBDE is to be encouraged. (Evidence grade Ib. Recommendation grade A.)*

In deciding to perform an ERCP in conjunction with LC the clinician can choose to routinely or selectively endoscope patients before surgery. Alternatively he/she can perform postoperative (or, more rarely, intraoperative) ERCP on patients with a positive intraoperative cholangiogram.

Given that only a minority of patients undergoing LC are likely to have bile duct stones identified, indiscriminate use of preoperative ERCP is not recommended. Selecting patients on the basis of jaundice or abdominal ultrasound/computerised tomography scanning increases the likelihood of identifying bile duct stones at ERCP to around 50%. Using this approach <5% of patients with CBDS are predicted to be missed prior to surgery. However, the highest yield is obtained when patients undergo ERCP on the basis of a positive IOC. Under such circumstances >70% of ERCPs performed will identify CBDS.<sup>104</sup>

On the basis of these observations selective postoperative ERCP is more cost effective than selective preoperative ERCP.<sup>220 221</sup> However, the analyses upon which this conclusion is based did not incorporate the use of newer imaging modalities such as MR and EUS, which can improve the overall likelihood of stones being found to over 90%.<sup>169 222–224</sup> Use of these additional imaging techniques is likely therefore to render the two approaches equivalent, as discussed in section 9.3.

In randomised control trials the outcomes associated with LC plus LCBDE are comparable with those of LC plus selective ESE. This applies regardless of whether ESE is performed preoperatively or postoperatively.<sup>103 151 154 225</sup> A single stage procedure incorporating LCBDE may be associated with shorter hospital stays<sup>103 151</sup> and an argument for a single stage laparoscopic approach has also been made on grounds of cost effectiveness.<sup>220</sup> However, given that LCBDE does not appear superior to a dual stage procedure in terms of efficacy, morbidity or mortality,<sup>154</sup> the most important considerations when deciding on treatment for an individual patient are local availability and expertise.

### 11.3 Acute biliary pancreatitis

*Where appropriate local facilities exist, those patients with (predicted) severe pancreatitis of suspected or proven biliary origin should undergo biliary sphincterotomy +/- endoscopic stone extraction within 72 h of presentation. (Evidence grade Ib. Recommendation grade B.)*

## Guidelines

It is recommended that non-jaundiced patients with mild biliary pancreatitis require supportive treatment only during the acute stage of their illness. (Evidence grade Ib. Recommendation grade A.) Where such patients undergo cholecystectomy this should be performed within 2 weeks of presentation. In this setting routine preoperative ERCP is unnecessary, though MR cholangiography, IOC or laparoscopic ultrasound should be considered. (Evidence grade Ib. Recommendation grade A.)

Common bile duct stones are a recognised cause of acute pancreatitis. A biliary aetiology for pancreatitis may be suggested by liver function test abnormalities; the presence of gallbladder stones, ductal stones or bile duct dilatation on imaging; or co-existent cholangitis. In such cases the timing and selection of patients for ESE is important. The following recommendations are aligned with current UK Guidelines on the management of acute pancreatitis,<sup>3</sup> which are available at the BSG website ([www.bsg.org.uk](http://www.bsg.org.uk)). They do not supplant these guidelines, or any subsequent update of them.

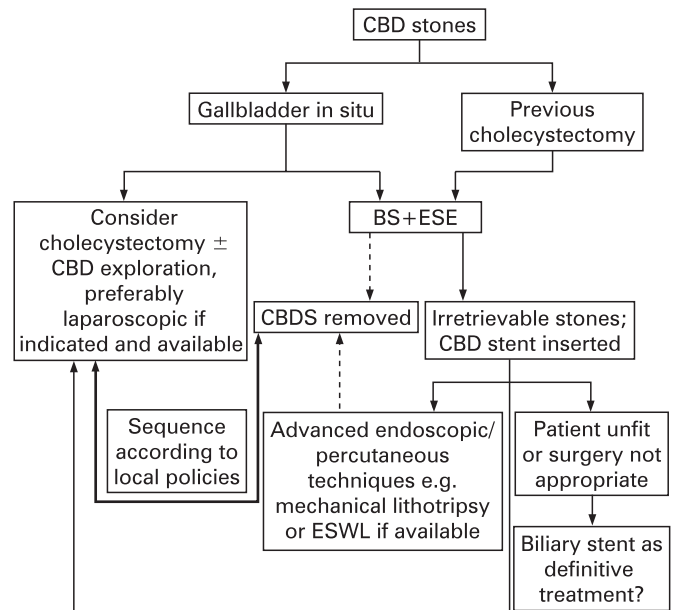
First, where patients have jaundice, cholangitis or (predicted) severe disease of biliary aetiology<sup>226 227</sup> BS plus ESE within 72 h of presentation is recommended. When compared to delayed ESE this approach has been shown to reduce morbidity and may also reduce mortality in the subgroup of patients with severe pancreatitis and biliary obstruction.<sup>228 229</sup>

In patients with (predicted) mild pancreatitis and normal or only mildly elevated serum bilirubin levels, it has been clearly shown that ERCP has no role, with one randomised control trial suggesting an increase in complication rate,<sup>230</sup> two suggesting no benefit<sup>228 229</sup> and one published in abstract form suggesting improvement.<sup>231</sup> Meta-analysis of these trials suggests early ESE for unselected cases of biliary pancreatitis will save one life for every 26 patients treated.<sup>232</sup> However, this conclusion appears to be misleading given the heterogeneity of the studies described. Furthermore, a conservative approach to mild pancreatitis is supported by observations that 80% of patients with mild biliary pancreatitis pass stones spontaneously<sup>233</sup> and that it is uncommon to find ductal stones in this group at ERCP.<sup>104</sup> It is therefore recommended that non-jaundiced patients with mild biliary pancreatitis require supportive treatment only during the acute stage of their illness. Where such patients undergo cholecystectomy this should be performed within 2 weeks of presentation. Routine preoperative ERCP is unnecessary.<sup>234 235</sup> Some very recent reports, which only came to light as these guidelines went to press, seem to support the view that only patients with acute pancreatitis who also have cholangitis will benefit specifically from emergency sphincterotomy and that perhaps early intervention in patients with pancreatitis but no cholangitis is not advantageous (Petrov, accepted for publication).

#### 11.4 Acute cholangitis

Patients with acute cholangitis who fail to respond to antibiotic therapy or who have signs of septic shock require urgent biliary decompression. Biliary sphincterotomy, supplemented by stenting or stone extraction, is therefore indicated. Radiographically guided percutaneous drainage can be considered as an alternative to ERCP but open surgery should be avoided. (Evidence grade Ib. Recommendation grade A.)

The majority of patients with calculous cholangitis have mild to moderate disease, which responds to antibiotics. In such circumstances endoscopic and/or surgical management can be planned on an elective basis. However, a minority have signs of severe sepsis and, overall, 15–30% of patients with bacterial cholangitis fail to respond to antibiotic therapy.<sup>236</sup> Such patients require urgent biliary decompression. Where bile duct stones are



**Figure 2** Algorithm for management of common bile duct stones. BS, biliary sphincterotomy; CBD, common bile duct; CBDS, common bile duct stones; ESE, endoscopic stone extraction; ESWL, extra-corporeal shock wave lithotripsy.

identified endoscopic biliary sphincterotomy and stone extraction is treatment of choice with reported success rates of over 90% and mortality rates of 4–10%.<sup>237 238</sup> It should be noted that for patients with pus within the bile duct many clinicians advocate stenting +/- BS as initial therapy, to avoid prolonged ERCP times and minimise complication rates of the procedure. Open surgery in this group is associated with a considerably higher mortality than ERCP and should be avoided.<sup>237 239</sup> It is recognised that in circumstances where ERCP fails or is unavailable percutaneous biliary drainage has a role.

A minority of patients with gallstones and severe cholangitis have an empty common bile duct at the time of ERCP. Mortality in this group is low when compared to patients with a retained stone. Hui *et al*<sup>240</sup> have reported that whilst BS shortens duration of both fever and hospital stay in such patients, it does not influence the incidence of recurrent cholangitis. Nonetheless, given that small stones can be missed on cholangiography, BS followed by balloon or basket tawl of the duct is recommended for all cholangitis patients that require emergency ERCP.

#### 11.5 CBDS in pregnancy

In pregnant patients with symptomatic CBDS, recommended treatment options include ERCP (with biliary sphincterotomy and endoscopic stone extraction) and LCBDE. (Evidence grade III. Recommendation grade B.)

Little has been published in this area. However, a review of case series and individual reports suggest that BS is a safe and effective treatment for CBDS in the pregnant patient.<sup>241 242</sup> The foetus should be appropriately shielded and it is important that the endoscopist keeps radiation exposure to a minimum, which can be achieved by limiting fluoroscopy time and taking “screen grabs” rather than hard copies of ERCP images. To minimise the risk of aspiration arising from gastro-oesophageal reflux, women in the 2<sup>nd</sup> or 3<sup>rd</sup> trimester of pregnancy should have ERCP performed under general anaesthesia with endotracheal

intubation. It should be remembered that in late pregnancy the supine position can induce severe hypotension and must be avoided. Successful laparoscopic cholecystectomy and stone clearance has also been reported in pregnant patients<sup>243-245</sup> and may be considered in units where the technique is available. It should be noted there is insufficient data to draw firm conclusions about the efficacy of surgery versus endoscopy.

## 12.0 ACKNOWLEDGEMENTS

The writing group would also like to acknowledge the comments and suggestions of Nick Hayes, Association of Upper Gastrointestinal Surgeons of Great Britain and Ireland (AUGIS); Don Menzies, Association of Laparoscopic Surgeons of Great Britain and Ireland (ALS); Kel Palmer, previous chair of both the Joint Advisory Group on Gastrointestinal Endoscopy (JAG) and BSG Endoscopy Committee; Duncan Loft, on behalf of the BSG Clinical Standards and Services Committee; and Roland Valori, National Endoscopy Lead.

**Competing interests:** None.

## REFERENCES

- American Gastroenterological Association.** *The burden of gastro-intestinal diseases.* Bethesda, MD: American Gastroenterological Association, 2001.
- British Society of Gastroenterology.** *Guidelines for informed consent for endoscopic procedures.* London: BSG, 1999.
- British Society of Gastroenterology.** United Kingdom guidelines for the management of acute pancreatitis. *Gut* 2005;**54**:1-9.
- British Society of Gastroenterology.** *Antibiotic prophylaxis in gastrointestinal endoscopy.* London: BSG, January 2001. Updates available at [www.bsg.org.uk](http://www.bsg.org.uk).
- Neugebauer E, Sauerland S, Fingerhut A, et al.** eds. *EAES guidelines for endoscopic surgery.* Berlin: Springer, 2006. chaps 15 and 16.
- National Institutes of Health.** Gastro-intestinal endoscopy. In: The NIH State-of-the-Science Conference: ERCP for Diagnosis and Therapy. *Gastrointest Endosc* 2002;**56**:Suppl 6.
- Everhart JE, Khare M, Hill M, et al.** Prevalence and ethnic differences in gallbladder disease in the United States. *Gastroenterology* 1999;**117**:632-9.
- Pixley F, Wilson D, McPherson K, et al.** Effect of vegetarianism on development of gall stones in women. *BMJ (Clin Res Ed)* 1985;**291**:11-2.
- Bateson MC.** Gallstones and cholecystectomy in modern Britain. *Postgrad Med J* 2000;**76**:700-3.
- Barbara L, Sama C, Morselli Labate AM, et al.** A population study on the prevalence of gallstone disease: the Sirmione Study. *Hepatology* 1987;**7**:913-7.
- Gracie WA, Ransohoff DF.** The natural history of silent gallstones: the innocent gallstone is not a myth. *N Engl J Med* 1982;**307**:798-800.
- Attili AF, De Santis A, Capri R, et al.** The natural history of gallstones: the GREPCO experience. The GREPCO Group. *Hepatology* 1995;**21**:655-60.
- Lund J.** Surgical indication in cholelithiasis: prophylactic cholecystectomy elucidated on the basis of long-term follow up on 526 non-operated cases. *Ann Surg* 1960;**151**:153-62.
- Ralson D, Smith L.** The natural history of cholelithiasis: a 15-30 year follow up of 116 patients. *Minn Med* 1965;**48**:327-32.
- Kaufman HS, Magnuson TH, Lillemo KD, et al.** The role of bacteria in gallbladder and common duct stone formation. *Ann Surg* 1989;**209**:584-91; discussion 91-2.
- Cetta FM.** Bile infection documented as initial event in the pathogenesis of brown pigment biliary stones. *Hepatology* 1986;**6**:482-9.
- Neuhauser H, Feussner H, Ungeheuer A, et al.** Prospective evaluation of the use of endoscopic retrograde cholangiography prior to laparoscopic cholecystectomy. *Endoscopy* 1992;**24**:745-9.
- Saltzstein EC, Peacock JB, Thomas MD.** Preoperative bilirubin, alkaline phosphatase and amylase levels as predictors of common duct stones. *Surg Gynecol Obstet* 1982;**154**:381-4.
- Lacaine F, Corlette MB, Bismuth H.** Preoperative evaluation of the risk of common bile duct stones. *Arch Surg* 1980;**115**:1114-6.
- Houdart R, Perniceni T, Darne B, et al.** Predicting common bile duct lithiasis: determination and prospective validation of a model predicting low risk. *Am J Surg* 1995;**170**:38-43.
- Welbourn CR, Mehta D, Armstrong CP, et al.** Selective preoperative endoscopic retrograde cholangiography with sphincterotomy avoids bile duct exploration during laparoscopic cholecystectomy. *Gut* 1995;**37**:576-9.
- Collins C, Maguire D, Ireland A, et al.** A prospective study of common bile duct calculi in patients undergoing laparoscopic cholecystectomy: natural history of choledocholithiasis revisited. *Ann Surg* 2004;**239**:28-33.
- Yeong ML, Nicholson GI, Lee SP.** Regression of biliary cirrhosis following choledochal cyst drainage. *Gastroenterology* 1982;**82**:332-5.
- Hammel P, Couvelard A, O'Toole D, et al.** Regression of liver fibrosis after biliary drainage in patients with chronic pancreatitis and stenosis of the common bile duct. *N Engl J Med* 2001;**344**:418-23.
- Nathan T, Kjeldsen J, Schaffalitzky de Muckadell OB.** Prediction of therapy in primary endoscopic retrograde cholangiopancreatography. *Endoscopy* 2004;**36**:527-34.
- Onken JE, Brazer SR, Eisen GM, et al.** Predicting the presence of choledocholithiasis in patients with symptomatic cholelithiasis. *Am J Gastroenterol* 1996;**91**:762-7.
- Trondsen E, Edwin B, Reiertsen O, et al.** Prediction of common bile duct stones prior to cholecystectomy: a prospective validation of a discriminant analysis function. *Arch Surg* 1998;**133**:162-6.
- Thornton JR, Lobo AJ, Lintott DJ, et al.** Value of ultrasound and liver function tests in determining the need for endoscopic retrograde cholangiopancreatography in unexplained abdominal pain. *Endoscopy* 1992;**33**:1559-61.
- Carlson GL, Rhodes M, Stock S, et al.** Role of endoscopic retrograde cholangiopancreatography in the investigation of pain after cholecystectomy. *Br J Surg* 1992;**79**:1342-5.
- Chen YK, McCarter TL, Santoro MJ, et al.** Utility of endoscopic retrograde cholangiopancreatography in the evaluation of idiopathic abdominal pain. *Am J Gastroenterol* 1993;**88**:1355-8.
- Soto JA, Velez SM, Guzman J.** Choledocholithiasis: diagnosis with oral-contrast-enhanced CT cholangiography. *AJR Am J Roentgenol* 1999;**172**:943-8.
- Soto JA, Alvarez O, Munera F, et al.** Diagnosing bile duct stones: comparison of unenhanced helical CT, oral contrast-enhanced CT cholangiography, and MR cholangiography. *AJR Am J Roentgenol* 2000;**175**:1127-34.
- Ishikawa M, Tagami Y, Toyota T, et al.** Can three-dimensional helical CT cholangiography before laparoscopic cholecystectomy be a substitute study for endoscopic retrograde cholangiography? *Surg Laparosc Endosc Percutan Tech* 2000;**10**:351-6.
- Polkowski M, Palucki J, Regula J, et al.** Helical computed tomographic cholangiography versus endosonography for suspected bile duct stones: a prospective blinded study in non-jaundiced patients. *Gut* 1999;**45**:744-9.
- Jimenez Cuenca I, del Olmo Martinez L, Perez Horns M.** Helical CT without contrast in choledocholithiasis diagnosis. *Eur Radiol* 2001;**11**:197-201.
- Neitlich JD, Topazian M, Smith RC, et al.** Detection of choledocholithiasis: comparison of unenhanced helical CT and endoscopic retrograde cholangiopancreatography. *Radiology* 1997;**203**:753-7.
- Okada M, Fukada J, Toya K, et al.** The value of drip infusion cholangiography using multidetector-row helical CT in patients with choledocholithiasis. *Eur Radiol* 2005;**15**:2140-5. Epub 005 Jun 21.
- Amouyal P, Amouyal G, Levy P, et al.** Diagnosis of choledocholithiasis by endoscopic ultrasonography. *Gastroenterology* 1994;**106**:1062-7.
- Sugiyama M, Atomi Y.** Endoscopic ultrasonography for diagnosing choledocholithiasis: a prospective comparative study with ultrasonography and computed tomography. *Gastrointest Endosc* 1997;**45**:143-6.
- Kondo S, Isayama H, Akahane M, et al.** Detection of common bile duct stones: comparison between endoscopic ultrasonography, magnetic resonance cholangiography, and helical-computed-tomographic cholangiography. *Eur J Radiol* 2005;**54**:271-5.
- Demartines N, Eisner L, Schnabel K, et al.** Evaluation of magnetic resonance cholangiography in the management of bile duct stones. *Arch Surg* 2000;**135**:148-52.
- Holzkecht N, Gauger J, Sackmann M, et al.** Breath-hold MR cholangiography with snapshot techniques: prospective comparative study with endoscopic retrograde cholangiography. *Radiology* 1998;**206**:657-64.
- Lomas DJ, Bearcroft PW, Gimson AE.** MR cholangiopancreatography: prospective comparison of a breath-hold 2D projection technique with diagnostic ERCP. *Eur Radiol* 1999;**9**:1411-7.
- Soto JA, Barish MA, Alvarez O, et al.** Detection of choledocholithiasis with MR cholangiography: comparison of three-dimensional fast spin-echo and single- and multisection half-Fourier rapid acquisition with relaxation enhancement sequences. *Radiology* 2000;**215**:737-45.
- Varghese JC, Liddell RP, Farrell MA, et al.** Diagnostic accuracy of magnetic resonance cholangiopancreatography and ultrasound compared with direct cholangiography in the detection of choledocholithiasis. *Clin Radiol* 2000;**55**:25-35.
- Varghese JC, Farrell MA, Courtney G, et al.** A prospective comparison of magnetic resonance cholangiopancreatography with endoscopic retrograde cholangiopancreatography in the evaluation of patients with suspected biliary tract disease. *Clin Radiol* 1999;**54**:513-20.
- Guibaud L, Bret PM, Reinhold C, et al.** Bile duct obstruction and choledocholithiasis: diagnosis with MR cholangiography. *Radiology* 1995;**197**:109-15.
- Stiris MG, Tennoe B, Aadland E, et al.** MR cholangiopancreatography and endoscopic retrograde cholangiopancreatography in patients with suspected common bile duct stones. *Acta Radiol* 2000;**41**:269-72.
- Sugiyama M, Atomi Y, Hachiya J.** Magnetic resonance cholangiography using half-Fourier acquisition for diagnosing choledocholithiasis. *Am J Gastroenterol* 1998;**93**:1886-90.
- Guarise A, Baltieri S, Mainardi P, et al.** Diagnostic accuracy of MRCP in choledocholithiasis. *Radiol Med (Torino)* 2005;**109**:239-51.
- Shanmugam V, Beattie GC, Yule SR, et al.** Is magnetic resonance cholangiopancreatography the new gold standard in biliary imaging? *Br J Radiol* 2005;**78**:888-93.

## Guidelines

52. **Scheiman JM**, Carlos RC, Barnett JL, *et al*. Can endoscopic ultrasound or magnetic resonance cholangiopancreatography replace ERCP in patients with suspected biliary disease? A prospective trial and cost analysis. *Am J Gastroenterol* 2001;**96**:2900–4.
53. **de Ledinghen V**, Lecesne R, Raymond JM, *et al*. Diagnosis of choledocholithiasis: EUS or magnetic resonance cholangiography? A prospective controlled study. *Gastrointest Endosc* 1999;**49**:26–31.
54. **Ainsworth AP**, Rafaelsen SR, Wamberg PA, *et al*. Is there a difference in diagnostic accuracy and clinical impact between endoscopic ultrasonography and magnetic resonance cholangiopancreatography? *Endoscopy* 2003;**35**:1029–32.
55. **Materne R**, Van Beers BE, Gigot JF, *et al*. Extrahepatic biliary obstruction: magnetic resonance imaging compared with endoscopic ultrasonography. *Endoscopy* 2000;**32**:3–9.
56. **Verma D**, Kapadia A, Eisen GM, *et al*. EUS vs MRCP for detection of choledocholithiasis. *Gastrointest Endosc* 2006;**64**:248–54.
57. **Prat F**, Amouyal G, Amouyal P, *et al*. Prospective controlled study of endoscopic ultrasonography and endoscopic retrograde cholangiography in patients with suspected common-bile-duct lithiasis. *Lancet* 1996;**347**:75–9.
58. **Burtin P**, Palazzo L, Canard JM, *et al*. Diagnostic strategies for extrahepatic cholestasis of indefinite origin: endoscopic ultrasonography or retrograde cholangiography? Results of a prospective study. *Endoscopy* 1997;**29**:349–55.
59. **Canto MI**, Chak A, Stellato T, *et al*. Endoscopic ultrasonography versus cholangiography for the diagnosis of choledocholithiasis. *Gastrointest Endosc* 1998;**47**:439–48.
60. **Norton SA**, Alderson D. Prospective comparison of endoscopic ultrasonography and endoscopic retrograde cholangiopancreatography in the detection of bile duct stones. *Br J Surg* 1997;**84**:1366–9.
61. **Chak A**, Hawes RH, Cooper GS, *et al*. Prospective assessment of the utility of EUS in the evaluation of gallstone pancreatitis. *Gastrointest Endosc* 1999;**49**:599–604.
62. **Dancygier H**, Nattermann C. The role of endoscopic ultrasonography in biliary tract disease: obstructive jaundice. *Endoscopy* 1994;**26**:800–2.
63. **Aube C**, Delorme B, Yzet T, *et al*. MR cholangiopancreatography versus endoscopic sonography in suspected common bile duct lithiasis: a prospective, comparative study. *AJR Am J Roentgenol* 2005;**184**:55–62.
64. **Jowell PS**, Baillie J, Branch MS, *et al*. Quantitative assessment of procedural competence. A prospective study of training in endoscopic retrograde cholangiopancreatography. *Ann Intern Med* 1996;**125**:983–9.
65. **Williams EJ**, Taylor S, Fairclough P, *et al*. Are we meeting the standards set for endoscopy? Results of a large-scale prospective survey of endoscopic retrograde cholangiopancreatography practice. *Gut* 2007;**56**:821–9.
66. **Joint Advisory Group on Gastrointestinal Endoscopy**. *Guidelines on the training, appraisal and assessment of trainees in GI endoscopy*. London: JAG, 2004 Available at <http://www.thejag.org.uk> (accessed 7 May 2008).
67. **Freeman ML**, Nelson DB, Sherman S, *et al*. Complications of endoscopic biliary sphincterotomy. *N Engl J Med* 1996;**335**:909–18.
68. **Rabenstein T**, Schneider HT, Bulling D, *et al*. Analysis of the risk factors associated with endoscopic sphincterotomy techniques: preliminary results of a prospective study, with emphasis on the reduced risk of acute pancreatitis with low-dose anticoagulation treatment. *Endoscopy* 2000;**32**:10–9.
69. **Loperfido S**, Angelini G, Benedetti G, *et al*. Major early complications from diagnostic and therapeutic ERCP: a prospective multicenter study. *Gastrointest Endosc* 1998;**48**:1–10.
70. **Masci E**, Toti G, Mariani A, *et al*. Complications of diagnostic and therapeutic ERCP: a prospective multicenter study. *Am J Gastroenterol* 2001;**96**:417–23.
71. **Mehta SN**, Pavone E, Barkun JS, *et al*. Predictors of post-ERCP complications in patients with suspected choledocholithiasis. *Endoscopy* 1998;**30**:457–63.
72. **Christensen M**, Matzen P, Schulze S, *et al*. Complications of ERCP: a prospective study. *Gastrointest Endosc* 2004;**60**:721–31.
73. **Williams EJ**, Taylor S, Fairclough P, *et al*. Risk factors for complication following ERCP: results of a large-scale, prospective multicenter study. *Endoscopy* 2007;**39**:793–801.
74. **Freeman ML**, DiSario JA, Nelson DB, *et al*. Risk factors for post-ERCP pancreatitis: a prospective, multicenter study. *Gastrointest Endosc* 2001;**54**:425–34.
75. **Nelson DB**, Freeman ML. Major hemorrhage from endoscopic sphincterotomy: risk factor analysis. *J Clin Gastroenterol* 1994;**19**:283–7.
76. **Ainsworth AP**, Rafaelsen SR, Wamberg PA, *et al*. Cost-effectiveness of endoscopic ultrasonography, magnetic resonance cholangiopancreatography and endoscopic retrograde cholangiopancreatography in patients suspected of pancreaticobiliary disease. *Scand J Gastroenterol* 2004;**39**:579–83.
77. **Cullinan M**, Gray AJG, Hargraves CMK, *et al*. Scoping Our Practice. Report from National Enquiry into Post-Operative Deaths 2004. London: available online at [www.ncepod.org.uk](http://www.ncepod.org.uk) or as a CD from NCEPOD, Epworth House, 25 City Road, London EC1Y 1AA.
78. **Oren A**, Breumelhof R, Timmer R, *et al*. Abnormal clotting parameters before therapeutic ERCP: do they predict major bleeding? *Eur J Gastroenterol Hepatol* 1999;**11**:1093–7.
79. **Grant A**, Neuberger J. Guidelines on the use of liver biopsy in clinical practice. London: British Society of Gastroenterology, 2004. Available at [www.bsg.org.uk](http://www.bsg.org.uk) (accessed 18 April 2008).
80. **Eisen GM**, Baron TH, Dominitz JA, *et al*. Guideline on the management of anticoagulation and antiplatelet therapy for endoscopic procedures. *Gastrointest Endosc* 2002;**55**:775–9.
81. **Zuckerman MJ**, Hirota WK, Adler DG, *et al*. ASGE guideline: the management of low-molecular-weight heparin and nonaspirin antiplatelet agents for endoscopic procedures. *Gastrointest Endosc* 2005;**61**:189–94.
82. **Rabenstein T**, Fischer B, Wiessner V, *et al*. Low-molecular-weight heparin does not prevent acute post-ERCP pancreatitis. *Gastrointest Endosc* 2004;**59**:606–13.
83. **Harris A**, Chan AC, Torres-Viera C, *et al*. Meta-analysis of antibiotic prophylaxis in endoscopic retrograde cholangiopancreatography (ERCP). *Endoscopy* 1999;**31**:718–24.
84. **Thompson BF**, Arguedas MR, Wilcox CM. Antibiotic prophylaxis prior to endoscopic retrograde cholangiopancreatography in patients with obstructive jaundice: is it worth the cost? *Aliment Pharmacol Ther* 2002;**16**:727–34.
85. **Niederau C**, Pohlmann U, Lubke H, *et al*. Prophylactic antibiotic treatment in therapeutic or complicated diagnostic ERCP: results of a randomized controlled clinical study. *Gastrointest Endosc* 1994;**40**:533–7.
86. **Alvey CG**. Antimicrobial prophylaxis of acute biliary endoscopic procedures. *J Antimicrob Chemother* 1993;**31**(Suppl B):101–5.
87. **Testoni PA**, Cicardi M, Bergamaschini L, *et al*. Infusion of C1-inhibitor plasma concentrate prevents hyperamylasemia induced by endoscopic sphincterotomy. *Gastrointest Endosc* 1995;**42**:301–5.
88. **Andriulli A**, Leandro G, Niro G, *et al*. Pharmacologic treatment can prevent pancreatic injury after ERCP: a meta-analysis. *Gastrointest Endosc* 2000;**51**:1–7.
89. **Duvnjak M**, Supanc V, Simicevic VN, *et al*. Use of octreotide-acetate in preventing pancreatitis-like changes following therapeutic endoscopic retrograde cholangiopancreatography. *Acta Med Croatica* 1999;**53**:115–8.
90. **Tulassay Z**, Dobronte Z, Pronai L, *et al*. Octreotide in the prevention of pancreatic injury associated with endoscopic cholangiopancreatography. *Aliment Pharmacol Ther* 1998;**12**:1109–12.
91. **Arcidiacomo R**, Gambitta P, Rossi A, *et al*. The use of a long-acting somatostatin analogue (octreotide) for prophylaxis of acute pancreatitis after endoscopic sphincterotomy. *Endoscopy* 1994;**26**:715–8.
92. **Moreto M**, Zaballa M, Casado I, *et al*. Transdermal glyceryl trinitrate for prevention of post-ERCP pancreatitis: A randomized double-blind trial. *Gastrointest Endosc* 2003;**57**:1–7.
93. **Sudhindran S**, Bromwich E, Edwards PR. Prospective randomized double-blind placebo-controlled trial of glyceryl trinitrate in endoscopic retrograde cholangiopancreatography-induced pancreatitis. *Br J Surg* 2001;**88**:1178–82.
94. **Deviere J**, Le Moine O, Van Laethem JL, *et al*. Interleukin 10 reduces the incidence of pancreatitis after therapeutic endoscopic retrograde cholangiopancreatography. *Gastroenterology* 2001;**120**:498–505.
95. **Sand J**, Nordback I, Koskinen M, *et al*. Nifedipine for suspected type II sphincter of Oddi dyskinesia. *Am J Gastroenterol* 1993;**88**:530–5.
96. **Prat F**, Amaris J, Ducot B, *et al*. Nifedipine for prevention of post-ERCP pancreatitis: a prospective, double-blind randomized study. *Gastrointest Endosc* 2002;**56**:202–8.
97. **Li ZS**, Pan X, Zhang WJ, *et al*. Effect of octreotide administration in the prophylaxis of post-ERCP pancreatitis and hyperamylasemia: A multicenter, placebo-controlled, randomized clinical trial. *Am J Gastroenterol* 2007;**102**:46–51.
98. **Andriulli A**, Clemente R, Solmi L, *et al*. Gabexate or somatostatin administration before ERCP in patients at high risk for post-ERCP pancreatitis: a multicenter, placebo-controlled, randomized clinical trial. *Gastrointest Endosc* 2002;**56**:488–95.
99. **Andriulli A**, Solmi L, Loperfido S, *et al*. Prophylaxis of ERCP-related pancreatitis: A randomized, controlled trial of somatostatin and gabexate mesylate. *Clin Gastroenterol Hepatol* 2004;**2**:713–8.
100. **Andriulli A**, Leandro G, Federici T, *et al*. Prophylactic administration of somatostatin or gabexate does not prevent pancreatitis after ERCP: an updated meta-analysis. *Gastrointest Endosc* 2007;**65**:624–32.
101. **British Society of Gastroenterology**. *Safety and sedation during endoscopic procedures*. London: BSG, 2003 Available at [www.bsg.org.uk](http://www.bsg.org.uk) (accessed 18 April 2008).
102. **Rex DK**, Heuss LT, Walker JA, *et al*. Trained registered nurses/endoscopy teams can administer propofol safely for endoscopy. *Gastroenterology* 2005;**129**:1384–91.
103. **Rhodes M**, Sussman L, Cohen L, *et al*. Randomised trial of laparoscopic exploration of common bile duct versus postoperative endoscopic retrograde cholangiography for common bile duct stones. *Lancet* 1998;**351**:159–61.
104. **Tham TC**, Lichtenstein DR, Vandervoort J, *et al*. Role of endoscopic retrograde cholangiopancreatography for suspected choledocholithiasis in patients undergoing laparoscopic cholecystectomy. *Gastrointest Endosc* 1998;**47**:50–6.
105. **Geron N**, Reshef R, Shiller M, *et al*. The role of endoscopic retrograde cholangiopancreatography in the laparoscopic era. *Surg Endosc* 1999;**13**:452–6.
106. **Perissat J**, Huibregtse K, Keane FB, *et al*. Management of bile duct stones in the era of laparoscopic cholecystectomy. *Br J Surg* 1994;**81**:799–810.
107. **Koo KP**, Traverso LW. Do preoperative indicators predict the presence of common bile duct stones during laparoscopic cholecystectomy? *Am J Surg* 1996;**171**:495–9.
108. **Arregui ME**, Davis CJ, Arkush AM, *et al*. Laparoscopic cholecystectomy combined with endoscopic sphincterotomy and stone extraction or laparoscopic choledochoscopy and electrohydraulic lithotripsy for management of cholelithiasis with choledocholithiasis. *Surg Endosc* 1992;**6**:10–5.
109. **Suc B**, Escat J, Cherqui D, *et al*. Surgery vs endoscopy as primary treatment in symptomatic patients with suspected common bile duct stones: a multicenter randomized trial. French Associations for Surgical Research. *Arch Surg* 1998;**133**:702–8.
110. **Hammarstrom LE**, Stridbeck H, Ihse I. Endoscopic sphincterotomy for bile duct calculi-factors influencing the success rate. *Hepatogastroenterology* 1996;**43**:127–33.



111. **Prat F**, Malak NA, Pelletier G, *et al*. Biliary symptoms and complications more than 8 years after endoscopic sphincterotomy for choledocholithiasis. *Gastroenterology* 1996;**110**:894–9.
112. **Bergman JJ**, van der Mey S, Rauws EA, *et al*. Long-term follow-up after endoscopic sphincterotomy for bile duct stones in patients younger than 60 years of age. *Gastrointest Endosc* 1996;**44**:643–9.
113. **Hawes RH**, Cotton PB, Vallon AG. Follow-up 6 to 11 years after duodenoscopic sphincterotomy for stones in patients with prior cholecystectomy. *Gastroenterology* 1990;**98**:1008–12.
114. **Elta GH**, Barnett JL, Wille RT, *et al*. Pure cut electrocautery current for sphincterotomy causes less post-procedure pancreatitis than blended current. *Gastrointest Endosc* 1998;**47**:149–53.
115. **Stefanidis G**, Karamanolis G, Viazis N, *et al*. A comparative study of postendoscopic sphincterotomy complications with various types of electrosurgical current in patients with choledocholithiasis. *Gastrointest Endosc* 2003;**57**:192–7.
116. **Gorelick A**, Cannon M, Barnett J, *et al*. First cut, then blend: an electrocautery technique affecting bleeding at sphincterotomy. *Endoscopy* 2001;**33**:976–80.
117. **Kohler A**, Maier M, Benz C, *et al*. A new HF current generator with automatically controlled system (Endocut mode) for endoscopic sphincterotomy – preliminary experience. *Endoscopy* 1998;**30**:351–5.
118. **Siegel JH**, Veerappan A, Tucker R. Bipolar versus monopolar sphincterotomy: a prospective trial. *Am J Gastroenterol* 1994;**89**:1827–30.
119. **Macintosh DG**, Love J, Abraham NS. Endoscopic sphincterotomy by using pure-cut electrosurgical current and the risk of post-ERCP pancreatitis: a prospective randomized trial. *Gastrointest Endosc* 2004;**60**:551–6.
120. **Perini RF**, Sadurski R, Cotton PB, *et al*. Post-sphincterotomy bleeding after the introduction of microprocessor-controlled electrosurgery: does the new technology make the difference? *Gastrointest Endosc* 2005;**61**:53–7.
121. **Bergman JJ**, Rauws EA, Fockens P, *et al*. Randomised trial of endoscopic balloon dilation versus endoscopic sphincterotomy for removal of bile duct stones. *Lancet* 1997;**349**:1124–9.
122. **Baron TH**, Harewood GC. Endoscopic balloon dilation of the biliary sphincter compared to endoscopic biliary sphincterotomy for removal of common bile duct stones during ercp: a metaanalysis of randomized, controlled trials. *Am J Gastroenterol* 2004;**99**:1455–60.
123. **Park do H**, Kim MH, Lee SK, *et al*. Endoscopic sphincterotomy vs. endoscopic papillary balloon dilation for choledocholithiasis in patients with liver cirrhosis and coagulopathy. *Gastrointest Endosc* 2004;**60**:180–5.
124. **Yasuda I**, Tomita E, Enya M, *et al*. Can endoscopic papillary balloon dilation really preserve sphincter of Oddi function? *Gut* 2001;**49**:686–91.
125. **Minami A**, Nakatsu T, Uchida N, *et al*. Papillary dilation vs sphincterotomy in endoscopic removal of bile duct stones. A randomized trial with manometric function. *Dig Dis Sci* 1995;**40**:2550–4.
126. **Ochi Y**, Mukawa K, Kiyosawa K, *et al*. Comparing the treatment outcomes of endoscopic papillary dilation and endoscopic sphincterotomy for removal of bile duct stones. *J Gastroenterol Hepatol* 1999;**14**:90–6.
127. **Bergman JJ**, van Berkel AM, Bruno MJ, *et al*. A randomized trial of endoscopic balloon dilation and endoscopic sphincterotomy for removal of bile duct stones in patients with a prior Billroth II gastrectomy. *Gastrointest Endosc* 2001;**53**:19–26.
128. **Arnold JC**, Benz C, Martin WR, *et al*. Endoscopic papillary balloon dilation vs. sphincterotomy for removal of common bile duct stones: a prospective randomized pilot study. *Endoscopy* 2001;**33**:563–7.
129. **DiSario JA**, Freeman ML, Bjorkman DJ, *et al*. Endoscopic balloon dilatation vs. sphincterotomy (EDES) for bile duct stone removal [abstract]. *Digestion* 1998;**59**:26.
130. **Fujita N**, Maguchi H, Komatsu Y, *et al*. Endoscopic sphincterotomy and endoscopic papillary balloon dilatation for bile duct stones: A prospective randomized controlled multicenter trial. *Gastrointest Endosc* 2003;**57**:151–5.
131. **Weinberg BM**, Shindy W, Lo S. Endoscopic balloon sphincter dilation (sphincteroplasty) versus sphincterotomy for common bile duct stones. *Cochrane Database Syst Rev* 2006;CD004890.
132. **Maluenda F**, Csendes A, Burdiles P, *et al*. Bacteriological study of choledochal bile in patients with common bile duct stones, with or without acute suppurative cholangitis. *Hepatogastroenterology* 1989;**36**:132–5.
133. **Bergman JJ**, Rauws EA, Tijssen JG, *et al*. Biliary endoprosthesis in elderly patients with endoscopically irretrievable common bile duct stones: report on 117 patients. *Gastrointest Endosc* 1995;**42**:195–201.
134. **Chopra KB**, Peters RA, O'Toole PA, *et al*. Randomised study of endoscopic biliary endoprosthesis versus duct clearance for bile duct stones in high-risk patients. *Lancet* 1996;**348**:791–3.
135. **Vandervoort J**, Carr-Locke DL. Needle-knife access papillotomy: an unfairly maligned technique? *Endoscopy* 1996;**28**:365–6.
136. **Boender J**, Nix GA, de Ridder MA, *et al*. Endoscopic papillotomy for common bile duct stones: factors influencing the complication rate. *Endoscopy* 1994;**26**:209–16.
137. **Huibregtse K**. Complications of endoscopic sphincterotomy and their prevention. *N Engl J Med* 1996;**335**:961–3.
138. **Binmoeller KF**, Seifert H, Gerke H, *et al*. Papillary roof incision using the Erlangen-type pre-cut papillotomy to achieve selective bile duct cannulation. *Gastrointest Endosc* 1996;**44**:689–95.
139. **Foutch PG**. A prospective assessment of results for needle-knife papillotomy and standard endoscopic sphincterotomy. *Gastrointest Endosc* 1995;**41**:25–32.
140. **Kasmin FE**, Cohen D, Batra S, *et al*. Needle-knife sphincterotomy in a tertiary referral center: efficacy and complications. *Gastrointest Endosc* 1996;**44**:48–53.
141. **Williams EJ**, the Steering Committee, British Committee of Gastroenterology Audit of ERCP. Efficacy and safety of pre-cut papillotomy; results of a very large-scale survey of endoscopic retrograde cholangio-pancreatography (ERCP). *Endoscopy* 2005;**37**:A280.
142. **Mavrogiannis C**, Liatsos C, Romanos A, *et al*. Needle-knife fistulotomy versus needle-knife pre-cut papillotomy for the treatment of common bile duct stones. *Gastrointest Endosc* 1999;**50**:334–9.
143. **Tarnasky PR**, Palesch YY, Cunningham JT, *et al*. Pancreatic stenting prevents pancreatitis after biliary sphincterotomy in patients with sphincter of Oddi dysfunction. *Gastroenterology* 1998;**115**:1518–24.
144. **Fazel A**, Quadri A, Catalano MF, *et al*. Does a pancreatic duct stent prevent post-ERCP pancreatitis? A prospective randomized study. *Gastrointest Endosc* 2003;**57**:291–4.
145. **Smithline A**, Silverman W, Rogers D, *et al*. Effect of prophylactic main pancreatic duct stenting on the incidence of biliary endoscopic sphincterotomy-induced pancreatitis in high-risk patients. *Gastrointest Endosc* 1993;**39**:652–7.
146. **Singh P**, Das A, Isenberg G, *et al*. Does prophylactic pancreatic stent placement reduce the risk of post-ERCP acute pancreatitis? A meta-analysis of controlled trials. *Gastrointest Endosc* 2004;**60**:544–50.
147. **Kozarek RA**. Pancreatic stents can induce ductal changes consistent with chronic pancreatitis. *Gastrointest Endosc* 1990;**36**:93–5.
148. **Sherman S**, Hawes RH, Savides TJ, *et al*. Stent-induced pancreatic ductal and parenchymal changes: correlation of endoscopic ultrasound with ERCP. *Gastrointest Endosc* 1996;**44**:276–82.
149. **Moore MJ**, Bennett CL. The learning curve for laparoscopic cholecystectomy. The Southern Surgeons Club. *Am J Surg* 1995;**170**:55–9.
150. **Majeed AW**, Price C. Resource and manpower calculations for the provision of hepatobiliary surgical services in the UK. *Ann R Coll Surg Engl* 2004;**86**:91–5.
151. **Cuschieri A**, Lezoche E, Morino M, *et al*. E.A.E.S. multicenter prospective randomized trial comparing two-stage vs single-stage management of patients with gallstone disease and ductal calculi. *Surg Endosc* 1999;**13**:952–7.
152. **Tranter SE**, Thompson MH. Comparison of endoscopic sphincterotomy and laparoscopic exploration of the common bile duct. *Br J Surg* 2002;**89**:1495–504.
153. **Gurusamy KS**, Samraj K. Primary closure versus T-tube drainage after laparoscopic common bile duct stone exploration. *Cochrane Database Syst Rev* 2007;CD005641.
154. **Martin DJ**, Vernon DR, Touli J. Surgical versus endoscopic treatment of bile duct stones. *Cochrane Database Syst Rev* 2006;CD003327.
155. **Lygidakis NJ**. Operative risk factors of cholecystectomy-choledochotomy in the elderly. *Surg Gynecol Obstet* 1983;**157**:15–9.
156. **Siegel JH**, Kasmin FE. Biliary tract diseases in the elderly: management and outcomes. *Gut* 1997;**41**:433–5.
157. **Gonzalez JJ**, Sanz L, Grana JL, *et al*. Biliary lithiasis in the elderly patient: morbidity and mortality due to biliary surgery. *Hepatogastroenterology* 1997;**44**:1565–8.
158. **Hacker KA**, Schultz CC, Helling TS. Choledochotomy for calculous disease in the elderly. *Am J Surg* 1990;**160**:610–20; discussion 3.
159. **Mitchell RM**, O'Connor F, Dickey W. Endoscopic retrograde cholangiopancreatography is safe and effective in patients 90 years of age and older. *J Clin Gastroenterol* 2003;**36**:72–4.
160. **Garcia-Cano Lizcano J**, Gonzalez Martin JA, Taberna Arana L, *et al*. [Therapeutic biliary endoscopy in patients over 90 years of age]. *An Med Interna* 2002;**19**:409–11.
161. **Ohtani T**, Kawai C, Shirai Y, *et al*. Intraoperative ultrasonography versus cholangiography during laparoscopic cholecystectomy: a prospective comparative study. *J Am Coll Surg* 1997;**185**:274–82.
162. **Barteau JA**, Castro D, Arregui ME, *et al*. A comparison of intraoperative ultrasound versus cholangiography in the evaluation of the common bile duct during laparoscopic cholecystectomy. *Surg Endosc* 1995;**9**:490–6.
163. **Catheline J**, Rizk N, Champault G. A comparison of laparoscopic ultrasound versus cholangiography in the evaluation of the biliary tree during laparoscopic cholecystectomy. *Eur J Ultrasound* 1999;**10**:1–9.
164. **Tranter SE**, Thompson MH. A prospective single-blinded controlled study comparing laparoscopic ultrasound of the common bile duct with operative cholangiography. *Surg Endosc* 2003;**17**:216–9. Epub 2002 Dec 4.
165. **Rosenthal RJ**, Steigerwald SD, Imig R, *et al*. Role of intraoperative cholangiography during endoscopic cholecystectomy. *Surg Laparosc Endosc* 1994;**4**:171–4.
166. **Faris I**, Thomson JP, Grundy DJ, *et al*. Operative cholangiography: a reappraisal based on a review of 400 cholangiograms. *Br J Surg* 1975;**62**:966–72.
167. **Cranley B**, Logan H. Exploration of the common bile duct—the relevance of the clinical picture and the importance of peroperative cholangiography. *Br J Surg* 1980;**67**:869–72.
168. **Pagana TJ**, Stahlgren LH. Indications and accuracy of operative cholangiography. *Arch Surg* 1980;**115**:1214–5.
169. **Boraschi P**, Gigoni R, Braccini G, *et al*. Detection of common bile duct stones before laparoscopic cholecystectomy. Evaluation with MR cholangiography. *Acta Radiol* 2002;**43**:593–8.
170. **Meroni E**, Bisagni P, Bona S, *et al*. Pre-operative endoscopic ultrasonography can optimise the management of patients undergoing laparoscopic cholecystectomy with abnormal liver function tests as the sole risk factor for choledocholithiasis: a prospective study. *Dig Liver Dis* 2004;**36**:73–7.
171. **McMahon AJ**, Russell IT, Baxter JN, *et al*. Laparoscopic versus minilaparotomy cholecystectomy: a randomised trial. *Lancet* 1994;**343**:135–8.
172. **The Southern Surgeons Club**. A prospective analysis of 1518 laparoscopic cholecystectomies. *N Engl J Med* 1991;**324**:1073–8.

## Guidelines

173. **Williams EJ**, and the Steering Committee. BSG audit of ERCP. Diagnosis and management of suspected common bile duct stones in patients fit for cholecystectomy: a survey of 5 UK regions. *Gut* 2006;**55**:A94 (361) Abstract.
174. **Thompson MH**, Tranter SE. All-comers policy for laparoscopic exploration of the common bile duct. *Br J Surg* 2002;**89**:1608–12.
175. **Decker G**, Borie F, Millat B, *et al*. One hundred laparoscopic choledochotomies with primary closure of the common bile duct. *Surg Endosc* 2003;**17**:12–8.
176. **Franklin ME Jr.**, Pharand D, Rosenthal D. Laparoscopic common bile duct exploration. *Surg Laparosc Endosc* 1994;**4**:119–24.
177. **Berci G**, Morgenstern L. Laparoscopic management of common bile duct stones. A multi-institutional SAGES study. Society of American Gastrointestinal Endoscopic Surgeons. *Surg Endosc* 1994;**8**:1168–74; discussion 74–5.
178. **Petelin JB**. Laparoscopic common bile duct exploration. *Surg Endosc* 2003;**10**:10.
179. **DePaula AL**, Hashiba K, Bafutto M. Laparoscopic management of choledocholithiasis. *Surg Endosc* 1994;**8**:1399–403.
180. **Vaage A**, Stromberg C, Leijonmarck CE, *et al*. Long-term results from laparoscopic common bile duct exploration. *Surg Endosc* 2003;**17**:1181–5. Epub 2003 May 13.
181. **Ricciardi R**, Islam S, Canete JJ, *et al*. Effectiveness and long-term results of laparoscopic common bile duct exploration. *Surg Endosc* 2003;**17**:19–22. Epub 2002 Oct 29.
182. **Chung SC**, Leung JW, Leong HT, *et al*. Mechanical lithotripsy of large common bile duct stones using a basket. *Br J Surg* 1991;**78**:1448–50.
183. **Cipolletta L**, Costamagna G, Bianco MA, *et al*. Endoscopic mechanical lithotripsy of difficult common bile duct stones. *Br J Surg* 1997;**84**:1407–9.
184. **Schneider MU**, Matek W, Bauer R, *et al*. Mechanical lithotripsy of bile duct stones in 209 patients—effect of technical advances. *Endoscopy* 1988;**20**:248–53.
185. **Garg PK**, Tandon RK, Ahuja V, *et al*. Predictors of unsuccessful mechanical lithotripsy and endoscopic clearance of large bile duct stones. *Gastrointest Endosc* 2004;**59**:601–5.
186. **Staritz M**, Grosse A, Alkier R, *et al*. [Therapy of choledocholithiasis using extracorporeal shock wave lithotripsy and adjuvant surgical endoscopy]. *Z Gastroenterol* 1992;**30**:156–61.
187. **Nicholson DA**, Martin DF, Tweedle DE, *et al*. Management of common bile duct stones using a second-generation extracorporeal shockwave lithotripter. *Br J Surg* 1992;**79**:811–4.
188. **Binmoeller KF**, Bruckner M, Thonke F, *et al*. Treatment of difficult bile duct stones using mechanical, electrohydraulic and extracorporeal shock wave lithotripsy. *Endoscopy* 1993;**25**:201–6.
189. **Lomanto D**, Fiocca F, Nardovino M, *et al*. ESWL experience in the therapy of difficult bile duct stones. *Dig Dis Sci* 1996;**41**:2397–403.
190. **Gilchrist AM**, Ross B, Thomas WE. Extracorporeal shockwave lithotripsy for common bile duct stones. *Br J Surg* 1997;**84**:29–32.
191. **Sackmann M**, Holl J, Sauter GH, *et al*. Extracorporeal shock wave lithotripsy for clearance of bile duct stones resistant to endoscopic extraction. *Gastrointest Endosc* 2001;**53**:27–32.
192. **Ellis RD**, Jenkins AP, Thompson RP, *et al*. Clearance of refractory bile duct stones with extracorporeal shockwave lithotripsy. *Gut* 2000;**47**:728–31.
193. **Okugawa T**, Tsuyuguchi T, K CS, *et al*. Peroral cholangioscopic treatment of hepatolithiasis: Long-term results. *Gastrointest Endosc* 2002;**56**:366–71.
194. **Eil C**, Hochberger J, May A, *et al*. Laser lithotripsy of difficult bile duct stones by means of a rhodamine-6G laser and an integrated automatic stone-tissue detection system. *Gastrointest Endosc* 1993;**39**:755–62.
195. **Jakobs R**, Adamek HE, Maier M, *et al*. Fluoroscopically guided laser lithotripsy versus extracorporeal shock wave lithotripsy for retained bile duct stones: a prospective randomised study. *Gut* 1997;**40**:678–82.
196. **Neuhauss H**, Zillinger C, Born P, *et al*. Randomized study of intracorporeal laser lithotripsy versus extracorporeal shock-wave lithotripsy for difficult bile duct stones. *Gastrointest Endosc* 1998;**47**:327–34.
197. **Bonnel DH**, Liguory CE, Cornud FE, *et al*. Common bile duct and intrahepatic stones: results of transhepatic electrohydraulic lithotripsy in 50 patients. *Radiology* 1991;**180**:345–8.
198. **Sato M**, Watanabe Y, Tokui K, *et al*. A case of complex hepatolithiasis successfully treated with a systematic approach. *Hepatogastroenterology* 1999;**46**:3083–6.
199. **Zanon E**, Righi D, Maisano U, *et al*. Percutaneous transhepatic sphincterotomy – a report on 3 cases. *Endoscopy* 1991;**23**:25–8.
200. **Moon JH**, Cho YD, Ryu CB, *et al*. The role of percutaneous transhepatic papillary balloon dilation in percutaneous choledochoscopic lithotomy. *Gastrointest Endosc* 2001;**54**:232–6.
201. **Gil S**, de la Iglesia P, Verdu JF, *et al*. Effectiveness and safety of balloon dilation of the papilla and the use of an occlusion balloon for clearance of bile duct calculi. *AJR Am J Roentgenol* 2000;**174**:1455–60.
202. **Chen MF**, Jan YY. Percutaneous transhepatic cholangioscopic lithotripsy. *Br J Surg* 1990;**77**:530–2.
203. **Neuhauss H**. Endoscopic and percutaneous treatment of difficult bile duct stones. *Endoscopy* 2003;**35**:S31–4.
204. **Diaz D**, Bories P, Ampelas M, *et al*. Methyl tert-butyl ether in the endoscopic treatment of common bile duct radiolucent stones in elderly patients with nasobiliary tube. *Dig Dis Sci* 1992;**37**:97–100.
205. **Palmer KR**, Hofmann AF. Intraductal mono-octanoil for the direct dissolution of bile duct stones: experience in 343 patients. *Gut* 1986;**27**:196–202.
206. **British National Formulary**. March 2007. updates available at [www.bnf.org](http://www.bnf.org).
207. **Venneman NG**, Besselink MG, Keulemans YC, *et al*. Ursodeoxycholic acid exerts no beneficial effect in patients with symptomatic gallstones awaiting cholecystectomy. *Hepatology* 2006;**43**:1276–83.
208. **Johnson GK**, Geenen JE, Venu RP, *et al*. Treatment of non-extractable common bile duct stones with combination ursodeoxycholic acid plus endoprosthesis. *Gastrointest Endosc* 1993;**39**:528–31.
209. **Miller K**, Hell E, Lang B, *et al*. Gallstone formation prophylaxis after gastric restrictive procedures for weight loss: a randomized double-blind placebo-controlled trial. *Ann Surg* 2003;**238**:697–702.
210. **Swobodnik W**, Janowitz P, Kratzer W, *et al*. [Preventing the recurrence of common bile duct calculi following endoscopic papillotomy with ursodeoxycholic acid]. *Z Gastroenterol* 1990;**28**:621–5.
211. **Hammarstrom LE**, Holmin T, Stridbeck H, *et al*. Long-term follow-up of a prospective randomized study of endoscopic versus surgical treatment of bile duct calculi in patients with gallbladder in situ. *Br J Surg* 1995;**82**:1516–21.
212. **Boerma D**, Rauws EA, Keulemans YC, *et al*. Wait-and-see policy or laparoscopic cholecystectomy after endoscopic sphincterotomy for bile-duct stones: a randomised trial. *Lancet* 2002;**360**:761–5.
213. **Targarona EM**, Ayuso RM, Bordas JM, *et al*. Randomised trial of endoscopic sphincterotomy with gallbladder left in situ versus open surgery for common bile duct calculi in high-risk patients. *Lancet* 1996;**347**:926–9.
214. **Ando T**, Tsuyuguchi T, Okugawa T, *et al*. Risk factors for recurrent bile duct stones after endoscopic papillotomy. *Gut* 2003;**52**:116–21.
215. **Hammarstrom LE**, Holmin T, Stridbeck H. Endoscopic treatment of bile duct calculi in patients with gallbladder in situ: long-term outcome and factors. *Scand J Gastroenterol* 1996;**31**:294–301.
216. **Kapoor R**, Kaushik SP, Saraswat VA, *et al*. Prospective randomized trial comparing endoscopic sphincterotomy followed by surgery with surgery alone in good risk patients with choledocholithiasis. *HBP Surg* 1996;**9**:145–8.
217. **Neoptolemos JP**, Carr-Locke DL, Fossard DP. Prospective randomised study of preoperative endoscopic sphincterotomy versus surgery alone for common bile duct stones. *Br Med J (Clin Res Ed)* 1987;**294**:470–4.
218. **Stain SC**, Cohen H, Tsuishoysha M, *et al*. Choledocholithiasis. Endoscopic sphincterotomy or common bile duct exploration. *Ann Surg* 1991;**213**:627–33; discussion 33–4.
219. **Stiegmann GV**, Goff JS, Mansour A, *et al*. Precholecystectomy endoscopic cholangiography and stone removal is not superior to cholecystectomy, cholangiography, and common duct exploration. *Am J Surg* 1992;**163**:227–30.
220. **Urbach DR**, Khajanchee YS, Jobe BA, *et al*. Cost-effective management of common bile duct stones: a decision analysis of the use of endoscopic retrograde cholangiopancreatography (ERCP), intraoperative cholangiography, and laparoscopic bile duct exploration. *Surg Endosc* 2001;**15**:4–13.
221. **Erickson RA**, Carlson B. The role of endoscopic retrograde cholangiopancreatography in patients with laparoscopic cholecystectomies. *Gastroenterology* 1995;**109**:252–63.
222. **Liu TH**, Consorti ET, Kawashima A, *et al*. Patient evaluation and management with selective use of magnetic resonance cholangiography and endoscopic retrograde cholangiopancreatography before laparoscopic cholecystectomy. *Ann Surg* 2001;**234**:33–40.
223. **Liu TH**, Consorti ET, Kawashima A, *et al*. The efficacy of magnetic resonance cholangiography for the evaluation of patients with suspected choledocholithiasis before laparoscopic cholecystectomy. *Am J Surg* 1999;**178**:480–4.
224. **Dwerryhouse SJ**, Brown E, Vipond MN. Prospective evaluation of magnetic resonance cholangiography to detect common bile duct stones before laparoscopic cholecystectomy. *Br J Surg* 1998;**85**:1364–6.
225. **Sgourakis G**, Karaliotas K. Laparoscopic common bile duct exploration and cholecystectomy versus endoscopic stone extraction and laparoscopic cholecystectomy for choledocholithiasis. A prospective randomized study. *Minerva Chir* 2002;**57**:467–74.
226. **Blarney S**, Imrie C, O'Neill J, *et al*. Prognostic factors in acute pancreatitis. *Gut* 1984;**25**:1340–46.
227. **Ranson J**. The timing of biliary surgery in acute pancreatitis. *Ann Surg* 1979;**189**:654–63.
228. **Neoptolemos JP**, London N, Slater ND, *et al*. A prospective study of ERCP and endoscopic sphincterotomy in the diagnosis and treatment of gallstone acute pancreatitis. A rational and safe approach to management. *Arch Surg* 1986;**121**:697–702.
229. **Fan ST**, Lai EC, Mok FP, *et al*. Early treatment of acute biliary pancreatitis by endoscopic papillotomy. *N Engl J Med* 1993;**328**:228–32.
230. **Folsch UR**, Nitsche R, Ludtke R, *et al*. Early ERCP and papillotomy compared with conservative treatment for acute biliary pancreatitis. The German Study Group on Acute Biliary Pancreatitis. *N Engl J Med* 1997;**336**:237–42.
231. **Nowak A**, Nowakowska-Dulawa E, Marek TA, *et al*. Final results of the prospective randomised controlled study on endoscopic sphincterotomy versus conventional management in acute biliary pancreatitis [abstract]. *Gastroenterology* 1995;**108**:A380.
232. **Sharma VK**, Howden CW. Metaanalysis of randomized controlled trials of endoscopic retrograde cholangiography and endoscopic sphincterotomy for the treatment of acute biliary pancreatitis. *Am J Gastroenterol* 1999;**94**:3211–4.
233. **Acosta MJ**, Rossi R, Ledesma CL. The usefulness of stool screening for diagnosing cholelithiasis in acute pancreatitis. A description of the technique. *Am J Dig Dis* 1977;**22**:168–72.

234. **Chang L**, Lo S, Stabile BE, *et al*. Preoperative versus postoperative endoscopic retrograde cholangiopancreatography in mild to moderate gallstone pancreatitis: a prospective randomized trial. *Ann Surg* 2000;**231**:82–7.
235. **Howden JK**, Baillie J. Preoperative versus postoperative endoscopic retrograde cholangiopancreatography in mild to moderate pancreatitis: a prospective randomized trial. *Gastrointest Endosc* 2001;**53**:834–6.
236. **Andrew DJ**, Johnson SE. Acute suppurative cholangitis, a medical and surgical emergency. A review of ten years experience emphasizing early recognition. *Am J Gastroenterol* 1970;**54**:141–54.
237. **Lai EC**, Mok FP, Tan ES, *et al*. Endoscopic biliary drainage for severe acute cholangitis. *N Engl J Med* 1992;**326**:1582–6.
238. **Leung JW**, Chung SC, Sung JJ, *et al*. Urgent endoscopic drainage for acute suppurative cholangitis. *Lancet* 1989;**1**:1307–9.
239. **Larraz-Mora E**, Mayol J, Martinez-Sarmiento J, *et al*. Open biliary tract surgery: multivariate analysis of factors affecting mortality. *Dig Surg* 1999;**16**:204–8.
240. **Hui CK**, Lai KC, Wong WM, *et al*. A randomised controlled trial of endoscopic sphincterotomy in acute cholangitis without common bile duct stones. *Gut* 2002;**51**:245–7.
241. **Cappell MS**. The fetal safety and clinical efficacy of gastrointestinal endoscopy during pregnancy. *Gastroenterol Clin North Am* 2003;**32**:123–79.
242. **Tham TC**, Vandervoort J, Wong RC, *et al*. Safety of ERCP during pregnancy. *Am J Gastroenterol* 2003;**98**:308–11.
243. **Abuabara SF**, Gross GWW, Sirinek KR. Laparoscopic Cholecystectomy During Pregnancy Is Safe for Both Mother and Fetus. *J Gastrointest Surg* 1997;**1**:48–52.
244. **Lieberman MA**, Phillips EH, Carroll B, *et al*. Management of choledocholithiasis during pregnancy: a new protocol in the laparoscopic era. *J Laparoendosc Surg* 1995;**5**:399–403.
245. **DePaula AL**, Hashiba K, Bafutto M, *et al*. Laparoscopic antegrade sphincterotomy. *Surg Laparosc Endosc* 1993;**3**:157–60.
246. **Abboud PA**, Malet PF, Berlin JA, *et al*. Predictors of common bile duct stones prior to cholecystectomy: a meta-analysis. *Gastrointest Endosc* 1996;**44**:450–5.
247. **Barkun AN**, Barkun JS, Fried GM, *et al*. Useful predictors of bile duct stones in patients undergoing laparoscopic cholecystectomy. McGill Gallstone Treatment Group. *Ann Surg* 1994;**220**:32–9.