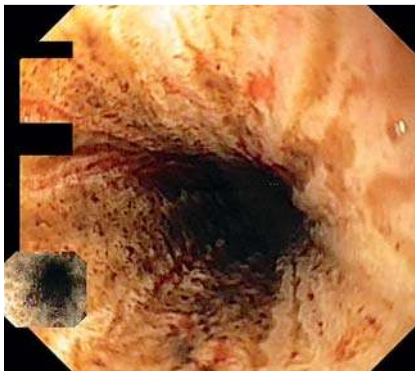


Gurvitis syndrome: the dark shade of hematemesis

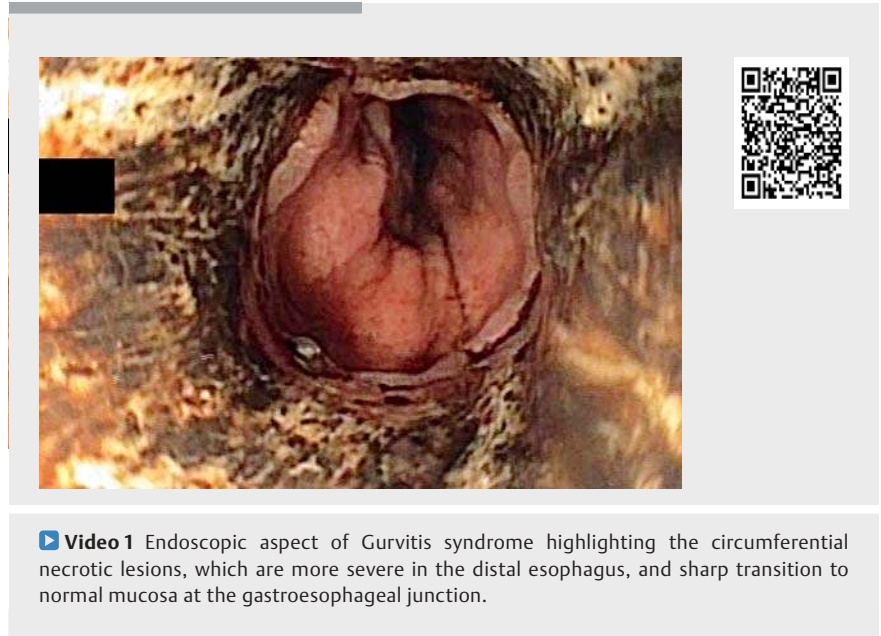
► **Table 1** Blood work-up upon admission.

Parameter	Result
Total leukocyte count, cells/mm ³	22 600
Neutrophils, %	89.3
Thrombocyte count, cells/mm ³	117 000
Hemoglobin, g/dL	9.6
Mean corpuscular volume, fL	104
Serum albumin, g/dL	1.8
Creatinine, mg/dL	2.7
Serum urea, mg/dL	85
Total bilirubin, mg/dL	2.4
Conjugated bilirubin, mg/dL	1.8
Alkaline phosphatase, U/L	242
Gamma glutamyl transpeptidase, U/L	848
International normalized ratio	1.32
Prothrombin time, seconds	16.3



► **Fig. 1** Proximal esophagus with circumferential lesions and minimal necrotic tissue.

Gurvitis syndrome, also known as acute esophageal necrosis (AEN) or “black esophagus,” is a rare syndrome characterized by necrotic lesions affecting the mucosa and submucosa, mainly in the distal part of the esophagus. Prevalence is 0.2% and incidence is 0.01%–0.0125% among Caucasians [1, 2].



► **Video 1** Endoscopic aspect of Gurvitis syndrome highlighting the circumferential necrotic lesions, which are more severe in the distal esophagus, and sharp transition to normal mucosa at the gastroesophageal junction.

A 63-year-old man who was a chronic smoker presented with a 12-hour history of hematemesis, increased abdominal girth, and weight loss (5 kg in the previous month). His medical history included biopsy-proven tubular adenocarcinoma liver metastases of unknown origin, which had been diagnosed 9 months prior to presentation and was treated with a 5-month course of chemotherapy with nanoparticles of gemcitabine and cisplatin as part of a clinical trial. Two months prior to presentation, the patient underwent two sessions of FOLFIRI (folinic acid, fluorouracil, irinotecan) as second-line chemotherapy. There was no history of corrosive intake or alcohol in the past. At admission the patient was hypotensive, with palpable liver margin and ascites. Blood work was modified as shown in ► **Table 1**. Abdominal ultrasound showed ascites, liver metastasis, and splenomegaly. Esophagogastroduodenoscopy showed AEN, circumferential black discoloration with sharp distal transition to normal mucosa at the gastroesophageal junction, starting from the superior esophageal sphincter (► **Fig. 1**),

which was more severe in the distal third of the esophagus (► **Video 1**), and a bulbar ulcer. Esophageal biopsies were not done, as these are not required for diagnosis [2].

The patient was kept nil-per-os, started on aggressive resuscitation with intravenous fluids, and given proton-pump inhibitor and broad-spectrum antibiotics. His condition did not improve, with acute liver failure and severe coagulopathy (international normalized ratio 6.8), worsened neurological status, hypoglycemia, and finally death by cardiorespiratory arrest after 4 days. Mortality rate is high (30%–50%) and related to severe co-morbidities, as the death rate due to AEN is only 6% [3, 4].

Endoscopy_UCTN_Code_CCL_1AB_2AC_3AZ

Competing interests

None

The authors

Cătălina Diaconu^{1,2}, **Mihai Ciocîrlan**^{2,3},
Mădălina Ilie^{1,2}, **Vasile Sandru**¹, **Daniel Vasile**
Balaban^{2,4}, **Oana Plotogea**^{1,2}, **Mircea**
Diculescu^{2,5}

- 1 Department of Gastroenterology, Clinical Emergency Hospital Bucharest, Bucharest, Romania
- 2 "Carol Davila" University of Medicine and Pharmacy, Bucharest, Romania
- 3 Department of Gastroenterology, Agrippa Ionescu Hospital, Bucharest, Romania
- 4 Department of Gastroenterology, Carol Davila Central Military Emergency University Hospital, Bucharest, Romania
- 5 Department of Gastroenterology, Fundeni Clinical Institute, Bucharest, Romania

Corresponding author

Mihai Ciocîrlan, MD, PhD

Department of Gastroenterology, "Agrippa Ionescu" Hospital, Ion Mincu no 7, PC 011356, Bucharest, Romania
ciocirlanm@yahoo.com

References

- [1] Zacharia GS, Sangesh K, Tamachandran TM. Acute esophageal necrosis: an uncommon cause of hematemesis. *Oman Med J* 2014; 29: 302–304
- [2] Gurvitis E. Black esophagus: acute esophageal necrosis syndrome. *World J Gastroenterol* 2010; 16: 3219–3225
- [3] Lin K, Naing Lin A, Lin S et al. Black esophagus due to metastasis colonic carcinoma. *MOJ Clin Med Case Rep* 2017; 7: 258–260
- [4] Ullah W, Mehmood A, Micaily I et al. Comprehensive review of acute oesophageal necrosis. *Br Med J Case Rep* 2019; 12: 1–4

Bibliography

DOI <https://doi.org/10.1055/a-1059-9268>
Published online: 2.12.2019
Endoscopy 2020; 52: E181–E182
© Georg Thieme Verlag KG
Stuttgart · New York
ISSN 0013-726X

ENDOSCOPY E-VIDEOS <https://eref.thieme.de/e-videos>



Endoscopy E-Videos is a free access online section, reporting on interesting cases and new techniques in gastroenterological endoscopy. All papers include a high quality video and all contributions are freely accessible online.

This section has its own submission website at
<https://mc.manuscriptcentral.com/e-videos>