

## HAEMATOLOGICAL AND HISTOLOGICAL FINDINGS IN EXPERIMENTAL NEWCASTLE DISEASE

F. GALINDO-MUÑIZ<sup>1</sup>, N. L. CALDERÓN<sup>1</sup>, M. N. CHARLES<sup>1</sup>, I. G. TÉLLEZ<sup>1</sup>, T. I. FORTOUL<sup>2</sup>

<sup>1</sup>Department of Avian Production, Faculty of Veterinary Medicine and Animal Sciences, National Autonomous University of Mexico, 04510 Mexico City; <sup>2</sup>Department of Cellular and Tisular Biology, Faculty of Medicine, National Autonomous University of Mexico, 04510 Mexico City

Received December 14, 2000

Accepted May 28, 2001

### Abstract

Galindo-Muñiz F., N. L. Calderón, M. N. Charles, I. G. Téllez, T. I. Fortoul: *Haematological and Histological Findings in Experimental Newcastle Disease*. Acta Vet. Brno 2001, 70: 185-189.

To obtain more information about pathogenesis of haemorrhages in Newcastle disease, blood cells counts with special emphasis on thrombocytes were performed in 25 specific pathogen-free chickens experimentally infected by ocular instillation of 10<sup>6</sup> embryo-lethal doses 50% of a velogenic viscerotropic strain of Newcastle disease virus (Chimalhuacan strain); five control chickens were included. Histological evaluation of the bone marrow, the brain, the kidneys, the lungs and the proventriculus was carried out. Birds were killed at 24 h post infection, followed by 12 h intervals. Whole blood and tissue samples were collected. In the bone marrow early necrosis of haematopoietic islands was noted at 48 hpi. At 60 hpi, an increase in heterophil and a decrease in monocyte and lymphocyte counts was observed; thromboblats showed basophilia, nuclear and cytoplasmic vacuolation. During the same period, swelling and vacuolation of capillary endothelial cells were evident, mainly in the lungs. We consider thrombocytopenia and endothelial damage to be the main causes of haemorrhages in this animal model. A significant reduction at 72 h post infection (hpi) of thrombocyte counts and multifocal necrosis of bone marrow cells was observed. Our results suggested that thrombocytopenia was the end result of a direct viral damage to bone marrow precursor cells.

*Newcastle disease, haemorrhages, vascular endothelium, thrombocyte, bone marrow*

Petechial and ecchymotic haemorrhages are common findings in some avian diseases, however, the pathogenesis of these haemorrhages has been poorly studied. Haemorrhages may be due to bone marrow aplasia, seen in the coagulopathies, the lack of clotting factors or may occur as a consequence of disseminated intravascular coagulation and microthrombi, reported in other viral infections such as avian influenza (Gagel et al. 1970; Mo et al. 1997), in the infectious bursal disease (Skeels et al. 1980), and also in the viral infectious anemia. The possibility of direct destruction of endothelium by infectious agents in some of these infectious diseases should also be considered (Ridde11 1996). Newcastle disease (ND) velogenic viscerotropic pathotype is characterized by a high morbidity and mortality rate in unprotected chickens and by haemorrhagic and necrotic lesions in the gastrointestinal tract and other tissues and organs such as subcutis, muscles, larynx, peritracheal/esophageal tissues, serous membranes, trachea, lungs, air sacs, pericardium and myocardium. In adult hens haemorrhages are reported in ovarian follicles (Kouwenhoven 1993; Alexander 1997). The majority of lesions in ND are due to destructive effects of the virus on the endothelial cells, and other findings are, e.g. hyperaemia, oedema and haemorrhages (Cheville et al. 1972). Several viral diseases cause extensive endothelial damage, and when blood vessels are injured the haemostatic plug formed is structured by thrombocytes. These cells are present in the blood of all non-mammalian vertebrates. They are derived from mononuclear precursor cells in the bone marrow (thromboblats) which also have phagocytic activity (Grant and Zucker 1973; Chao-Fu and Hamilton 1979; Traill et al. 1983;

#### Address for correspondence:

M. V. Z. Felipa Galindo-Muñiz  
Department of Avian Production  
Faculty of Veterinary Medicine and Animal Sciences  
National Autonomous University of Mexico, 04510 Mexico City

Phone: (525) 622-5867  
Fax: (525) 622-5867 or 68  
E-mail: fegam@yahoo.com  
<http://www.vfu.cz/acta-vet/actavet.htm>

Sturkie 1986). Research into the relation between thrombocytopenia and possible thrombopoietic damage in bone marrow as a consequence of a ND virus infection is limited, and the aim of the haematological and histological evaluation is to elucidate these issues.

#### Materials and Methods

Studies were performed in 30 specific pathogen-free White Leghorn chickens, six-week-old. The absence of antibodies against ND virus was corroborated by haemagglutination inhibition (HI) test in each bird. Twenty-five birds were infected by unilateral ocular instillation with a dose of 0.2 ml per chicken of ND virus Chimalhuacan strain, an PMV-1 Mexican field isolation. The stock fluid was adjusted to an infectivity titre of  $10^6$  ELD<sub>50</sub>. The remaining 5 birds were used as controls. The birds were housed in isolation units (one group per unit) belonging to the Department of Avian Production, Faculty of Veterinary Medicine and Animal Sciences. Clinical signs were recorded during the experiment every day.

#### Haematological and histological studies

Whole blood samples were obtained and collected into a tube containing EDTA (ethylenediaminetetraacetic acid) as anticoagulant at a 1:10 dilution. Blood smears were made and stained with the classic Wright's stain. The following determinations were conducted for each blood sample: white blood cell count, differential white blood cell count, thrombocyte count, packed cell volume, plasma proteins and fibrinogen. A total thrombocyte count was calculated from a blood smear by obtaining the average number of thrombocytes in five oil immersion (monolayer) fields and applying the following formula (Campbell 1992): Estimated thrombocyte count/ $\mu$ l = mean No. of thrombocytes in 5 fields/ $1000 \times 3\ 500\ 000$ .

#### Total plasma proteins and fibrinogen

Two capillary tubes were filled with 0.1 ml of whole blood. The first tube was centrifuged for 10 min at 400 g and the plasma obtained was used to determine total plasma proteins in the Goldberg refractometer. The second tube, after centrifugation, was heated at 56 °C for 10 min to precipitate fibrinogen and again centrifuged for other 10 min at 400 g. Total plasma proteins from the second tube were determined as described. The difference between both plasma protein determinations represents the fibrinogen concentration of the sample expressed in g/dl (Coles 1989). White blood cells, packed cell volume were counted, and plasma proteins and fibrinogen determined using standard manual methods (Campbell 1992 and 1994). Groups of five chicks were sacrificed by injection of 1.5 ml barbiturate into the brachial vein at intervals of 24 h post-inoculation (hpi), 36 hpi, 48 hpi, 60 hpi, and the remaining five birds at 72 hpi. Necropsies were performed immediately and samples of bone marrow, brain, kidney, lungs and proventriculus were collected.

Five non-infected birds were killed and used as controls. Tissues were collected from each bird and fixed in 10% neutral buffered formalin for light microscopical examination. Tissues were processed and embedded in paraffin wax after fixation for 24 h, sectioned 4-5  $\mu$ m and stained with haematoxylin-eosin and Giemsa.

#### Statistical analysis

Mean values and differences were analysed using Student's *t*-test ( $p < 0.05$ ).

### Results

All the inoculated birds were clinically healthy until 24 hpi. Infected chickens had slightly reddish conjunctivas and the majority of them showed dyspnoea, sneezing and depression at 48 hpi. These signs became more pronounced with time, so that at 72 hpi the birds were obviously depressed with ruffled feathers, watery diarrhoea, anorexia and nose exudate. No neurological signs were detected at any time. Thrombocyte counts were markedly increased at 48 hpi, but in the following hours a significant reduction was evident ( $p < 0.05$ ); within 72 hpi a 50% decrease was detected (Fig. 1). Lymphocyte counts increased at 48 hpi compared with the values in control birds. A decrease in the heterophil counts was observed at 48 hpi, followed by an increase of more than 50% in

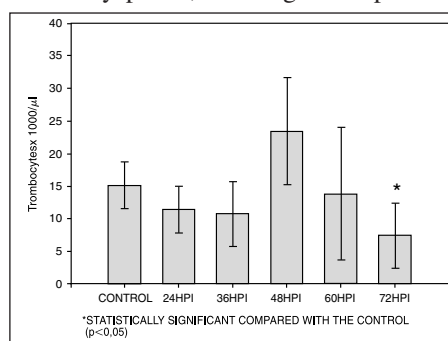


Fig. 1. Changes in thrombocytes counts after viral inoculation

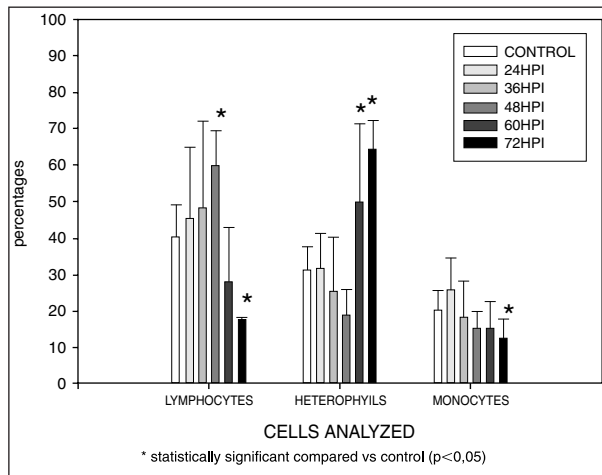


Fig. 2. Changes in blood cells after viral exposure

tissue proliferation within 60 and 72 hpi. Thromboblats had marked cytoplasmic vacuolization at 36 hpi, and nuclear vacuolization and basophilia was found at 72 hpi (Plate VIII, Figs 3, 4). There was a marked swelling of endothelial cells, mainly in small capillaries, from the bone marrow at 48 hpi (Plate IX, Figs 5, 6, Plate X, Figs 7, 8), the lungs at 60 hpi, the proventriculus and the brain at 72 hpi. Other microscopic lesions detected in the lungs, the proventriculus and the brain consisted of lymphocytic inflammation and they were very similar to those previously described in ND.

### Discussion

Clinical signs detected in the infected chickens in the present study were similar to those described in the literature on ND (Cheville et al. 1972; Lancaster 1981; McFerran and McCracken 1988; Parede and Young 1990; Kouwenhoven 1993; Alexander 1997), except that in our experimental animals the symptoms occurred earlier (48 hpi) than reported by others (Ojok and Brown 1996). This difference could be related to virulence and pathogenicity of the virus strain (Kingsbury 1991; Alexander 1997). As indicated by our results, the haematological findings are in agreement with those described by Ergene et al. (1988) except that this author found basopenia, probably due to the virus strain used for the infection of birds. In our report thrombocytosis at 48 hpi and a marked thrombocytopenia at 72 hpi. were found, similar to Cheville et al. (1972). In our study the thrombocytosis may reflect a rebound response following the destruction, or a recovery from other conditions associated with excessive utilization of thrombocytes, such as extensive endothelial damage in viral infections. The thrombocytopenias are usually indicative of excessive peripheral demand for thrombocytes, although a thrombopoietic depletion in bone marrow due to viral lesions should be considered (Campbell 1994). An immunohistochemical study related to the pathogenesis of ND, reports severe damage to bone marrow (Ojok and Brown 1996) and the presence of viral particles, associated with extensive necrosis of haematopoietic islands. In the present experiment, a significant reduction in thrombocyte counts was consistent with the results of the sequential bone marrow biopsies, which showed a progressive degeneration of the precursor cells, such as, thromboblats and the entire cell population. Calderón et al. (1997) reported that in some viral diseases, e.g. acute classical swine fever, mammals

the following hours. Monocyte counts had a progressive reduction, of about 50% at 72 hpi (Fig. 2). Values of basophil and eosinophil cell counts, packed cell volume, plasma proteins, and fibrinogen were not different from the control birds. Histological findings in the bone marrow at 48 hpi consisted of lymphocytic proliferative foci and depletion of haematopoietic cell lines. Haematopoietic islands of bone marrow were affected by multiple cell degeneration, focal necrosis and some discrete haemorrhages as well as some foci of connective

develop thrombocytopenia as a result of progressive degeneration and necrosis of megakaryocytes infected by the virus. Lymphocytosis should be expected with antigenic stimulation associated with viral infections as it was our case, and lymphopenias have been reported with certain acute viral diseases. The heterophilia usually relates to the magnitude or severity of the inflammatory process (Campbell 1994). In this study the heterophilia and lymphopenia were presented at 72 hpi, which could indicate severe damage to all tissues including lymphoid cells. The gradual monocytopenia found at about 72 hpi may be related to the capacity of the ND virus to infect many cell types and cause their degeneration and necrosis. A sequential study in chickens after ND virus infection was made by Lam (1996) who detected that the virus induced apoptosis principally in mononuclear cells macrophages and lymphocytes of the peripheral blood. Probably the thrombocytes are also affected due to their phagocytic function and the participation in removing foreign material from the blood (Chao-Fu and Hamilton 1979; Sturkie 1986; Campbell 1994). Studies of pathogenicity in other diseases showed that birds infected with the chicken anaemia agent, which produces haemorrhages, caused destruction of erythroid progenitors in bone marrow resulting in severe anaemia, and depletion of granulocytes, lymphocytes and thrombocytes, and suggested that the lesions might be closely related to the bone marrow function (Taniguchi et al. 1982, 1983; Adair 2000). In an experimental infection with infectious bursal disease virus the results indicated that the haemorrhages are associated with the depletion of some clotting factor (Skeeles 1980) but the damage in bone marrow and vascular endothelium was not evaluated. Julian (1996) mentioned that other cell types affected by endotheliotropic viruses are the endothelial cells, which are phagocytic and may ingest microorganisms causing vasculitis or obstruct capillaries which would induce necrosis. In the present study vasculitis was observed and was indicated by lymphocytic proliferation, as well as by swelling of endothelial cells, mainly in capillaries of the bone marrow, lungs, proventriculus and brain. Based on our results, thrombocytopenia and endothelial damage are considered the main causes of haemorrhages in acute stages of the ND. Our results suggest that the thrombocytopenia resulted from a direct viral damage of thrombocytes precursor cells in the bone marrow.

#### **Hematologický a histologický nález při experimentální infekci pseudomorem drůbeže**

Cílem naší experimentální práce bylo získat více informací o patogenezi krvácenin při pseudomoru drůbeže. Byl stanoven počet buněk, zejména trombocytů, z krve 25 bezmikrobních kuřat experimentálně infikovaných  $10^6$  intraokulární embryonální letální dávkou 50% velogenního viscerotropního kmenu viru pseudomoru drůbeže (Chimalhuacan); pět kmenů bylo kontrolních. Drůbež byla utrácena po 24 hodinových, posléze po 12 hodinových intervalech. K vyšetření byla odebrána krev a vzorky tkání. Histologicky byla zpracována kostní dřevina, mozek, ledviny, plíce a žláznatý žaludek. Zjistili jsme, že 72 hodin po infekci došlo k významnému snížení počtu trombocytů a k multifokální nekróze. Současně byl zaznamenán vzestup heterofilů a pokles monocytů i lymfocytů 60 hodin po infekci. Otok a vakuolizace kapilárních endoteliálních buněk, zejména v plicích, nastaly 60 hodin po infekci. V kostní dřevině jsme zaznamenali nekrózu hematopoetických ostrůvků 48 hodin po infekci; multifokální nekrózu jsme prokázali po 72 hodinách. Po 60 hodinách vykazovaly tromboplasty nukleární a cytoplazmatickou vakuolizaci a bazofilii. Za hlavní příčinu krvácenin byla považována trombocytopenie a poškození endoteliální výstelky. Naše výsledky potvrdily, že trombocytopenie byla vyvolána přímým destruktivním působením viru na prekurzory buněk kostní dřeviny.

### Acknowledgements

The authors thank Francisco Pasos from the Dept. of Cellular and Tisular Biology, Fac. Medicine, for his technical support with the illustrations.

### References

- ADAIR, B. M. 2000: Immunopathogenesis of chicken anemia virus infection. *Dev. Comp. Immunol.* **24**: 247-255
- ALEXANDER, D. J. 1997: Newcastle Disease and other avian Paramixoviridae infections. In: CALNEK, B. W., BARNES, C. W., REID, W. M., YODER, H. W.: *Diseases of Poultry*. Iowa State University Press, Ames Iowa, pp. 541-569.
- CALDERÓN, N. L., PAASCH, L. H., BOUDA, J. 1997: Haematological and histological bone marrow findings in experimental classical swine fever. *Acta Vet. Brno* **66**: 171-176
- CAMPBELL, W. T. 1992: *Avian Hematology and Cytology*. Iowa State University Press, Ames Iowa, 32 p.
- CAMPBELL, W. T. 1994: Hematology. In: BRANSON, W.R., HARRISON, J.G., HARRISON, R.L.: *Avian Medicine: principles and application*. Wingers, Lake Worth Florida, pp.176-198.
- CHEVILLE, N. F., STONE, H., RILEY, J., RITCHIE, E. A. 1972: Pathogenesis of virulent Newcastle disease in chickens. *J. Am. Vet. Med. Assoc.* **161**: 169-179
- CHAO-FU, CH., HAMILTON, P. B. 1979: The thrombocyte as the primary circulating phagocyte in chickens. *J. Reticuloendothel. Soc.* **25**: 585-590.
- COLES, E.H. 1989: *Diagnostico y Patologia en Veterinaria*. 4<sup>a</sup> ed. Interamericana Mc Graw-Hill, Mexico D.F., pp. 23-24.
- EASTERDAY, B. C., HINSHAW, U. S. 1997: Influenza. In: CALNEK, B. W., BARNES, C. W., REID, W. M., YODER, H. W. *Diseases of Poultry*. Iowa State University Press, Ames Iowa, pp. 583-605.
- ERGENE, N., CÖTELIOĞLU, Ü., ASI, Y., GÜREL, A., İYISAN, S. 1988: Hematological changes in chicken affected by Newcastle Disease. *J. Fac. Vet Univ. Istanbul* **14**: 91-106.
- GAGEL, C. H., LINDER, M., MULLER-BERGHAUS, G., LASCH, H. G. 1970: A study of the pathogenesis of haemorrhages in virus infections. Coagulopathy in classical fowl pest. *Zbl. Vet.-Med.* **17B**: 410-417
- GRANT, A. R., ZUCKER, B. M. 1973: Avian thrombocyte aggregation and shape change in vitro. *Am. J. Physiol.* **225**: 340-343
- JULIAN, R. J. 1996: Cardiovascular system. In: RIDELL, C.: *Avian Histopathology*. American Association of Avian Pathologists, Pennsylvania, pp. 69-88.
- KINGSBURY, D. W. 1991: Paramyxoviridae and their replication. In: FIELDS, B.N., KNIPE, D. M., et al.: *Fundamental Virology*. Raven Press Ltd, New York, pp. 507-524.
- KOUWENHOVEN, B. 1993: Newcastle disease. In: McFERRAN, J. B., McNULTY, M. S.: *Virus Infections of Birds*. Elsevier Science Publishers, New York, pp. 341-361.
- LANCASTER, E. J. 1981: Newcastle disease-pathogenesis and diagnosis. *World's Poult. Sci. J.* **37**: 26-33
- Mc FERRAN, B. J. McCracken, M. R. 1988: Newcastle disease. In: ALEXANDER, J. D.: *Newcastle disease*. Kluwer Academic Publishers, Massachusetts, pp. 161-183.
- MO, I. P., BRUGH, M., FLETCHER, O. J., ROWLAND, G. N. SWAYNE, D. E. 1997: Comparative pathology of chickens experimentally inoculated with avian influenza viruses of low and high pathogenicity. *Avian Dis.* **41**:125-136
- NAM-YONG, P. 1982: Disseminated intravascular coagulation in experimental fowl cholera of chickens. *Korean J. Vet. Res.* **22**: 211-219
- OJOK, L. BROWN, C. 1996: An immunohistochemical study of the pathogenesis of virulent viscerotropic Newcastle disease in chickens. *J. Comp. Path.* **115**: 221-227
- PAREDE, L., YOUNG, P. L. 1990: The pathogenesis of velogenic Newcastle disease virus infection of chickens of different ages and different levels of immunity. *Avian Dis.* **34**: 803-808
- SKELEES, J. K., SLAVIK, M., BEASLEY, J. N., BROWN, A. H., MEINECKE, C. F., MARUCA, S., WELCH, S. 1980: An age-related coagulation disorder associated with experimental infection with infectious bursal disease virus. *Am. J. Vet. Res.* **41**:1458-1461
- STURKIE, D. P., GRIMINGER, P. 1986: Body Fluids: Blood. In: STURKIE, D. P.: *Avian Physiology*. Springer-Verlag, New York, pp. 102-129.
- TANIGUCHI, T. A., YUASA, A. N., MAEDA, A. M., HORIUCHI, A. T. 1982: Hematopathological changes in dead and moribund chicks induced by chicken anemia agent. *Natl. Inst. Anim. Health Q.* **22**: 61-69
- TANIGUCHI, T. A., YUASA, A. N., MAEDA, A. M., HORIUCHI, A. T. 1983: Chronological observations on hemato-pathological changes in chicks inoculated with chicken anemia agent. *Natl. Inst. Anim. Health Q.* **23**:112
- TRAILL, K. N., BÖCK, G., BOYD, R., WICK, G. 1983: Chicken thrombocytes. Isolation, serological and functional characterisation using the fluorescence activated cell sorter. *Develop. Comp. Immunology* **7**: 111-125

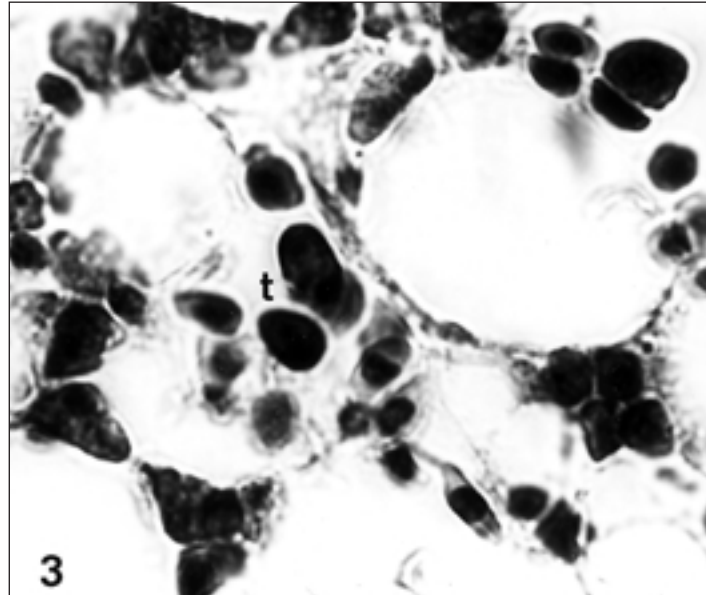


Fig. 3. Normal thromboplast.(t) with a large nucleus and scarce cytoplasm. Giemsa. x 100.

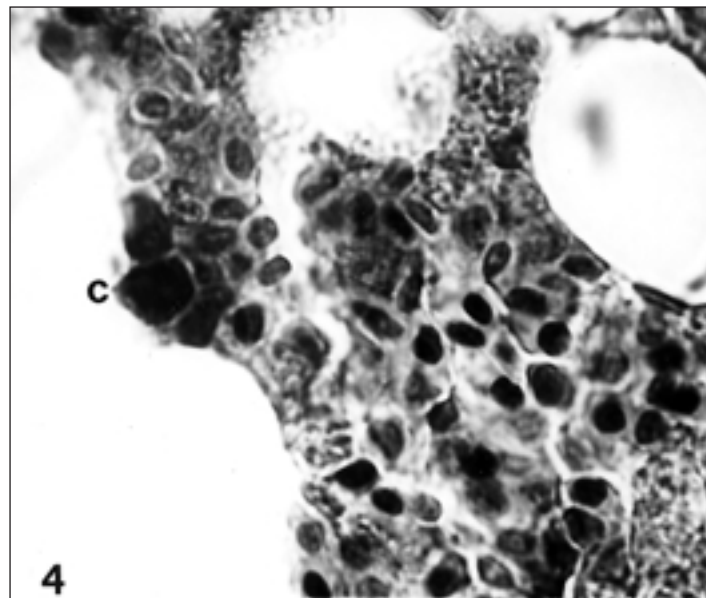


Fig. 4. Thromboplast (c) with cytoplasmic vacuolization at 36 hpi in the bone marrow of chickens infected with Newcastle Disease virus. Giemsa, x 100.

Plate IX

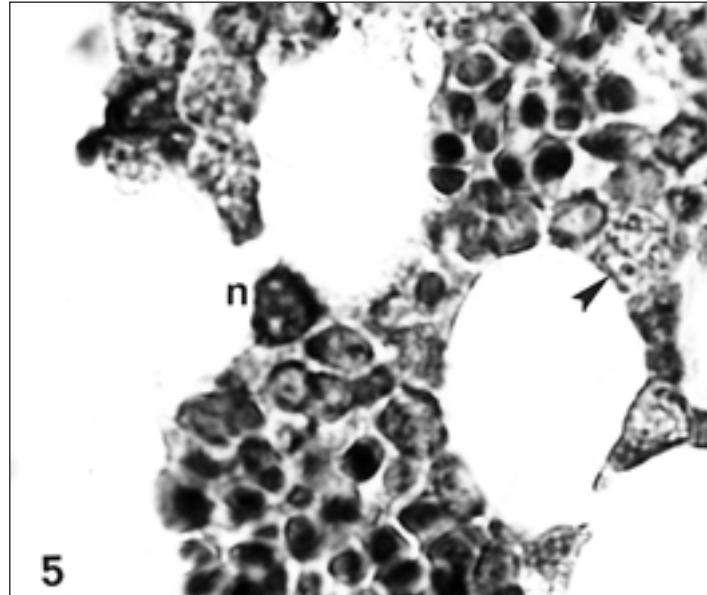


Fig. 5. Thromboplast (n) with nuclear vacuolization at 72 hpi, in the bone marrow of chickens infected with Newcastle Disease virus. Giemsa, x 100.

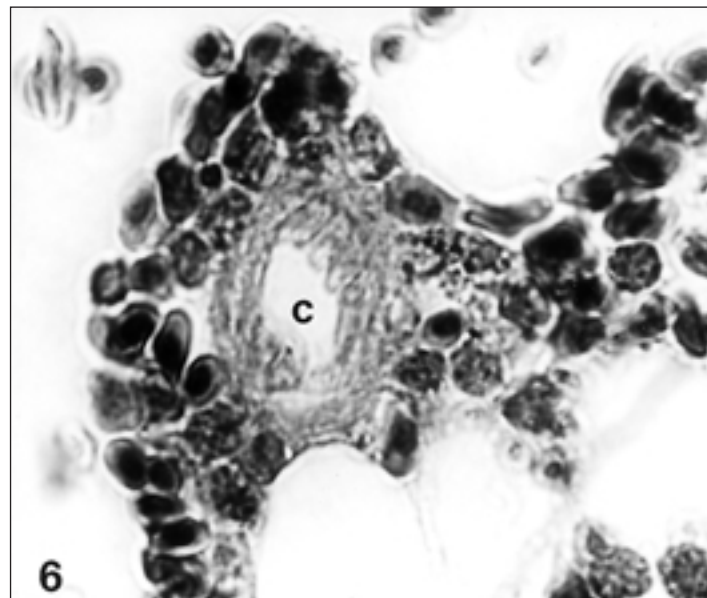


Fig. 6 Normal capillary (c) with endothelium. Giemsa, x 100.

Plate X

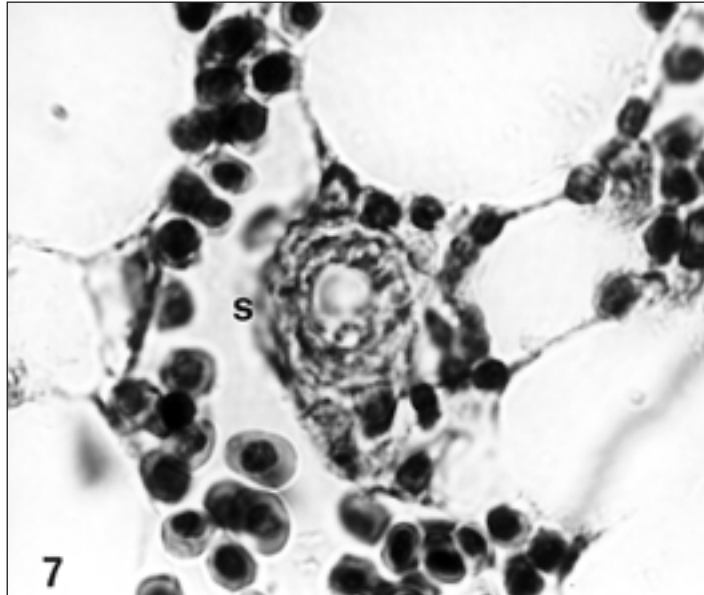


Fig. 7. Capillary (s) with swelling of endothelial cells at 48 hpi in the bone marrow of chickens infected with Newcastle Disease virus. Giemsa, x 100.

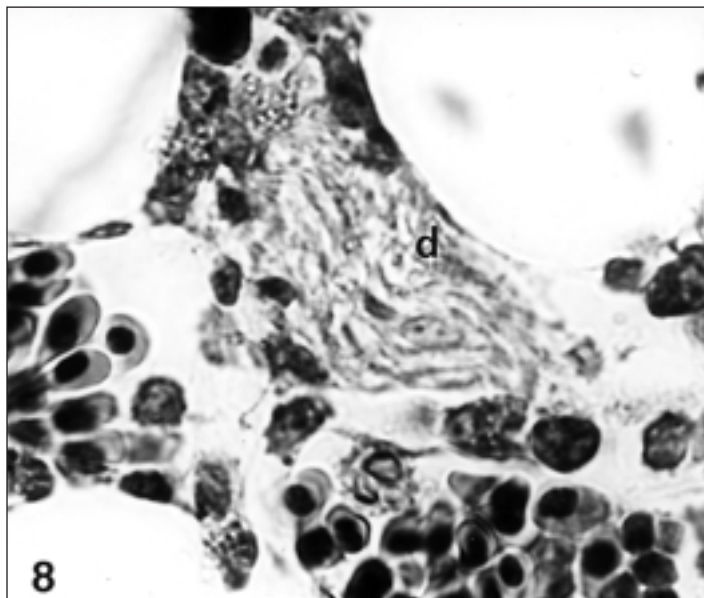


Fig. 8. Capillary (d) with vessel wall degenerated at 72 hpi, in the bone marrow of chickens infected with Newcastle Disease virus. Giemsa, x 100.