

REVIEW

Open Access

Hajdu-Cheney syndrome: a review

Ernesto Canalis* and Stefano Zanotti

Abstract

Hajdu Cheney Syndrome (HCS), Orpha 955, is a rare disease characterized by acroosteolysis, severe osteoporosis, short stature, specific craniofacial features, wormian bones, neurological symptoms, cardiovascular defects and polycystic kidneys. HCS is rare and is inherited as autosomal dominant although many sporadic cases have been reported. HCS is associated with mutations in exon 34 of *NOTCH2* upstream the PEST domain that lead to the creation of a truncated and stable NOTCH2 protein with enhanced NOTCH2 signaling activity. Although the number of cases with *NOTCH2* mutations reported are limited, it would seem that the diagnosis of HCS can be established by sequence analysis of exon 34 of *NOTCH2*. Notch receptors are single-pass transmembrane proteins that determine cell fate, and play a critical role in skeletal development and homeostasis. Dysregulation of Notch signaling is associated with skeletal developmental disorders. There is limited information about the mechanisms of the bone loss and acroosteolysis in HCS making decisions regarding therapeutic intervention difficult. Bone antiresorptive and anabolic agents have been tried to treat the osteoporosis, but their benefit has not been established. In conclusion, Notch regulates skeletal development and bone remodeling, and gain-of-function mutations of *NOTCH2* are associated with HCS.

Keywords: Notch, Skeleton, Bone remodeling, Hajdu-Cheney syndrome, Fractures, Polycystic kidneys, B cell lymphoma

Review

Disease name/synonyms

Hajdu-Cheney syndrome; Acroosteolysis dominant type; Serpentine fibula polycystic kidney syndrome; Orpha number: 955

Definition

Hajdu-Cheney syndrome (HCS) is a rare inherited connective tissue disease characterized by acroosteolysis of hands and feet, developmental defects of bones, teeth and joints causing distinctive craniofacial and skull changes, and also manifested by severe osteoporosis and short stature. The disease was first described by Hajdu in 1948 in a 37 year old accountant who died 12 years later of severe neurological complications, and the syndrome was reported further by Cheney in 1965 (Table 1) [1,2].

Epidemiology

HCS is a rare disease; less than 100 cases have been reported, but its exact prevalence is unknown.

Clinical description

Hajdu-Cheney syndrome (HCS) is a rare disease with autosomal genetic inheritance, although the disease can also have sporadic presentations. It is characterized by acroosteolysis of distal phalanges, severe osteoporosis with fractures, craniofacial and dental abnormalities and short stature [1-7]. Patients with HCS exhibit prominent skeletal features including facial dysmorphisms, craniofacial defects, such as micrognathia, mid-face flattening and dental abnormalities. There is high clinical variability and a phenotypical evolution of the clinical manifestations. Some signs of the disease, such as synophrys, hypotelorism and epicanthal folds present as early as in the first two years of life and others become more evident in young children and adolescents, so that facial features become coarser over time [7]. Eventually, adult patients develop classic features of craniofacial dysmorphism characterized by bathrocephaly with prominent occiput, mild hypertelorism with telecanthus, downslanted eyes with synophrys, low-set ears, long philtrum, micrognathia with highly arched palate or cleft palate, and short neck. Acroosteolysis is frequently observed and can present with symptoms of inflammation, including pain and swelling. Patients have short and broad digits. Generalized and local joint hypermobility are reported frequently. Spinal abnormalities

* Correspondence: canalis@uchc.edu
Departments of Orthopaedic Surgery and Medicine, UConn Health, 263 Farmington Avenue, Farmington CT 06030, USA

Table 1 Hajdu-Cheney syndrome clinical features

Craniofacial features	Skeletal features	Other features
• Facial dysmorphism, micrognathism	• Acroosteolysis, fibular deformities, fractures, joint hyperlaxity	• Short stature, developmental delay
• Open sutures, wormian bones	• Short and broad digits	• Polycystic kidneys
• Platybasia and basilar invagination	• Osteoporosis with fractures	• Neurologic symptoms, hearing loss
• Periodontal disease, tooth abnormalities and loss	• Vertebral deformities, scoliosis	• Congenital heart/vessel defect

include compression fractures, deformities, kyphosis, scoliosis, platybasia and basilar invagination. Long bone deformities such as serpentine fibula also are noted [8]. Abnormal dental eruptions, decay and premature loss of teeth are common, and patients have a deep voice, hearing loss and hirsutism. Cardiovascular defects, including patent ductus arteriosus, atrial and ventricular septal defects, mitral and aortic valve abnormalities leading to valvular insufficiency or stenosis have been reported in HCS [9,10]. Respiratory infections can present in patients with HCS. Platybasia and basilar invagination are among the most serious complications of the disease and result in severe neurological problems, including hydrocephalus, central respiratory arrest and sudden death. Some patients present with renal cysts or polycystic kidneys, and serpentine fibula polycystic kidney syndrome seems to be the same disease as HCS.

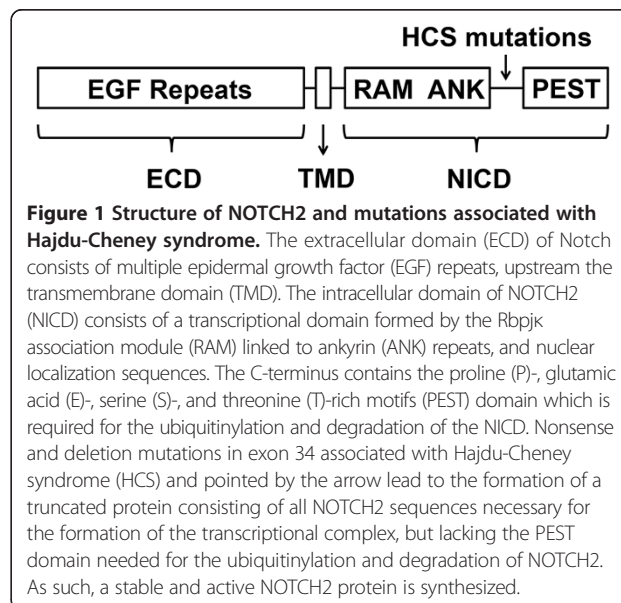
Aetiology

Over 60 years after the original description, whole exome sequencing of individuals affected by HCS revealed the presence of mutations in exon 34, the terminal exon of *NOTCH2*. Either nonsense mutations or deletions leading to a shift in the open reading frame and the creation of a termination codon in exon 34 of *NOTCH2* upstream the PEST domain are associated with HCS [11-14]. *NOTCH2* transcript levels are equivalent and not lower than those observed in controls, indicating a reduced capacity to activate the process of nonsense-mediated mRNA decay. This is common in mutations affecting terminal exons of a gene. Since the PEST domain contains sequences necessary for the ubiquitinylation and degradation of *NOTCH2* in the proteasome, the mutations lead to the accumulation of a stable protein and persistence of *NOTCH2* signaling since all sequences required for the formation of the Notch transcriptional complex are upstream the PEST domain and are therefore preserved (Figure 1). *NOTCH2* is located in Chromosome 1, 1p13 - p11.

It is of interest that somatic *NOTCH2* mutations causing loss of the PEST domain have been identified in B cell lymphoma, specifically in splenic marginal zone lymphoma [15-18]. These mutants exhibit enhanced transactivating activity in Notch reporter assays *in vitro* demonstrating that absence of the PEST domain leads to enhanced Notch activation [15,16]

Despite the pronounced skeletal abnormalities reported in HCS, little is known regarding the mechanisms underlying the bone loss. Although the distal phalangeal osteolytic lesions suggest increased localized bone resorption, there is no information on the mechanisms responsible for the generalized osteoporosis. The focal osteolysis is accompanied by neovascularization, inflammation and fibrosis [19-21]. Tissue from iliac crest biopsies has been examined in a small number of cases of HCS and revealed decreased trabecular bone, normal or increased bone remodeling, and normal or decreased bone formation [21-24]. In two published cases, increased number of osteoclasts with normal or increased osteoblasts were found suggesting that increased bone resorption may be responsible for the bone phenotype [21,25]. These observations are compatible with the known effects of *Notch2* on the murine skeleton. In osteoclast precursors, *Notch2* induces Nuclear factor of T-cells 1 transcription and osteoclastogenesis, and this effect could explain the increased bone remodeling [26,27]. Whether the osteoblast/osteocyte are also responsible for changes in bone turnover has not been established.

Mechanisms responsible for the craniofacial developmental abnormalities probably relate to the effects of Notch on skeletal development, and the short stature



may be secondary to the inhibitory effects of Notch on chondrogenesis. Less is known about potential mechanisms to explain the periodontal disease and tooth loss and those responsible for the polycystic kidney disease. Notch plays a role in cardiovascular development and angiogenesis, and this would explain the congenital heart defects.

Missense mutations in exon 34 of *NOTCH2*, upstream of sequences encoding for the PEST domain, also have been detected in patients affected by serpentine fibula-polycystic kidney syndrome and the mutations are similar to those associated with HCS [4,28,29].

Diagnosis

Patients with HCS have distinct radiologic findings, including acroosteolysis of distal phalanges of hands and feet. Plain radiographs of the skull reveal open sutures, intra sutural bones, abnormal flattening of the base of the skull, elongated sella turcica and absent frontal sinuses. Radiographs of the spine reveal bone loss and fractures. In addition, bone mineral density can be utilized to determine the presence of osteoporosis, although caution is required for its interpretation since diagnostic criteria established for postmenopausal osteoporosis may or may not apply. This is the case, for instance, with most forms of secondary osteoporosis, where a correlation between bone mineral density and fracture risk has not been established [30,31].

Based on a limited number of cases reported so far, the common pathogenetic mechanism in HCS seems to involve nonsense or deletion mutations in exon 34 of *NOTCH2*, resulting in a protein product lacking the PEST domain. Based on this information, the diagnosis of HCS would be carried out by sequence analysis of exon 34 of *NOTCH2*. For this purpose, genomic DNA is isolated from peripheral leukocytes and exon 34 amplified by polymerase chain reaction (PCR) using specific primers followed by sequence analysis of the PCR product [32].

Differential diagnosis

HCS can present with a wide range of skeletal and non-skeletal manifestations so that the differential diagnosis may include a large array of clinical conditions. Acroosteolysis can be secondary to autoimmune disorders, such as scleroderma, systemic lupus erythematosus, Sjogren's syndrome, rheumatoid arthritis and Raynaud's disease; frostbite and injuries; neuropathies; diabetes mellitus; porphyria and psoriasis [19]. Osteoporosis, primary and secondary, should be considered in the differential diagnosis of HCS [33,34]. Werner's syndrome and progeria, osteogenesis imperfecta and other rare skeletal disorders, such as Ehlers-Danlos syndrome, cleidocranial dysplasia, idiopathic juvenile osteoporosis also form part of the differential diagnosis [35].

Genetic counseling and antenatal diagnosis

Most cases of HCS are sporadic, although in certain families autosomal dominant transmission is found [11-13].

There is limited information on genetic counseling and antenatal diagnosis regarding HCS. This is in part because the disease is rare, and because many cases of HCS are sporadic. In inherited cases, prenatal diagnosis could entail *NOTCH2* gene sequence analysis, although as indicated under Diagnosis, the number of HCS cases associated with *NOTCH2* mutations is limited and other gene mutations are possible. There is limited information about the penetrance of the disease, and it is conceivable that selected patients presenting with severe idiopathic osteoporosis are low penetrance cases of HCS.

Management, including treatment of skeletal manifestations

The management of HCS requires a multi-system approach related to the organs affected by the disease in a given patient. Although patients develop acroosteolysis and osteoporosis, the mechanism of the bone loss is not known, making decisions regarding therapeutic interventions difficult. The acroosteolysis seems related to an inflammatory process. There are no controlled trials on the management of the osteoporosis; only anecdotal cases treated with either bisphosphonates or teriparatide. Bisphosphonate therapy (alendronate and pamidronate) alone or in combination with anabolic therapy with teriparatide has been attempted for the treatment of the skeletal manifestations of patients with HCS, but there is no clear evidence that either therapy is beneficial [36,37]. Teriparatide recently was shown to increase bone mineral density in a patient with HCS, but whether bisphosphonates or teriparatide offer fracture protection is not known [7]. Importantly, long-term activation of Notch signaling causes osteosarcoma in experimental mouse models, a potential concern when considering the use of teriparatide [38].

There is reasonable evidence indicating that activation of *NOTCH2* signaling causes HCS, and *NOTCH2* itself could be a future target for the treatment of the disease. Experimental modalities to control Notch signaling have been reported, including the use of antibodies to the Notch extracellular domain or its ligands, and the use of cell membrane permeable peptides that interfere with the formation of the Notch transcriptional complex [39,40]. These approaches could form the basis for the development of future therapies for HCS. However, reduced Notch signaling can result in the formation of vascular tumors in experimental animals [41]. There have been no studies reported in humans exploring these therapeutic approaches to block *NOTCH2* signaling [41].

Prognosis

HCS is a serious disease, but there is limited information about the overall prognosis of affected patients, and the

prognosis is dependent on the organs affected and the complications of the disease. The natural evolution of HCS leads to the development of acroosteolysis and osteoporosis with fractures. As a consequence of the fractures, morbidity and mortality are increased [42]. The prognosis of patients with HCS is not favorable when there is evidence of neurological impairment. Basilar invagination is one of the most serious complications of HCS, and can occur in about 50% of the cases and result in neurological complications including central respiratory arrest [6]. Due to the limited number of cases, it is not possible to know whether lifespan is reduced, although it is reasonable to believe that patients with severe neurological complications may suffer from reduced lifespan.

Molecular basis

Bone remodeling consists in the coordinated resorption and formation of bone, a process that requires the integrated involvement of cells of the osteoclast and osteoblast lineage and of signals released by these cells [43-48]. Osteoclasts are multinucleated cells derived from the fusion of mononuclear precursors of the hematopoietic lineage. The formation of osteoclasts requires receptor activator of nuclear factor κ -B ligand (RANKL) and macrophage colony stimulating factor (M-CSF) [49]. Osteoblasts are cells of mesenchymal origin, and their differentiation is tightly regulated by specific signals [50-53]. As osteoblasts become differentiated, they encounter various terminal destinies, including becoming embedded in distinct lacunae in the bone matrix as osteocytes, cells that play a fundamental role in mechanotransduction [54].

Notch 1 to 4 are single-pass transmembrane receptors that play a critical role in cell fate decisions [55-60]. Notch has a complex structure, and its extracellular domain contains multiple epidermal growth factor-like tandem repeats upstream a negative regulatory region. Downstream the transmembrane domain, there is a Notch intracellular domain (NICD) consisting of an RBPJ κ association module linked to ankyrin repeats, and together they form the Notch transcriptional domain. The C terminus contains the Proline (P), glutamic acid (E), serine (S) and threonine (T) rich (PEST) domain which is required for the ubiquitinylation and degradation of the NICD (Figure 1). There are five classic Notch ligands, which are Jagged1 and 2, and Delta Like1, 3 and 4 [61]. Notch-ligand interactions result in the proteolytic cleavage and release of the NICD, which translocates to the nucleus and interacts with Rbpj κ , and with Mastermind-like proteins to regulate transcription (Figure 2) [62-65]. This is termed the canonical signaling pathway, which leads to the transcription of Hairy and enhancer of split (Hes) 1, 5 and 7 and Hes-related with YRPW motif (Hey) 1, 2 and L [66]. The Notch non-canonical signaling pathway does not require Rbpj κ [61,67].

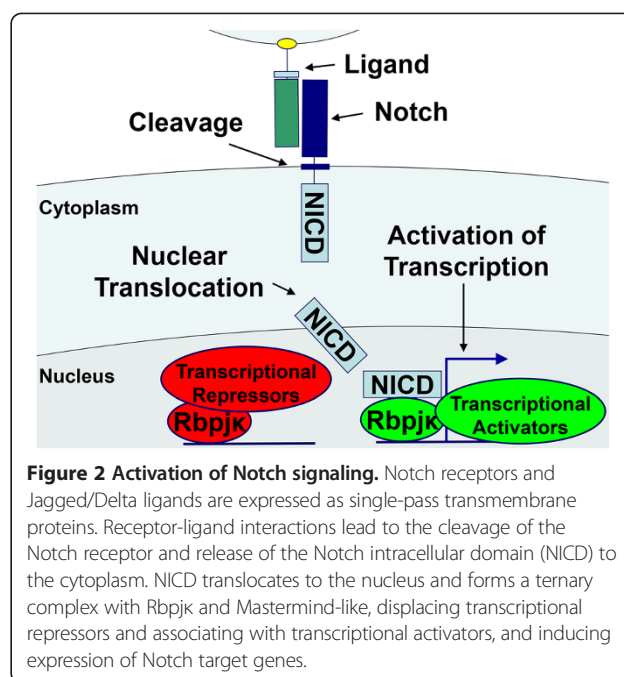


Figure 2 Activation of Notch signaling. Notch receptors and Jagged/Delta ligands are expressed as single-pass transmembrane proteins. Receptor-ligand interactions lead to the cleavage of the Notch receptor and release of the Notch intracellular domain (NICD) to the cytoplasm. NICD translocates to the nucleus and forms a ternary complex with Rbpj κ and Mastermind-like, displacing transcriptional repressors and associating with transcriptional activators, and inducing expression of Notch target genes.

Skeletal cells express Notch1, Notch2 and low levels of Notch3 transcripts [68-70]. Notch regulates cell renewal in multiple organs and cell systems, and it is involved in skeletal development and homeostasis, and in osteoblast and osteoclast differentiation [57,61,71,72]. Transgenic overexpression of Notch1 NICD in cells of the osteoblastic lineage impairs osteoblast differentiation/function and causes osteopenia [72]. Notch signaling also suppresses chondrogenesis [57,73-80]. The effects of Notch in cells of the osteoblastic lineage are cell-context dependent and determined by the degree of differentiation of the cells targeted by Notch. When Notch is activated in undifferentiated cells of the osteoblastic lineage, it suppresses their progression to maturity and inhibits osteoblast function leading to the suppression of bone formation and as a consequence to bone loss [81]. In contrast, activation of Notch in mature osteoblasts and in osteocytes increases trabecular bone mass due to suppressed osteoclast formation and decreased bone resorption [81,82]. Accordingly, developmental or post-natal inactivation of *Notch1* and *Notch2* in osteoblast progenitors enhances cancellous bone volume by increasing osteoblast number and activity [57,83].

Most of the studies reported on the function of Notch in the skeleton have examined Notch1, so that less is known regarding the function of Notch2, 3 and 4. Notch1 and Notch 2 retain structural similarity, but these receptors have distinct activities, and global null mutations of either receptor result in embryonic lethality, indicating that they do not have redundant functions [84-87]. In contrast to the inhibitory effects of Notch1 on osteoclastogenesis, Notch2 enhances osteoclastogenesis [27,88].

Unresolved questions

Current evidence indicates an association between mutations in Exon 34 of *NOTCH2* and HCS. However, the exact mechanisms by which *NOTCH2* causes the manifestations of HCS are not known. Limited bone histological analysis has resulted in inconclusive results. It is not established whether the bone loss is the result of increased bone resorption, decreased bone formation or both. As a consequence, it is difficult to make optimal therapeutic decisions, and it is not known whether anti-resorptive and anabolic therapy will reduce the incidence of fractures in patients affected by the disease. Specific inactivation of *NOTCH2* signaling by use of anti-*NOTCH2* antibodies or soluble peptides that interfere with the formation of the transcriptional complex may offer novel alternative treatments. However, appropriate clinical trials are necessary to establish their effectiveness and potential adverse event profile. The pathogenesis of the acroosteolysis may be inflammatory leading to localized bone resorption but necessary studies to establish mechanisms involved are lacking and need to be conducted.

Mouse models of HCS, where mutations are introduced in Exon 34 of *Notch2* upstream the PEST domain should serve to study the disease, explore mechanisms involved and ways to reverse phenotypic manifestations. These should form the basis for a better understanding of the disease.

Conclusions

Genetic mutations causing either gain- or loss-of-function of various components of the Notch signaling pathway are associated with diverse skeletal disorders, confirming that Notch is critical for skeletal development and homeostasis. Findings in human diseases are consistent with results of numerous pre-clinical studies. Although HCS affects a limited number of individuals, discovering a cluster of mutations in a single domain of *NOTCH2* in patients with HCS has advanced our knowledge regarding potential mechanisms leading to bone loss.

In conclusion, Notch signaling is required for skeletal development and bone homeostasis and diseases associated with dysregulation of Notch signaling are uncommon, but present with severe clinical manifestations.

Abbreviations

ANK: Ankyrin; ECD: Extracellular domain; EGF: Epidermal growth factor; HCS: Hajdu-Cheney syndrome; *Hes*: Hairy enhancer of split; *Hey*: Hes-related with YRPW-motif; M-CSF: Macrophage colony stimulating factor; NICD: Notch intracellular domain; PEST: Proline (P), glutamic acid (E), serine (S) and threonine (T) rich; PCR: Polymerase chain reaction; RAM: Rbpjk association module; RANKL: Receptor activator of nuclear factor κ -B ligand; TMD: Transmembrane domain.

Competing interests

The authors declare that they have no competing interests.

Authors' contributions

EC and SZ participated in the conception and writing of the manuscript. Both authors have read and approve the manuscript.

Acknowledgments

This work was supported by grant DK045227 (EC) from the National Institute of Diabetes, Digestive and Kidney Diseases. The content is solely the responsibility of the authors and does not necessarily represent the official views of the National Institute of Health.

Received: 26 September 2014 Accepted: 21 November 2014

Published online: 10 December 2014

References

1. Cheney WD: Acro-Osteolysis. *Am J Roentgenol Radium Ther Nucl Med* 1965, **94**:595–607.
2. Hajdu N, Kauntze R: Cranio-skeletal dysplasia. *Br J Radiol* 1948, **21**:42–48.
3. Currarino G: Hajdu-Cheney syndrome associated with serpentine fibulae and polycystic kidney disease. *Pediatr Radiol* 2009, **39**:47–52.
4. Gray MJ, Kim CA, Bertola DR, Arantes PR, Stewart H, Simpson MA, Irving MD, Robertson SP: Serpentine fibula polycystic kidney syndrome is part of the phenotypic spectrum of Hajdu-Cheney syndrome. *Eur J Hum Genet* 2012, **20**:122–124.
5. Silverman FN, Dorst JP, Hajdu N: Acroosteolysis (Hajdu-Cheney syndrome). *Birth Defects Orig Artic Ser* 1974, **10**:106–123.
6. Brennan AM, Pauli RM: Hajdu-Cheney syndrome: evolution of phenotype and clinical problems. *Am J Med Genet* 2001, **100**:292–310.
7. Descartes M, Rojnuangnit K, Cole L, Sutton A, Morgan SL, Patry L, Samuels ME: Hajdu-Cheney syndrome: phenotypical progression with de-novo *NOTCH2* mutation. *Clin Dysmorphol* 2014, **23**:88–94.
8. Stathopoulos IP, Trovas G, Lampropoulou-Adamidou K, Koromila T, Kollia P, Papaioannou NA, Lyrakis G: Severe osteoporosis and mutation in *NOTCH2* gene in a woman with Hajdu-Cheney syndrome. *Bone* 2013, **52**:366–371.
9. Kaler SG, Geggel RL, Sadeghi-Nejad A: Hajdu-Cheney syndrome associated with severe cardiac valvular and conduction disease. *Dysmorph Clin Genet* 1990, **4**:43–47.
10. Sargin G, Cildag S, Senturk T: Hajdu-Cheney syndrome with ventricular septal defect. *Kaohsiung J Med Sci* 2013, **29**:343–344.
11. Isidor B, Lindenbaum P, Pichon O, Bezieau S, Dina C, Jacquemont S, Martin-Coignard D, Thauvin-Robinet C, Le MM, Mandel JL, David A, Faivre L, Cormier-Daire V, Redon R, Le CC: Truncating mutations in the last exon of *NOTCH2* cause a rare skeletal disorder with osteoporosis. *Nat Genet* 2011, **43**:306–308.
12. Majewski J, Schwartztruber JA, Caqueret A, Patry L, Marcadier J, Fryns JP, Boycott KM, Ste-Marie LG, McKiernan FE, Marik I, Van EH, Michaud JL, Samuels ME: Mutations in *NOTCH2* in families with Hajdu-Cheney syndrome. *Hum Mutat* 2011, **32**:1114–1117.
13. Simpson MA, Irving MD, Asilmaz E, Gray MJ, Dafou D, Elmslie FV, Mansour S, Holder SE, Brain CE, Burton BK, Kim KH, Pauli RM, Aftimos S, Stewart H, Kim CA, Holder-Espinasse M, Robertson SP, Drake WM, Trembath RC: Mutations in *NOTCH2* cause Hajdu-Cheney syndrome, a disorder of severe and progressive bone loss. *Nat Genet* 2011, **43**:303–305.
14. Zhao W, Petit E, Gafni RI, Collins MT, Robey PG, Seton M, Miller KK, Mannstadt M: Mutations in *NOTCH2* in patients with Hajdu-Cheney syndrome. *Osteoporos Int* 2013, **24**:2275–2281.
15. Zhang X, Shi Y, Weng Y, Lai Q, Luo T, Zhao J, Ren G, Li W, Pan H, Ke Y, Zhang W, He Q, Wang Q, Zhou R: The Truncate Mutation of *Notch2* Enhances Cell Proliferation through Activating the NF- κ B Signal Pathway in the Diffuse Large B-Cell Lymphomas. *PLoS One* 2014, **9**:e108747.
16. Lee SY, Kumano K, Nakazaki K, Sanada M, Matsumoto A, Yamamoto G, Nannya Y, Suzuki R, Ota S, Ota Y, Izutsu K, Sakata-Yanagimoto M, Hangaishi A, Yagita H, Fukayama M, Seto M, Kurokawa M, Ogawa S, Chiba S: Gain-of-function mutations and copy number increases of *Notch2* in diffuse large B-cell lymphoma. *Cancer Sci* 2009, **100**:920–926.
17. Kiel MJ, Velusamy T, Betz BL, Zhao L, Weigelin HG, Chiang MY, Huebner-Chan DR, Bailey NG, Yang DT, Bhagat G, Miranda RN, Bahler DW, Medeiros LJ, Lim MS, Elenitoba-Johnson KS: Whole-genome sequencing identifies recurrent somatic *NOTCH2* mutations in splenic marginal zone lymphoma. *J Exp Med* 2012, **209**:1553–1565.

18. Rossi D, Trifonov V, Fangazio M, Brusca A, Rasi S, Spina V, Monti S, Vaisitti T, Arruga F, Fama R, Ciardullo C, Greco M, Cresta S, Piranda D, Holmes A, Fabbri G, Messina M, Rinaldi A, Wang J, Agostinelli C, Piccaluga PP, Lucioni M, Tabbo F, Serra R, Franceschetti S, Deambrogi C, Daniele G, Gattei V, Marasca R, Facchetti F, et al: **The coding genome of splenic marginal zone lymphoma: activation of NOTCH2 and other pathways regulating marginal zone development.** *J Exp Med* 2012, **209**:1537–1551.
19. Elias AN, Pinals RS, Anderson HC, Gould LV, Streeten DH: **Hereditary osteodysplasia with acro-osteolysis. (The Hajdu-Cheney syndrome).** *Am J Med* 1978, **65**:627–636.
20. Nunziata V, Di GG, Ballanti P, Bonucci E: **High turnover osteoporosis in acro-osteolysis (Hajdu-Cheney syndrome).** *J Endocrinol Invest* 1990, **13**:251–255.
21. Udell J, Schumacher HR Jr, Kaplan F, Fallon MD: **Idiopathic familial acroosteolysis: histomorphometric study of bone and literature review of the Hajdu-Cheney syndrome.** *Arthritis Rheum* 1986, **29**:1032–1038.
22. Avela K, Valanne L, Helenius I, Makitie O: **Hajdu-Cheney syndrome with severe dural ectasia.** *Am J Med Genet A* 2011, **155A**:595–598.
23. Blumenauer BT, Cranney AB, Goldstein R: **Acro-osteolysis and osteoporosis as manifestations of the Hajdu-Cheney syndrome.** *Clin Exp Rheumatol* 2002, **20**:574–575.
24. Brown DM, Bradford DS, Gorlin RJ, Desnick RJ, Langer LO, Jowsey J, Sauk JJ: **The acro-osteolysis syndrome: Morphologic and biochemical studies.** *J Pediatr* 1976, **88**:573–580.
25. Leidig-Bruckner G, Pfeilschifter J, Penning N, Limberg B, Priemel M, Dellling G, Ziegler R: **Severe osteoporosis in familial Hajdu-Cheney syndrome: progression of acro-osteolysis and osteoporosis during long-term follow-up.** *J Bone Miner Res* 1999, **14**:2036–2041.
26. Ikeda F, Nishimura R, Matsubara T, Hata K, Reddy SV, Yoneda T: **Activation of NFAT signal in vivo leads to osteopenia associated with increased osteoclastogenesis and bone-resorbing activity.** *J Immunol* 2006, **177**:2384–2390.
27. Fukushima H, Nakao A, Okamoto F, Shin M, Kajiya H, Sakano S, Bigas A, Jimi E, Okabe K: **The association of Notch2 and NF-kappaB accelerates RANKL-induced osteoclastogenesis.** *Mol Cell Biol* 2008, **28**:6402–6412.
28. Isidor B, Le MM, Exner GU, Pichon O, Thierry G, Guiochon-Mantel A, David A, Cormier-Daire V, Le CC: **Serpentine fibula-polycystic kidney syndrome caused by truncating mutations in NOTCH2.** *Hum Mutat* 2011, **32**:1239–1242.
29. Majewski F, Enders H, Ranke MB, Voit T: **Serpentine fibula-polycystic kidney syndrome and Melnick-Needles syndrome are different disorders.** *Eur J Pediatr* 1993, **152**:916–921.
30. Canalis E, Mazziotti G, Giustina A, Bilezikian JP: **Glucocorticoid-Induced Osteoporosis: Pathophysiology and Therapy.** *Osteoporos Int* 2007, **18**:1319–1328.
31. Mazziotti G, Canalis E, Giustina A: **Drug-induced osteoporosis: mechanisms and clinical implications.** *Am J Med* 2010, **123**:877–884.
32. Narumi Y, Min BJ, Shimizu K, Kazukawa I, Sameshima K, Nakamura K, Kosho T, Rhee Y, Chung YS, Kim OH, Fukushima Y, Park WY, Nishimura G: **Clinical consequences in truncating mutations in exon 34 of NOTCH2: report of six patients with Hajdu-Cheney syndrome and a patient with serpentine fibula polycystic kidney syndrome.** *Am J Med Genet A* 2013, **161a**:518–526.
33. Franchimont N, Canalis E: **Management of glucocorticoid induced osteoporosis in premenopausal women with autoimmune disease.** *Autoimmun Rev* 2003, **2**:224–228.
34. Miller PD: **Unrecognized and unappreciated secondary causes of osteoporosis.** *Endocrinol Metab Clin North Am* 2012, **41**:613–628.
35. Mannstadt M, Lin AE, Le LP: **Case records of the Massachusetts General Hospital. Case 24–2014. A 27-year-old man with severe osteoporosis and multiple bone fractures.** *N Engl J Med* 2014, **371**:465–472.
36. Galli-Tsinopoulou A, Kyrgios I, Giza S, Giannopoulou EM, Maggana I, Laliotis N: **Two-year cyclic infusion of pamidronate improves bone mass density and eliminates risk of fractures in a girl with osteoporosis due to Hajdu-Cheney syndrome.** *Minerva Endocrinol* 2012, **37**:283–289.
37. McKiernan FE: **Integrated anti-remodeling and anabolic therapy for the osteoporosis of Hajdu-Cheney syndrome: 2-year follow-up.** *Osteoporos Int* 2008, **19**:379–380.
38. Tao J, Jiang MM, Jiang L, Salvo JS, Zeng HC, Dawson B, Bertin TK, Rao PH, Chen R, Donehower LA, Gannon F, Lee BH: **Notch activation as a driver of osteogenic sarcoma.** *Cancer Cell* 2014, **26**:390–401.
39. Moellering RE, Cornejo M, Davis TN, Del BC, Aster JC, Blacklow SC, Kung AL, Gilliland DG, Verdine GL, Bradner JE: **Direct inhibition of the NOTCH transcription factor complex.** *Nature* 2009, **462**:182–188.
40. Ryeom SW: **The cautionary tale of side effects of chronic Notch1 inhibition.** *J Clin Invest* 2011, **121**:508–509.
41. Liu Z, Turkoz A, Jackson EN, Corbo JC, Engelbach JA, Garbow JR, Piwnicka-Worms DR, Kopan R: **Notch1 loss of heterozygosity causes vascular tumors and lethal hemorrhage in mice.** *J Clin Invest* 2011, **121**:800–808.
42. Kado DM, Browner WS, Palermo L, Nevitt MC, Genant HK, Cummings SR: **Vertebral fractures and mortality in older women: a prospective study. Study of Osteoporotic Fractures Research Group.** *Arch Intern Med* 1999, **159**:1215–1220.
43. Canalis E, Giustina A, Bilezikian JP: **Mechanisms of Anabolic Therapies for Osteoporosis.** *N Engl J Med* 2007, **357**:905–916.
44. Canalis E: **The fate of circulating osteoblasts.** *N Engl J Med* 2005, **352**:2014–2016.
45. Parfitt AM: **The bone remodeling compartment: a circulatory function for bone lining cells.** *J Bone Miner Res* 2001, **16**:1583–1585.
46. Seeman E, Delmas PD: **Bone quality—the material and structural basis of bone strength and fragility.** *N Engl J Med* 2006, **354**:2250–2261.
47. Sims NA, Martin TJ: **Coupling the activities of bone formation and resorption: a multitude of signals within the basic multicellular unit.** *BoneKey reports* 2014, **3**:481.
48. Martin TJ: **Coupling factors: how many candidates can there be?** *J Bone Miner Res* 2014, **29**:1519–1521.
49. Teitelbaum SL: **Osteoclasts: what do they do and how do they do it?** *Am J Pathol* 2007, **170**:427–435.
50. Canalis E: **Wnt signalling in osteoporosis: mechanisms and novel therapeutic approaches.** *Nat Rev Endocrinol* 2013, **9**:575–583.
51. Canalis E, Economides AN, Gazzerro E: **Bone morphogenetic proteins, their antagonists, and the skeleton.** *Endocr Rev* 2003, **24**:218–235.
52. Gazzerro E, Canalis E: **Bone morphogenetic proteins and their antagonists.** *Rev Endocr Metab Disord* 2006, **7**:51–65.
53. Monroe DG, McGee-Lawrence ME, Oursler MJ, Westendorf JJ: **Update on Wnt signaling in bone cell biology and bone disease.** *Gene* 2012, **492**:1–18.
54. Dallas SL, Prideaux M, Bonewald LF: **The osteocyte: an endocrine cell ... and more.** *Endocr Rev* 2013, **34**:658–690.
55. Zanotti S, Canalis E: **Notch regulation of bone development and remodeling and related skeletal disorders.** *Calcif Tissue Int* 2012, **90**:69–75.
56. Zanotti S, Canalis E: **Notch signaling in skeletal health and disease.** *Eur J Endocrinol* 2013, **168**:R95–R103.
57. Hilton MJ, Tu X, Wu X, Bai S, Zhao H, Kobayashi T, Kronenberg HM, Teitelbaum SL, Ross FP, Kopan R, Long F: **Notch signaling maintains bone marrow mesenchymal progenitors by suppressing osteoblast differentiation.** *Nat Med* 2008, **14**:306–314.
58. Fortini ME: **Notch signaling: the core pathway and its posttranslational regulation.** *Dev Cell* 2009, **16**:633–647.
59. Mumm JS, Kopan R: **Notch signaling: from the outside in.** *Dev Biol* 2000, **228**:151–165.
60. Sahlgren C, Lendahl U: **Notch signaling and its integration with other signaling mechanisms.** *Regen Med* 2006, **1**:195–205.
61. Zanotti S, Canalis E: **Notch and the Skeleton.** *Mol Cell Biol* 2010, **30**:886–896.
62. Kovall RA: **More complicated than it looks: assembly of Notch pathway transcription complexes.** *Oncogene* 2008, **27**:5099–5109.
63. Nam Y, Sliz P, Song L, Aster JC, Blacklow SC: **Structural basis for cooperativity in recruitment of MAML coactivators to Notch transcription complexes.** *Cell* 2006, **124**:973–983.
64. Schroeter EH, Kisslinger JA, Kopan R: **Notch-1 signalling requires ligand-induced proteolytic release of intracellular domain.** *Nature* 1998, **393**:382–386.
65. Wilson JJ, Kovall RA: **Crystal structure of the CSL-Notch-Mastermind ternary complex bound to DNA.** *Cell* 2006, **124**:985–996.
66. Iso T, Kedes L, Hamamori Y: **HES and HERP families: multiple effectors of the Notch signaling pathway.** *J Cell Physiol* 2003, **194**:237–255.
67. Andersen P, Uosaki H, Shenje LT, Kwon C: **Non-canonical Notch signaling: emerging role and mechanism.** *Trends Cell Biol* 2012, **22**:257–265.
68. Bai S, Kopan R, Zou W, Hilton MJ, Ong CT, Long F, Ross FP, Teitelbaum SL: **NOTCH1 regulates osteoclastogenesis directly in osteoclast precursors and indirectly via osteoblast lineage cells.** *J Biol Chem* 2008, **283**:6509–6518.
69. Dallas DJ, Genever PG, Patton AJ, Millichip MI, McKie N, Skerry TM: **Localization of ADAM10 and Notch receptors in bone.** *Bone* 1999, **25**:9–15.
70. Pereira RM, Delany AM, Durant D, Canalis E: **Cortisol regulates the expression of Notch in osteoblasts.** *J Cell Biochem* 2002, **85**:252–258.

71. Engin F, Yao Z, Yang T, Zhou G, Bertin T, Jiang MM, Chen Y, Wang L, Zheng H, Sutton RE, Boyce BF, Lee B: **Dimorphic effects of Notch signaling in bone homeostasis.** *Nat Med* 2008, **14**:299–305.
72. Zanotti S, Smerdel-Ramoya A, Stadmeier L, Durant D, Radtke F, Canalis E: **Notch Inhibits Osteoblast Differentiation And Causes Osteopenia.** *Endocrinology* 2008, **149**:3890–3899.
73. Dong Y, Jesse AM, Kohn A, Gunnell LM, Honjo T, Zuscik MJ, O'Keefe RJ, Hilton MJ: **RBPjkappa-dependent Notch signaling regulates mesenchymal progenitor cell proliferation and differentiation during skeletal development.** *Development* 2010, **137**:1461–1471.
74. Francis JC, Radtke F, Logan MP: **Notch1 signals through Jagged2 to regulate apoptosis in the apical ectodermal ridge of the developing limb bud.** *Dev Dyn* 2005, **234**:1006–1015.
75. Kageyama R, Masamizu Y, Niwa Y: **Oscillator mechanism of Notch pathway in the segmentation clock.** *Dev Dyn* 2007, **236**:1403–1409.
76. Zanotti S, Smerdel-Ramoya A, Canalis E: **Hairy and enhancer of split (HES)1 is a determinant of bone mass.** *J Biol Chem* 2011, **286**:2648–2657.
77. Chen S, Tao J, Bae Y, Jiang MM, Bertin T, Chen Y, Yang T, Lee B: **Notch gain of function inhibits chondrocyte differentiation via Rbpj-dependent suppression of Sox9.** *J Bone Miner Res* 2013, **28**:649–659.
78. Kohn A, Dong Y, Mirando AJ, Jesse AM, Honjo T, Zuscik MJ, O'Keefe RJ, Hilton MJ: **Cartilage-specific RBPjkappa-dependent and -independent Notch signals regulate cartilage and bone development.** *Development* 2012, **139**:1198–1212.
79. Mead TJ, Yutzey KE: **Notch pathway regulation of chondrocyte differentiation and proliferation during appendicular and axial skeleton development.** *Proc Natl Acad Sci U S A* 2009, **106**:14420–14425.
80. Zanotti S, Canalis E: **Notch suppresses nuclear factor of activated T cells (Nfat) transactivation and Nfatc1 expression in chondrocytes.** *Endocrinology* 2013, **154**:762–772.
81. Canalis E, Parker K, Feng JQ, Zanotti S: **Osteoblast Lineage-specific Effects of Notch Activation in the Skeleton.** *Endocrinology* 2013, **154**:623–634.
82. Canalis E, Adams DJ, Boskey A, Parker K, Kranz L, Zanotti S: **Notch Signaling in Osteocytes Differentially Regulates Cancellous and Cortical Bone Remodeling.** *J Biol Chem* 2013, **288**:25614–25625.
83. Zanotti S, Canalis E: **Notch1 and Notch2 expression in osteoblast precursors regulates femoral microarchitecture.** *Bone* 2014, **62**:22–28.
84. Bigas A, Martin DI, Milner LA: **Notch1 and Notch2 inhibit myeloid differentiation in response to different cytokines.** *Mol Cell Biol* 1998, **18**:2324–2333.
85. Swiatek PJ, Lindsell CE, del Amo FF, Weinmaster G, Gridley T: **Notch1 is essential for postimplantation development in mice.** *Genes Dev* 1994, **8**:707–719.
86. Conlon RA, Reaume AG, Rossant J: **Notch1 is required for the coordinate segmentation of somites.** *Development* 1995, **121**:1533–1545.
87. Weinmaster G, Roberts VJ, Lemke G: **Notch2: a second mammalian Notch gene.** *Development* 1992, **116**:931–941.
88. Sekine C, Koyanagi A, Koyama N, Hozumi K, Chiba S, Yagita H: **Differential regulation of osteoclastogenesis by Notch2/Delta-like 1 and Notch1/Jagged1 axes.** *Arthritis Res Ther* 2012, **14**:R45.

doi:10.1186/s13023-014-0200-y

Cite this article as: Canalis and Zanotti: Hajdu-Cheney syndrome: a review. *Orphanet Journal of Rare Diseases* 2014 **9**:200.

Submit your next manuscript to BioMed Central and take full advantage of:

- Convenient online submission
- Thorough peer review
- No space constraints or color figure charges
- Immediate publication on acceptance
- Inclusion in PubMed, CAS, Scopus and Google Scholar
- Research which is freely available for redistribution

Submit your manuscript at
www.biomedcentral.com/submit

