

4. Shaikh N, Leonard E, Martin JM. Prevalence of streptococcal pharyngitis and streptococcal carriage in children: a meta-analysis. *Pediatrics*. 2010;126:e557–64. <http://dx.doi.org/10.1542/peds.2009-2648>
5. Liang Y, Shen X, Huang G, Wang C, Shen Y, Yang Y. Characteristics of *Streptococcus pyogenes* strains isolated from Chinese children with scarlet fever. *Acta Paediatr*. 2008;97:1681–5. <http://dx.doi.org/10.1111/j.1651-2227.2008.00983.x>
6. Lau MCK. Increase in scarlet fever cases in 2011. *Communicable Diseases Watch*. 2011; 8:48–9 [cited 2012 Jun 30]. http://www.chp.gov.hk/files/pdf/cdw_v8_12.pdf
7. Duncan CJ, Duncan SR, Scott S. The dynamics of scarlet fever epidemics in England and Wales in the 19th century. *Epidemiol Infect*. 1996;117:493–9. <http://dx.doi.org/10.1017/S0950268800059161>
8. Köhler W, Gerlach D, Knöll H. Streptococcal outbreaks and erythrogenic toxin type A. *Zentralbl Bakteriol Mikrobiol Hyg [A]*. 1987;266:104–15. [10.1016/S0176-6724\(87\)80024-x](http://dx.doi.org/10.1016/S0176-6724(87)80024-x).
9. Nishiura H, Chowell G. The effective reproduction number as a prelude to statistical estimation of time-dependent epidemic trends. In: Chowell G, Hayman JM, Bettencourt LMA, editors. *Mathematical and statistical estimation approaches in epidemiology*. New York: Springer; 2009. p. 103–21.

Address for correspondence: Eric H.Y. Lau, School of Public Health, The University of Hong Kong, Pokfulam, Hong Kong Special Administrative Region, People's Republic of China; email: ehylau@hku.hk

Letters

Letters commenting on recent articles as well as letters reporting cases, outbreaks, or original research are welcome. Letters commenting on articles should contain no more than 300 words and 5 references; they are more likely to be published if submitted within 4 weeks of the original article's publication. Letters reporting cases, outbreaks, or original research should contain no more than 800 words and 10 references. They may have 1 Figure or Table and should not be divided into sections. All letters should contain material not previously published and include a word count.

Hand, Foot, and Mouth Disease Caused by Coxsackievirus A6

To the Editor: Coxsackievirus A6 (CVA6) is a human enterovirus associated with herpangina in infants. In the winter of 2012, we evaluated a cluster of 8 patients, 4 months–3 years of age, who were brought for treatment at Boston Children's Hospital (Boston, MA, USA) with a variant of hand, foot, and mouth disease (HFMD) that has now been linked to CVA6 (Table, Appendix, wwwnc.cdc.gov/EID/article/18/10/12-0813-T1.htm). During this same period, the Boston Public Health Commission's syndromic surveillance system detected a 3.3-fold increase in emergency department discharge diagnoses of HFMD. In the United States, HFMD typically occurs in the summer and early autumn and is characterized by a febrile exanthem of oral ulcers and macular or vesicular lesions on the palms and soles; the etiologic agents are most often CVA16 and enterovirus 71.

In contrast to the typical manifestation, the patients in the Boston cluster exhibited symptoms in late winter (Table, Appendix) and had perioral (Figure, panel A) and perirectal (Figure, panel B) papules and vesicles on the dorsal aspects of the hands and feet (Figure, panel C). Patients experienced a prodrome lasting 1–3 days, consisting of fever (8 patients), upper respiratory tract symptoms (4 patients), and irritability (7 patients). This prodrome was followed by the development of a perioral papular rash (8 patients), which was often impetiginized with secondary crusting; a prominent papulovesicular rash on the dorsum of the hands and feet (6 patients); and a perirectal eruption (7 patients). Half of the patients had intraoral lesions. Fever abated in most of the patients within a day after onset of

the exanthem. The rash resolved over 7–14 days with no residual scarring. Samples from the oropharynx, rectum, and vesicles from these patients were sent to the Centers for Disease Control and Prevention (Atlanta, GA, USA) for analysis. Reverse transcription PCR and sequencing by using primers specific for a portion of the viral protein 1 coding region identified CVA6 (1) (Table, Appendix).

Outbreaks of HFMD caused by CVA6 have been described in Singapore, Finland, Taiwan, and most recently in Japan; most cases have occurred in the warmer months (2–6). Cases in the cluster described here are likely related to an emerging outbreak of CVA6-associated HFMD in the United States (7). The atypical seasonality of the outbreak, during the winter in Boston, could be related to the unusually mild temperatures in the winter of 2012.

Recent CVA6 outbreaks have been characterized by a febrile illness associated with an oral exanthem and lesions on the palms, soles, and buttocks. CVA6 infections in Taiwan during 2004–2009 were associated with HFMD in 13% of cases, with disease defined as oral ulcers on the tongue or buccal mucosa and vesicular rashes on the palms, soles, knees, or buttocks (2). In Singapore, where CVA6 accounted for 24% of HFMD cases, patients had oral lesions and <5 peripheral papules, placing them on a spectrum closer to the herpangina more typically observed in CVA6 infection (8).

The patients we report in this cluster most typically had perioral and perirectal papules in addition to vesicles on the dorsum of their hands. Two reports of CVA6-associated HFMD outbreaks describe cases that more closely resemble patients in the Boston outbreak. In a series from Finland in 2008, representative patients had both perioral lesions and vesicles on the dorsum of their hands (6). In a large series of patients with

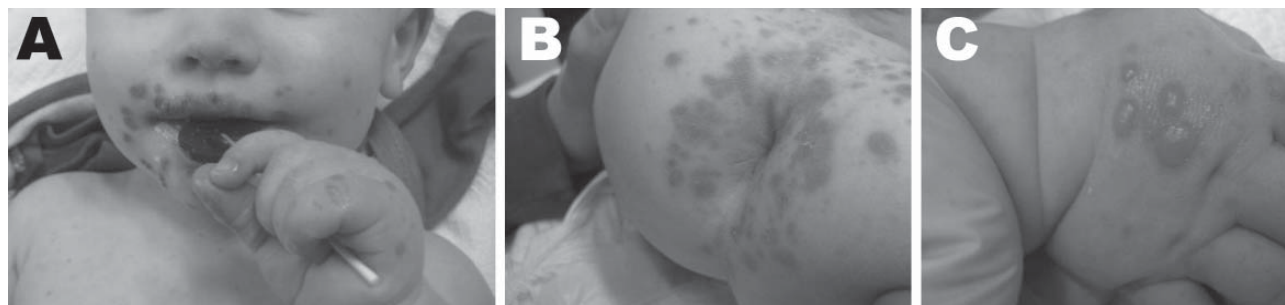


Figure. Manifestations of hand, foot, and mouth disease in patients, Boston, Massachusetts, USA, 2012. Discrete superficial crusted erosions and vesicles symmetrically distributed in the perioral region (A), in the perianal region (B), and on the dorsum of the hands (C). A color version of this figure is available online (wwwnc.cdc.gov/EID/article/18/10/12-0813-F1.htm).

HFMD in Taiwan in 2010, patients with CVA6 had perioral lesions in addition to an enanthem (3).

Outbreaks of CVA6-associated HFMD in Finland, Taiwan, and Japan were associated with onychomadesis, with the loss of nails occurring 1–2 months after initial symptoms (3,4,6). The association between more typical HFMD and onychomadesis has additionally been described in the United States and Europe but without a link to specific serotype or with a small percentage of CVA6-associated cases (9). Cases from the Boston epidemic may fit into an emerging clinical phenotype of CVA6, and it will be interesting to see whether nail loss develops in those patients.

Given the numerous CVA6 outbreaks in multiple countries in 2008 and a US population that may be relatively naïve to this serotype, CVA6 is likely to spread throughout North America. Clinicians should be aware that, although standard precautions are routinely recommended for managing enteroviral infections in health care settings, contact precautions are indicated for children in diapers to control institutional outbreaks (10). In addition, the presence of perioral lesions and peripheral vesicles on the dorsum rather than palmar/plantar surface of the hands and feet represents a unique phenotype of HFMD that could be confused with herpes simplex or varicella-zoster virus infections.

Because of the atypical presentation of CVA6-associated HFMD, clinical vigilance is needed to recognize emerging regional outbreaks. More detailed epidemiologic and genetic analyses will be required to characterize the role of CVA6 in US outbreaks of HFMD.

Acknowledgments

We thank Richard Rossi and Renee Roy for clinical sample preparation and processing and Kenneth McIntosh for critical review of this manuscript.

A.A.A. is supported by National Institutes of Health grant no. 5 K08 AI093676-02.

**Kelly Flett,¹ Ilan Youngster,¹
Jennifer Huang,
Alexander McAdam,
Thomas J. Sandora,
Marcus Rennick,
Sandra Smole,
Shannon L. Rogers,
W. Allan Nix, M. Steven Oberste,
Stephen Gellis, and Asim A. Ahmed**

Author affiliations: Children's Hospital Boston, Boston, Massachusetts, USA (K. Flett, I. Youngster, J. Huang, A. McAdam, T.J. Sandora, S. Gellis, A.A. Ahmed); Boston Public Health Commission, Boston (M. Rennick); Massachusetts Department of Public Health, Jamaica Plain, Massachusetts, USA (S. Smole); and Centers for Disease Control and Prevention, Atlanta, Georgia, USA (S.L. Rogers, W.A. Nix, M.S. Oberste)

DOI: <http://dx.doi.org/10.3201/eid1810.120813>

References

1. Nix WA, Oberste MS, Pallansch MA. Sensitive, seminested PCR amplification of VP1 sequences for direct identification of all enterovirus serotypes from original clinical specimens. *J Clin Microbiol.* 2006;44:2698–704. <http://dx.doi.org/10.1128/JCM.00542-06>
2. Lo SH, Huang YC, Huang CG, Tsao KC, Li WC, Hsieh YC, et al. Clinical and epidemiologic features of coxsackievirus A6 infection in children in northern Taiwan between 2004 and 2009. *J Microbiol Immunol Infect.* 2011;44:252–7. <http://dx.doi.org/10.1016/j.jmii.2011.01.031>
3. Wei SH, Huang YP, Liu MC, Tsou TP, Lin HC, Lin TL, et al. An outbreak of coxsackievirus A6 hand, foot, and mouth disease associated with onychomadesis in Taiwan, 2010. *BMC Infect Dis.* 2011;11:346. <http://dx.doi.org/10.1186/1471-2334-11-346>
4. Fujimoto T, Iizuka S, Enomoto M, Abe K, Yamashita K, Hanaoka N, et al. Hand, foot, and mouth disease caused by coxsackievirus A6, Japan, 2011. *Emerg Infect Dis.* 2012;18:337–9. <http://dx.doi.org/10.3201/eid1802.111147>
5. Blomqvist S, Klemola P, Kajjalainen S, Paananen A, Simonen ML, Vuorinen T, et al. Co-circulation of coxsackieviruses A6 and A10 in hand, foot and mouth disease outbreak in Finland. *J Clin Virol.* 2010;48:49–54. <http://dx.doi.org/10.1016/j.jcv.2010.02.002>
6. Osterback R, Vuorinen T, Linna M, Susi P, Hyypia T, Waris M. Coxsackievirus A6 and hand, foot, and mouth disease, Finland. *Emerg Infect Dis.* 2009;15:1485–8. <http://dx.doi.org/10.3201/eid1509.090438>

¹These authors contributed equally to this article.

7. Centers for Disease Control and Prevention. Notes from the field: severe hand, foot, and mouth disease associated with coxsackievirus A6—Alabama, Connecticut, California, and Nevada, November 2011–February 2012. *MMWR Morb Mortal Wkly Rep.* 2012;61:213–4.
8. Wu Y, Yeo A, Phoon MC, Tan EL, Poh CL, Quak SH, et al. The largest outbreak of hand, foot and mouth disease in Singapore in 2008: the role of enterovirus 71 and coxsackievirus A strains. *Int J Infect Dis.* 2010;14:e1076–81. <http://dx.doi.org/10.1016/j.ijid.2010.07.006>
9. Bracho MA, Gonzalez-Candelas F, Valero A, Cordoba J, Salazar A. Enterovirus coinfections and onychomadesis after hand, foot, and mouth disease, Spain, 2008. *Emerg Infect Dis.* 2011;17:2223–31. <http://dx.doi.org/10.3201/eid1712.110395>
10. Siegel JD, Rhinehart E, Jackson M, Chiarello L. 2007 Guideline for isolation precautions: preventing transmission of infectious agents in health care settings. *Am J Infect Control.* 2007;35(Suppl 2):S65–164. <http://dx.doi.org/10.1016/j.ajic.2007.10.007>

Address for correspondence: Asim A. Ahmed, Children's Hospital Boston—Infectious Diseases, 300 Longwood Ave, Boston, MA 02115, USA; email: asim.ahmed@childrens.harvard.edu

Duffy Phenotype and *Plasmodium vivax* infections in Humans and Apes, Africa

To the Editor: Benign tertian malaria, caused by *Plasmodium vivax*, has long been considered absent, or at least extremely rare, in western and central Africa. In these regions, 95%–99% of humans are of the Duffy negative phenotype, a condition that is thought to confer complete protection against the parasite during the blood stages of its life cycle (1,2). Sporadic reports throughout the latter half of the 20th century, however, have hinted at

the presence of the parasite in these regions, the most convincing of which were the steady and consistent numbers of non-African travelers who returned to their countries of origin infected with malarial parasites that were subsequently identified as *P. vivax* (2).

More recently, evidence has emerged regarding the transmission of *P. vivax* in regions of Africa where the local human population is predominantly Duffy negative (3–6). In 4 (3.5%) of 155 patients from western Kenya (6), 7 (0.8%) of 898 persons from Angola (4), and 8 (8.2%) of 97 persons from Equatorial Guinea (4), *P. vivax* parasites were detected in the blood of apparently Duffy-negative persons, suggesting that the parasite might not be as absolutely dependent on the Duffy receptor for erythrocyte invasion as previously thought. These findings are supported by a report from Madagascar (where the human population is composed of a mixture of Duffy-positive and Duffy-negative persons), in which 42 (8.8%) of 476 Duffy-negative persons who had symptoms of malaria were reported to be positive for *P. vivax* by both microscopy and PCR (7). The prevalence of *P. vivax* in Duffy-negative persons was significantly lower than its prevalence in Duffy-positive persons residing in the same area, suggesting that Duffy negativity is a barrier to the parasite to some degree. Given the extremely high rates of malaria transmission in western and central Africa, a *P. vivax* parasite that could efficiently invade Duffy-negative erythrocytes would, presumably, become highly prevalent very rapidly.

With the exception of the cases reported from Angola and Kenya, which lie outside the area where the proportion of the population with Duffy negativity is highest, the reports of the transmission of *P. vivax* within predominantly Duffy-negative populations all come from regions inhabited by chimpanzees and

gorillas (i.e., Democratic Republic of the Congo [3], Uganda [4], and Equatorial Guinea [5]). During our seroepidemiologic study from the Democratic Republic of the Congo, in which *P. vivax* sporozoite-specific antibodies were detected in ≈10% of the population, we found that women were significantly more likely than men to have been exposed to *P. vivax* sporozoites (3). Women in this region typically spend more time than men near the forest fringe, where they work in crop fields. This forest is within the known habitat range of the chimpanzee *Pan troglodytes* and the gorilla, *Gorilla gorilla gorilla*, both of which have been reported to be natural hosts of the malaria parasite *P. schwezi*, which is a *P. vivax*-like or *P. ovale*-like parasite that might also be unable to invade the erythrocytes of persons who are Duffy negative (8). These animals have recently been shown to be infected occasionally with parasites that have mitochondrial genomes closely resembling those of *P. vivax* (9,10).

We have argued that, given the high malaria transmission rates in sub-Saharan Africa, it is plausible that the 1%–5% of the human population who are Duffy positive might maintain the transmission of the parasite (2). The discovery of *P. vivax* parasites (or *P. vivax*-like parasites) in the blood of African great apes leads to a question: could nonhuman primates in Africa be acting as Duffy-positive reservoirs of *P. vivax* in regions where the human population is almost entirely unsusceptible? This possibility warrants further investigation. Given the increasing rarity of the great apes, however, their capacity to act as zoonotic reservoirs could be limited. It would be informative, in any case, to determine how the regions that *P. vivax*-positive travelers visit during their stay in Africa correspond with the ranges of chimpanzees and gorillas.

If African great apes do, indeed, constitute a zoonotic reservoir of *P. vivax* parasites, what are the