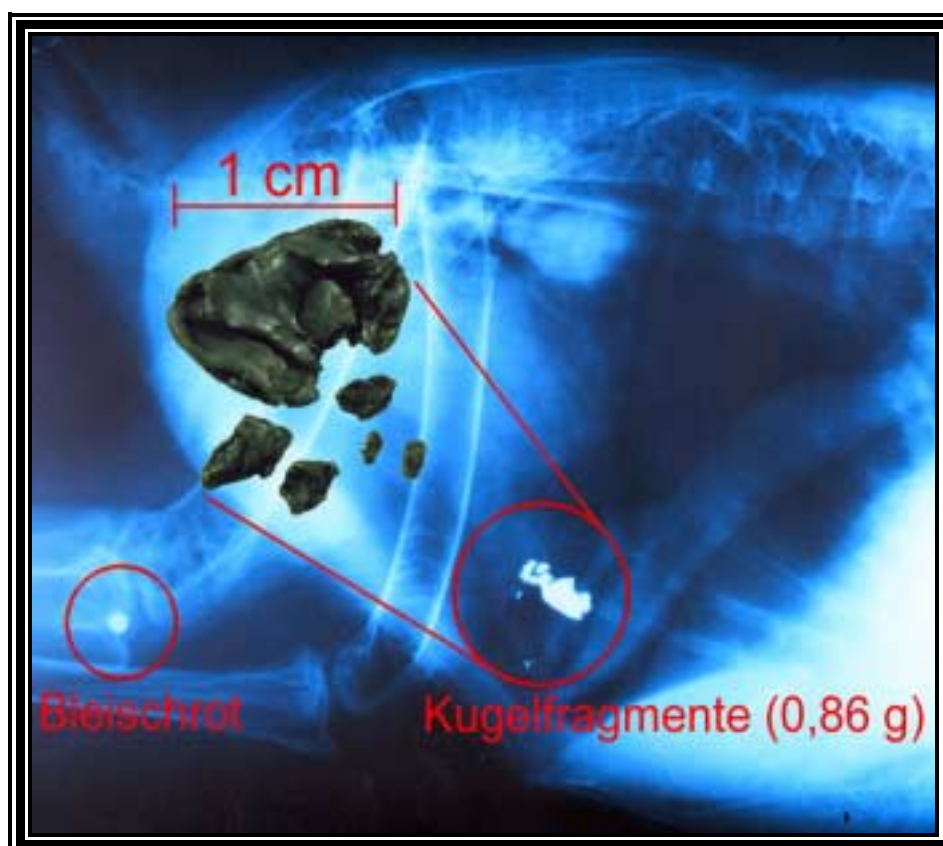


## Kapitel 2

### Heavy metals in soft tissue of white-tailed eagles found dead or moribund in Germany and Austria from 1993 to 2000

Norbert Kenntner, Frieda Tataruch, Oliver Krone

erschienen in „Environmental Toxicology and Chemistry 20 (2001): 1831-1837”



Röntgenbild eines Seeadlers mit Geschossfragmenten (Inlet) im Magen

(Röntgenbild: Kerstin Müller, Foto d. Fragmente: Norbert Kenntner)

## Introduction

The white-tailed eagle (*Haliaeetus albicilla*) is a top predator in the northern Palearctic aquatic food web. The distribution of this species is closely associated with water habitats, in which white-tailed eagles feed mainly on fish and waterfowl.

A strong decline in the European population from the mid-1950s to the 1970s, was mainly associated with the introduction of chlorinated hydrocarbons, in particular DDT and polychlorinated biphenyls. After the ban of these substances, the population has been steadily increasing in recent years in northern and central Europe (HELANDER & MIZERA 1997). This species breeds in Germany mainly in the freshwater rich region of northeastern Germany and along the Baltic coast. The Austrian breeding population has been extinct since 1945-1946. Wintering birds stay mainly in eastern Austria. A breeding attempt was unsuccessful in 1999.

Although numerous investigations have been conducted on heavy metal concentrations in the tissues of North American bald eagles (*Haliaeetus leucocephalus*), very little information is available for the white-tailed eagle from central Europe and elsewhere. This study reports the importance of the toxic heavy metals lead (Pb), mercury (Hg) and cadmium (Cd), on the breeding and wintering population of white-tailed eagles in Germany and Austria, with special emphasize on the occurrence of lead poisoning.

## Materials and Methods

We examined livers and kidneys of 61 white-tailed eagles. Most birds were found dead, sick, or injured in the field between March 1993 and February 2000 in the German regions of Brandenburg, Mecklenburg-Vorpommern, Saxony, and Schleswig-Holstein (Table 1). These samples were sent to the Institute for Zoo Biology and Wildlife Research in Berlin, Germany, for examination. In some cases, bird cores or organs of specimens were collected from taxidermists. Liver and kidney from the carcasses of five white-tailed eagles wintering in the region around Vienna,

Austria, were collected. Of 57 immature and adult white-tailed eagles, 48 birds were found dead, the others were never kept in captivity for longer than 5 d.

**Table 1:** Origin (Germany and Austria), sex and age of 57 white-tailed eagles (*Haliaeetus albicilla*). We define immature birds (<5 years) and adult birds (>5years).

	Brandenburg	Lower Saxony	Mecklenburg-Vorpommern	Saxony	Schleswig-Holstein	Austria	Total
<b>Sex</b>							
Female	9	0	13	3	1	3	29
Male	13	1	6	0	2	2	24
Unknown	2	0	0	0	2	0	4
Total	24	1	19	3	5	5	57
<b>Age</b>							
Immature	10	0	7	1	3	1	22
Adult	13	0	12	2	2	3	32
Unknown	1	1	0	0	0	1	3

The organs of three birds having been kept in captivity for different numbers of days (15, 21 and 65 d) and of one nestling were also analyzed, but the results are presented separately. Two of these birds were euthanized and two died during captivity.

We determined the age by plumage and bill characteristics (FISCHER 1984), and also sexed the bird during necropsy. Some birds were banded, and therefore, detailed background information was available. Body condition was categorized by body mass, breast muscle shape, and measurements of the subcutaneous, coronary, and abdominal cavity fat tissue. Five categories were used and the characteristics were ranked from very poor to very good. From 50 birds categorized for body condition, 21 were determined as very good, 15 as good, 6 as medium, 3 as poor, and only 5 white-tailed eagles were diagnosed as very poor. Macroscopic pathological and macro- and microscopic parasitological findings were recorded.

Most carcasses were x-rayed for embedded lead and lead fragments in the intestinal tract. Separated soft tissues were stored in polyethylene bags at  $-20^{\circ}\text{C}$  until analysis.

Sample preparation and measurements of residue levels were performed in the Research Institute of Wildlife Ecology at the University of Veterinary Medicine Vienna. About 1 to 2 g of tissue was weighed to the nearest 0.1 mg and digested with 32.5% nitric acid (Riedel-de Haën, Seelze, Germany) in long-necked digestion tubes for 2 hours at  $112^{\circ}\text{C}$ . After cooling, mineralized samples were filtered through ash-free filter paper washed with nitric acid and deionized  $\text{H}_2\text{O}$ , and filled up to the defined volume with deionized  $\text{H}_2\text{O}$ .

Measurements for cadmium and lead were performed with a Perkin-Elmer 4100 ZL Zeeman atomic absorption spectrometer (Norwalk, CT, USA) equipped with a graphite-furnace unit, with autosampler AS-71 and argon as the purge gas. Total mercury levels were determined with a Perkin-Elmer 5000 atomic absorption spectrometer with MHS-1 mercury-hydride-system (Norwalk, CT, USA) using a cold-vapor technique.

### *Histopathology*

Tissue samples were fixed in 10 % neutral buffered formalin, embedded in paraffin and sectioned at  $4\ \mu\text{m}$ . The sections were stained with haematoxylin and eosin, periodic acid-Schiff, toluidine blue for hemosiderin, and Ziehl-Neelsen acid stain for the identification of intranuclear inclusion bodies (BANCROFT & STEVENS 1996).

### *Statistical analysis*

All measurements were highly skewed to the right. In consideration of this nonnormal distribution we used exclusively nonparametric statistics. Significance was determined at the  $\alpha = 0.05$  level. All data are given in milligram per kilogram, or parts per million (ppm), on a wet-weight basis. For comparison with results presented for dry weight we used the factor 3.5 for liver tissue and 4 for kidney tissue (SCANLON 1982).

## Results

We report the median, geometric mean, and arithmetic mean so that comparison with other published data is possible. Results for all analyzed elements are given in Table 2 and Figure 1. Heavy metals in organs of four white-tailed eagles excluded from the main sample are presented in Table 3.

**Table 2:** Residues of heavy metals in liver and kidney tissue of 57 white-tailed eagles (*Haliaeetus albicilla*) from Germany and Austria. All values are given in ppm on a wet-weight basis.

	Lead		Mercury		Cadmium		
	Liver	Kidney	Liver	Kidney	Liver	Kidney	
Median	0.183	0.410	0.357	0.855	0.015	0.132	
Geom. Mean	0.619	0.680	0.375	1.055	0.019	0.119	
Mean	7.033	2.926	0.577	2.942	0.039	0.161	
Std. Dev.	14.085	4.476	0.632	6.121	0.106	0.126	
Range	Min	0.014	0.011	0.013	0.078	0.004	0.011
	Max	61.974	17.133	3.553	35.949	0.663	0.665

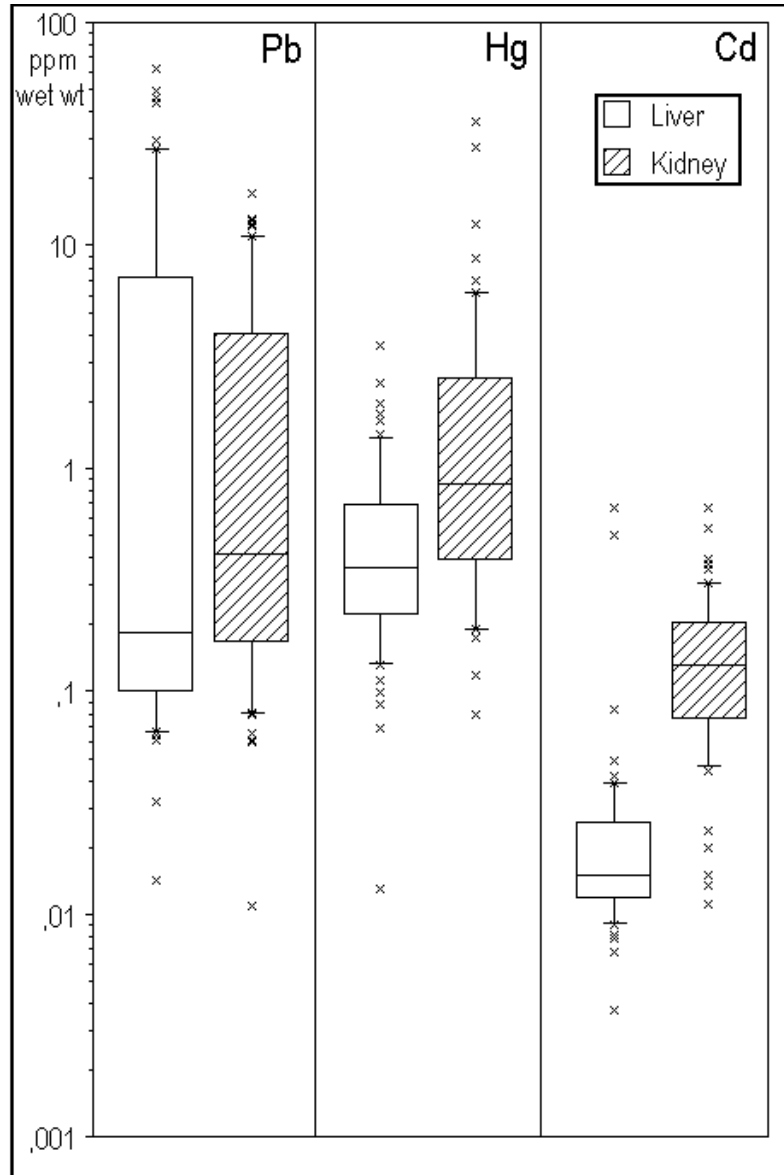
**Table 3:** Heavy metals in organs of three immature and adult white-tailed eagles held in captivity for longer than 5 d and liver values of one nestling.

Age	Sex	Captivity (d)	Lead		Mercury		Cadmium	
			Liver	Kidney	Liver	Kidney	Liver	Kidney
Adult	Female	15	0.326	0.454	0.251	0.532	0.016	0.156
Immature	Female	21	5.163	2.188	0.195	0.139	0.007	0.026
Adult	Female	65	0.293	0.079	0.177	0.139	0.013	0.271
Nestling	Male	3	0.106	NA <sup>a</sup>	0.057	NA	0.01	NA

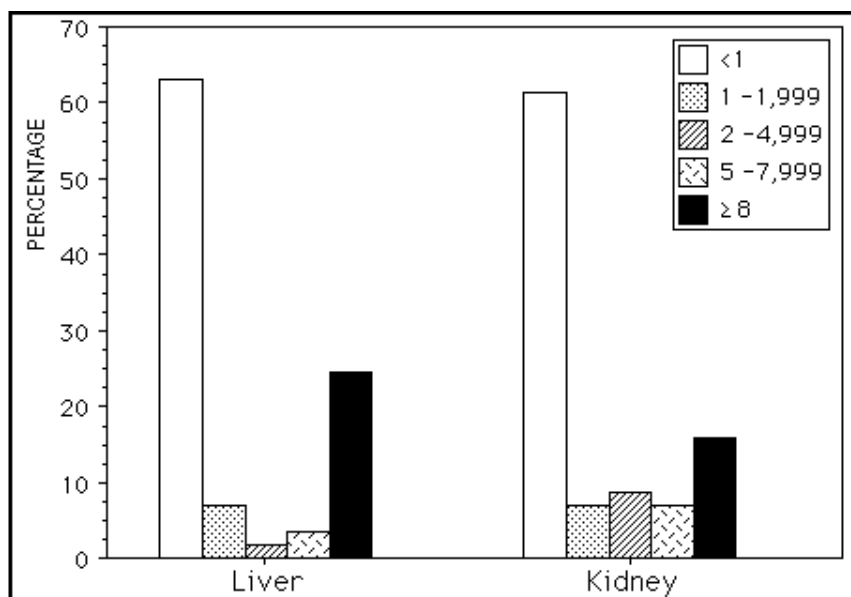
<sup>a</sup>NA = not analyzed

The highest heavy metal values in liver were recorded for lead. Lead also had the widest range of concentrations in liver. In consideration of the wide range of measurements for lead, residues in both organs were reported according to thresholds levels recommended for lead exposure in birds of prey by FRANSON (1996) in Figure 2. The geographical distribution and the percentage of white-tailed eagles

with lead residues in liver tissue higher than 5 ppm are shown in Figure 3. The highest values for mercury were found in kidney tissue. All measurements for cadmium in livers and kidneys were below 1 ppm (Table 2).



**Fig. 1:** Concentrations (ppm wet wt) for lead (Pb), mercury (Hg), and cadmium (Cd) in liver and kidney tissue of white-tailed eagles. Box plots illustrates the 10, 25, 50 (median), 75, and 90 percent percentiles and the outliers.



**Fig. 2:** Percentages of lead residues in organs of 57 white-tailed eagles categorized in thresholds for lead exposure (ppm wet wt).

With the exception of three birds, all specimens had kidney:liver ratios for cadmium concentrations  $> 1$  (Table 4). Lead and mercury did not show such a typical distribution at low levels, but if the lead concentrations in livers were greater than 4 ppm, residues in livers were higher than in kidneys in all cases. However, mercury levels in kidneys exceeded those in livers, with only one exception, if the liver values were above 1 ppm.

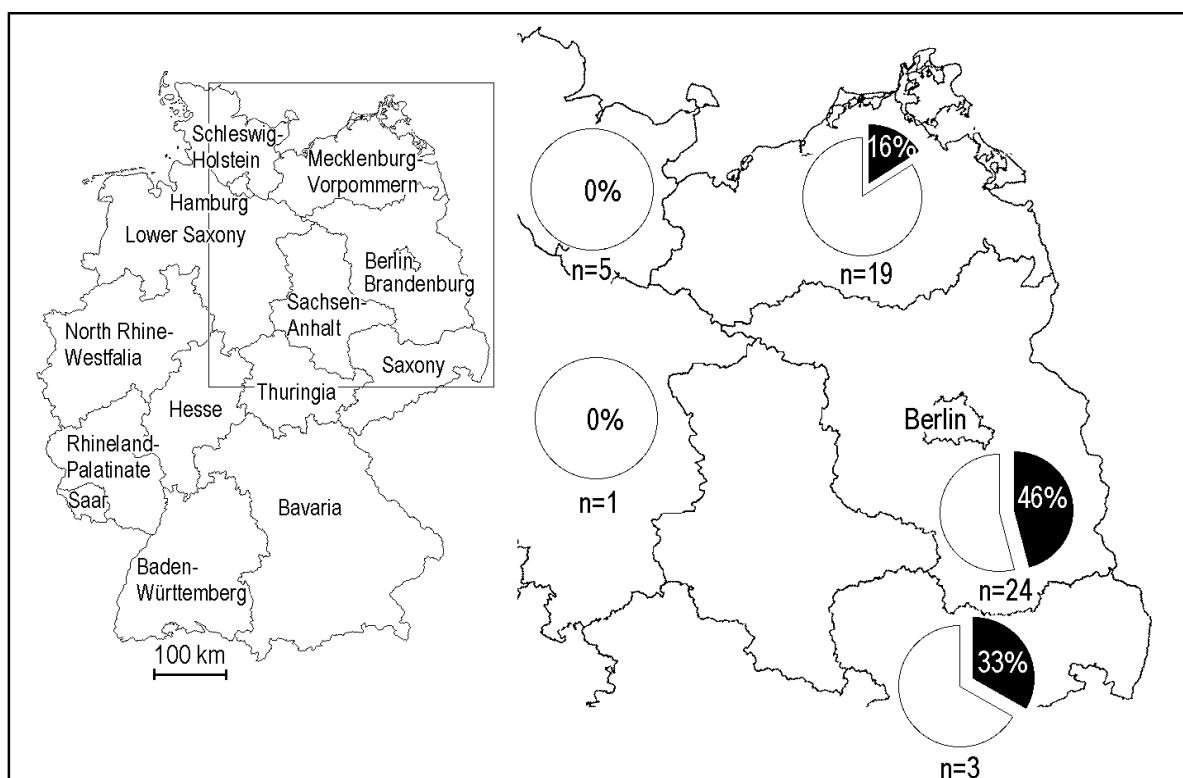
**Table 4:** Kidney:liver ratios for lead (Pb), mercury (Hg), and cadmium (Cd) from 57 white-tailed eagles found in Germany and Austria.

		Kidney:Liver ratio		
		Pb	Hg	Cd
Median		1.124	2.463	7.841
Geom. Mean		1.098	2.810	6.348
Mean		1.651	6.505	8.243
SD <sup>a</sup>		2.293	12.151	4.690
Range	Min	0.161	0.406	0.095
	Max	17.234	67.969	21.813

<sup>a</sup>SD

Wilcoxon signed-rank test revealed highly significant differences between liver and kidney for mercury and cadmium ( $p < 0.0001$ ), but not for lead ( $p = 0.458$ ).

Highly significant correlations existed for all elements between the two organs (Pb:  $r_s = 0.939$ ,  $p < 0.0001$ ; Hg:  $r_s = 0.596$ ,  $p < 0.0001$ ; Cd:  $r_s = 0.555$ ,  $p < 0.0001$ ). No influence of sex could be shown (Kolomogorov-Smirnov test) and there was no statistical correlation between the heavy metal burden and the five categories given for body condition during dissection in 50 white-tailed eagles (Kruskall-Wallis test). Differences for cadmium in kidney tissue (Kolomogorov-Smirnov test:  $p = 0.0049$ ) were calculated for the two age groups, but not for any other analyzed element or tissue type.



**Fig. 3:** Geographical distribution of white-tailed eagles from Germany with lead residues in liver tissue > 5ppm wet weight.

### *Pathological anatomy*

Pathological organ alterations were found in 14 birds with more than 5 ppm lead (wet wt) in liver tissue: 8 birds had swollen liver margins and enlarged gall bladder, and in 12 birds concentrated bile consisting of dark green, clotted and highly viscous material obstructed the bile ducts. Most birds had an empty stomach.



---

## *Histopathology*

Ten birds with high concentrations of tissue lead were examined histopathologically. Only one eagle, whose tissue samples were taken immediately after death was suitable of histopathological interpretations, whereas the others were decomposed. The following alterations were found.

The heart had small necrotic foci in the myocardium, without evidence of inflammatory cell reactivity. The liver had dark brownish granules in the Kupffer's cells with hemosiderinic nature (toluidine blue staining). Diffuse fatty vacuolization was found in many hepatocytes. The kidneys had degeneration and swelling with evidence of hydropic change of lining epithelium of cortical tubules. In some tubules necrotic cells with pyknotic nuclei sloughed into the tubular lumen with a cellular or coarsely granular appearance. Several acid-fast intranuclear inclusion bodies were present in cells of the tubules. In the brain, cerebellar Purkinje cells were apparently reduced in number, leaving behind empty spaces.

## **Discussion**

### *Lead*

Given the thresholds for lead exposure for birds of prey suggested by FRANSON (1996) we categorized the results of our sample in Figure 2, and added a further threshold ( $\geq 8$  ppm wet wt) used by CRAIG et al. (1990) and WAYLAND and BOLLINGER (1999). Considering these thresholds, 40 birds (70%) of the sample had lead residues in liver tissue  $< 2$  ppm wet weight, within the range of background levels. Sixteen birds (28%) in our study had liver values in the range from 5 to 62 ppm wet weight, which suggests that they may have suffered from acute lead exposure and lead poisoning (FRANSON 1996). Thirteen (23%) of these 16 birds also had high lead concentrations in their kidneys (5 -17 ppm wet wt). The three remaining kidney values were 4.602, 3.524, and 1.908 ppm. These high lead residues in both organs include also one out of the five analyzed white-tailed eagles found moribund in Austria. The geographical distribution of white-tailed eagles from Germany considered to indicate acute lead exposure and lead poisoning is shown in Figure 3.

In one further bird we analyzed liver (4.323 ppm) and kidney (2.564 ppm) residues, indicating subclinical to toxic physiological effects (FRANSON 1996). In all of these 17 birds above background levels, liver lead values exceeded the corresponding kidney values. Two additional eagles had kidney values >3 ppm expected for strong physiological effects, but liver values below the upper threshold for background levels.

From the data presented separately in Table 3, one female bird in the first year, held in captivity for 21 d, had liver and kidney values of 5.163 and 2.188 ppm, and died of circulatory failure caused by kachexia. These organ residues indicate a previous lead exposure. The other two caged white-tailed eagles and the nestling showed only background contamination.

Two specimens had x-ray-dense metallic particles in their stomachs. These fragments were analyzed by the Institute of Geochemistry in Vienna, Austria, using electron microprobe analyses to investigate the metal compounds. Evidence was found that the metal was lead, presumably fragments from lead ammunition. Both birds were in good body condition; however, necropsy results indicated greenish intestine contents and pathologically enlarged liver and gall bladder, which are characteristics of lead intoxications (LOCKE & THOMAS 1996). One of these birds died in spite of veterinary treatment for lead poisoning within 2 d. Histopathological findings (see results) support the toxicological and pathological results for lead intoxication. The macroscopic and microscopic pathological findings are identical with those described in the literature (LOCKE & THOMAS 1996). In addition to the formerly described histopathological alterations, degenerated Purkinje cells were diagnosed in the cerebellum. In this white-tailed eagle, lead residues of 46.257 ppm were found in liver, and 12.985 ppm were found in kidney tissue.

Two immature birds had lead shot in their muscle tissue, but organ lead levels were in the range of background contamination. Although not all birds were x-rayed, interference from lead shot particles in analyzed organs can be precluded because elevated values in liver tissue were accompanied by correspondingly high kidney values.

Lead poisoning in white-tailed eagles was reported in two specimens from Poland (FALANDYSZ et al. 1988), one from Germany (Brandenburg) with the extraordinarily high residues of 334 ppm wet weight in liver and 115 ppm wet weight

in kidney tissue (LANGGEMACH 1997), and one eagle found on the Japanese island of Hokkaido (KIM et al. 1999).

The occurrence of lead poisoning in bald eagles in the USA and Canada has been much more exhaustively investigated. KAISER et al. (1980) examined 168 bald eagles found in the United States between 1975 and 1977, and determined that 9 birds (5.4%) had died from lead poisoning. In a continuing study between 1978 and 1981, 17 of 293 examined bald eagles (5.8%) were suspected to have died of lead poisoning, with liver residues > 10ppm wet weight (REICHEL et al. 1984), a first threshold recommended by PATTEE et al. (1981). CRAIG et al. (1990) diagnosed liver values from six bald eagles, of which five had residue levels exceeding 8 ppm wet weight, the threshold recommended for acute lead exposure for this species.

ELLIOTT et al. (1992) estimated that of 65 bald eagles found dead between 1988 and 1991 in British Columbia, Canada, 14% had lead poisoning and a further 23% subclinical lead exposure, with the data being based on renal lead residues and the ratio of activated to nonactivated  $\delta$ -aminolevulinic acid dehydratase in blood samples. A similar occurrence of 12% of birds with toxic lead levels but only 2% with elevated lead levels was diagnosed in 83 bald eagles found in the Canadian prairie provinces (WAYLAND & BOLLINGER 1999). Both Canadian studies used a value of 20 ppm dry wt (about 5 ppm wet wt) in kidney tissue for a lethal threshold. WAYLAND and BOLLINGER (1999) and an additional Canadian study (WAYAND et al. 1999) discussed a concentration of 30 ppm dry weight (8.5 ppm wet wt) in hepatic tissue as a potentially lethal level and concentrations of > 6 ppm dry weight (1.71 ppm wet wt) and > 8 ppm dry weight (2 ppm wet wt) for elevated lead exposure in hepatic tissue and renal tissue, respectively. In this study 13 of 57 (23%) birds exceeded this calculated dry-weight threshold for a lethal lead intoxication in liver tissue and 12 of 57 (21%) had higher values in both organs.

However, numerous studies suggested that these high lead concentrations in organs of predatory and scavenging birds, such as white-tailed eagles, result exclusively from ingestion of metallic lead embedded in shot waterfowl and game, found as carcasses and gut piles or captured as handicapped prey (PATTEE et al 1981; Pattee & Hennes 1983; KRAMER & REDIG 1997). Like golden eagles (*Aquila chrysaetos*) and ravens (*Corvus corax*), white-tailed eagles are also known to search for prey, carcasses or gut piles after human game hunting (FISCHER 1984; BEZZEL & FÜNFSTÜCK 1995).

During the summer season white-tailed eagles feed mainly on fish and waterfowl; however, waterfowl is the main food supply in winter, together with mammals and carcasses (FISCHER 1984). Because of its strong beak, this species is also able to open carcasses of game and presumably starts these openings on wounds if present. Gunshot wounds represent a potential source of lead fragments through split bullets or lead shot.

DUKE et al. (1974) analyzed pH values in gastric juice of different raptor species. They report the lowest value, meaning the highest activity of acids, for the bald eagle. Assuming very similar relations for the white-tailed eagle, this results in a better solubility of metallic lead, for example, lead shot, ingested by feeding, favoring a higher intestinal resorption.

All birds in our investigation with liver lead residues  $> 2$  ppm, indicating acute lead exposure, were found between December and March, including the main hunting season during October to January in Germany and Austria. However, we can't exclude fishing weights as potential source of elevated lead exposure in white-tailed eagles, as described for birds such as common loons (*Gavia immer*) or mute swans (*Cygnus olor*) (SCHEUHAMMER & NORRIS 1996). Nevertheless, fish are in deep water during the winter season or inaccessible in frozen lakes and therefore of only minor importance as a winter food supply for white-tailed eagles.

### *Mercury*

In aquatic environments mercury compounds are transformed through microorganisms to methylmercury. Because of its lipophilicity, methylmercury bioaccumulates in the aquatic food web. Therefore, white-tailed eagles and other top predators of the aquatic food web are exposed to higher mercury levels compared to predators involved in the terrestrial food web (WREN et al. 1997). Terrestrial sources for mercury exposure were mainly mercury compounds used as seed dressing in agriculture. However, these pesticides were banned in Germany in 1982, but used in the former German Democratic Republic up to 1990 and in Austria until 1992.

Twenty-six birds had mercury residues above 1 ppm in liver, kidneys, or both, but only one had a kidney:liver ratio  $< 1$ . At lower contamination levels ( $< 1$  ppm), such strong differences were not found between liver and kidney levels. Therefore, by splitting the sample in two groups including values  $> 1$  ppm or  $< 1$  ppm, the

difference in significance between both organs decrease from  $p < 0.0001$  to  $p = 0.0033$  (Wilcoxon signed-rank test). Kidney values are known to represent mainly inorganic mercury and kidney:liver ratios  $> 2$  prove such exposure (SCHEUHAMMER 1987).

Similar to that reported here, 84% of 24 white-tailed eagles from the northern part of the former German Democratic Republic exhibited higher mercury residues in kidneys than in liver tissue (OEHME 1981), as did all cases of four and seven analyzed white-tailed eagles from Finland and Poland, respectively (HENRIKSSON et al. 1966; FALANDYSZ 1986; FALANDYSZ et al. 1988; AMAROWICZ et al. 1989). Mercury intoxication was diagnosed in 7 of 35 birds of the German survey (OEHME 1981).

A Norwegian survey of 24 white-tailed eagles revealed an increasing kidney:liver ratio due to higher kidney contaminations. These authors calculated a median of 3.3 ppm wet weight in hepatic tissue and 3.5 ppm wet wt in renal tissue (NORHEIM & FRØSLIE 1978). Further Norwegian investigations presented data for 28 white-tailed eagles with medians of 2.4 ppm wet weight and 3.5 ppm wet weight in liver and kidney tissue (HOLT et al. 1979) and a similar median value of 2.4 ppm wet wt for 75 analyzed liver samples of white-tailed eagles (FRØSLIE ET AL. 1986). Mercury concentrations of European surveys on white-tailed eagles are summarized in Table 5. Considering different analytical techniques in these surveys, caution must be taken when comparing with the results of this study, especially in investigations reported in the 1960s.

In summary, the above European studies showed higher median, mean and maximum values for mercury than we found in our study for birds from the 1990s. Therefore, we suggest a decline of the environmental concentrations of mercury, perhaps due to the ban of organomercury seed dressings.

However, in our study two adult white-tailed eagles with kidney residues of 27.776 and 35.949 ppm are in a critical range for a suspected mercury intoxication (THOMPSON 1996). However, both birds had liver values below 1 ppm making interpretation difficult. All other values are below 10 ppm and in a range presumably not affecting top predators of the aquatic food web.

**Table 5:** Mercury concentrations in liver and kidney of European white-tailed eagles. Values are given in ppm on a wet-weight basis; sample size is given in parentheses<sup>a</sup>.

Country	Period	Liver		Kidney		References
		Range	Median	Range	Median	
Finland	1965-1966	4.6-27.1 (6)		48.6-123.1 (4)		HENRIKSSON et al. 1966
Germany	1969	48 (1)		27 (1)		KOEMAN et al. 1972
Norway	1965-1976	<0.1-16 (25)	2.4	<0.1-55 (27)	3.5	HOLT et al. 1979
Norway	1972-1977	0.3-16 (24)	3.3	0.3-55 (24)	3.5	NORHEIM & FRØSLIE 1978
Germany	1967-2/1976	ND-7.5 (25)	0.8	ND-14.3 (23)	5.8	OEHME 1981
	12/1976-1978	4.8-133.5 (10)	90.8	6.1-306 (10)	115.5	
Norway	1965-1983	<0.1-51 (75)	2.4	NA		FRØSLIE et al. 1986
Poland	1982	30 (1)		NA		FALANDYSZ 1984
Poland	1984	0.99 +11 (2)		6+44 (2)		FALANDYSZ 1986
Poland	1986-1987	0.86-33 (4)		2.5-56 (4)		FALANDYSZ et al. 1988
Poland	1987	1.32 (1)		NA		AMAROWICZ et al. 1989
Germany +Austria	1993-2000	0.013-3.553 (57)	0.357	0.078-35.949 (57)	0.855	this study

<sup>a</sup>ND = not detectable; NA = not analyzed

## Cadmium

In spite of the long biological half-life of cadmium and the age-structure of the eagles (Table 1), the analyzed residues were far below accepted critical limits that would be expected to yield physiological effects (FURNESS 1996). Adult birds had significantly higher cadmium residues in kidneys than immature birds, but not in livers. The range of cadmium in liver (0.004 – 0.663 ppm) and kidneys (0.011 – 0.665 ppm) was similar to that found in eight analyzed white-tailed eagles found dead in Poland in the 1980s (FALANDYSZ 1984; FALANDYSZ 1986; FALANDYSZ et al. 1988; AMAROWICZ et al. 1989) and one specimen from Hokkaido (KIM et al. 1999). In these cases, kidney values exceed liver values with kidney:liver ratio of 1.79 to 20.5. The suggestion has been made that cadmium levels in soft tissue of white-tailed eagles represent background levels, as presented already by investigations on birds of prey from Europe (FRANK 1986; GARCIA-FERNANDEZ et al. 1995) and a single study from the state of Lower Saxony in Germany, carried out in the early 1980s (TERNES et al. 1986).

---

## Conclusions

Cadmium residue levels in this study are considered to be harmless in white-tailed eagles. Compared with former studies on the influences of mercury on this species, residues in organs of these top predators in aquatic food webs are decreasing since the ban of organic mercury as seed dressing in agriculture.

Whereas the former studies focused mainly on mercury residues, the influence of lead on white-tailed eagles has been underestimated. According to our results, this element seems to be a major threat for this species. In 28% of birds tested, lead concentrations in livers exceeded the critical level of 5 ppm wet weight. The only possible way to prevent lead intoxication in raptors is to ban lead shot and bullets for hunting and substitute with nontoxic shot. In several European countries lead shot has been banned either for all hunting or only for hunting waterfowl in wetlands. The German Federal Ministry of Food, Agriculture and Forestry and the largest German Hunters Federation started to recommend the use of nonlead shot only for the hunting of waterfowl in wetlands in December 1993 (KUIVENHOVEN et al. 1997). The Agreement on the Conservation of African-Eurasian Migratory Waterbirds developed under the Convention on the Conservation of Migratory Species of Wild Animals, also commonly known as the Bonn Convention, contains an action plan, called management of human activities. This action plan includes the resolution that "parties shall endeavour to phase out the use of lead shot for hunting in wetlands by the year 2000". This agreement has been signed by 53 states and the European Community. But up to July 2000, no effort had been made to ban lead shot in Germany and Austria (KÖSTERS et al. 1995; THOMAS & OWEN 1996; KUIVENHOVEN et al. 1997), with the exception of the province of Schleswig-Holstein in northern Germany, where lead shot for waterfowl hunting in wetlands was banned in October 1999.

However, lead shot is not the only source of elevated lead exposure and lead poisoning in birds of prey. The gizzard of one white-tailed eagle that died of lead poisoning contained lead fragments of various sizes up to a single weight of 0.75 g, presumably representing fragments of a lead bullet. Further studies should investigate lead exposure in the distribution area of the white-tailed eagle and also in other scavenging birds or birds species able to hunt game.

## Acknowledgement

We are grateful to R. Altenkamp, A. Aue, H. Frey, T. Langgemach, K. Müller, R. Schmahl, P. Sömmer, B. Struwe-Juhl, P. Wernicke, W. Mewes, U. Wittstatt, L. Wölfel, WWF Projektgruppe Seeadlerschutz Schleswig-Holstein and all unmentioned persons for their cooperation and supplying of carcasses. We also thank T. Steineck for dissecting the white-tailed eagles found in Austria and H. Weinke for analyzing the lead fragments with micro electronprobe analysis. Further we wish to thank J. Wisser for the histopathological findings and G. Florant for his critical review of the manuscript.

## Abstract

Residues of the potentially toxic metals lead, mercury and cadmium were analyzed in liver and kidney tissue of 61 free-ranging white-tailed eagles (*Haliaeetus albicilla*) found dead or moribund in Germany and Austria between 1993 and 2000. Highest values and the widest range were detected for lead in liver and for mercury in kidney tissue. Lead concentrations considered to induce lethal lead poisoning (> 5 ppm wet wt) were determined in 28% of liver samples. Lead fragments were detected in the gizzards of two specimens, presumably having died from lead intoxication. Histopathological findings in a recently dead white-tailed eagle indicating acute lead exposure comprise degenerative Purkinje cells in the cerebellum and inclusion bodies in renal tubular cells. Mercury residues in organs are decreasing compared to former studies in periods when organomercury compounds were used as seed dressing. All cadmium values were low or are at background levels in white-tailed eagles. The present study clearly identifies lead as a toxic metal poison in white-tailed eagles in Germany and Austria.



## References

- AMAROWICZ R, SZYMKIEWICZ M, GLAZEWSKI R, KORCZAKOWSKA B, MARKIEWICZ K, MELLIN M (1989): Content of chlorinated hydrocarbons, polychlorinated biphenyls and heavy metals in tissue of the white-tailed eagle and lesser spotted eagle. *Przeegląd Zoologiczny* 33: 613-617
- BANCROFT JD & STEVENS AS (1996): *Theory and Practice of Histological Techniques*. Churchill Livingstone, Edinburgh, Scotland
- BEZZEL E & FÜNFSÜCK H-J (1995): Lead poisoning as a threat to golden eagles (*Aquila chrysaetos*) in the northern Alps? *Journal für Ornithologie* 136: 294-296
- CRAIG TH, CONNELLY JW, CRAIG EH, PARKER TL (1990): Lead concentrations in golden and bald eagles. *Wilson Bulletin* 102: 130-133
- DUKE GE, JEGERS AA, LOFF G, EVANSON OA (1974): Gastric digestion in some raptors. *Comparative Biochemistry and Physiology* 50A: 649-656
- ELLIOTT JE, LANGELIER KM, SCHEUHAMMER AM, SINCLAIR PH, WHITEHEAD PE (1992): *Incidence of lead poisoning in bald eagles and lead shot in waterfowl gizzards from British Columbia, 1988-91*. Canadian Wildlife Service, Progress Notes 200, Ottawa, Canada
- FALANDYSZ J (1984): Metals and organochlorines in a female white-tailed eagle from Uznam Island, southwestern Baltic sea. *Environmental Conservation* 11: 262-263
- FALANDYSZ J (1986): Metals and organochlorines in adult and immature males of white-tailed eagles. *Environmental Conservation* 13: 69-70
- FALANDYSZ J, JAKUCZUN B, MIZERA T (1988): Metals and organochlorines in four female white-tailed eagles. *Marine Pollution Bulletin* 19: 521-526
- FISCHER W (1984): *Die Seeadler*, Spektrum Akademischer Verlag, Heidelberg, Germany
- FRANK A (1986): In search of biomonitors for cadmium: Cadmium content of wild Swedish fauna during 1973-1976. *The Science of the Total Environment* 57: 57-65
- FRANSON C (1996): Interpretation of tissue lead residues in birds other than waterfowl. In: BEYER WN, HEINZ GH, REDMON-NORWOOD AW (Hrsg): *Environmental Contaminants in Wildlife—Interpreting Tissue Concentrations*. CRC, Boca-Raton, FL, USA, pp 265-279
- FRØSLIE A, HOLT G, NORHEIM G (1986) Mercury and persistent chlorinated hydrocarbons in owls *Strigiformes* and birds of prey *Falconiformes* collected in Norway during the period 1965-1983. *Environmental Pollution* 11B: 91-108
- FURNESS RE (1996): Cadmium in birds. In: BEYER WN, HEINZ GH, REDMON-NORWOOD AW (Hrsg): *Environmental Contaminants in Wildlife—Interpreting Tissue Concentrations*. CRC, Boca-Raton, FL, USA, pp 389-404
- GARCIA-FERNANDEZ AJ, SANCHEZ-GARCIA JA, JIMENEZ-MONTALBAN P, LUNA A (1995): Lead and cadmium in wild birds in southeastern Spain. *Environmental Toxicology and Chemistry* 14: 2049-2058
- HELANDER B & MIZERA T (1997): White-tailed eagle. In Hagemeyer WJM, Blair MJ (Hrsg): *The EBCC Atlas of European Breeding Birds: Their Distribution and Abundance*. T & AD Poyser, London, UK, pp 136-137
- HENRIKSSON K, KARPPANEN E, HELMINEN M (1966): High residue of mercury in Finnish white-tailed eagles. *Ornis Fennica* 43: 38-45

- HOLT G, FRØSLIE A, NORHEIM G (1979): Mercury, DDE, and PCB in the avian fauna in Norway 1965-1976. *Acta Veterinaria Scandinavica*, Supplementum 70: 1-28
- KAISER TE, REICHEL WL, LOCKE LN, CROMARTIE E, KRYNITSKY AJ, LAMONT TG, MULHERN BM, PROUTY RM, STAFFORD CJ, SWINEFORD DM (1980): Organochlorine pesticide, PCB, PBB residues and necropsy data for bald eagles from 29 states — 1975 -1977. *Pesticides Monitoring Journal* 13: 145-149
- KIM E-Y, GOTO R, IWATA H, MASUDA Y, TANABE S, FUJITA S (1999): Preliminary survey of lead poisoning of Stellar's sea eagle (*Haliaeetus pelagicus*) and white-tailed sea eagle (*Haliaeetus albicilla*) in Hokkaido, Japan. *Environmental Toxicology and Chemistry* 18: 448-451
- KOEMAN JH, HADDENRINGH RG, BIJLEVELD MFIJ (1972): Persistent pollutants in the white-tailed eagle (*Haliaeetus albicilla*) in the Federal Republic of Germany. *Biological Conservation* 4: 373-377
- KÖSTERS J, HILBICH D, STOLLE A, BRUNNER B, GRIMM F (1995): Is the use of lead shot for hunting small game still keeping with the times? *Archivum Veterinarium Polonicum* 35: 269-277
- KRAMER JL & REDIG PT (1997): Sixteen years of lead poisoning in eagles, 1980-95: An epizootologic view. *Journal of Raptor Research* 31: 327-332
- KUIVENHOVEN P, VAN VESSEM J, VAN MAANEN E (1997): *Lead poisoning in waterfowl. International update report 1997*. Wetlands International, Wageningen, The Netherlands
- LANGGEMACH T (1997): Bleibelastung bei Seeadlern. *Brandenburgische Forstnachrichten* 71/72: 17-18
- LOCKE LN & THOMAS NJ (1996): Lead poisoning of waterfowl and raptors. In: Fairbrother A, Locke LN, Hoff GL. (Hrsg): *Noninfectious Diseases of Wildlife*. Iowa State University Press, Ames, IA, USA, pp 108-117
- NORHEIM G & FRØSLIE A (1978): The degree of methylation and organ distribution of mercury in some birds of prey in Norway. *Acta Pharmacologica et Toxicologica* 43: 196-204
- OEHME G (1981): On the level of mercury residues in white-tailed eagles (*Haliaeetus albicilla*) found dead 1967-1978. *Hercynia N F* 18: 353-364
- PATTEE OH, WIEMEYER SN, MULHERN BM, SILEO L, CARPENTER JW (1981): Experimental lead shot poisoning in bald eagles. *Journal of Wildlife Diseases* 45: 806-810
- PATTEE OH & HENNES SK (1983): Bald eagles and waterfowl: The lead shot connection. *Transactions of the North American Wildlife and Natural Resources Conference* 48: 230-237
- REICHEL WL, SCHMELING SK, CROMARTIE E, KAISER TE, KRYNITSKY AJ, LAMONT TG, MULHERN BM, PROUTY RM, STAFFORD CJ, SWINEFORD DM (1984): Pesticide, PCB, and lead residues and necropsy data for bald eagles from 32 states — 1978-81. *Environmental Monitoring and Assessment* 4: 395-403
- SCANLON PF (1982): Wet and dry weight relationship of mallard (*Anas platyrhynchos*) tissues. *Bulletin of Environmental Contamination and Toxicology* 29: 615-617
- SCHEUHAMMER AM (1987): The chronic toxicity of aluminium, cadmium, mercury and lead in birds: A review. *Environmental Pollution* 46: 263-295
- SCHEUHAMMER AM & NORRIS SL (1996): The ecotoxicology of lead shot and fishing weights. *Ecotoxicology* 5: 279-295
- TERNES W, PETERAT B, RÜSSEL-SINN HA (1986): Belastung der Greifvögel in Norddeutschland mit den Schwermetallen Blei, Cadmium und Quecksilber. *Proceedings, V. Tagung über Vogelkrankheiten*, Munich, Germany, 6.-7. März 1986, pp 187-194
- THOMAS VG & OWEN M (1996): Preventing lead toxicosis of European waterfowl by regulatory and non-regulatory means. *Environmental Conservation* 22: 358-364

- THOMPSON DR (1996): Mercury in birds and terrestrial mammals. In: Beyer WN, Heinz GH, Redmon-Norwood AW (Hrsg): *Environmental Contaminants in Wildlife—Interpreting Tissue Concentrations*. CRC, Boca-Raton, FL, USA, pp 341-356
- WAYLAND M & BOLLINGER T (1999): Lead exposure and poisoning in bald eagles and golden eagles in the Canadian prairie provinces. *Environmental Pollution* 104: 341-350
- WAYLAND M, NEUGEBAUER E, BOLLINGER T (1999): Concentrations of lead in liver, kidney, and bone of bald and golden eagles. *Archives of Environmental Contamination and Toxicology* 37: 267-272
- WREN CD, HARRIS S, HARTTRUP N (1995): Ecotoxicology of mercury and cadmium. In: Hoffmann DJ, Rattner BA, Burton GA, Cairns J (Hrsg): *Handbook of Ecotoxicology*. Lewis Publishers, Boca Raton, FL, USA, pp 392-423