

Case Report

Hemophagocytic Lymphohistiocytosis Complicating Dengue and *Plasmodium vivax* Coinfection

Muhammad Khurram, Muhammad Faheem, Muhammad Umar, Asif Yasin, Wajeeda Qayyum, Amna Ashraf, Javeria Zahid Khan, Ali Hasnain Yasir, Yusra Ansari, Muhammad Asad, Iram Khan, Shuja Abbas, Irum Rasheed, Natasha Rasool, and Hamama Tul Bushra Khar

Rawalpindi Medical College, Holy Family Hospital, Rawalpindi 46300, Pakistan

Correspondence should be addressed to Muhammad Khurram; drmkhurram@gmail.com

Received 6 June 2015; Revised 26 July 2015; Accepted 5 August 2015

Academic Editor: Christian Urban

Copyright © 2015 Muhammad Khurram et al. This is an open access article distributed under the Creative Commons Attribution License, which permits unrestricted use, distribution, and reproduction in any medium, provided the original work is properly cited.

Hemophagocytic lymphohistiocytosis (HLH) is a rare disorder. Dysfunction of cytotoxic T and natural killer (NK) cells causes uncontrolled activity of lymphocytes and histiocytes which leads to HLH. Infections, malignancies, and autoimmune disorders are associated with development of HLH. Dengue and *Plasmodium vivax* are rare causes of HLH. We report the first ever case of a young man who developed fatal HLH that complicated Dengue Hemorrhagic Fever (DHF) and *Plasmodium vivax* infection.

1. Introduction

Hemophagocytic lymphohistiocytosis (HLH) is a rare disorder which can be familial or acquired. Acquired HLH complicates a number of viral, bacterial, and parasitic infections. It is also associated with autoimmune disorders and certain malignancies like T cell lymphoma. Familial HLH has autosomal recessive transmission and is seen in infants less than 18 months old. HLH is associated with high mortality [1]. HLH results from dysfunction of cytotoxic T and natural killer (NK) cells that cause uncontrolled lymphocytes and histiocytes activity which is associated with phagocytosis of hematopoietic cells [2].

HLH is characterized by prolonged fever and sepsis-like syndrome. It presents with nonspecific clinical features like fever and hepatosplenomegaly. Laboratory findings include cytopenias, raised serum aminotransferase levels, hypofibrinogenemia, hypertriglyceridemia, hyperferritinemia, and increased lactic dehydrogenase (LDH) levels. Dengue and malaria are important but rare causes of HLH [3, 4]. We report the first ever case of 19-year-old male with HLH diagnosed in settings of both Dengue Hemorrhagic Fever (DHF) and *Plasmodium vivax* (*P. vivax*) malaria infections.

2. Case Report

A 19-year-old, previously healthy, motor mechanic was admitted with 13-day history of high grade fever, headache, retroorbital pain, and myalgias. One day before admission he became restless and irritable. On examination his pulse was 104/minute, temperature 101°F, respiratory rate 24/minute, and blood pressure 110/70 mmHg (pulse pressure 40 mmHg). He was jaundiced. Abdominal examination revealed tender hepatomegaly with liver span of 18 cm. Chest examination was suggestive of right sided mild to moderate pleural effusion. He was noted to be drowsy, disoriented, and confused. His Glasgow Coma Scale (GCS) was 12/15 (E3, M5, and V4). No focal neurological deficit or signs of meningeal irritation were noted. The rest of the clinical examination was unremarkable.

Ultrasonographic examination at admission showed thick walled gall bladder (wall thickness 13 mm), hepatomegaly (17 cm), splenomegaly (13.6 cm), mild to moderate ascites, and mild to moderate pleural effusion. CT scan brain without contrast showed brain edema. Respiratory alkalosis was noted on arterial blood gas (ABG) analysis. ECG was

TABLE 1: Hematological and biochemical parameters.

	Day 1	Day 2	Day 3	Day 4	Day 5	Day 6	Day 7	Day 8
Hemoglobin (g%)	13.4	7.8	9.3	9.4	10.3	12.5	14.0	12.9
Hematocrit (%)	38.9	22.5	26.6	26	29.4	37.3	40.0	39
WBC ($\times 10^3$ /cu mm)	17.2	5.3	6.3	3.1	7.0	8.4	6.2	5.4
Neutrophils (%)	25.9	45.5	53.7	70.3	84.1		79	75
Lymphocytes (%)	70.3	47.5	40	25.3	8.7		17	20
Platelets ($\times 10^3$ /cu mm)	80	62	74	69	78	138	258	229
PT* (seconds prolonged)		7	6	0			8	2
aPTT** (seconds prolonged)		7	37	12			2	2
Fibrinogen (150–350 mg/dL)		160	135					225
ALT*** (<43 IU/L)	1283	684	865	546	486	343	284	291
AST**** (<43 IU/L)	37						64	
ALP***** (<147 IU/L)	1974							
Bilirubin (<1.0 mg/dL)	8.3	5	5.1			3.8		
Albumin (3.5–5 g/dL)	4.4	3.2	3.3			4.6	4.1	
Urea (10–50 mg/dL)	75	52	45	90	39	36	42	
Creatinine (<1.2 mg/dL)	1	0.9	0.4	1.0	0.8	0.8	0.9	
Na ⁺ (135–145 meq/L)	129	137	135	133		135	144	
K ⁺ (3–5 meq/L)	5.6	4.3	4.0	3.2			4.5	
Calcium (8–10 mg/dL)	9.6	7.9	8.6	7.0	7.2	6.8	8.1	9.1
Amylase (30–110 U/L)	175	260	230					
Serum lipase (<50 IU/L)						74.6		
Creatinine kinase (<190 IU/L)		1668	1355					
Serum LDH (225–450 IU/L)	123	535					60	
Troponin T (by ICT)	Negative			Negative				

*PT, prothrombin time; **aPTT, activated partial thromboplastin time; ***ALT, alanine transferase; ****AST, aspartate transferase; *****ALP, alkaline phosphatase.

normal and chest X-ray showed right pleural effusion. Other investigations are shown in Table 1.

Day 1. An initial assessment of DHF complicated by dengue fulminant hepatic failure was made with differential diagnosis of encephalitis, cerebral malaria, sepsis, and multiorgan dysfunction. Injectable artesunate, piperacillin/tazobactam, acyclovir, and dexamethasone (0.4 mg/Kg, 12 hourly) were started. Standard DHF management was commenced. Lactulose and N-acetyl cysteine were also administered per nasogastric tube.

Day 2. Clinical condition remained the same. Investigation showed positive dengue markers (NS1, IgM antibodies, and IgG antibodies performed by SD Dengue Capture ELISA Kit) and positive smear examination for malarial parasite (gametocytes and schizonts of *P. vivax*). Markers for hepatitis A, hepatitis B, hepatitis C, and hepatitis E turned out negative. Ferritin (40000 ng/mL, normal value 12–300 ng/mL) and triglycerides levels (292 mg%, normal value < 140 mg/dL) were elevated. Serum fibrinogen levels were on lower side (Table 1). Diagnosis of HLH in settings of DHF and *P. vivax* coinfection was considered. Dexamethasone was replaced with methyl prednisolone (30 mg/Kg/day for 3 days). PCR for dengue was also sent along with Congo fever markers.

Day 3. Patient's conscious level, restlessness, and irritability improved. Two episodes of melena and epistaxis occurred. Intravenous proton pump infusion was started and fresh whole blood was transfused.

Day 4. Patient became breathless. Chest examination revealed bilateral wheeze and crepitations. Oxygen saturation dropped to 74%. On ABGs, PO₂ was 48 mmHg. CXR showed bilateral infiltrates. Diagnosis of ARDS was considered and patient was started on ventilatory support.

Day 5. Patient's condition remained the same. Mechanical ventilation was continued. ECG showed sinus tachycardia. Dexamethasone was restarted at a dose of 10 mg/m² per day.

Day 6. Fever and hypotension developed. Antibiotics were modified to Imipenem and Vancomycin considering the diagnosis of hospital acquired infection. Ultrasound scan revealed right sided moderate to massive pleural effusion. Thoracocentesis was done and straw-colored 1-liter fluid was aspirated which was transudative on laboratory evaluation. Echocardiography showed dilated left ventricular (LV) and globally reduced LV systolic function. Ejection fraction was 25%. Diagnosis of dengue myocarditis was also considered and digoxin was added to treatment regimen.

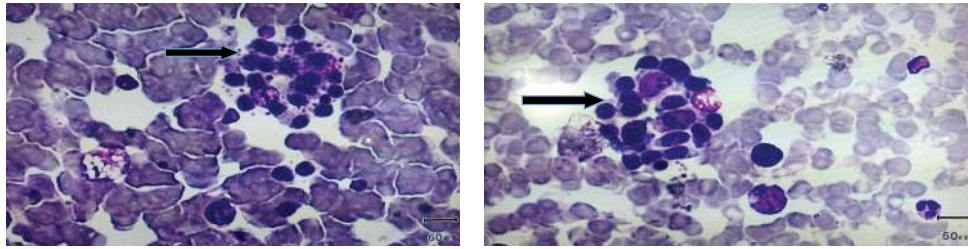


FIGURE 1: Two bone marrow biopsy slides of patient showing histiocyte surrounded by erythroblasts (arrow).

Day 7. Patient's condition did not improve and management continued. Repeat ultrasound scan showed mild bilateral effusion. Bone marrow biopsy was done; it was suggestive of HLH (Figure 1).

Days 8 and 9. Patient went into asystole and resuscitation resulted in recovery. Inotropic support was added.

Day 10. Patient expired.

The report of dengue PCR and Congo fever markers was received after expiry. Den 3 was isolated (RNA extraction by Qiagen viral RNA mini kit, and amplification by real-time PCR). Congo fever markers were negative.

3. Discussion

HLH is an uncommon inflammatory disorder which is characterized by activation of macrophages that cause phagocytosis of blood cells in bone marrow. HLH is diagnosed when 5 out of 8 diagnostic criteria are fulfilled [2, 5–7]. Criteria fulfilled in our patients were (1) fever, (2) cytopenia on peripheral film examination, (3) hypertriglyceridemia or hypofibrinogenemia, (4) hyperferritinemia, and (5) enlargement of spleen. Bone marrow picture in our patient was suggestive but not diagnostic of HLH. It should however be noted that, in about 30% of patients with HLH, first bone marrow examination may not be diagnostic and repeat biopsy may have to be performed [8]. We did not get it; additionally evaluation of natural killer (NK) cell activity and soluble interleukin (IL) level was not possible in our circumstances.

Dengue is an uncommon cause of HLH [9–12]. In dengue infection, virus infected T cells produce cytokines like TNF- α and IFN gamma which possibly contribute to development of HLH syndrome [13]. Most of the dengue related HLH cases described in literature are associated with DHF [4]. Our patient had DHF: (1) his illness started during dengue epidemic period in a dengue epidemic hit area, (2) clinical features were suggestive of dengue infection, that is, fever, headache, retroorbital pain, and myalgias, (3) thrombocytopenia was noted, (4) serological tests for secondary dengue infection and PCR were positive, and (5) ultrasonography showed evidence of plasma leakage on day 1. In our patient DEN 3 was isolated. DEN 3 has been noted to be associated with HLH in USA [14]. HLH due to DEN 1 and DEN 4 was noted in Puerto Rico [15].

P. vivax malaria is another unusual cause of HLH syndrome [5, 11]. Malarial infection causes increased production of interferon gamma, tumor necrosis factor-alpha, interleukin-1, and interleukin-6 that may lead to HLH [13]. Fever, enlargement of spleen, and thrombocytopenia in our patient indicate, while *P. vivax* detection confirms diagnosis of malaria.

Treatment of the cause, supportive therapy, and suppressing immune response are main stay of HLH management [16]. Specific treatment of HLH is based on HLH protocol that includes usage of dexamethasone, etoposide, and intrathecal methotrexate [16]. It is further divisible in induction, salvage, and continuation therapies. Antithymocyte globulin or alemtuzumab, anti-interferon- γ monoclonal antibodies, and hematopoietic stem cell transplantation are additional available modalities for HLH treatment [16].

Complexity of clinical situation, difficulty in differentiation from sepsis, and multiorgan dysfunction lead to delayed diagnosis in HLH [16]. Untreated HLH is associated with poor outcome. In a study focusing on 162 adult HLH patients, 58% survival was noted [8]. In a seminar about adult hemophagocytic syndrome 41% mortality was described in 1109 adult patients [5]. Outcome in *P. vivax* associated HLH is generally good if appropriate antimalarials are used [17–19]. 0–100% mortality has been reported in dengue related HLH [9, 10, 15, 20]. Dengue related HLH in which the patient recovered has been documented in Pakistan as well [21].

Our patient had dual infection with dengue virus and *P. vivax*. Malaria and dengue coinfection can occur in countries where these are endemic; however HLH complicating the two infections has never been reported according to our knowledge. Both these diseases come in the differential diagnosis of acute febrile illness. The question is what predominantly caused HLH in our patient. *P. vivax* was not detected after artesunate administration on smear and bone marrow examinations of our patient making it less plausible etiological factor for HLH development.

Persistence of fever > 8 days in dengue alerts towards diagnosis of HLH, as duration of dengue febrile phase is generally 3–7 days [22, 23]. Additionally dengue virus remains detectable for 2–12 days after the onset of illness [24]. In our patient dengue virus was isolated on 14th day of onset of illness which is unusual and has not been focused previously. HLH thus possibly complicated dengue infection. Genetic factors and *P. vivax* infection may have additional variable contribution.

Our patient had cardiac involvement. Troponin T was negative twice however. It is known that Troponin autoantibodies can result in false negative Troponin T results [25]. Was it uncontrolled immune activity which lead to it in our patient? This remains to be evaluated in further studies.

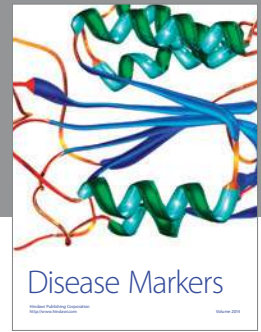Our patient received focused DHF management, anti-malarials for *P. vivax*, corticosteroids for HLH, cover for infection, and supportive therapy. He however did not receive etoposide, methotrexate, and immunoglobulins. HLH related neurological, respiratory, hepatic, and cardiac involvement lead to multiorgan dysfunction which caused death in our patient. Infection possibly contributed to it as well, which can complicate the scenario because of HLH pathophysiology and immunosuppressive medications like steroids used in treatment. HLH protocol was not employed in our patient that may have altered the outcome. Remembering that HLH can occur in similar settings can help in early diagnosis and institution of HLH protocol.

Conflict of Interests

The authors declare that there is no conflict of interests regarding the publication of this paper.

References

- [1] A. Karras and O. Hermine, "Macrophage activation syndrome," *La Revue de Médecine Interne*, vol. 23, no. 9, pp. 768–778, 2002.
- [2] J.-I. Henter, A. Horne, M. Aricó et al., "HLH-2004: diagnostic and therapeutic guidelines for hemophagocytic lymphohistiocytosis," *Pediatric Blood and Cancer*, vol. 48, no. 2, pp. 124–131, 2007.
- [3] P. S. Sung, I. H. Kim, J. H. Lee, and J. W. Park, "Hemophagocytic Lymphohistiocytosis (HLH) associated with *Plasmodium vivax* Infection: case report and review of the literature," *Chonnam Medical Journal*, vol. 47, no. 3, pp. 173–176, 2011.
- [4] S. Ray, S. Kundu, M. Saha, and P. Chakrabarti, "Hemophagocytic syndrome in classic dengue fever," *Journal of Global Infectious Diseases*, vol. 3, no. 4, pp. 399–401, 2011.
- [5] M. Ramos-Casals, P. Brito-Zerón, A. López-Guillermo, M. A. Khamashta, and X. Bosch, "Adult haemophagocytic syndrome," *The Lancet*, vol. 383, no. 9927, pp. 1503–1516, 2014.
- [6] G. E. Janka and K. Lehmsberg, "Hemophagocytic syndromes—an update," *Blood Reviews*, vol. 28, no. 4, pp. 135–142, 2014.
- [7] F. G. N. Rosado and A. S. Kim, "Hemophagocytic lymphohistiocytosis: an update on diagnosis and pathogenesis," *American Journal of Clinical Pathology*, vol. 139, no. 6, pp. 713–727, 2013.
- [8] S. Rivière, L. Galicier, P. Coppo et al., "Reactive hemophagocytic syndrome in adults: a retrospective analysis of 162 patients," *American Journal of Medicine*, vol. 127, no. 11, pp. 1118–1125, 2014.
- [9] A. M. Vijayalakshmi and V. R. R. Ganesh, "Hemophagocytic syndrome associated with Dengue hemorrhagic fever," *Indian Pediatrics*, vol. 46, no. 6, article 545, 2009.
- [10] A.-S. De Koninck, J. Dierick, S. Steyaert, and P. Taelman, "Hemophagocytic lymphohistiocytosis and dengue infection: rare case report," *Acta Clinica Belgica*, vol. 69, no. 3, pp. 210–213, 2014.
- [11] T. Benter, L. Klühs, and U. Teichgräber, "Sonography of the spleen," *Journal of Ultrasound in Medicine*, vol. 30, no. 9, pp. 1281–1293, 2011.
- [12] A. H. Filipovich, "Hemophagocytic lymphohistiocytosis (HLH) and related disorders," *American Society of Hematology. Education Book*, pp. 127–131, 2009.
- [13] I. Nakamura, F. Nakamura-Uchiyama, N. Komiya, and K. Ohnishi, "A case of dengue fever with viral-associated hemophagocytic syndrome," *Kansenshōgaku Zasshi*, vol. 83, no. 1, pp. 60–63, 2009.
- [14] T. M. Sharp, L. Gaul, A. Muehlenbachs et al., "Fatal hemophagocytic lymphohistiocytosis associated with locally acquired Dengue virus infection—New Mexico and Texas, 2012," *Morbidity and Mortality Weekly Report*, vol. 63, no. 3, pp. 49–54, 2014.
- [15] E. M. Ellis, J. Pérez-Padilla, L. González et al., "Unusual cluster in time and space of Dengue-associated hemophagocytic lymphohistiocytosis in Puerto Rico," *Blood*, vol. 122, no. 21, p. 3497, 2013.
- [16] M. B. Jordan, C. E. Allen, S. Weitzman, A. H. Filipovich, and K. L. McClain, "How I treat hemophagocytic lymphohistiocytosis," *Blood*, vol. 118, no. 15, pp. 4041–4052, 2011.
- [17] J.-I. Henter, A. Samuelsson-Horne, M. Aricó et al., "Treatment of hemophagocytic lymphohistiocytosis with HLH-94 immunochemotherapy and bone marrow transplantation," *Blood*, vol. 100, no. 7, pp. 2367–2373, 2002.
- [18] A. Aouba, M. E. Noguera, J. P. Clauvel, and L. Quint, "Haemophagocytic syndrome associated with *Plasmodium vivax* infection," *British Journal of Haematology*, vol. 108, no. 4, pp. 832–833, 2000.
- [19] T. S. Park, S. H. Oh, J. C. Choi et al., "*Plasmodium vivax* malaria complicated by hemophagocytic syndrome in an immunocompetent serviceman," *American Journal of Hematology*, vol. 74, no. 2, pp. 127–130, 2003.
- [20] L. H. Tan, L. C. S. Lum, S. F. S. Omar, and F. K. Kan, "Hemophagocytosis in dengue: comprehensive report of six cases," *Journal of Clinical Virology*, vol. 55, no. 1, pp. 79–82, 2012.
- [21] R. Rathore, S. M. Daniyal, A. Iqbal, N. F. Butt, and F. Mehbob, "Hemophagocytic syndrome—a rare complication of Dengue fever," *Annals of KEMU*, vol. 18, no. 1, pp. 124–126, 2012.
- [22] P. Pal, P. P. Giri, and A. V. Ramanan, "Dengue associated hemophagocytic lymphohistiocytosis: a case series," *Indian Pediatrics*, vol. 51, no. 6, pp. 496–497, 2014.
- [23] E. S. Halsey, M. Williams, V. A. Laguna-Torres et al., "Occurrence and correlates of symptom persistence following acute dengue fever in Peru," *The American Journal of Tropical Medicine and Hygiene*, vol. 90, no. 3, pp. 449–456, 2014.
- [24] D. J. Gubler, "Dengue and dengue hemorrhagic fever," *Clinical Microbiology Reviews*, vol. 11, no. 3, pp. 480–496, 1998.
- [25] S. Eriksson, H. Halenius, K. Pulkki, J. Hellman, and K. Pettersson, "Negative interference in cardiac troponin I immunoassays by circulating troponin autoantibodies," *Clinical Chemistry*, vol. 51, no. 5, pp. 839–847, 2005.



Hindawi

Submit your manuscripts at
<http://www.hindawi.com>

