

Hepatoprotective activity of *Ficus carica* Linn. leaf extract against carbon tetrachloride-induced hepatotoxicity in rats

¹Krishna Mohan G., ¹Pallavi E., ¹Ravi Kumar B., ¹Ramesh M., ^{*2}Venkatesh S.

¹University College of Pharmaceutical Sciences, Kakatiya University, Warangal, ²G. Pulla Reddy College of Pharmacy, Mehdipatnam, Hyderabad, India

Received: 5 Dec 2006; Revised: 4 March 2007; Accepted: 6 March 2007

ABSTRACT

The methanol extract of the leaves of *Ficus carica* Linn. (Moraceae) was evaluated for hepatoprotective activity in rats with liver damage induced by carbon tetrachloride. The extract at an oral dose of 500 mg/kg exhibited a significant protective effect by lowering the serum levels of aspartate aminotransferase, alanine aminotransferase, total serum bilirubin, and malondialdehyde equivalent, an index of lipid peroxidation of the liver. These biochemical observations were supplemented by histopathological examination of liver sections. The activity of extract was also comparable to that of silymarin, a known hepatoprotective.

Keywords: *Ficus carica*, Leaves, Hepatoprotective; Carbon tetrachloride

INTRODUCTION

Liver is the largest organ in the vertebrate body and the site for intense metabolism. Liver diseases remain one of the serious health problems and the Indian traditional system of medicine, especially Ayurveda have put forward a number of medicinal plants and their formulations for liver disorders. In this modern age it is very important to provide scientific proof to justify the various medicinal uses of herbs. Herbal drugs are prescribed widely even when their biologically active components are unknown because of their effectiveness, fewer side effects and relatively low cost (1). However, we are not aware of a satisfactory remedy for serious liver diseases and search for effective and safe drugs for liver disorders continues to be an area of interest.

Ficus carica Linn. (Moraceae) is a deciduous tree, which grows in tropical and subtropical regions of India and is commonly known as fig tree (2). In traditional medicine the roots are used in treatment of leucoderma and ringworms and its fruits which are sweet, have antipyretic, purgative, aphrodisiac properties and have shown to be useful in inflammations and paralysis (3,4). *F. carica* is claimed to be useful in liver and spleen disorders, to cure piles and in treatment of gout. Locally the leaves are being used in the treatment of jaundice (personal information from users). Earlier chemical examination of this plant have shown the presence of psoralen, bergapten, umbelliferone (5,6), β -sitosterol, campesterol, stigmasterol, fucosterol, fatty acids (7), 6-(2-methoxy-Z-vinyl)-7-methyl-pyrano-coumarin and 9,19-cycloarlane triterpenoid as an anticancer (8,9) and antiproliferative agent: 6-O-acyl- β -D-

glucosyl- β -sitosterol (10), calotropenyl acetate, and lupeol acetate (11).

Previously it was reported that the leaf extracts of *Ficus racemosa* (12) and *Ficus hispida* (13) possess significant hepatoprotective activity against carbon tetrachloride- and paracetamol-induced hepatotoxicity in rats, respectively. In view of the reported hepatoprotective activity of other *Ficus* species and traditional claims, the leaves of *F. carica* was evaluated against carbon tetrachloride induced hepatic damage in rats with the aim of developing a natural hepatoprotective drug.

MATERIALS AND METHODS

Plant material

F. carica leaves were collected from Kodur, Andhra Pradesh, India and authenticated by Dr. S. Raju, Taxonomist, Botany department, Kakatiya University, Warangal. A voucher specimen (UCPSC/KU/27) is deposited in the laboratory of Pharmacognosy, University College of Pharmaceutical Sciences, Kakatiya University, Warangal, India.

Preparation of extract

Dried leaf powder (200 g) was extracted with methanol by maceration for five days. The concentrated methanolic extract (16.6 g) was tested for qualitative phytoconstituents and indicated the presence of steroids/triterpenoids and their glycosides and coumarins (14).

Animals

Male Wistar rats (200-220 g) procured from the National Institute of Nutrition, Hyderabad, were

maintained under standard environmental conditions. Animals had free access to feed (Hindustan Liver, Bangalore) and tap water *ad libitum* during the quarantine period. All procedures compiled with the norms of the animal ethics committee of our university.

Hepatoprotective effect against CCl₄-induced hepatotoxicity in rats

Animals were divided into four groups of six rats each. Group I and II served as normal and intoxicated control, respectively and received only the vehicle (5% gum acacia; 1 ml/kg; p.o). Group III animals were treated with standard silymarin at an oral dose of 100 mg/kg and group IV received the methanolic extract of *F. carica* at an oral dose of 500 mg/kg, as a fine suspension of 5% aqueous gum acacia. The treatment was continued for 7 days, once daily. On the day of 7 for groups II-IV, 30 min post-dose of extract administration animals received CCl₄ at the dose of 1.5 ml/kg (1:1 of CCl₄ in olive oil) orally (15, 16). The animals were sacrificed after 36 h after administration of acute dose of CCl₄. The blood was collected by carotid artery. The serum was separated out and used for estimation of aspartate aminotransferase (AST), alanine aminotransferase (ALT) (17), alkaline phosphatase (ALP) (18) and total serum bilirubin using Span diagnostic kits. The liver was immediately removed and the liver tissue was used for estimation of malondialdehyde equivalent (19), an index of lipid peroxides and a section of liver was processed for histological studies.

Histopathological studies

The tissues of liver were fixed in 10% formalin and embedded in paraffin wax. Sections of 4-5 microns thickness were made using rotary microtome and stained with haematoxylin-eosin and histological observations were made under light microscope (20,21).

Statistical analysis

The results are expressed as means \pm S.D. The difference between experimental groups were compared by one-way ANOVA (toxic control versus treatment, Bonferroni's method; using Jandal scientific, Sigmastat statistical software, version 1.0) and were considered statistically significant when $p < 0.05$.

RESULTS

The animals treated with toxic doses of carbon tetrachloride had markedly elevated values of the serum ALT, AST, ALP and total bilirubin compared to normal rats, indicating acute hepatocellular damage (Table-1). Serum enzyme values in the animals pretreated with methanolic extract

of *F. carica* (500 mg/kg; p.o) were significantly ($p < 0.001$) lower than those of toxic control values and except for ALP. ALT, AST, total bilirubin serum enzyme values in treated animals were similar to the normal control values. Malondialdehyde values in the *F. carica* extract treated animals were significantly lower ($p < 0.001$) than those of toxic control values. The effects of the methanolic extract of *F. carica* were comparable to that of standard silymarin activity. Histopathological examination of liver sections of control group showed normal cellular architecture with distinct hepatic cells, sinusoidal spaces and central vein (Fig.1). Disarrangement of normal hepatic cells with centrilobular necrosis, vacuolization of cytoplasm and fatty degeneration were observed in CCl₄ intoxicated animals (Fig. 2). The liver sections of the rats treated with methanolic extract of *F. carica* and silymarin followed by CCl₄ intoxication showed a sign of protection as it was evident by the absence of necrosis and vacuoles (Fig. 3 and 4).

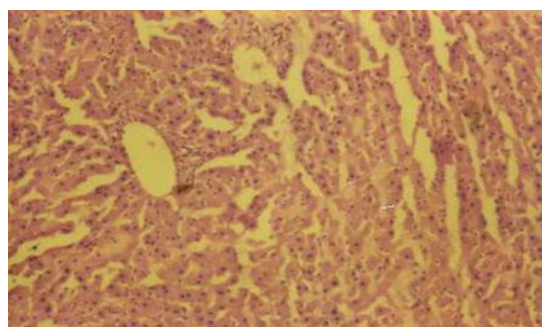


Figure 1. Microphotograph of normal rat liver section H&E staining (x200)

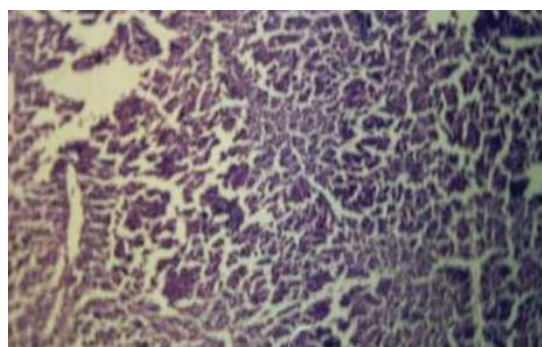


Figure 2. Microphotograph of rat liver section treated with CCl₄ H&E staining (x200)

DISCUSSION

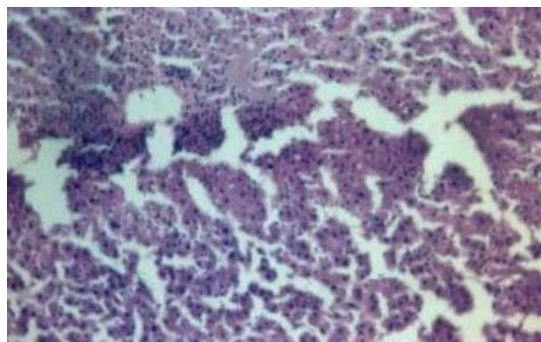
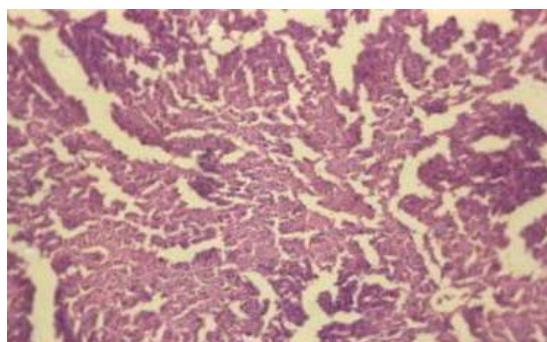
The methanolic extract of *Ficus carica* leaves, administered prophylactically, exhibited significant protection against CCl₄-induced liver injury as manifested by the reduction in toxin-mediated rise in serum transaminases, ALP and total bilirubin in rats. Liver damage induced by CCl₄ is commonly used model for the screening of

Table 1. Effect of pretreatment with methanolic extract of *Ficus carica* on CCl₄-induced rats

Group	Treatment, p.o	Bio chemical parameters				MDA (equi)
		ALT (U/L)	AST (U/L)	ALP (U/L)	Total bilirubin (mg/dl)	
I	Control-Normal	22±2.8	122.9±5.0	115.6±8.9	0.40±0.04	4.71 ± 0.5
II	CCl ₄ -treated	37.2±1.9	130.3±3.9	191.5±7.5	0.87±0.07	12.73±1.3*
III	Silymarin+CCl ₄	21.8±1.8*	119.3±3.3*	188.2±4.5	0.56±0.1*	5.4±1.5*
IV	MeOH ext+CCl ₄	22.5±2.3*	117.6±4.6*	188.7±5.6	0.51±0.1*	6.43±1.3*

Groups from II to VI received CCl₄ 30 min after treatment on 7th day.

Values are mean ± S.D; n=6. *p< 0.001 vs. Group II

**Figure 3.** Microphotograph of liver section from silymarin and CCl₄ treated rat H&E staining (x200)**Figure 4.** Microphotograph of liver section from methanolic extract and CCl₄ treated rat H&E staining (x200)

hepatoprotective drugs (22). The rise in serum levels of AST, ALT and ALP has been attributed to the damaged structural integrity of the liver, because they are cytoplasmic in location and released into circulation after cellular damages (23). The rise in the levels of serum bilirubin is the most sensitive and confirms the intensity of jaundice (24). The CCl₄ is converted into reactive metabolite, halogenated free radical by hepatic cytochrome P450s (25,26), which in turn covalently binds to cell membrane and organelles to elicit lipid peroxidation with subsequent tissue injury. High lipid peroxidation values indicate excessive free radical induced peroxidation. The measurement of lipid peroxide is also a marker of hepatocellular damage (27,28).

Pretreatment of animals with methanolic extract of *F. carica* and silymarin prevented the CCl₄-induced rise in serum level of transaminases and total serum bilirubin, confirming the protective effects of methanolic extract of *F. carica* leaves against carbon tetrachloride induced hepatic damage. The hepatoprotective activity of *F. carica* (500 mg/kg) was comparable with the activity of standard silymarin (100 mg/kg). However there was no effect on rise in serum alkaline phosphatase levels by the test extract and silymarin. A comparative histopathological study of the livers from different groups further corroborated the hepatoprotective potential.

In animals treated with methanolic extract and silymarin, the rise in lipid peroxides in liver tissue homogenate was prevented significantly. The decrease in lipid peroxides may be due to the antioxidant effect of the extract. A possible mechanism of the *F. carica* extract as hepatoprotective may be due to its anti-oxidant effect or inhibition of cytochrome P450s which impair the bioactivation of CCl₄ (29) into their corresponding reactive species.

The preliminary phytochemical studies indicated the presence of steroids/triterpenoids and their glycosides and coumarins in the methanolic extract of leaves of *F. carica*. Since coumarins have hepatoprotective activity (30-32), it may be speculated that these constituents of *Ficus* are responsible for the observed protective effects. However the role of steroids/triterpenoids can not be ruled out.

ACKNOWLEDGEMENT

The authors wish to thank Principal, UCPSC for providing research facilities. The authors also wish to thank Prof. D.R. Krishna, UCPSC, Kakatiya University, Warangal, India for his valuable help and suggestions during the course of work. The All India Council of Technical Education, New Delhi, India financially supported this investigation.

REFERENCES

1. Valiathan MS. Healing plants. *Curr Sci* 1998; 75: 1122-1127.
2. Anonymous. The wealth of India: Raw Materials. Vol. 4, India: CSIR publication, 2002. p. 26-32.

3. Kirthikar KR, Basu BD. Indian medicinal plants. Vol. 3, 2nd ed, India: International Book Distributors, 1996. p. 2329-2331.
4. Nadkarni KM, Nadkarni AK. Indian material medica. Vol. 1, India: Popular Prakashan, 1995. p. 545-547.
5. Seong-Kuk K, Dong-Ok C, Hee-Jong C. Purification and identification of antimicrobial substances in phenolic fraction of fig leaves. *Han'guk Nonghwa Hakhoechi* 1995; 38: 293-296.
6. Louis P, Patrick P, Andre M, Jean-Marie B, Andre F, Jean-Paul R. Bergapten content in fig leaves. *Annales des Falsifications de l'Expertise Chimiqui et Toxicologique* 2000; 93: 427-435.
7. Jeong WS, Lachance PA. Phytosterols and fatty acids in fig (*Ficus carica*, var. Mission) fruit and tree components. *J Food Sci* 2001; 66: 278-281.
8. Weiping Y, Hongming C, Tianxin W, Mengshen C. A new coumarin compound with anticancer activity. *Zhongcaoyao* 1997; 28: 3-4.
9. Weiping Y, Hongming C, Tianxin W, Mengshen C. Research on the chemical structure and anticancer activity of 9, 19-Cyclopropane-24, 25 ethyleneoxide-5-en-3 β -spirostol. *Zhongguo Yaowu Huaxue Zazhi* 1997; 7: 46-47.
10. Shai R, Yoel K, Ruth R, Michael S, Raphael M. Suppressors of cancer cell proliferation from fig (*Ficus carica*) resin: Isolation and structure elucidation. *J Nat Prod* 2001; 64: 993-996.
11. Saeed MA, Sabir AW. Irritant potential of triterpenoids from *Ficus carica* leaves. *Fitoterapia* 2002; 73: 417-420.
12. Subhash CM, Tapan KM, Das J, Pal M, Saha BP. Hepatoprotective activity of *Ficus racemosa* leaf extract on liver damage caused by carbon tetrachloride in rats. *Phytother Res* 1999; 13: 430-432.
13. Subhash CM, Saraswathi B, Ashok Kumar CK, Mohana Lakshmi S, Maiti BC. Protective effect of leaf extract of *Ficus hispida* Linn against paracetamol-induced hepatotoxicity in rats. *Phytother Res* 2000; 14: 457-459.
14. Trease EG, Evan WC. Textbook of pharmacognosy. 12th ed, Oxford: Alden Press, 1983. p. 539
15. Saraf S, Dixit VK. Hepatoprotective activity of *Tridax procumbens* part-II. *Fitoterapia* 1991; 62: 534-536.
16. Mohideen S, Ilavarasan R, Sasikala E, Thirumalai kumarn R. Hepatoprotective activity of *Nigella sativa* Linn. *Ind J Pharm Sci* 2003; 65: 550-551.
17. Reitman S, Frankel S. A colorimetric method for the determination of serum glutamic oxalacetic and glutamic pyruvic transaminases. *Amer J Clin Pathol* 1957; 28: 56-63.
18. Mac Comb RB, Bowers GN. Study of optimum buffer conditions for measuring alkaline phosphatase activity in human serum. *Clin Chem* 1972; 18: 97-104.
19. Ohkawa H, Ohishi N, Yagi K. Assay of lipid peroxide in animal tissues by thiobarbituric acid reaction. *Anal Biochem* 1979; 95: 351-358.
20. Galighor AE, Kozloff EN. In: *Essentials of practical Micro Technique*. 2nd ed. New York: Lea and Febiger, 1976.
21. Luna GLHT. *Manual of Histologic and special staining methods of the Armed Forces Institute of Pathology*. 3rd ed. New York: Mc Graw Hill, 1968.
22. Slater TF. *Biochemical mechanism of liver injury*. London: Academic Press, 1965.
23. Sallie R, Tredger JM, William R. *Drugs and the liver*. Part I. Testing liver function. *Biopharm Drug Disp* 1991; 12: 251-259.
24. Drotman RB, Lawhorn GT. Serum enzymes as indicators of chemically induced liver damage. *Drug Chem Toxicol* 1978; 1: 163-171.
25. Packer JE, Slater TF, Wilson RL. Reactions of the carbon tetrachloride related peroxy free radical (CC 130.2) with amino acids: pulse radiolysis evidence. *Life Sci* 1978; 23: 2617-2620.
26. Van de Straat R, de Vries J, Debets AJ, Vermueulein NP. The mechanism of prevention of paracetomaol-induced hepatotoxicity by 3,5-dialkyl substitution. The role of glutathione depletion and oxidative stress. *Biochem Pharmacol* 1987; 36: 2065-2070.
27. Brattin WJ, Glenda EA Jr, Recknagel RO. Pathological mechanisms in carbon tetrachloride hepatotoxicity. *J Free Radical Biol Med* 1985; 1: 27-38.
28. Prabakaran M, Rangasamy A, Devaki T. Protective effect of *Hemidesmus indicus* against rifampicin and isoniazid-induced hepatotoxicity in rats. *Fitoterapia* 2000; 71: 55-59.
29. Recknagel RO, Glende EA, Dolak JA, Waller RL. Mechanisms of carbon tetrachloride toxicity. *Pharmacol Ther* 1989; 43:139-154.
30. Matsuda H, Murakami T, Kageura T, Ninoniya K, Toguchida I, Nishida N, Yoshikawa M. Hepatoprotective and nitric oxide production inhibitory activities of coumarin and polyacetylene constituents from the roots of *Angelica furcijuga*. *Bioorg Med Chem Lett* 1998; 8: 2191-2196.

31. Park EJ, Oh H, Kang TH, Sohn DH, Kim YC. An isocoumarin with hepatoprotective activity in Hep G2 and primary hepatocytes from *Agrimonia pilosa*. Arch Pharm Res 2004; 27: 944-946.
32. Oh H, Lee HS, Kim T, Chai KY, Chung HT, Kwon TO, Jun JY, Jeong OS, Kim YC, Yun YG. Furocoumarins from *Angelica dahurica* with hepatoprotective activity on tacrine-induced cytotoxicity in Hep G2 cells. Planta Med 2002; 68: 463-464.
33. Oh H, Ko EK, Jun JY, Oh MH, Park SU, Kang KH, Lee HS, Kim YS. Hepatoprotective and free radical scavenging activities of prenylflavonoids, coumarins and stilbene from *Morus alba*. Planta Med 2002; 68: 932-934.