

Full Length Research Paper

Hepatoprotective effect of basil (*Ocimum basilicum* L.) on CCl₄-induced liver fibrosis in rats

Galila A. Yacout, Nihal M. Elguindy* and Eman F. El Azab

Department of Biochemistry, Faculty of Science, Alexandria University, Egypt.

Accepted 2 October, 2012

The hepatoprotective effect of basil (*Ocimum basilicum*) extract against liver fibrosis-induced by carbon tetrachloride (CCl₄) was studied in rats. Rats were allocated into five groups: Group I (control group); Group II [CCl₄ group; rats were injected subcutaneously with CCl₄ (1 ml/kg b.w.) twice weekly for 4 weeks (phenobarbital, 350 mg/L, was added to the drinking water throughout the experiment)]; Group III received daily oral doses of basil extract of 200 mg/kg b.w. along with CCl₄ and phenobarbital for 6 weeks; Groups IV and V rats were treated with phenobarbital and CCl₄ for 6 weeks then treated daily with oral dose of 200 mg/kg b.w basil extract, or by 300 mg/kg b.w dimethyl diphenyl bicarboxylate (DDB), respectively for 6 weeks. Basil-treatment significantly reduced the liver content of hydroxyproline and significantly increased the activity of hyaluronidase (HAase). The hepatic activity of superoxide dismutase (SOD) was stimulated while the lipid peroxidation was significantly reduced by the effect of basil extract. Treatment with CCl₄ significantly increased the activities of transaminases [aspartate aminotransferase (AST), alanine aminotransferase (ALT)], and alkaline phosphatase (ALP). These activities were significantly decreased by basil extract. The higher levels of serum urea and creatinine in CCl₄ group were significantly guarded by the protection of basil.

Key words: Carbon tetrachloride, liver fibrosis, antioxidant, *Ocimum basilicum*, dimethyl diphenyl bicarboxylate.

INTRODUCTION

During the last decade, considerable attention was given to the involvement of oxygen free radicals in various diseases. There is no doubt that reactive oxygen species (ROS) play an important role in pathological changes in the liver, particularly in the case of alcoholic and toxic liver diseases (Das and Vasudevan, 2007). Biological membranes are particularly prone to ROS effect. The peroxidation of unsaturated fatty acids in biological membranes leads to the decrease of membrane fluidity and the disruption of membrane integrity and function. Such peroxidation effect is implicated in serious pathological changes in liver resulting in hepatotoxicity (Cabre et

al., 2000). Several endogenous protective mechanisms have evolved to limit ROS effect and the damage caused by them (Sies, 1993). However, when this protection is not complete, or when the formation of ROS is excessive, additional protective mechanisms of dietary antioxidants may be of a great importance. Therefore, many natural and synthetic agents possessing antioxidative properties have been proposed to prevent and treat hepatopathies induced by oxidative stress (Kandasamy et al., 2010). There is increasing evidence of the hepatoprotective role of hydroxy and polyhydroxy organic compounds, particularly from vegetables, fruits and some herbs (Bass, 1999).

Sweet basil (*Ocimum basilicum* L., Lamiaceae family) was employed traditionally as a folk remedy for a wide spectrum of ailments. It is also incorporated into a number of herbal medicinal preparations in India. Basil is known to have numerous pharmacological activities. Basil leaf extracts have potent antioxidant, anti-aging, anticancer, antiviral, and antimicrobial properties (Dasgupta et al., 2004; Bozin et al., 2006). The volatile oil

*Corresponding author. E-mail: Faynt2001us@yahoo.com. Tel: +203-4211163. Fax: +203-3911794.

Abbreviations: ROS, Reactive oxygen species; CCl₄, carbon tetrachloride; DDB, dimethyl diphenyl bicarboxylate; HAase, hyaluronidase enzyme; SOD, superoxide dismutase; MDA, malondialdehyde; TBAR, thiobarbituric acid reacting substance.

of basil has estragol, linalool, eugenol, methyl chavicol and small quantities of methyl cinnamate, cineole, apigenin, luteolin, orientin, vicenin, and other terpenes (Samudralwar and Garg, 1996). Leaves of *O. Sanctum* are commonly used in mild indigestion, diminished appetite and malaise (Vats et al., 2004). Consumption of basil or basil oil has been associated with a reduction in total cholesterol, low-density lipoprotein and triglyceride (Hicham et al., 2009).

Batra and Gupta (2006) indicated that *O. Sanctum* leaf supplementation reduced the severity of hydropericardium, hepatitis, myocarditis accompanied with haemorrhages, oedema in lungs, lymphocytic depletion in lymphoid organs and focal interstitial nephritis. Rupert (2009) reported that basil and basil oil have agents for prevention and treatment of cardiovascular diseases. It has also been shown that *O. Sanctum* leaf extracts can protect the liver from toxicity by heavy metals (Sharma et al., 2002) and prevent isoproterenol induced myocardial necrosis in rats (Sood et al., 2005).

Liver injury produced by CCl_4 depends on its metabolism to the highly reactive trichloromethyl (CCl_3) radical, which initiates lipid peroxidation. This leads to CCl_4 hepatotoxicity by starting lipid peroxidation in membranes (Parola et al., 1992; Abd El-Ghany, 2006). Dimethyl diphenyl bicarboxylate (DDB), a traditional oriental medicinal plant, is a synthetic analogue of schizandrin C which is one of the active components isolated from *Fructus schizandra* (Kim et al., 1999). DDB has a beneficial effect on elevated liver enzymes and histopathological changes (Xu et al., 1997). It was used successfully for treatment of cases of chemically induced hepatitis (Park et al., 2005).

The aim of the present work was to investigate the hepatoprotective effect of the ethanol extract of basil on liver fibrosis developed by CCl_4 intoxication in rats, and also to compare the curative effect of basil ethanol extract on liver fibrosis with that of DDB.

MATERIALS AND METHODS

Chemicals

All chemicals were of an analytical grade. Tetramethoxy propane, superoxide dismutase, hyaluronic acid, N-acetylglucosamine and hydroxyproline were purchased from Sigma. Thiobarbituric acid, diethylene triaminopentaacetic and pyrogallol were purchased from Sigma-Aldrich company. Chloramine-T was purchased from Aldrich Company. Perchloric acid was purchased from Diamond Company. All other chemicals were purchased from El Nasr Company for Pharmaceutical Chemicals. Kits for aspartate aminotransferase (AST), alanine aminotransferase (ALT), alkaline phosphatase (ALP), albumin as well as urea, creatinine, and total protein were purchased from Biodiagnostic Company, Egypt. DDB was obtained from Beijing Union Pharmaceutical Factory, P.R.C.

Preparation of basil ethanol extract

Fresh plant leaves of basil (*O. basilicum*) were purchased from Faculty of Agriculture, Alexandria, Egypt. Fresh basil leaves (800 g)

were cut into small pieces. Basil ethanol extract was prepared by boiling plant leaves with aqueous ethanol (ethanol: distilled water, 80:20 V/v) for 3 h using the Soxhlet apparatus. The solvent was removed by evaporation under reduced pressure using Rotary Evaporator Büchi CH-9230. Yield of the ethanol extract were given to rats as 200 mg/kg b.w intragastric.

Experimental animals

35 male rats (Sprague Dawley) were purchased from the Animal House, Faculty of Medicine, University of Alexandria, Egypt. The rats weighed about 90 ± 10 g. Animals were provided with standard diet composed of 20% casein, 15% corn oil, 55% corn starch, 5% salt mixture and 5% vitaminized starch. Water was available *ad libitum*. After 10 days of acclimatization period, they were randomly assigned into five groups, each comprising seven rats. Group I (control) rats received twice-weekly subcutaneous injections of corn oil at a dose of 1 ml/kg b.w for 4 weeks. Group II and Group III rats received twice-weekly subcutaneous injections of CCl_4 /corn oil (50% v/v) at a dose of 1 mg/kg b.w for 4 weeks (Wei et al., 2004). Phenobarbital was added to the drinking water (350 mg/L) two weeks before start of the CCl_4 treatment and throughout the experiment (Rivera et al., 2001). Group II rats were the " CCl_4 group". Group III (basil + CCl_4) rats received daily oral doses of basil extract of 200 mg/kg b.w along with CCl_4 and phenobarbital for 6 weeks. The extract was administered one week before the CCl_4 treatment. Group IV and V rats were treated with phenobarbital and CCl_4 for 6 weeks, then treated daily with an oral dose of 200 mg/kg b.w basil extract (basil group), or by 300 mg/kg b.w DDB (DDB group) for 6 weeks, respectively. The local committee approved the design of the experiments, and the protocol conformed to the guidelines of the National Institutes of Health (NIH).

Histological examination

The treated animals and control were sacrificed by decapitation at the end of the experimental period. Liver was removed immediately and a portion of the tissue was instantly fixed in 10% phosphate buffered formalin. Fixed tissues were embedded in paraffin wax and sections of 4 mm thickness were cut. Slides were stained with haematoxylin and eosin for histological examination.

Sample analysis

At the end of the experimental period, rats remained fasting for 10 h before sacrificing them under light diethyl ether anesthesia. Blood samples and liver tissues were collected for biochemical studies. Serum was separated by centrifugation for 15 min at $3500 \times g$ using PLC-05 series cooling centrifuge. Liver tissues from all animal groups were removed immediately after decapitation and placed in ice, washed with ice cold saline (0.9% NaCl), then frozen at -20°C for biochemical investigations.

Biochemical parameters

ALP, AST, ALT activities were assayed. Albumine (Alb), total protein, urea, and creatinine levels were estimated in serum using the respective kits. Serum hyaluronidase (HAase) activity was measured according to the method of Reissig et al. (1955). Liver tissue (100 mg) was digested in 5 M HCl at 100°C for 4 h, and then the tissue homogenate was decolorized with activated charcoal, filtered after 2 min and rinsed with 500 μl of 0.8 mM NaOH followed by 500 μl of distilled water. Clear supernatant (400 μl) was used for the determination of hepatic hydroxyproline content (Patiyal and Katoch, 2006). Superoxide dismutase (SOD) activity in liver was

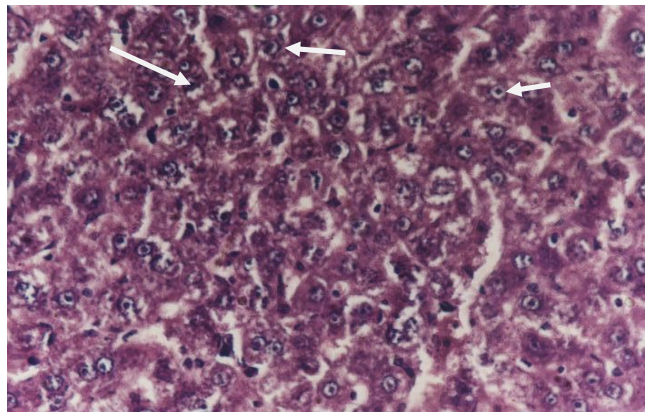


Figure 1. Section of liver of a control rat; the liver tissue appeared normal (400 \times).

analysed (Stefan and Gudrun, 1974). Lipid peroxidation in liver homogenate was determined as malondialdehyde (MDA), a thiobarbituric acid reacting substance (TBARS), using tetramethoxy propane as standard (Ohkawa et al., 1979).

Statistical analysis

All results were expressed as mean value \pm S.D. The statistical analysis was performed using analysis of variance followed by student's *t*-test with $p < 0.001$ considered statistically significant.

RESULTS

Histological observations

Figure 1 shows the histological structure of the liver of control rat (Group I). However, liver of rats treated with CCl_4 for 4 weeks (Group II) showed fibrosis with the loss of structural integrity and formation of nodules that lacked a central vein. Steatosis and ballooning degeneration were observed too (Figure 2a, b and c). CCl_4 caused severe focal necrosis and inflammation. The hepatic parenchymal cells were slightly enlarged. The sinusoids were dilated with Kupffer-cell proliferation, focal congestion and an increase in collagen fibers. Some mononuclear infiltrates were found in the periportal areas. Fat droplets predominated in the cytoplasm. The fatty droplets were most numerous in pericentral locations.

When basil was given simultaneously with CCl_4 (Group III), a distinct decrease in the morphological alteration was observed. Cell size decreased and revealed gradual restoration of the normal structure of liver tissues (Figure 3). The sinusoids were narrow, necrosis and fatty changes were slight, as was connective-tissue proliferation, and inflammatory changes were virtually non-existent. Treatment with basil (Figure 4) or DDB (Figure 5) markedly showed alleviation in the degree of liver fibrosis indicated by a decrease in the collagen deposition and inflammation, then CCl_4 group.

Figures 6 to 8 showed a significant ($p < 0.001$) increase

in serum activities of transaminases, ALT and AST, and ALP in CCl_4 treated group compared to the control. Protection or treatment with basil (Groups III and IV), and treatment with DDB (Group V) significantly ($p < 0.001$) reduced transaminases and ALP activities in comparison to CCl_4 Group II.

In comparison to the control group, hepatic SOD activity was significantly ($p < 0.001$) decreased in the CCl_4 group (Figure 9). Basil groups (III or IV), or that treated with DDB significantly enhanced hepatic SOD activity compared with the CCl_4 group. On the other hand, hepatic MDA was significantly ($p < 0.001$) elevated in the CCl_4 group when compared to the control group. Basil (Groups III or IV), or treatment with DDB significantly reduced MDA levels compared with CCl_4 group (Figure 10).

Serum HAase activity was remarkably reduced ($p < 0.001$) in the CCl_4 group to 129.0 ± 13.6 U/L as compared to the control group (261.8 ± 12.06 U/L), as shown in Figure 11. Protection with basil and treatment with either basil or DDB significantly enhanced HAase activity, compared with CCl_4 group to 238.2 ± 7.4 , 187.5 ± 3.0 and 203.39 ± 6.0 U/L, respectively. CCl_4 induced liver fibrosis accompanied by a significant ($p < 0.001$) increase of hepatic hydroxyproline (818.7 ± 19.1 nmol/mg tissue) in CCl_4 group (Figure 12). Meanwhile, basil treatment caused a significant reduction in hydroxyproline content to 307.2 ± 7.9 , 534.75 ± 11.6 nmol/mg tissue in Groups III and IV, respectively, as compared to the CCl_4 group. Also, the hepatic hydroxyproline level was significantly reduced in the DDB group to 462.1 ± 4.6 nmol/mg tissue in comparison to CCl_4 group.

CCl_4 treated group showed a significant ($p < 0.001$) increase in serum total protein with a significant decrease in serum albumin concentration as compared to the control. On the other hand, Basil + CCl_4 , Basil, and DDB groups showed a significant ($p < 0.001$) decrease in serum total protein and a significant increase in serum albumin compared with CCl_4 group (Table 1). Serum urea and creatinine contents were significantly ($p < 0.001$) increased by CCl_4 treatment compared with the control (Table 1). These contents were decreased significantly ($p < 0.001$) by basil in Group III and IV as well as by DDB treatment compared with CCl_4 group.

DISCUSSION

The mortality of patients with liver fibrosis is gradually increasing because it shows various pathologic conditions, sometimes resulting in the development of liver carcinoma. Various plant extracts have been widely applied to treat chronic liver diseases, including chronic hepatic inflammation and fibrosis (Masahiko et al., 2002). The present study demonstrates the beneficial effect of basil in the prevention of liver fibrosis produced by CCl_4 . It also shows a comparison between the treatment of fibrosis by basil or by DDB, as a drug already used for

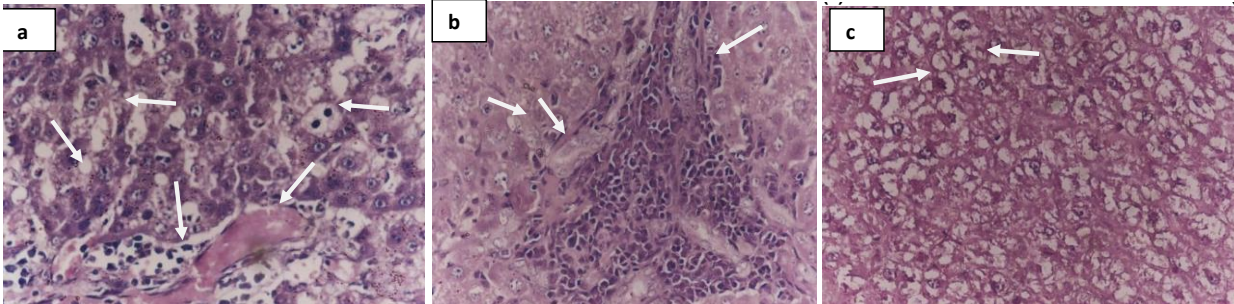


Figure 2. Section of liver of CCl_4 -treated rat after four weeks showing congested and enlarged central vein and mass of leucocytic infiltrations, also, steatosis and ballooning degeneration are shown (arrows), (400 \times).

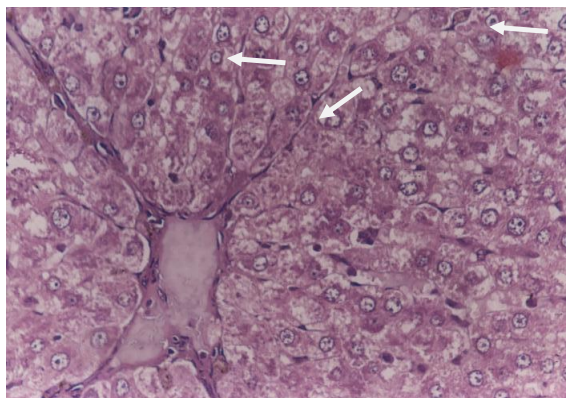


Figure 3. Liver section of a rat treated with CCl_4 and basil for 4 weeks, showing an obvious degree of improvement. Cell size decreased and revealed gradual restoration of the normal structure of liver tissues (arrows) (400 \times).

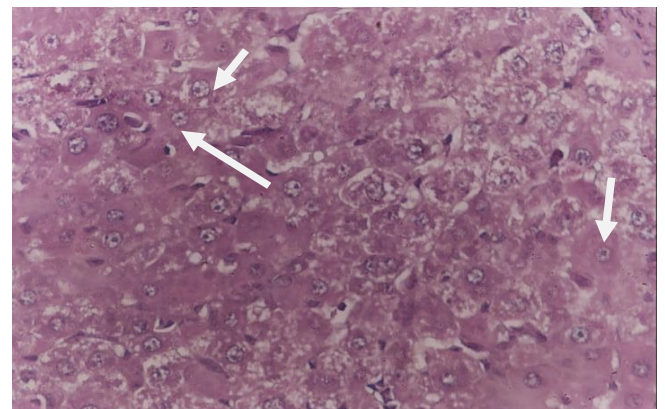
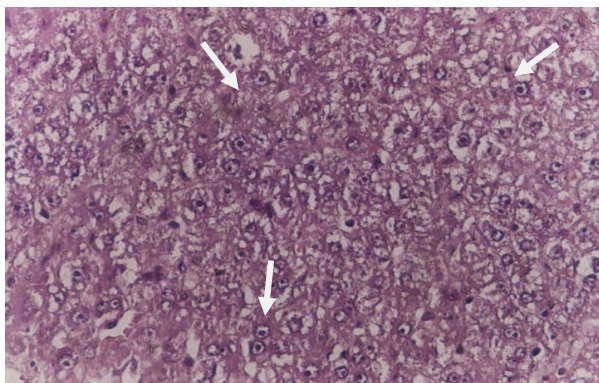


Figure 5. Liver section of CCl_4 -treated rat for 4 weeks and then treated with DDB for 6 weeks. It markedly showed alleviation in the degree of liver fibrosis indicated by a decrease in the collagen deposition and inflammation than that in CCl_4 group (400 \times).



Figures 4. Liver section of CCl_4 -treated rat for 4 weeks and then treated with basil for 6 weeks. The figure markedly shows alleviation in the degree of liver fibrosis indicated by a decrease in the collagen deposition and inflammation than that in CCl_4 group (400 \times).

the treatment of liver fibrosis.

Results obtained in the present work indicate that CCl_4 induced histological and biochemical alterations. Con-

cerning the histological effects, liver of CCl_4 -treated animals showed many degenerative changes including cytoplasmic vacuolization of the hepatocytes, fatty infiltrations, leucocytic infiltrations, congestion of blood vessels, and fibrosis. Similar results were obtained by Sakr et al. (2011) in albino rats intoxicated with CCl_4 . Moreover, the current results are in accordance with Sreelatha et al. (2009) who reported that liver injury, including marked alteration of the entire liver structures, with degenerative changes, were observed after CCl_4 administration. CCl_4 causes an elevation in the serum marker enzymes ALT, AST and ALP, since liver damage releases these enzymes in the blood circulation after the administration of hepatotoxin; such as CCl_4 (Kew, 2000). The toxicity of CCl_4 is initiated by formation of a reactive metabolite trichloromethyl radical which binds covalently to the macromolecules and induces peroxidative degradation of membrane lipids of endoplasmic reticulum rich in polyunsaturated fatty acids. This peroxidative degradation of membrane lipids leads to the formation of lipid peroxides which probably causes damage to cell membrane (Cabre et al., 2000; Kandasamy et al., 2010).

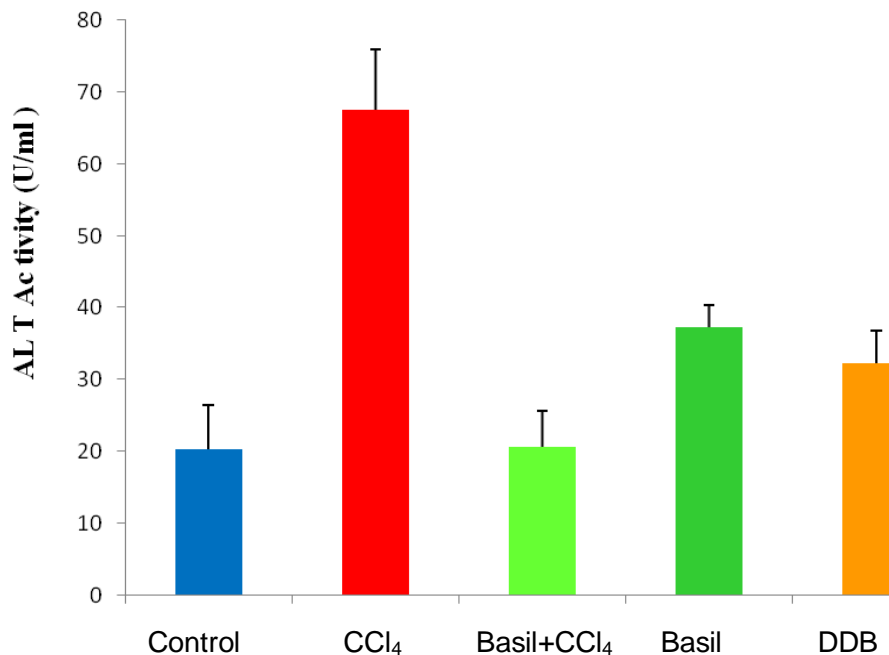


Figure 6. Activities of ALT (U/ml) in different experimental groups.

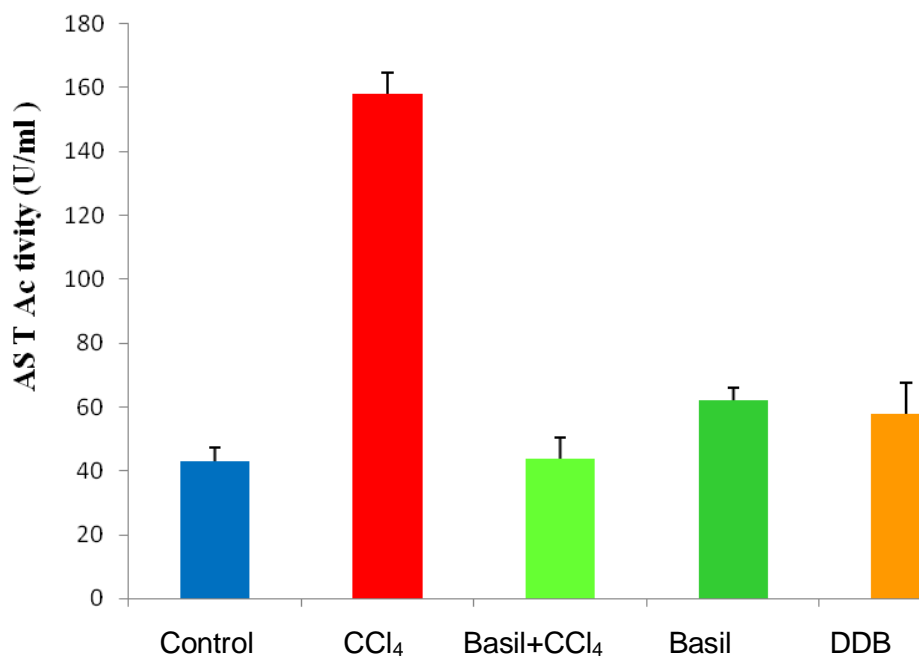


Figure 7. Activities of AST (U/ml) in different experimental groups.

The present findings demonstrate that basil improved the histological changes and increased liver function enzyme activity induced by CCl₄. This indicates the effectiveness of basil in the prevention of CCl₄ hepatotoxicity. The hepatoprotective effects of basil have appeared in the study on experimental liver damage by Sakr et al. (2011) who proved that basil suppressed hepatic fibrosis

and protected liver against parenchymal damage induced by CCl₄. In addition, the obtained data indicate that induction of liver fibrosis in rats by CCl₄ caused a significant decrease in serum albumin and a significant increase in total protein; they are clinically useful markers of hepatic synthetic function (Friedman et al., 1996). This result is in agreement with a previous study by Ravanshad et al.

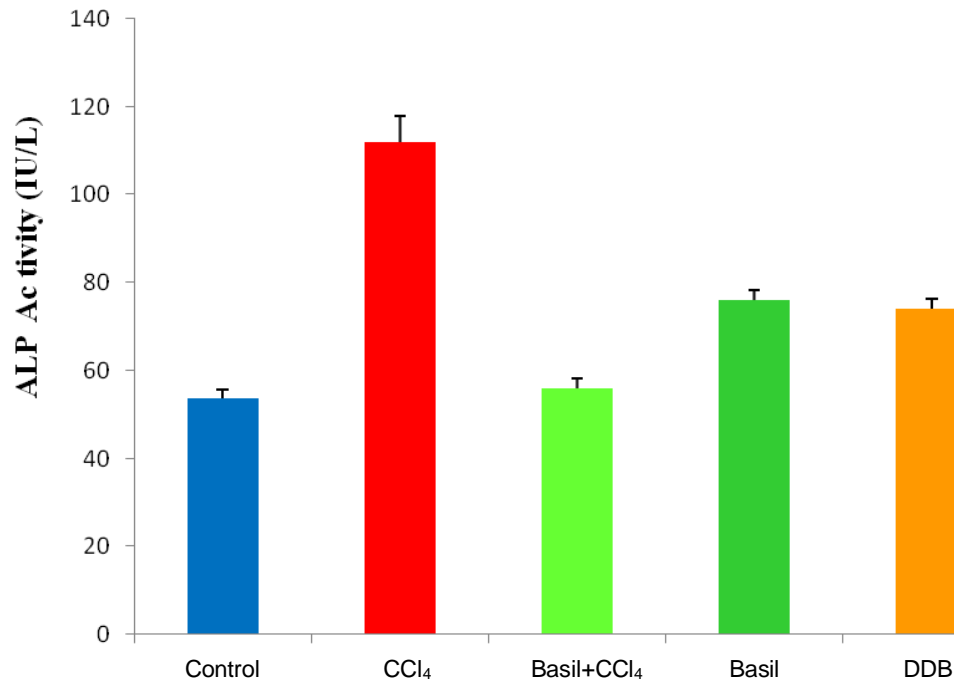


Figure 8. Activities of ALP (IU/L) in different experimental groups.

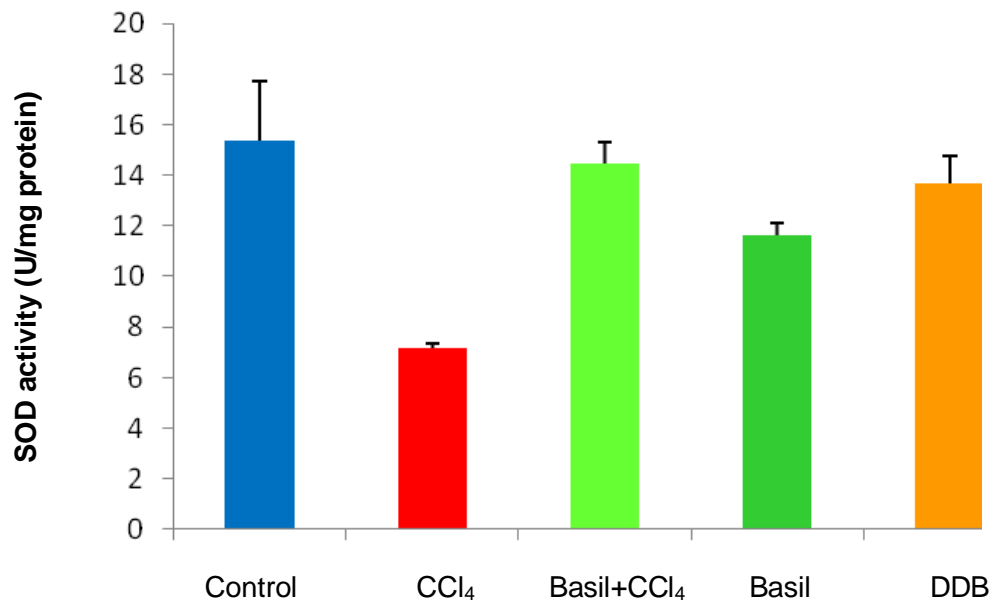


Figure 9. Activity of hepatic SOD in different experiment groups.

(2005). They reported that patient with non alcoholic fatty liver disease showed an increase in serum globulin.

Protection and treatment with basil remitted the decreased serum albumin and the increase in total protein because basil could ameliorate the decline of liver hepatocytes synthetic function caused by CCl₄ (Wen-Chuan and Wei-Lii, 2006). In addition, the basil treatment

clearly controlled the increase in serum levels of urea and creatinine, thus ameliorating the impairment of kidney functions caused by the CCl₄ induction.

Administration of DDB, after CCl₄ treatment, showed a significant decrease in liver enzyme activities that were elevated by the action of CCl₄, and remitted the levels of albumin and total protein. These results indicated the

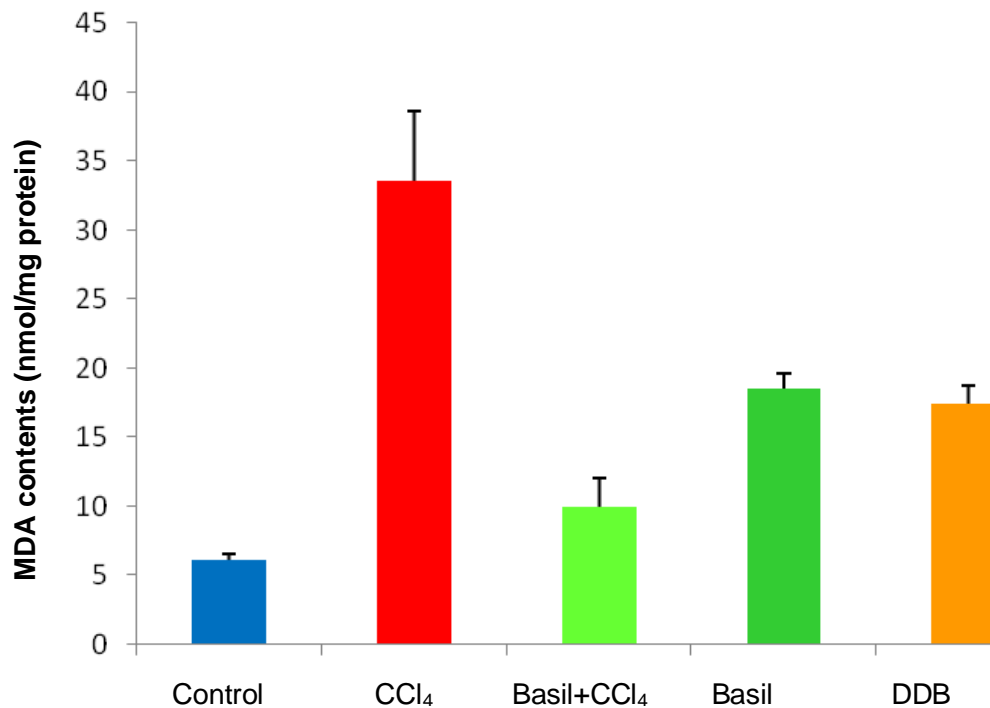


Figure 10. Hepatic MDA (nmol/mg protein) in different experimental groups.

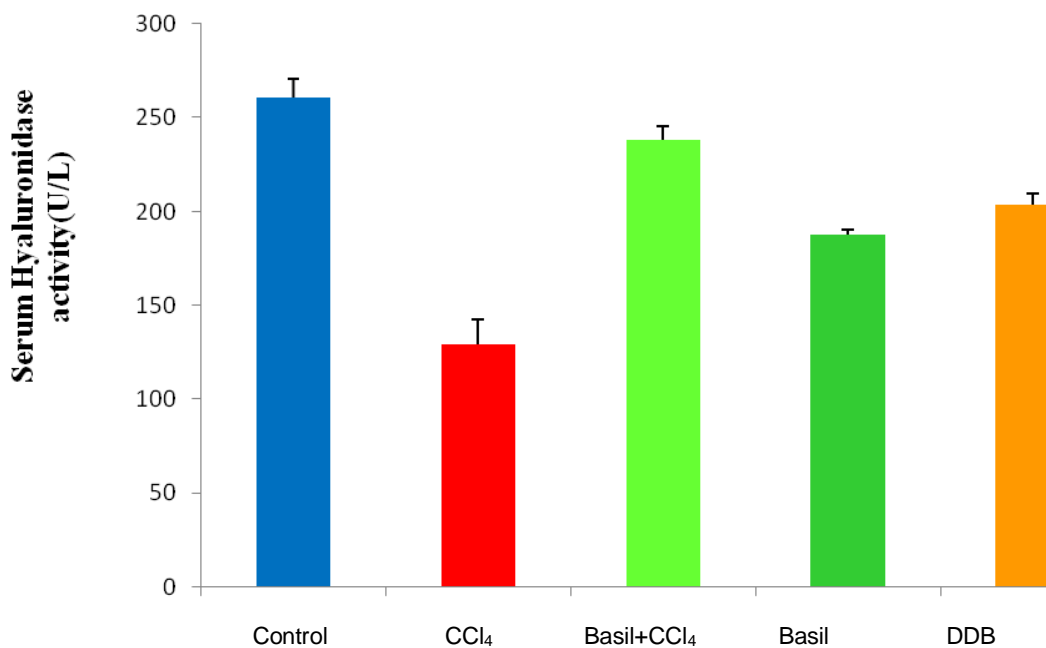


Figure 11. Activities of serum hyaluronidase (U/L) in experimental rat groups.

efficacy of DDB as an anti-inflammatory liver cell agent in induced liver damage. On the other hand, impairment in renal functions caused by CCl₄ was demonstrated by a reduction in the levels of urea and creatinine. Moreover, findings are in concordance with the results proving that

DDB is of a beneficial effect on damaged liver resulting from CCl₄ administration (Wasfy et al., 2011).

Oxidative stress is a state of redox imbalance caused by increased reactive oxygen species (ROS) generation and decreased antioxidant capacity. Administration of CCl₄ is an

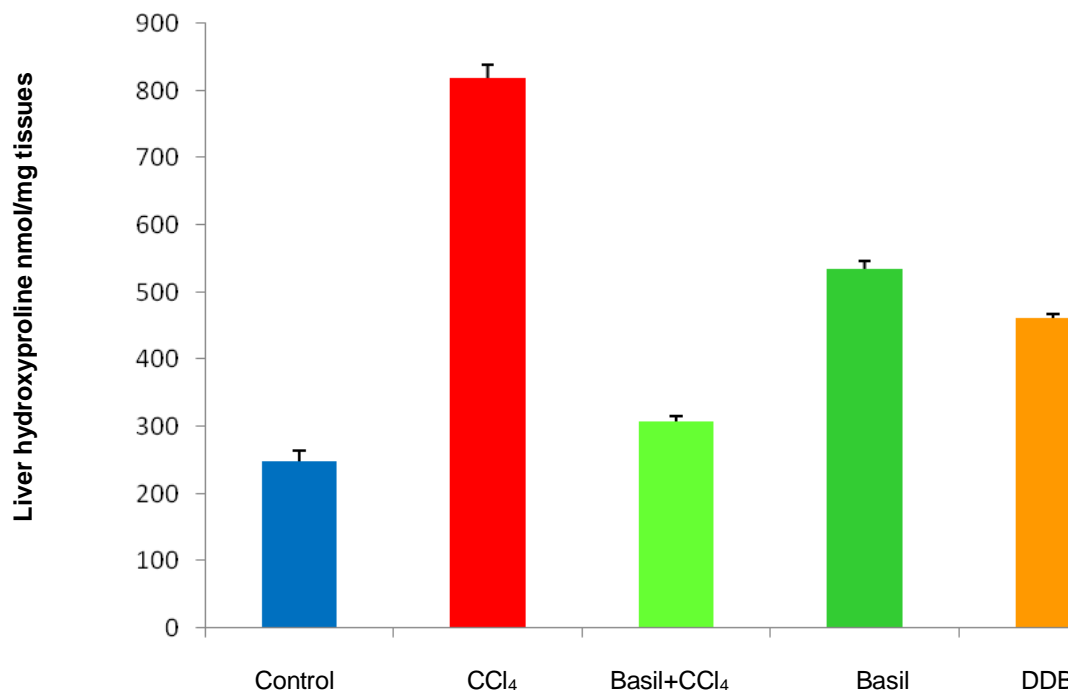


Figure 12. Hepatic hydroxyproline (nmol/mg tissues) in experimental rat groups.

Table 1. Mean value \pm SD of the measured serum parameters of experimental rat groups.

Group	Total Protein (g/dl)	Albumin (g/dl)	Urea (mg/dl)	Creatinine (mg/dl)
Control (I)	6.326 \pm 0.198 ^c	3.930 \pm 0.178 ^c	22.228 \pm 1.209 ^a	0.594 \pm 0.009 ^a
CCl ₄ (II)	7.648 \pm 0.154 ^a	3.148 \pm 0.107 ^a	57.790 \pm 5.916 ^{bb}	0.990 \pm 0.131 ^b
Basil + CCl ₄ (III)	6.474 \pm 0.166 ^c	4.040 \pm 0.100 ^c	27.998 \pm 1.674 ^a	0.566 \pm 0.021 ^a
Basil (IV)	6.450 \pm 0.208 ^c	3.226 \pm 0.107 ^b	22.700 \pm 2.026 ^a	0.608 \pm 0.030 ^a
DDB (V)	6.414 \pm 0.199 ^c	3.706 \pm 0.304 ^c	22.158 \pm 1.347 ^a	0.596 \pm 0.038 ^a

Values are mean \pm SD of seven rats per group. Mean values in each column having different superscript (a, b, c) are significant; $p < 0.001$.

established experimental model of severe toxic liver injury involving generation of oxidative stress (Abd El-Ghany, 2006). A decrease in the level of antioxidant enzymes and an increase in lipid peroxidation level were recorded after CCl₄ administration (Campo et al., 2004). The present findings demonstrate the effectiveness of basil in the prevention of CCl₄ hepatotoxicity by enhancing the activity of liver SOD and reducing liver MDA contents. This may be attributed to the presence of numerous compounds with high antioxidant activities that scavenge the produced superoxide anion and hydroxyl radicals (Dasgupta et al., 2004).

Basil is a rich source of flavonoids, which have been shown to possess various biological properties related to antioxidant mechanisms. Sakr et al. (2011) concluded that the hepatoprotective effect of *O. basilicum* may be attributed to the antioxidant activity of its flavonoids. Lee and Scagel (2009) reported that the presence of chicoric acid was the major phenolic compound in basil leaves.

Our results show that DDB has a strong scavenging effect against active oxygen radicals by decreasing levels of MDA, an indicator of lipid peroxidation, and by increasing the activity of liver SOD. These results are in agreement with that reported by Wassfy et al. (2011).

Serum hyaluronate (HA) and hyaluronidase (HAase) are considered markers of toxic liver injury, as confirmed by George and Stern (2004). Previous reports also showed that the HA concentration significantly increased in chronic diseases of the liver of different etiology. This is due not only to a greater hepatic production but also to a decrease in its degradation by hyaluronidases enzymes (Fraser et al., 1997). Our results show that the basil extract or DDB significantly reduced the content of hyaluronic acid (HA) by increasing the activity of hyaluronidases (HAase). These findings indicate that both basil and DDB can remit the action of liver fibrosis. These results were supported earlier by the fact that HAase activity decreased in proportion to the severity of liver disorders

(Abdelfattah et al., 2006). Also, the increase of HAase activity by basil extract may be due to the inhibition of serum inhibitors of HAase (Mio et al., 2000).

The accumulation of collagen in the liver is the primary hallmark of hepatic fibrosis (Bissel et al., 1990). Science hydroxyproline is the main characteristic compound in collagen; the amount of collagen can be reflected by assay of hydroxyproline and can be used to express the extent of fibrosis (Hanuske-Abel, 1996). When CCl_4 was applied in this experiment to induce liver fibrosis, the level of hydroxyproline in liver significantly increased. Basil and DDB were found to be useful for repairing hepatic fibrosis. Improvement of fibrotic changes in the liver and promoting liver regeneration in fibrotic rats were confirmed by the marked reduction of hydroxyproline deposition in hepatocytes, and the free radicals stimulate the synthesis of collagen as well (Parola and Robino, 2001).

The antifibrotic effect of basil may be referred to its antioxidant activity that relate to the presence of flavonoids and rosmarinic acid in the extract (Salmah et al., 2005). Rosmarinic acid reduced the conversion of hepatic stellate cells into myofibroblasts and down-regulated the gene expression of extracellular matrix components necessary for fibrosis (Salmah et al., 2005). The improving effect of DDB highly depended on the suppression of hepatic stellate cells activation which is responsible for the deposition of collagen fibers in the liver and the repairing of both structure and function of damaged hepatocytes (Xu et al., 1997). Further pharmacological and chemical investigations are required to elucidate the exact mechanism of action of this extract and to isolate the active principles responsible for such effects.

Conclusion

The aqueous ethanol extract of basil has a potent hepatoprotective effect on CCl_4 -induced hepatic fibrosis which controlled all tested parameters except hydroxyproline, and that is possibly due to its antioxidant effect and free radical scavenging properties. In addition, both basil and DDB have an ameliorative effect on the treatment of fibrotic rats.

ACKNOWLEDGEMENT

We would like to thank the Department of Biochemistry, Faculty of Science, Alexandria University for providing us with all the necessary facilities to complete this work.

REFERENCES

Abdelfattah MA, El-Shahat AT, Ahmad ME, Mosaad AA, Mohamed MO, Gamal ES (2006). Discriminant function based on hyaluronic acid and its degrading enzymes and degradation products for differentiating cirrhotic from non-cirrhotic liver-diseased patients in chronic HCV infection. *Clinica. Chimica. Acta.* 369:66–72.

Abd El-Ghany MA (2006). Nutritional effects of garlic, olive, parsley and menthe oils on CCl_4 induced liver damage in rats. *Egyptian. J. Nutr.* 21(4):125-159.

Bass NM (1999). Is there any use for nontraditional or alternative therapies in patients with chronic liver disease?. *Curr. Gastroenterol. Rep.* 1:50-56.

Batra M, Gupta RP (2006). Effects of *Ocimum sanctum* leaf on pathology and immune response in chickens experimentally infected with hydropericardium syndrome. *J. Indian Vet. Pathol.* 30:4750-4758.

Bissel DM, Friedman SL, Maher JJ, Roll FJ (1990). Connective tissue biology and hepatic fibrosis: report of a conference. *Hepatology* 11:488–498.

Bozin B, Mimica-Dukic N, Simin N, Anackov G (2006). Characterization of the volatile composition of essential oils of some lamiaceae spices and the antimicrobial and antioxidant activities of the entire oils. *J. Agric. Food Chem.* 54:1822–1828.

Cabre M, Camps J, Paternain JL, Ferre N, Joven J (2000). Time-course of changes in hepatic lipid peroxidation and glutathione metabolism in rats with carbon tetrachloride-induced cirrhosis. *Clin. Exp. Pharmacol. Physiol.* 27(9):694-699.

Campo MG, Avenoso A, Campo S, Ascola A, Ferlazzo MA, Calatroni A (2004). The antioxidant and antifibrogenic effects of the glycosaminoglycans hyaluronic acid and chondroitin-4- sulphate in a subchronic rat model of CCl_4 - induced liver fibrogenesis. *J. Chem. Biol. Interact.* 148(3):125-138.

Das SK, Vasudevan DM (2007). Alcohol induced oxidative stress. *Life Sci.* 81(3):177-187.

Dasgupta T, Rao AR, Yadava PK (2004). Chemo-modulatory efficacy of basil leaf (*Ocimum basilicum*) on drug metabolizing and antioxidant enzymes, and on carcinogen-induced skin and forestomach papillomagenesis. *Phytomedicine* 11(2-3):139–51.

Fraser JRE, Laurent TC, Laurent UBG (1997). Hyaluronan: its nature, distribution, functions and turnover. *J. Internal Med.* 242(1):27-33.

Friedman LS, Martin P, Munoz SJ (1996). Liver function tests and the objective evaluation of the patient with liver disease. In: Zakim D, Boyer TD (Eds.), *Hepatology: a textbook of liver disease*, 3rd ed. WB Saunders, Philadelphia: p. 791.

George J, Stern R (2004). Serum hyaluronan and hyaluronidase: very early markers of toxic liver injury. *Clinica. Chimica. Acta.* 348:189–197.

Hanuske-Abel HM (1996). Fibrosis: representative molecular elements, a basic concept and emerging targets for suppressive treatment. In: Zakim D, Boyer TD (Eds.), *Hepatology: A Textbook of Liver Disease*. W.B. Saunders Company, Philadelphia, pp. 465–506.

Hicham H, Mohammed A, Souliman A (2009). Sweet basil (*Ocimum basilicum* L.) improves lipid metabolism in hypercholesterolemic rats. *J. Clin. Nutr. Metab.* 4:181-186.

Kandasamy CS, Shimna TP, Mohammed BE, Arul RP, Gopal V, Venkatnarayanan R (2010). Anti-hepatotoxic activity of polyherbal formulation in carbon tetrachloride induced toxicity in rats. *RJPBCS.* 1:342-346.

Kew MC (2000). Serum aminotransferase concentration as evidence of hepatocellular damage. *Lancet.* 355:591.

Kim SN, Kim SY, Yim HK, Lee WY, Ham KS, Kim SK, Yoon MY (1999). Effect of dimethyl-4, 4'-dimethoxy-5, 6, 5', 6' dimethylenedioxybiphenyl-2, 2'- dicarboxylate (DDB) on chemical-induced liver injury. *Biol. Pharm. Bull.* 22:93-95.

Lee J, Scagel CF (2009). Chicoric acid found in basil (*Ocimum basilicum* L.) leaves. *Food Chem.* 115:650–656

Masahiko K, Bing Q, Tailin CUI, Atsuhide H, Saburo Y, Masahide O, Mitsuhiro M, Shojiro K, Yutaka N. (2002). Effect of sho-saiko-to extract on hepatic inflammation and fibrosis in dimethylnitrosamine induced liver injury in rats. *Biol. Pharm. Bull.* 25:1417-1421.

Mio K, Carrette O, Maibach HI, Stern R (2000). Evidence that the serum inhibitor of hyaluronidase may be a member of the inter-alpha-inhibitor family. *J. Biol. Chem.* 275:32413–32421.

Ohkawa H, Nobuko O, Kunio Y (1979). Assay for lipid peroxides in animal tissues by thiobarbituric acid reaction. *Anal. Biochem.* 95:351-358.

Park EY, KI SH, KO MS, Kim CW, Lee MH, Lee YS, Kim SG (2005). Garlic oil and DDB comprised in a pharmaceutical composition for the treatment with viral hepatitis, prevents acute liver injuries potentiated by glutathione deficiency in rats. *Chemico-Biological Interact.* 155:82–96.

- Parola M, Robino G (2001). Oxidative stress-related molecules and liver fibrosis. *J. Hepatol.* 35:297-306.
- Parola M, Leonarduzzi G, Biasi F, Albano E, Biocca ME, Poli G, Dianzani MU (1992). Vitamin E dietary supplementation protects against carbon tetrachloride-induced chronic liver damage and cirrhosis. *Hepatology* 16:1014–1021.
- Patiyal SN, Katoch SS (2006). Tissue specific and variable collagen proliferation in swiss albino mice treated with clenbuterol. *Physiol. Res.* 55:97-103.
- Ravanshad S, Amirkalali B, Saberfirozi M, Zare N, Setoudeh M (2005). Therapeutic effects of restricted diet in obese patients with non-alcoholic fatty liver disease (naflid). *Pak. J. Med.* 21(4):472-475.
- Reissig JL, Strominger JL, Leloir LF (1955). A modified colorimetric method for the estimation of N-acetylamino sugars. *J. Biol. Chem.* 217:959-966.
- Rivera CA, Bradford BU, Hunt KJ, Adachi Y, Schrun W, Koop DR, Burchardt ER, Rippe RA, Thurman RG (2001). Attention of CCl4 – induced hepatic fibrosis by GdCl3 treatment or dietary glycine. *Am. J. Physiol. Gastrointest. Liver Physiol.* 282:G200-G207.
- Rupert T (2009). Cooking with fresh herbs and spices can boost immune systems, reduce cholesterol, and help protect against cancer. *Med. J. Australia* 361:264-270.
- Sakr SA, El-Abd SF, Osman M, Kandil AM, Helmy MS (2011). Ameliorative Effect of Aqueous Leave Extract of *Ocimum basilicum* on CCl4 - Induced Hepatotoxicity and Apoptosis in Albino Rats. *J. Am. Sci.* 7(8):116-27.
- Salmah I, Mahmood AA, Sidik K (2005). Synergiistic effects of alcoholic extract of sweet basil (*Ocimum basilicum* L.) Leaves and honey on cutaneous wound healing in rats. *Int. J. Mol. Med. Adv. Sci.* 1:220-224.
- Samudralwar DL, Garg AN (1996). Minor and trace elemental determination in the Indian herbal and other medicinal preparations. *Biol. Trace. Elem. Res.* 54:113-21.
- Sharma MK, Kumar M, Kumar A (2002). *Ocimum sanctum* leaves extract provides protection against mercury induced toxicity in Swiss albino mice. *Indian J. Exp. Biol.* 40:1072–1082.
- Sies H (1993). Strategies of antioxidant defense. *Eur. J. Biochem.* 215:213-219.
- Sood S, Narang A, Dinda S, Maulik K (2005). Chronic oral administration of *Ocimum sanctum* Linn. augments cardiac endogenous antioxidants and prevents isoproterenol-induced myocardial necrosis in rats. *J. Pharm. Pharmacol.* 57:127-133.
- Sreelatha S, Padma PR, Umadevi M (2009). Protective effects of Coriandrum sativum extracts on carbon tetrachloride-induced hepatotoxicity in rats. *Food Chem. Toxicol.* 47:702-708.
- Stefan M, Gudrun M (1974). Involvement of the superoxide anion radical in the autoxidation of pyrogallol and a convenient assay for superoxide dismutase. *Eur. J. Biochem.* 47:469-474.
- Vats V, Yadav SP, Grover JK (2004). Ethanol extract of *Ocimum sanctum* leaves partially attenuates streptozotocin-induced alterations in glycogen content and carbohydrate metabolism in rats. *J. Ethnopharmacol.* 90:155-160.
- Wassfy AA, Ellaithy HM, Hamza YE, Arbid, MS, Osman AH, Kandil SM (2011). Therapeutic and Protective Effects of Biphenyl Dimethyl Dicarboxylate (DDB) and Silymarin in Human Infected with HCV and in Carbon Tetrachloride Induced Hepatitis in Rats. *J. Am. Sci.* 7:352-364.
- Wen-chuan L, Wei-Lii L (2006). Ameliorative effect of ganoderma lucidum on carbon tetrachloride induced liver fibrosis in rats. *World J. Gastroenterol* 12:265-270.
- Wei YH, Jun L, Qiang CJ (2004). Effect of losartan, an angiotension II antagonist, on hepatic fibrosis induced by CCl4 in rats. *Dig. Dis. Sci.* 49:1589-1594.
- Xu Q, Lu J, Wang R, Wu F, Cao JCX (1997). Liver injury model induced in mice by a cellular immunologic mechanism study for use in immunopharmacological evaluation. *Pharmacol. Res.* 35:273-287.