

Herellea corneal ulcer associated with the use of soft contact lenses

R. W. HERBST

Eye and Ear Infirmary, University of Illinois Hospital, Chicago, Illinois

The use of hydrophilic contact lenses has recently been recommended in a variety of pathological conditions. The results have so far been encouraging, but large series with reports of complications as well as of success rates have not yet appeared. The following case represents an instance of corneal abscess caused by a usually nonpathogenic organism in association with the use of a soft contact lens.

Case report

A 60-year-old white male underwent bilateral intracapsular lens extractions in 1960. Because of the development of Fuchs's endothelial dystrophy and bullous keratopathy, an 8-mm. penetrating keratoplasty was performed on the more severely involved left eye in 1968. Postoperatively, the patient developed a probable homograft reaction with a localized area of endothelial degeneration. Progression of this complication was controlled with the use of topical steroids, but an area of epithelial oedema with bullae later developed over the site of the degenerated endothelium. The patient complained of intractable glare and coloured haloes, although the visual acuity in the left eye was 20/40. Because of the failure of conventional medical management to control the symptoms, a standard, hard, methylmethacrylate contact lens was tried, but was not well tolerated. A soft contact lens made of polyhydroxyethyl methacrylate was then tried and a good fit was achieved on a trial lens basis without keratometer readings. The patient sterilized the lens each morning by boiling it in isotonic saline for 15 minutes, and the lens was worn all day and all night. Prophylactic antibiotic drops were not used.

After several months of comfortable wear, however, the patient complained of a red and painful left eye.

Examination

There was moderate to severe conjunctival and circumcorneal injection, and the cornea showed a deep central abscess with many large, frond-like vessels sweeping centrally from the limbus (Figure).

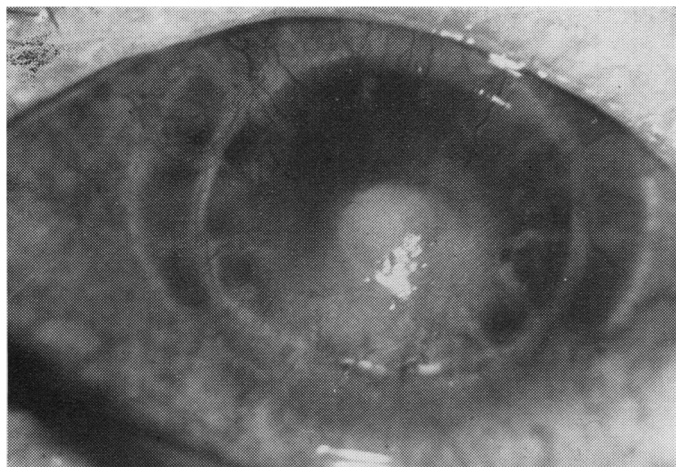


FIGURE *Appearance of corneal abscess before treatment.*

The anterior chamber was deep, and no hypopyon was noted, but further accurate ocular examination was impossible because of the corneal pathology. The visual acuity was reduced to hand movements.

The aphakic right eye showed a clear cornea with moderate central cornea guttata. The vitreous face was intact and the fundus was normal; the visual acuity was 20/20.

Diagnosis

A presumptive diagnosis of infectious corneal abscess of the left eye was made.

Investigations

Initial Gram-stain and KOH preparation showed no pathogens. Cultures were then obtained from the abscess itself, and the contact lens case, containing water, was also cultured. The corneal cultures grew many *Herellea vaginocola* and a few coagulase-negative staphylococci. The contact lens case also grew many *Herellea*, which had the same sensitivities as the organism in the cornea. The organism showed the characteristics noted in Tables I and II.

Table I Antibiotic sensitivity of *Herellea* cultured from cornea and contact lens case

Tetracycline	Sensitive
Kanamycin	Sensitive
Keflin	Resistant
Penicillin	Resistant
Ampicillin	Resistant
Nitrofurantoin	Sensitive

Table II Characteristics of *Herellea* cultured from cornea and contact lens case

Test	Result
Glucose metabolism	+
Lactose metabolism	+
Citrate metabolism	+
Oxidase	—
Nitrate reduction	—
Pigment	—
Motility	—

Treatment

The patient was given injections of Loridine beneath Tenon's capsule and topical chloramphenicol.

Because of the apparent resistance to cephalosporins, the patient was then given topical and intramuscular gentamicin. A gradual favourable response was noted, and the patient was discharged on topical medications only.

Result

The patient has not had any medication for the past 3 months. The left eye is now quiet, but a central stromal scar persists in the cornea. The visual acuity is 20/200.

Discussion

Soft contact lenses similar to those used by this patient have given encouraging results in a variety of pathological conditions (Gasset and Kaufman, 1970; Liebowitz and Rosenthal, 1971a,b). The absence of infections and other complications was specifically noted by Liebowitz and Rosenthal (1971a,b). The use of these lenses may, however, in some cases, induce an alteration of the normal corneal milieu and a lowering of corneal resistance to exogenous infection. This may occur more readily when one is dealing with already debilitated corneae. A review of the recent medical literature has shown many instances of altered host susceptibility resulting in infection with organisms that are usually innocuous (Amoury, Bowman and Malm, 1966; Darrell and Garrod, 1969; Richardson, 1969).

A common denominator in many of these instances is the use or implantation of foreign materials by the physician (Amoury and others, 1966; Darrell and Garrod, 1969).

In this case of corneal abscess, the usually nonpathogenic *Herellea* was found to be the probable aetiological organism; it is a Gram-negative diplobacillus, which can easily be confused with *Neisseria gonorrhoeae* on Gram staining. The genus *Mimae*, of which *Herellea* is a member, has been implicated in a variety of human infections, often in predisposed hosts (Richardson, 1969; Reynolds and Cluff, 1963). *Herellea* has been cultured by Thygeson and Kimura (1963) and Taplin, Rebell, and Zaias (1963) from a variety of sites in the human body, including the skin and the normal conjunctiva. Kenner and Kabler (1956) found that, like *Pseudomonas*, the organism grows well in water. Reynolds and Leighton (1963) found that it was frequently resistant to penicillin.

Thygeson and Kimura (1963), Burns and Florey (1963), and Canby (1968) have implicated *Herellea* in some cases of conjunctivitis, both acute and chronic. Furthermore, Canby (1968) reported it as a cause of purulent neonatal conjunctivitis which must be distinguished from that due to *Neisseria*. No previous case has apparently been reported in which this organism was felt to be the cause of corneal disease or abscess.

The route of infection in this patient is of some interest, particularly in view of the fact that the organism was cultured from the contact lens case. Although the patient boiled the lens each morning, his fingers might have been contaminated by the water in the contact lens case. Alternatively, the patient may be a normal carrier of the organism on the skin or in the conjunctival sac, and its presence in the contact lens case may have been due to autocontamination. Presumably, the bacteria invaded the cornea only after an alteration in the host-organism relationship.

Although generalizations cannot be drawn from single cases, it seems significant that this report of corneal infection in association with the use of hydrophilic lenses implicates an organism that is usually harmless. It is apparent that further studies are required to define more accurately the therapeutic indications for soft contact lenses, and ophthalmologists must remember the possible complications.

Summary

A case is reported of a corneal abscess associated with the use of soft contact lenses in bullous keratopathy. *Herellea vaginocola*, the organism implicated, has not previously been reported to cause corneal disease. Further evaluation of the possible complications that may attend the use of soft contact lenses is deemed to be necessary.

References

- AMOURY, R. A., BOWMAN, F. O., and MALM, J. R. (1966) *J. thorac. cardiovasc. Surg.*, **51**, 36
 BURNS, R. P., and FLOREY, M. J. (1963) *Amer. J. Ophthalm.*, **56**, 386
 CANBY, J. P. (1968) *Med. J. Aust.*, **2**, 1104
 DARRELL, J. H., and GARROD, L. P. (1969) *Brit. med. J.*, **2**, 481
 GASSET, A. R., and KAUFMAN, H. E. (1970) *Amer. J. Ophthalm.*, **69**, 252
 KENNER, B. A., and KABLER, P. W. (1956) *J. Bact.*, **72**, 870
 LIEBOWITZ, H. M., and ROSENTHAL, P. (1971a) *Arch. Ophthalm. (Chicago)*, **85**, 163
 ———— (1971b) *Ibid.*, **85**, 283
 REYNOLDS, R. C., and CLUFF, L. E. (1963) *Ann. intern. Med.*, **58**, 759
 RICHARDSON, R. L. (1969) *J. Amer. med. Ass.*, **207**, 1716
 TAPLIN, D., REBELL, G., and ZAIAS, N. (1963) *Ibid.*, **186**, 952
 THYGESON, P., and KIMURA, S. J. (1963) *Trans. Amer. Acad. Ophthalm. Otolaryng.*, **67**, 495