

HERNIA INGUINALIS PERMAGNA - TO THE LIGHT

Andreea Ștefania Racoviță¹, D. N. Păduraru^{1,2}, R. M. Mirică^{1,3}, R. V. Iosifescu^{1,3}

¹The University of Medicine and Pharmacy “Carol Davila”, Bucharest, Romania

²3rd Department of General Surgery, The University Emergency Hospital, Bucharest, Romania

³The Department of General Surgery, “Saint John” Clinical Emergency Hospital, Bucharest, Romania

Corresponding author: Radu Mihail Mirica

Phone no: 0040740992324

E-mail: mirica_rm@yahoo.com

Abstract

Giant inguinal hernias are rare, accounting for only 2,8-5% of all inguinal hernias. Neither its exact etiology nor its treatment resemble a consensus, the main challenge being loss of domain. This is the first full review pertaining to this aspect, according to our knowledge. We performed a review of the English literature using PubMed/Medline, Oxford Journal, Elsevier and Springer libraries. The objective is to present an unbiased picture of giant inguinal hernia management and pitfalls. We found 60 articles that treat this condition, with only one death reported. Comparing between the procedures was difficult because the majority of the publications are case reports or small scale case series. Among the differences, there were some common patterns in view of the popularity of open procedures in both developed and severely limited settings, with a favor for Lichtenstein. Evolution analysis was interesting considering laparoscopic procedures and postoperative aims. Among adjunct procedures, preoperative pneumoperitoneum had the most sustained evolution. Preventing abdominal compartment syndrome and considering unexpected hernia sac contents represented an interesting issue. Acknowledging tissue-targeted gene therapies sets further goals. Elective giant inguinal hernia repair must address a well-planned individualized approach, based on all available evidence and experience. The key to success treatment is not strict adherence to any one technique.

Keywords: *giant inguinal hernia, loss of domain, laparoscopic, Lichtenstein, pneumoperitoneum*

Introduction

There are various rationales that claim to define giant inguinal hernias (GIH), generally known as those that extend below the midpoint of the inner thigh in the standing position [1]. Even though it is estimated that inguinal hernia repairs represent 10-15% of all surgical procedures GIH account for a rare magnitude of only 2,8-5% of all inguinal hernias, but along with a higher recurrence, are more demanding and challenging in the era of laparoscopic hernia surgery [2].

It is the void in the literature concerning the standard surgical procedure that provoked surgeons' imagination for the promiscuous techniques that have been reported. Regardless, this results in difficult decision-making entwined with a low number of surgeons experienced with their management. The lack of a complete explanation for hernia formation should perpetually represent a motivation.

Through evidence-based medicine, any hernia repair procedure must be carefully evaluated concerning its benefits and its risks. Benefits should be measured in clinical, social

and economic terms. Similarly, benefits are evaluated across the whole patient environment and across the whole health care system. It is no longer adequate to demonstrate that some procedures work.

The main management difficulty of these cases is that of returning herniated viscera to the abdominal cavity accustomed to being empty, also known as loss of domain. The high rate of mortality is clearly observed following forced reduction of GIH, as a result of abdominal compartment syndrome. Intraabdominal hypertension can immediately develop after reduction or later in the postoperative period due to ileus. Consequently, one should find a manner of preparing the peritoneal cavity for the reception of the hernia sac contents.

Considering the struggle with this serious disability in terms of social isolation, anxiety, low self-esteem, there might be more than the surgical approach to be done in order to help these patients. Bias could restrain insight to the full topic, because these cases are a true reflection of how limiting to a surgical approach alone can fail.

In the evaluation process, the surgeon needs to take into account some questions and considerations: (1) why does the patient have a recurrent inguinal hernia, (2) why would the repair that we perform be better than one chosen by the previous surgeon? and (3) re-operations are always more difficult than first-time inguinal hernia repair, and the complications are more common.

Materials and Methods

We have performed a review of the English language literature using PubMed/Medline, Oxford Journal, Elsevier and Springer libraries. As keywords we have used a combination of the following terms: 'hernia', 'inguinal', 'giant', 'massive', 'large'. Results regarding infants were excluded.

Objectives

Whereas surgeons searching for ideal treatment strategies are challenged by a vast diverse scientific literature, much of which is

difficult to interpret and apply to one's local practice environment, herein the objective is to evaluate the pitfalls regarding patients with GIH.

Results

We found 60 articles that treat this hypothesis, with only one death reported (during emergency operation, in an extremely obese dyspneic man with bilateral GIH with perforation [3]). The majority of publications on the subject are case reports and case series, making it difficult to compare between the procedures. There were many differences, but also some common patterns in view of the popularity of open procedures among both developed and severely limited settings, and also a favor for Lichtenstein (Table 1). There was no consensus regarding scrotoplasty.

Evolution analysis of the procedures shows how the perspective changed from the aim of no recurrence towards great concerns about the complication of chronic pain and wound-related problems. In addition, the initial consideration for laparoscopic approach as a contraindication is obsolete, as there is a contribution of few. Among adjunct procedures used to gradually accommodate the hernia contents into the abdominal cavity, preoperative pneumoperitoneum has withstood the test of time proving its usefulness. Iatrogenic incisional hernia repaired using mesh, myocutaneous flaps or peritoneal flaps are no longer used.

Moreover, acknowledging the process of herniation as a mechanical disparity may not be the case. Present concepts put forward the premise that hernia development is a biological process. Therefore, MMPs, gene therapy and radiological pelvimetry are to be discussed.

Discussions

Biology or surgery?

We are so pertinent to look on tendons, fascial structures, and connective tissues as passive structures when in fact metabolic aspects perpetuate further the limits of surgery [50].

In addition, small number of reports have suggested that in patients with inguinal hernia, certain pelvic anatomical traits characterized by the low position of the groin prevail, resulting in a marked verticality of the inguinal fold. Surgeons could use pelvimetry for the selection of patients who are more fitted for non-mesh repairs (small Radoievitch's angle, thus a low pubic height and smaller Fruchaud's area) such as the Shouldice technique and also radiological pelvimetry could be included in the preoperative planning of hernia repair, for being simple and accurate [46,51].

The literature on the inheritance of groin hernias indicates that groin hernia is most likely an inherited disease; however, neither the extent of familial accumulation nor a clear inheritance pattern has yet been found. In order to establish whether groin hernias are accumulated in certain families and to what extent, large register studies based on hernia repair data or clinical examinations are needed [48].

OPERATION	Author	Number of cases
TAPP (trans-abdominal preperitoneal)	[4]	1
Mc Vay (Cooper's Ligament)	[5]	4
Stoppa	[5-7]	5
Shouldice	[5,7,8]	11
Bassini	[5,9]	8
Lichtenstein	[5,10–18]	34
Postempski	[19]	1
Hug technique	[20]	3
ULTRAPRO Hernia system	[21]	1
TEP (totally extraperitoneal)	[22]	1
Ladd	[23]	1
Laparoscopic component separation technique	[24]	1
TIPP (trans-inguinal preperitoneal)	[25,26]	9
Nyhus	[6]	1
classic component separation technique	[27,28]	2
double modified Rives	[29]	1
Rives	[8]	4
ADJUNCT TECHNIQUES		
<i>Resection of the contents (debulking)</i>		
-omentectomy	[11,12,14,15,30,31]	
-left hemicolectomy	[32]	
-extended right hemicolectomy and splenectomy	[33]	
-extended right hemicolectomy	[9,14,21,34,35]	
-right hemicolectomy		
<i>Intra-abdominal volume increase procedures</i>		
PPP (<i>Preoperative progressive pneumoperitoneum</i>)	[6,7,18,26,28,31,33,35–41]	
<i>Abdominal wall surface increase</i>		
Iatrogenic incisional hernia repaired using myocutaneous flaps/ tensor fascia latae flaps/ peritoneal flaps/ mesh	[28,34,42,43]	
<i>Phrenicectomy</i>		
Elemental diet	[44]	
<i>OTHER?</i>		
<i>Botulinum toxin A</i>	[45]	
<i>Radiological pelvimetry</i>	[46]	
	[47-49]	
<i>MMPs (Matrix metalloproteinases)</i>	[48]	
<i>Gene therapy</i>		

Table 1 - Summary of the previous publications pertaining to giant inguinal hernia techniques presented in descending chronological order

Why is this still happening?

In part of Africa the normal incidence of inguinal hernia is as high as 175% per 100.000 people [52]. A noted aphorism is that in Africa there are only two types of hernias: above the knee and below the knee, also being more individuals with inguinal hernias than HIV-infected.

Delay in medical care may occur because of patient rejection of timely surgical management due to lack of knowledge or economic issues. Unfortunately, some patients are relatively neglected for the fear that the treatment may cause even greater risk than the hernia itself or even advised against it because of technical difficulties of a low resource setting [53]. For example, Sahsamani et al even reported in 2016 a case of half century old irreducible giant inguinal hernia repaired through a “V” shaped incision (lower midline and extended inguinal incisions connected) by suturing a double mesh on the posterior wall of the inguinal canal and the posterior wall of the rectus muscle, with uneventful evolution [54].

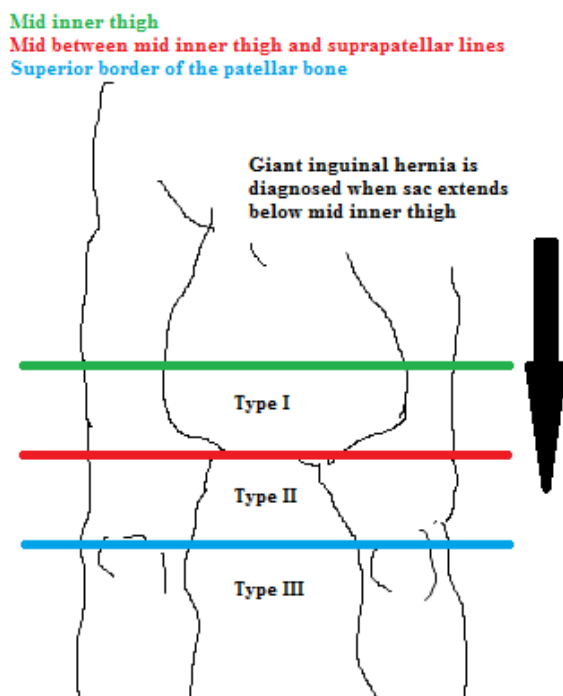


Figure 1 - New classification of giant inguinal hernia (after Trakarnsagna et al)

Risk factors like advanced age, cardiovascular or respiratory disease have an impact on both initial decision making and

postoperative recovery. The complexity of the repair, high recurrence rates and the attendant perioperative comorbid conditions, especially in morbidly obese patients does not inspire confidence, reluctance being justified by both the surgeon and the patient. The largest study to date correlating obesity and groin hernias analyzed 47,950 patients relative to body mass index and found that obesity is associated with a lower risk of groin hernia diagnosis, but the inverse relationship may be due to limitations of physical exam in obese patients [55]. Interestingly, obesity increases the probability of inguinal and hiatal hernias to occur together more often than expected by chance alone [56]. These results suggest that a common etiology may exist for both and support the theory that hiatal hernia is caused by an excessive push from increased intraabdominal pressure induced by inguinal hernia.

New classification of giant inguinal hernia and recommended procedure (after Trakarnsagna et al.)

Trakarnsagna et al categorized GIH into three types, according to the length of the scrotum from the mid inner thigh, while recommending an appropriate surgical approach (Figure 1). Therefore, hernioplasty with forced reduction is feasible for type I hernias, but intraabdominal and intrathoracic pressures must be closely observed. Most type II hernias require additional procedures rather than simple hernioplasty alone, except one reported case that addressed only a tension-free, onlay, prosthetic mesh repair [57]. In type III hernias, additional procedures are almost always needed in addition to forced reduction and simple hernioplasty [14].

But what it means loss of domain?

Concluding a definition for this issue may not be as obvious as thought. The volumetry of the abdominal cavity is the main indicator for loss of domain. It is imperative to obtain a native abdominal CT scan to evaluate the complexity of the abdominal wall defect. After a simple measurement of the volume of sac (VHS) and the volume of the abdominal cavity

(VAC), a reported VSH/VAC ratio higher than 25% is a good predictor for loss of domain [58].

Pertaining to the phenomena, the basic principle is that abdominal cavity adjusts to the viscera contained. Embryologically, the viscera enter and expand the abdomen. In GIH the reverse occurs, as viscera move into the hernia sac and the abdominal cavity shrinks. Due to retraction of the abdominal wall muscles and relaxation of the diaphragm, the viscera have forfeited the right of domicile.

Jack-in-the-box

The first abdominal content to find its way into the scrotal sac through a “locus minoris resistentiae” widens the neck of the sac, so that both inguinal orifices are enlarged and displaced at the same time. A large visceral mass, often having lost its right of domain, passes through the defect. Adhesions may develop rendering the hernia irreducible [13]. More abdominal contents can be forced into the sac: colonic frame, stomach, and exceptionally, ovaries, fallopian tube or kidney along with the ureter [58-60]. Also, cases of Amyand hernia may inspire prophylactic appendectomy [18]. As urinary bladder may reportedly at times occupy the medial portion of the sac, it is advisable and a safe practice to catheterize all such patients before commencing the surgical procedure [13]. On the other hand, some believe that it must be avoided because the area where the phallus is engulfed by the scrotal skin is colonized by bacteria [26].

Choosing the procedure

There is a consensus among inguinal hernia surgeon specialists that, if the patient had first-time hernia repair done by the anterior approach, no matter what the technique used, the recurrent inguinal hernia repair must be done through the preperitoneal approach and the usage of mesh is mandatory [6].

Obviously, the desiderata to speculate on are: solid repair, low morbidity and mortality rates, painless postoperative period, short hospital stay, inexpensive and easy to teach technique and feasibility of performing repairs by every surgeon [51].

Lichtenstein employs a total reinforcement of the inguinal floor using a suitable biomaterial. Alloplastic augmentations

and PPP are no competing, but complementary procedures.

This tension-free procedure is considered not only easy to perform, [12,18] but also has the advantage of a shorter recovery apart from laparotomy [17]. In a 2013 article, with a contribution of 15 cases, Bierca suggests that the choice for general anesthesia is dictated by the necessity to create optimal conditions of atonic abdominal wall and the predicted possibility of additional procedures [16]. Bowel preparation is recommended in all cases, associated with preoperative colonic evaluation, for debulking as a part of the treatment [14]. It is inadvisable to use a mesh if a bowel resection is performed.

As contents may be potentially difficult to reduce, there might be a tendency for a more forceful approach, in which case an intraabdominal pressure measurement may appear reasonable. Measurement of urinary bladder pressure can be a useful tool to identify patients with a higher risk of developing abdominal compartment syndrome [4,18].

The most frequent complications of this technique are: seroma, haematoma, local infection and neuralgia [5,16]. Regarding haematoma prevention, a closed drainage system proved successful in all cases with the exception of only one case [14]. Overzealous attempts of neat and careful separation of “misdiagnosed” adhesions can lead to harmful complications like faecal fistula or haematoma, which in the case of Lichtenstein may result in massive infection and dehiscence [13]. The role of antibiotic therapy in hernia repair using Lichtenstein technique is arguable and questioned by some authors [62,63], but most of them agree on the necessity [16,17].

Although recurrence rates are low, reconstruction of the abdominal wall using Marlex mesh and a tensor fascia latae flap to prevent recurrence was suggested [42]. The additional vascularized support over mesh not only strengthens the repairs, but also improves blood supply and protects the mesh.

Orchiectomy is an advantageous choice, for inguinal canal plasty is easier to perform and atrophic condition due to the remarkable length of the spermatic cord prone to torsion. Therefore, an informed consent is needed to

cover all possible operative procedures because final decision will be made intraoperatively.

ULTRAPRO Hernia system is a macroporous partially absorbable mesh designed for hernia repair. Maeda et al strengthened the posterior wall of the inguinal canal in two ways, by transversalis fascia underlay (as in laparoscopic repair) and anterior side of the inguinal canal onlay (as in Lichtenstein). This approach delivered significant reduction of pain, both short and long-term, versus conventional Lichtenstein [21].

Hug technique involves progressive reduction of the viscera without opening the sac. The key principle is that it is not necessary to detach the hernia content from the sac, but to reduce the “volume” of the content inside the jejunal-colonic loops so that they can “collapse” and be slowly reduced into the cavity. Cavalli et al successfully performed this technique in 3 of 5 cases, with no general or wound-related complications. Probably the first two cases should be included in learning curve. The reduction required about 1 h and along with scrotoplasty the mean surgery time was 332 min. Postoperative respiratory therapy was employed. This method permits avoiding the use of further specific procedures such as PPP [20].

Mc Vay, Shouldice and Bassini techniques are associated with high recurrence rates and more sequelae [29]. While Mc Vay principle is calibration of the internal inguinal ring, Bassini involves reconstruction of the canal's posterior wall in 3 layers. Low-resource settings where insufflation and prosthetic mesh are unavailable can benefit from this technique [5,9]. Suture line tension probably accounts for most recurrences after the Bassini repair. But, a review showed that literature sometimes describes operations that do not respect the original method. Therefore, the true Bassini method could be falsely afflicted with a relatively high recurrence rate [64]. The Shouldice repair can be thought of as a combination of a Bassini and McVay repair [65] and has the disadvantage of a longer learning curve than Lichtenstein, but the convenience for patients unsuitable for the use of mesh.

TEP approach may be an admired method for inguinal hernia repair, also an inviting

attempt, but still with seromas and haematomas common to see [22]. Gao et al shows that efficient drainage in preperitoneal space may effectively reduce the incidence of seroma after endoscopic TEP approach and it may be of vital significance especially in GIH and irreducible hernias [22]. Although mitigating postoperative pain, both TEP and TAPP have the disadvantages of long learning curve and being expensive.

TAPP was successfully used by Masato et al, achieving complete reduction of the contents within 2 h 50 min, following weigh reduction surgery, with no recurrence and only a loss of 700 ml of blood mainly due to the injury caused by the forceps when sought to reduce the incarcerated omentum. The clear advantage is not dissecting the hernia sac. There are some factors, along with pre-operative measures to prevent abdominal compartment syndrome, that contributed to the outcomes. Firstly, anticipating the reduction would be difficult, several options for reducing the contents of the hernia were prepared. Combining compression from outside of the body with pull from inside and additional use of ports is effective. Secondly, a large lightweight polypropylene mesh with an absorbable hydrogel barrier was used to cover all areas of potential hernia defects in the groin, while still providing margins of more than 3 cm from the defects [4]. Further studies are required to evaluate the feasibility of laparoscopic repair in the management of GIH.

TIPP approach consists in 2 inverted preperitoneal patches for deep inguinal ring repair, both medial and lateral. Applying the “Butterfly technique”, 7 patients with unilateral hernias showed uncomplicated and full recovery with no recurrence. This transinguinal preperitoneal approach excludes the hypothetical drawbacks of endoscopic procedures and does not imply any contact with the nerves in the inguinal canal or fixating sutures. Currently, a double blind prospective randomized trial is conducted to compare postoperative chronic pain after TIPP and Lichtenstein [25].

Double modified Rives, apart from the original technique, uses a very large unsplit prosthesis and parietalization of the spermatic cord helped by a wide opening of the Fruchaud's orifice, with epigastric vessels

diversion [29]. An advantage apart from TEP is of reduction in the vital laparoscopic risks and reinforcement of the wall by a short tension-free McVay technique. There is also no need to fix the prosthesis as in Lichtenstein, or to use fibrin or other types of expensive glues.

Nyhus technique was performed in unilateral hernia together with PPP, as loss of domain can jeopardize the results. Because the three apertures of the Fruchaud myopectineal orifice are well visualized and protected by the mesh, missed hernias are impossible to occur, with almost nil recurrence rates [6].

Preoperative Pneumoperitoneum was first reported regarding ventral hernias and subsequently employed for giant inguinal hernia repair. The concept refers to preoperatively ensure adequate room in the abdominal cavity before reduction of the hernial contents. While most authors preferred filtered ambient air [6,26,31,36,37], others chose CO₂, O₂ or NO [39,40].

The selected site for the insufflation should be well away from the hernia: linea semilunaris, left McBurney point or supra-/infra-umbilically. It was originally claimed that the first injections should be done cautiously as there may be some disturbances such as diffuse pain, nausea or pain in the shoulder (probably due to stretching of the suspensory ligament of the liver) that soon disappear, with tolerance for the latter insufflations. Intraoperatively, after the gas is released, the abdominal walls remain flaccid and contents are easily reduced, facilitating the closure. Interestingly, this process can gradually offer adhesiolysis. The disadvantage of the original procedure i.e. intermittent puncture for insufflation was excluded by the use of a double lumen catheter with an integrated antibacterial filter. Also, ultrasonographic or CT-guided insertion replaced earlier procedure done with the Veress needle, thus excluding the risk of visceral lesions [37].

Depending on the author, the process lasts 6-60 days, and the maintained volume can be 5000-15000 ml, relative to the conscious and alert patient reactions, with close observation for peritoneal irritation and slight respiratory distress. Thus, prolonged preoperative stay is a limitation. Using reconstruction of the abdominal surface by 3D stereography, a

constant abdominal circumference for two days may suggest process completion [38]. This indicates that a correlation between the abdominal expansion and the gas volume and pressure exists only in the first few days, ultimately becoming limited. It is generally considered that a patient who does not tolerate PPP insufflation well will also not tolerate the definitive surgical repair well. The insufflation of 500 ml of air may be the best way to determine candidates and exclude patients with limited cardiac or pulmonary reserves [7].

Vital capacity does not decrease neither during nor after the intervention. PPP leads to an increase of the intraabdominal pressure, thereby causing elevation of the diaphragm with restitution of its physiological tension and function [38]. This suggests a progressive recruitment of unused thoracic muscles for breathing with consequent improvement of respiratory mechanics.

While some authors aborted the procedure due to expansion of the thin scrotal sac only, with minimal effect on the scarred and contracted abdominal cavity, others suggest that the less compliant skin and hernial sac have a limited capacity even when they are stretched, and additional air preferentially stretches the diaphragm and the abdominal wall [40]. At the same time, the advantage is unmasking additional areas of fascial weakness and potential sites of recurrent herniations [7].

PPP is considered an indication regarding obese individuals [26] or in developing countries where medical facilities are limited [5], but should not be performed in patients with abdominal or scrotal infection, decompensated respiratory or cardiac function, small neck of the hernia or incarcerated hernias. Complications like infections of the catheter site, air embolism, deep vein thrombosis, or mediastinum and pericardium emphysema are rare. Subcutaneous emphysema prevails, maybe due to injection of air directly into the subcutaneous tissue or percolation [37].

With only two cases of technical failure, PPP avoids the abdominal compartment syndrome and is a successful adjunct in re-establishment of the right of domain [28,35].

Debulking methods are performed at the price of anastomotic leak or prosthetic infection. The limitation is difficulty to justify in a patient

with viable bowel and the changing of bowel function [17].

Elemental diet shows a decrease in visceral volume of approximately 2 liters over a period of 1 month through diminishing intestinal secretions and faecal volume, but the efficacy in extremely large hernia remains questionable [44].

Scrotoplasty or not?

As sometimes the scrotal retraction may be insufficient or absent, there is a case of GIH where the massive scrotal skin and hypertrophic dartos muscle were excised in toto to prevent development of scrotal haematoma or lymphedema [35]. One should exercise caution in excising, for the skin is usually oedematous and is likely to shrink postoperatively. The excision should be addressed as a primary or delayed procedure depending on the clinical status of the patient.

On the contrary, some surgeons believe that preserving all the redundant skin can serve as a safety net. If the repair fails in the early postoperative period, or in case of severe respiratory compromise, the bowel can be temporally returned to the scrotum [42]. At the same time, retraction of the scrotal skin by dartos muscle contraction is often seen [30].

What next?

Understanding the role of the equilibrium between MMPs and their inhibitors in collagen metabolism has now shed some light over the chronic degenerative aspect inguinal hernia, aiming reasons for failure of repair. MMPs comprise a family of zinc endopeptidases that play a role in physiological and pathological destruction of connective tissue and that show an optimal enzymatic activity at neutral pH [66]. The idea is supported by the fact that genetic connective tissue disorders have been associated with hernial processes [67]. At the same time, collagen protein in the fascia latae located on the side of the hernia was shown to be excessively degraded in patients with inguinal hernia who did not have congenital connective tissue disorder [49].

Therapeutic trials testing the pharmacological use of MMP inhibitors have not yet been conducted for abdominal hernias, but promising results for aortic aneurism,

obesity, cancers and joint disorders are well known. There is a need for a large population-based prospective study to explore feasibility.

Acknowledging regulation mechanisms of MMP gene expression may direct therapeutic strategies toward tissue-targeted gene therapies with agents that selectively inhibit specific MMPs [48].

Conclusions

Elective giant inguinal hernia repair must presume well planned integrated approach. The key to success treatment is not strict adherence to any one technique.

More studies are needed to improve groin hernia patient care worldwide by developing and globally distributing guidelines of care based on all available evidence and experience.

References

- [1] D. J. Hodgkinson and D. C. McIlrath, "Scrotal reconstruction for giant inguinal hernias," *Surg. Clin. North Am.*, vol. 64, no. 2, pp. 307–13, Apr. 1984.
- [2] P. Primatesta and M. J. Goldacre, "Inguinal hernia repair: incidence of elective and emergency surgery, readmission and mortality," *Int. J. Epidemiol.*, vol. 25, no. 4, pp. 835–9, Aug. 1996.
- [3] Y. Chida, R. Inokuchi, Y. Kumada, and K. Shinohara, "A case of lethal giant inguinal hernia," *Clin. Case Reports*, vol. 4, no. 3, pp. 301–302, 2016.
- [4] M. Momiyama, F. Mizutani, T. Yamamoto, Y. Aoyama, H. Hasegawa, and H. Yamamoto, "Treatment of a giant inguinal hernia using transabdominal pre-peritoneal repair," *J. Surg. Case Reports*, vol. 2016, no. 9, p. rjw159, 2016.
- [5] R. Lebeau et al., "Management of Giant Inguinoscrotal Hernia in Resource Limiting Setting," *J. Gastrointest. Dig. Syst.*, vol. 6, no. 1, pp. 1–5, 2016.
- [6] J. C. Beitler, S. M. Gomes, A. C. J. Coelho, and J. E. F. Manso, "Complex inguinal hernia repairs," *Hernia*, vol. 13, no. 1, pp. 61–66, 2009.
- [7] S. Willis and V. Schumpelick, "Use of progressive pneumoperitoneum in the repair of giant hernias," *Hernia*, vol. 4, no. 2, pp. 105–111, Jun. 2000.
- [8] G. Sturniolo, A. Tonante, E. Gagliano, F. Taranto, M. G. Schiavo, and C. D'Alia, "Surgical treatment of the giant inguinal hernia," *Hernia*, vol. 3, no. 1, pp. 27–30, 1999.

- [9]R. Groen, S. Sesay, A. Kushner, and S. Dumbuya, "Three-stage repair of a giant inguinal hernia in Sierra Leone: A management technique for low-resource settings," *J Surg Case Rep*, vol. 2011, no. 12, p. 8, 2011.
- [10]W. Hope, *17th Annual Hernia Repair*, vol. 20, no. S1. 2016.
- [11]S. Avula, S. Merta, and S. K. Patel, "Giant Inguinoscrotal Hernia – Lichtenstein's Tension Free Repair Without Loss of Domain: Case Report," *J. Evol. Med. Dent. Sci.*, vol. 4, no. 22, pp. 3903–3906, 2015.
- [12]M. Tarchouli et al., "Giant inguinoscrotal hernia containing intestinal segments and urinary bladder successfully repaired by simple hernioplasty technique: a case report," *J Med Case Rep*, vol. 9, p. 276, 2015.
- [13]K. Vagholkar and S. Vagholkar, "Surgical management of giant inguinoscrotal hernias," vol. 2, no. 4, pp. 693–695, 2015.
- [14]A. Trakarnsagna et al., "Giant inguinal hernia: Report of a case and reviews of surgical techniques," *Int. J. Surg. Case Rep.*, vol. 5, no. 11, pp. 868–872, 2014.
- [15]J. Kumar CD, "Giant Inguinoscrotal Hernia Repaired by Lichtensteins Technique Without Loss of Domain -A Case Report," *J. Clin. Diagnostic Res.*, pp. 7–8, 2014.
- [16]J. Bierca, A. Kosim, M. Kołodziejczak, J. Zmora, and E. Kultys, "Effectiveness of Lichtenstein repairs in planned treatment of giant inguinal hernia - Own experience," *Wideochirurgia I Inne Tech. Maloinwazyjne*, vol. 8, no. 1, pp. 36–42, 2013.
- [17]E. J. H. Turner, A. Malhas, I. Chisti, and T. Oke, "Management of a giant inguinoscrotal hernia with an ulcerated base in a patient with cardiac disease," *Jscr*, vol. 8, no. fig 1, p. 9, 2010.
- [18]J. C. Mayagoitia, D. Suárez, J. C. Arenas, and V. Díaz de León, "Preoperative progressive pneumoperitoneum in patients with abdominal-wall hernias," *Hernia*, vol. 10, no. 3, pp. 213–217, 2006.
- [19]M. Mongardini et al., "Appendiceal abscess in a giant left-sided inguinoscrotal hernia: a rare case of Amyand hernia.," *Springerplus*, vol. 4, p. 378, 2015.
- [20]M. Cavalli, A. Biondi, P. G. Bruni, and G. Campanelli, "Giant inguinal hernia: the challenging hug technique," *Hernia*, vol. 19, no. 5, pp. 775–783, 2015.
- [21]K. Maeda et al., "Giant left-sided inguinoscrotal hernia containing the cecum and appendix (giant left-sided Amyand's hernia).," *Clin. case reports*, vol. 2, no. 6, pp. 254–7, 2014.
- [22]D. Gao et al., "Clinical research of preperitoneal drainage after endoscopic totally extraperitoneal inguinal hernia repair," *Hernia*, vol. 19, no. 5, pp. 789–794, 2015.
- [23]S. E. Lee, "A case of giant inguinal hernia with intestinal malrotation," *Int. J. Surg. Case Rep.*, vol. 3, no. 11, pp. 563–564, 2012.
- [24]a. Hamad, K. Marimuthu, B. Mothe, and M. Hanafy, "Repair of massive inguinal hernia with loss of abdominal domain using laparoscopic component separation technique," *J. Surg. Case Reports*, vol. 2013, no. 3, p. rjt008-rjt008, 2013.
- [25]G. G. Koning and P. W. H. E. Vriens, "Anterior preperitoneal repair of extremely large inguinal hernias: An alternative technique," *Int. J. Surg. Case Rep.*, vol. 3, no. 2, pp. 45–48, 2012.
- [26]L. S. Kovachev, A. P. Paul, P. Chowdhary, P. Choudhary, and E. T. Filipov, "Regarding extremely large inguinal hernias with a contribution of two cases," *Hernia*, vol. 14, no. 2, pp. 193–197, 2010.
- [27]A. J. Valliattu and A. N. Kingsnorth, "Single-stage repair of giant inguinoscrotal hernias using the abdominal wall component separation technique," *Hernia*, vol. 12, no. 3, pp. 329–330, 2008.
- [28]E. W. Ek et al., "Component separation in the repair of a giant inguinoscrotal hernia," *ANZ J. Surg.*, vol. 76, no. 10, pp. 950–952, 2006.
- [29]J. H. Alexandre, J. L. Bouillot, P. Dupin, K. Aouad, and J. P. Bethoux, "Cure of inguinal hernias with large preperitoneal prosthesis: Experience of 2,312 cases.," *J. Minim. Access Surg.*, vol. 2, no. 3, pp. 134–8, Sep. 2006.
- [30]V. S. Karthikeyan, S. C. Sistla, D. Ram, S. M. Ali, and N. Rajkumar, "Giant inguinoscrotal hernia- Report of a rare case with literature review," *Int. Surg.*, vol. 99, no. 4, pp. 560–564, 2014.
- [31]A. S. El Saadi, A. H. Al Wadan, and S. Hamerna, "Approach to a giant inguinoscrotal hernia," *Hernia*, vol. 9, no. 3, pp. 277–279, 2005.
- [32]A. H. Imisairi and S. S. M. Hadi, "Giant inguinal hernia," *ANZ J. Surg.*, vol. 81, no. 6, pp. 488–488, Jun. 2011.
- [33]U. M. Monestiroli, A. Bondurri, F. Gandini, G. Lenna, S. Vellini, and P. Danelli, "Giant inguinoscrotal hernia [1]," *Tech. Coloproctol.*, vol. 11, no. 3, pp. 283–284, 2007.
- [34]A. Patsas, P. Tsiaousis, B. Papaziogas, I. Koutelidakis, C. Goula, and K. Atmatzidis, "Repair of a giant inguinoscrotal hernia," *Hernia*, vol. 14, no. 3, pp. 305–307, 2010.
- [35]K. Vasiliadis, H. P. Knaebel, N. Djakovic, J. Nyarangi-Dix, J. Schmidt, and M. B??chler, "Challenging surgical management of a giant inguinoscrotal hernia: Report of a case," *Surg. Today*, vol. 40, no. 7, pp. 684–687, 2010.
- [36]N. Agaoglu and M. Ulusahin, "Giant inguinoscrotal hernia," *Chir.*, vol. 29, no. 4, pp. 124–125, 2016.
- [37]M. C. López Sanclemente et al., "Progressive preoperative pneumoperitoneum in patients with

- giant hernias of the abdominal wall,” *Cir. Esp.*, vol. 91, no. 7, pp. 444–449, 2013.
- [38]R. S. Mcadory, W. S. Cobb, and A. M. Carbonell, “Progressive preoperative pneumoperitoneum for hernias with loss of domain,” *Am. Surg.*, vol. 75, no. 6, pp. 504–508, 2009.
- [39]C. Kayaalp, T. Piskin, C. Aydin, B. Barut, and A. Dirican, “Preoperative progressive pneumoperitoneum for giant inguinal hernias,” *Ann. Saudi Med.*, vol. 30, no. 4, p. 317, 2010.
- [40]M. M. Murr, E. E. Mason, and D. H. Scott, “The Use of Pneumoperitoneum in the Repair of Giant Hernias,” *Obes. Surg. Incl. Laparosc. Allied Care*, vol. 4, no. 4, pp. 323–327, 1994.
- [41]a R. Koontz and J. W. Graves, “Preoperative pneumoperitoneum as an aid in the handling of gigantic hernias,” *Ann. Surg.*, vol. 140, no. 5, pp. 759–762, 1954.
- [42]F. V. Mehendale, K. O. Taams, and A. N. Kingsnorth, “Repair of a giant inguinoscrotal hernia,” *Br. J. Plast. Surg.*, vol. 53, no. 6, pp. 525–529, Sep. 2000.
- [43]S. E. ZIFFREN and N. A. WOMACK, “An operative approach to the treatment of gigantic hernias,” *Surg. Gynecol. Obstet.*, vol. 91, no. 6, pp. 709–10, Dec. 1950.
- [44]M. G, “Techniques to aid in hernia repair complicated by the loss of domain,” *Surgery*, vol. 78, p. 408, 1975.
- [45]Ó. S. France, “Oral Communications Assessment,” vol. 20, p. 27, 2016.
- [46]H. V Harissis and G. K. Georgiou, “The role of pelvic bone anatomy in the pathogenesis of inguinal hernia,” *Chir.*, vol. 109, no. 6, pp. 783–787, 2014.
- [47]A. Aren, A. H. Gökçe, F. S. Gökçe, and N. Dursun, “Roles of matrix metalloproteinases in the etiology of inguinal hernia,” *Hernia*, vol. 15, no. 6, pp. 667–671, 2011.
- [48]G. A. Antoniou, G. S. Georgiadis, S. A. Antoniou, F. A. Granderath, A. D. Giannoukas, and M. K. Lazarides, “Abdominal aortic aneurysm and abdominal wall hernia as manifestations of a connective tissue disorder,” *J. Vasc. Surg.*, vol. 54, no. 4, pp. 1175–1181, 2011.
- [49]J. M. Bellón et al., “Fibroblasts from the transversalis fascia of young patients with direct inguinal hernias show constitutive MMP-2 overexpression,” *Ann. Surg.*, vol. 233, no. 2, pp. 287–91, 2001.
- [50]J. B. F. Jack Abrahamson, *Abdominal wall hernias principles and management*. Springer-Verlag, 2001.
- [51]M. P. Simons et al., “European Hernia Society guidelines on the treatment of inguinal hernia in adult patients,” *Hernia*, vol. 13, no. 4, pp. 343–403, Aug. 2009.
- [52]E. M. Nordberg, “Incidence and estimated need of caesarean section, inguinal hernia repair, and operation for strangulated hernia in rural Africa,” *Br. Med. J. (Clin. Res. Ed.)*, vol. 289, no. 6437, pp. 92–3, Jul. 1984.
- [53]V. Gupta, A. K. Sharma, and R. K. Chrungoo, “A giant inguinoscrotal hernia,” *JK Sci.*, vol. 9, no. 4, pp. 200–202, 2007.
- [54]G. Sahsamannis, S. Samaras, A. Basios, K. Katis, and G. Dimitrakopoulos, “Treatment of a half century year old giant inguinoscrotal hernia. A case report,” *Int. J. Surg. Case Rep.*, vol. 25, pp. 51–54, 2016.
- [55]S. Ravanbakhsh, M. Batech, and T. Tejirian, “Increasing Body Mass Index Is Inversely Related to Groin Hernias,” *Am. Surg.*, vol. 81, no. 10, pp. 1043–6, Oct. 2015.
- [56]L. De Luca et al., “Relationship between hiatal hernia and inguinal hernia,” *Dig. Dis. Sci.*, vol. 49, no. 2, pp. 243–7, Feb. 2004.
- [57]E. Coetzee et al., “Simple repair of a giant inguinoscrotal hernia,” *Int. J. Surg. Case Rep.*, vol. 2, no. 3, pp. 32–5, 2011.
- [58]E. Y. Tanaka, J. H. Yoo, A. J. Rodrigues, E. M. Utiyama, D. Birolini, and S. Rasslan, “A computerized tomography scan method for calculating the hernia sac and abdominal cavity volume in complex large incisional hernia with loss of domain,” *Hernia*, vol. 14, no. 1, pp. 63–69, Feb. 2010.
- [59]M. A. Dogar and A. Chaudhary, “Inguinal Hernia Containing Stomach , Transverse Colon and Small Bowel,” no. 3, pp. 597–599, 2011.
- [60]M. B. Weitzenfeld, B. T. Brown, G. Morillo, and N. L. Block, “Scrotal kidney and ureter: an unusual hernia,” *J. Urol.*, vol. 123, no. 3, pp. 437–8, Mar. 1980.
- [61]A. A. Virgínia, C. Santos, H. Contente, and C. Branco, “What is inside the hernia sac?,” *BMJ Case Rep.*, vol. 2016, Aug. 2016.
- [62]T. J. Aufenacker et al., “The role of antibiotic prophylaxis in prevention of wound infection after Lichtenstein open mesh repair of primary inguinal hernia: a multicenter double-blind randomized controlled trial,” *Ann. Surg.*, vol. 240, no. 6, pp. 955–60–1, Dec. 2004.
- [63]M. Kurzer, P. A. Belsham, and A. E. Kark, “THE LICHTENSTEIN REPAIR,” *Surg. Clin. North Am.*, vol. 78, no. 6, pp. 1025–1046, Dec. 1998.
- [64]R. Grabenhorst, “[Evaluation of the Bassini reconstruction principle for inguinal hernia],” *Zentralbl. Chir.*, vol. 118, no. 12, pp. 767–73, 1993.
- [65]R. G. C. D. Ion, “Bassini surgery,” *J. Surg. Sci.*, vol. 3, p. 214, 2016.

[66]M. G. Nagase H, Visse R, “Structure and function of matrix metalloproteinases and TIMPs,” *Cardiovasc. Res.*, vol. 69, no. 3, pp. 562–573, 2006.

[67]M. Rojkind, *Connective tissue in health and disease*. 1989.