

High- and Low-Risk Profiles for the Development of Multiple Sclerosis Within 10 Years After Optic Neuritis

Experience of the Optic Neuritis Treatment Trial

Optic Neuritis Study Group*

Objective: To identify factors associated with a high and low risk of developing multiple sclerosis after an initial episode of optic neuritis.

Methods: Three hundred eighty-eight patients who experienced acute optic neuritis between July 1, 1988, and June 30, 1991, were followed up prospectively for the development of multiple sclerosis. Consenting patients were reassessed after 10 to 13 years.

Results: The 10-year risk of multiple sclerosis was 38% (95% confidence interval, 33%-43%). Patients (160) who had 1 or more typical lesions on the baseline magnetic resonance imaging (MRI) scan of the brain had a 56% risk; those with no lesions (191) had a 22% risk ($P < .001$, log rank test). Among the patients who had no lesions on MRI, male gender and optic disc swelling were associated with a lower risk of multiple sclerosis, as was the presence of the following atypical features for optic neuritis: no light perception vision; absence of

pain; and ophthalmoscopic findings of severe optic disc edema, peripapillary hemorrhages, or retinal exudates.

Conclusions: The 10-year risk of multiple sclerosis following an initial episode of acute optic neuritis is significantly higher if there is a single brain MRI lesion; higher numbers of lesions do not appreciably increase that risk. However, even when brain lesions are seen on MRI, more than 40% of the patients will not develop clinical multiple sclerosis after 10 years. In the absence of MRI lesions, certain demographic and clinical features seem to predict a very low likelihood of developing multiple sclerosis. This natural history information is a critical input for estimating a patient's 10-year multiple sclerosis risk and for weighing the benefit of initiating prophylactic treatment at the time of optic neuritis or other initial demyelinating events in the central nervous system.

Arch Ophthalmol. 2003;121:944-949

OPTIC NEURITIS, an acute inflammatory disorder of the optic nerve, is a common initial manifestation of multiple sclerosis.¹ It typically manifests as sudden monocular visual loss accompanied by eye pain in young adults, with women more commonly affected than men. Even when optic neuritis occurs without other clinical signs of multiple sclerosis, magnetic

See also page 1039

resonance imaging (MRI) of the brain often demonstrates white matter T2-signal abnormalities (referred to subsequently as "lesions").² In a patient with optic neuritis, the presence of brain T2-signal lesions seen on MRI increases the probability that additional neurological manifestations sufficient for a diagnosis of multiple sclerosis will develop.³ We have previously re-

ported the 5-year risk of developing multiple sclerosis after an initial episode of optic neuritis, based on 388 patients enrolled in the Optic Neuritis Treatment Trial.⁴ Herein we report the 10-year risk of developing multiple sclerosis, including high- and low-risk profiles, based on further follow-up of the Optic Neuritis Treatment Trial cohort.

METHODS

The study protocol⁵ was approved by the institutional review board at each of 15 clinical centers. Patients provided written informed consent for participation in the original treatment trial (ie, the Optic Neuritis Treatment Trial). Patients provided written informed consent for continuation in the follow-up study after the first 2 years and again after the first 5 years. The study protocol has been detailed in prior publications and is summarized below.⁴⁻⁸

Between July 1, 1988, and June 30, 1991, we enrolled 388 patients with acute optic neu-

*The authors for the Optic Neuritis Study Group are the Writing Committee listed in the box on p 948 along with the investigators and coordinators who participated in the study.

ritis who did not already have clinically definite multiple sclerosis⁹ at study enrollment. The major eligibility criteria were as follows: (1) a diagnosis of acute unilateral optic neuritis with visual symptoms of 8 days or less, (2) aged between 18 and 46 years, (3) no evidence of a systemic disease other than multiple sclerosis that might be associated with optic neuritis, and (4) no previous treatment for multiple sclerosis. Patients were randomized to receive a single course of either intravenous methylprednisolone sodium succinate followed by oral prednisone, oral prednisone alone, or oral placebo. For 351 of the 388 patients, unenhanced MRIs of the brain, performed at study enrollment, were graded at a central reading center by a standardized protocol that included a count of the number of T2 white matter lesions at least 3 mm in diameter.²

Standardized neurological examinations were performed at study enrollment, after 6 and 12 months, and then annually through 1997. Thereafter, semiannual telephone contact was made with the patients until the period of 2001-2002, when willing patients underwent another standardized neurological examination. For living patients who were unwilling to undergo a neurological examination, an attempt was made to obtain information from a telephone interview and from medical records.

DIAGNOSTIC CRITERIA FOR MULTIPLE SCLEROSIS

Patients were defined as having multiple sclerosis if a clinical examination documented a new neurological deficit consistent with a patient report of neurological symptoms of at least 24 hours' duration and separated by at least 4 weeks from the initial optic neuritis event.⁹ The deficit had to be attributable to demyelination in the central nervous system but not in the optic nerves.

STATISTICAL ANALYSIS

Cumulative probabilities (referred to subsequently as "risk") of developing multiple sclerosis were calculated with use of the Kaplan-Meier method and, where indicated, compared with the log rank test. Data for patients not developing multiple sclerosis were censored on the later of either the date of the most recent neurological examination or the date of the last telephone assessment at which the patient reported no history consistent with the diagnosis of multiple sclerosis.

Unadjusted and adjusted hazard ratios for the development of multiple sclerosis were determined from a Cox proportional hazards regression model.¹⁰ Predictive factors for multiple sclerosis were assessed separately for patients with and without brain lesions seen on MRI. These factors were identified prior to the study and are the same factors that were evaluated after 5 years of follow-up.⁴

The baseline characteristics of the "noncompleters" (patients without multiple sclerosis who had 1-10 years of follow-up data) and "completers" (patients with multiple sclerosis or at least ≥ 10 years of follow-up data) were compared using the Fisher exact test for categorical variables and a Wilcoxon rank sum test for continuous variables. All reported *P* values are 2-tailed.

RESULTS

STATUS OF THE COHORT

The mean age of the 388 patients at the time of study enrollment was 31.7 years; 77% were female. The cohort was 85% white, 13% African American, 2% Hispanic, and 0.5% Asian.

Data were considered complete (diagnosis of multiple sclerosis or follow-up of at least 10 years) for 336 (87%) of the 388 patients. Among the 243 patients who

Table 1. Development of Multiple Sclerosis According to Number of Baseline Brain Magnetic Resonance Imaging (MRI) Lesions

No. of Brain MRI Lesions at Study Enrollment	No. of Patients	10-y Risk of Multiple Sclerosis, %*	Hazard Ratio (95% Confidence Interval)†
0	191	22	1.00
1	44	51	2.77 (1.64-4.67)
2-4	51	50	2.97 (1.80-4.92)
5-8	37	70	4.90 (2.98-8.06)
≥ 9	28	57	3.94 (2.19-7.06)
Total‡	388	38	NA

Abbreviations: NA, not applicable.

*Values are Kaplan-Meier estimates of cumulative probability.

†Value calculated from proportional hazards model.

‡Total includes 37 patients who had no baseline MRI data.

did not develop multiple sclerosis, the median follow-up time was 11.5 years (interquartile range, 10.4-12.2 years), with at least 10 years of follow-up data available for 191 (79%) of the patients (162 patients by neurological examination and 29 patients by telephone assessment). Three patients died prior to 10 years after study enrollment from causes unrelated to multiple sclerosis.

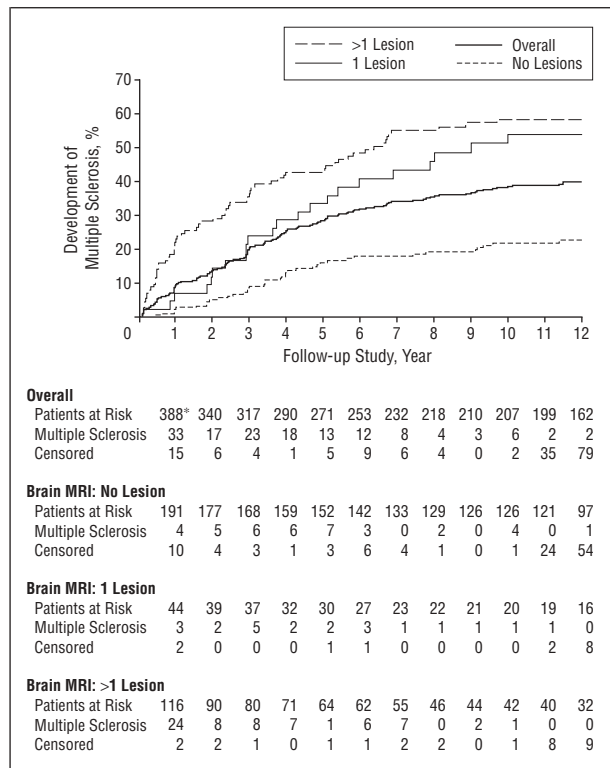
The age and sex of the 336 completers and the 52 noncompleters were similar (mean age, 31.9 vs 30.3 years, *P* = .13; female sex, 79% vs 67%, *P* = .08), but the completers were more likely to be white (87% vs 73%, *P* = .02). One or more baseline brain lesions seen on MRI were present in 144 (48%) of the 302 completers with baseline brain MRI and in 16 (33%) of the 49 noncompleters with baseline MRI (*P* = .06).

DEVELOPMENT OF MULTIPLE SCLEROSIS

The 10-year risk of multiple sclerosis was 38% (95% confidence interval [CI], 33%-43%) and the 12-year risk was 40% (95% CI, 35%-45%). Among the 145 patients who developed multiple sclerosis, the median time to diagnosis was 3.0 years. In 34% of patients, the diagnosis was made within the first 2 years after study enrollment, and in 72%, it was made within 5 years. The 10-year risk of multiple sclerosis was similar in the 3 original Optic Neuritis Treatment Trial groups (*P* = .49).

The development of multiple sclerosis was strongly associated with the presence of 1 or more lesions on the baseline MRI of the brain (*P* < .001; **Table 1** and the **Figure**). The 10-year risk of multiple sclerosis was 56% in the 160 patients with 1 or more brain lesions seen on MRI and 22% in the 191 patients with no lesions. However, among those with brain lesions seen on MRI, the risk with multiple lesions was not significantly higher than it was with a single lesion (58% vs 51%; *P* = .22, log rank test). Among patients who had not developed multiple sclerosis at 5 years after study enrollment, the probability of being diagnosed as having multiple sclerosis between 5 and 10 years was 7% in the 142 patients with no brain lesions seen on MRI and 27% in the 89 patients with 1 or more lesions.

In the presence of 1 or more brain lesions seen on MRI, a history of nonspecific neurological symptoms (usu-



The cumulative probability of multiple sclerosis was statistically significantly higher in patients with 1 or more lesions seen on the baseline magnetic resonance imaging (MRI) scan of the brain than in patients with no brain lesions ($P < .001$, log rank test) but was not significantly different comparing patients with a single brain lesion and patients with multiple lesions ($P = .22$, log rank test). The numbers of patients at risk are the numbers who had not developed multiple sclerosis at the beginning of each year. The "multiple sclerosis rows" indicate the number of patients classified as having multiple sclerosis during each yearly interval. The "censored" rows indicate the number of patients not developing multiple sclerosis whose last available follow-up data occurred during each yearly interval. Asterisk indicates 37 patients who had no baseline MRIs.

ally transient numbness) or prior optic neuritis in the fellow eye further increased the 10-year risk of multiple sclerosis (70% vs 50%, $P = .005$). However, among these 160 patients with 1 or more brain lesions seen on MRI, no demographic or clinical features of the optic neuritis were predictive of developing multiple sclerosis (**Table 2**).

In contrast, among the 191 patients without brain lesions seen on MRI, certain features did alter the risk of multiple sclerosis. The risk of multiple sclerosis was lower in male patients than in female patients (hazard ratio, 0.35; 95% CI, 0.12-0.98) and was lower when the optic disc was swollen (anterior optic neuritis, papillitis) than when it was not swollen (retrobulbar neuritis; hazard ratio, 0.41; 95% CI, 0.20-0.84) (Table 2). Among female patients, the risk of multiple sclerosis was halved when optic disc swelling was present. Among male patients, only 1 of 24 patients with optic disc swelling developed multiple sclerosis (**Table 3**). One hundred seventy-nine of the 191 patients with no brain lesions seen on MRI had no history of neurological symptoms or optic neuritis in the fellow eye and would be considered to have monofocal optic neuritis; their 10-year risk of multiple sclerosis was 20%.

In patients of both genders without brain lesions seen on MRI, multiple sclerosis did not develop in any patients whose visual loss was painless (18 patients) or total

(no light perception, 6 patients), or in those who had ophthalmoscopic findings of severe disc swelling (22 patients), hemorrhage of the optic disc or surrounding retina (16 patients), or retinal exudates (8 patients). When the criteria for multiple sclerosis were expanded to include the occurrence of optic neuritis in the fellow eye, the 10-year risk of multiple sclerosis was 45%: 31% in patients with no baseline brain lesions seen on MRI and 60% in patients with 1 or more lesions.

COMMENT

Within our cohort of 388 patients followed up from the onset of an acute episode of optic neuritis, the 10-year risk of development of multiple sclerosis, based strictly on conventional clinical criteria, was 38%, compared with a 5-year risk of 30%.⁴ Thus, although our patients continued to develop multiple sclerosis with each passing year, most did so within the first 5 years after the initial episode of acute optic neuritis. Our results have applicability not only to optic neuritis but also to patients seen with an initial demyelinating event of the brainstem or spinal cord because the 3 presentations share a common pathogenesis and have been reported to have similar risks for multiple sclerosis.¹¹

Our finding of a 38% 10-year risk of multiple sclerosis after acute optic neuritis is similar to that of several prior reports¹²⁻¹⁴ and lower than that of other reports,¹⁵⁻¹⁷ all of which had smaller sample sizes. Differences in risk estimates across studies can also be attributed to differences in patient inclusion criteria, retention rates, and diagnostic criteria for multiple sclerosis.

The most potent predictor of multiple sclerosis in our study was the presence of white matter lesions on the baseline MRI scan of the brain. The presence of 1 such lesion at least 3 mm in diameter more than doubled the 10-year risk of multiple sclerosis (from 22% to 56%). However, the presence of 1 or more lesions did not signify that the patient was destined to develop multiple sclerosis. Among patients with brain lesions seen on MRI, the 10-year probability of remaining free of multiple sclerosis was 44%. Conversely, the absence of brain lesions seen on MRI did not eliminate the risk of developing multiple sclerosis; in the absence of any lesions, the 10-year probability of multiple sclerosis was 22%.

Among patients with 1 or more brain lesions seen on MRI, no demographic characteristics or clinical features of acute optic neuritis were useful in further defining the risk. But among patients without brain MRI lesions, the risk was 3 times lower in male patients than in female patients, consistent with the well-documented lower prevalence of multiple sclerosis in male patients than in female patients and consistent with findings from studies conducted prior to the availability of MRI of the brain.^{12,14} The risk was also lower when the optic neuritis was associated with a swollen rather than a normal optic disc. Among female patients with no brain MRI lesions, those with optic disc edema had a risk of multiple sclerosis that was half as great as those without optic disc edema. The risk of multiple sclerosis when no baseline brain lesions were present on MRI was 0 among the small group of patients who had any one of the fol-

Table 2. Baseline Factors Predictive of Multiple Sclerosis According to the Presence or Absence of Brain Magnetic Resonance Imaging (MRI) Lesions at Study Enrollment

Variable	Patients Who Had No Brain Lesions on MRI					Patients Who Had ≥1 Brain Lesion on MRI				
	No. of Patients	10-y Risk of Multiple Sclerosis, %*	Hazard Ratio†	95% Confidence Interval	P Value	No. of Patients	10-y Risk of Multiple Sclerosis*	Hazard Ratio†	95% Confidence Interval	P Value
Overall	191	22	NA	NA	NA	160	56	NA	NA	NA
Gender										
Female	142	25	1.00			128	58	1.00	NA	
Male	49	10	0.35	0.12-0.98	.05	32	51	1.05	0.62-1.78	.86
Race‡										
White	163	22	1.00			135	60	1.00	NA	
African American	21	25	1.06	0.37-2.98	.92	24	40	0.58	0.30-1.13	.11
Age, y										
≤30	76	21	1.00			71	55	1.00	NA	
>30	115	22	0.94	0.50-1.78	.81	89	57	0.98	0.65-1.50	.43
Visual acuity in affected eye										
≤20/200	56	24	1.00		.32	73	60	1.00	NA	
20/50-20/190	43	26	1.21	0.54-2.78		33	40	0.56	0.30-1.04	
≥20/40	92	18	0.73	0.34-1.53		54	62	1.05	0.67-1.65	.60
Optic disc appearance										
Normal	110	28	1.00			105	60	1.00	NA	
Edema	81	14	0.41	0.20-0.84	.01	55	50	0.88	0.57-1.37	.57
Pain§										
Yes	173	24	1.0	NA		148	57	1.00	NA	
No	18	0	NA	NA		12	42	0.71	0.29-1.75	.46

Abbreviation: NA, not applicable.

*Values are Kaplan-Meier estimates of cumulative probability.

†Hazard ratios, 95% confidence intervals, and P values are from unadjusted proportional hazards models; in adjusted models, the hazard ratio for gender was not affected when adjusted by optic disc appearance, and the hazard ratio for optic disc appearance was not affected when adjusted by gender.

‡Patients of other races are excluded.

§The presence of pain was ascertained at baseline by querying the patients as to whether pain was present, and if present, as to its severity, constancy, and relation to eye movement.

Table 3. Gender and Optic Disc Appearance Combined as Predictors of Multiple Sclerosis in Patients Who Had No Brain Lesions on Magnetic Resonance Imaging (MRI) at Study Enrollment

Variable	No. of Patients	No. of Patients Developing Multiple Sclerosis	10-y Risk of Multiple Sclerosis, %*	Hazard Ratio (95% Confidence Interval)†
Female				
Optic disc normal	85	26	31	1.00
Optic disc edema	57	9	16	0.42 (0.20-0.89)
Male				
Optic disc normal	25	3	15	0.36 (0.11-1.19)
Optic disc edema	24	1	5	0.14 (0.02-1.00)

*Values are Kaplan-Meier estimates of cumulative probability.

†Values are calculated from proportional hazards model.

lowing findings: no light perception vision in the affected eye, optic fundus findings including severe optic disc edema, peripapillary hemorrhages, retinal exudates, or the absence of periorcular pain. Thus, when there are no brain MRI lesions, the presence of any of these clinical features seems to predict a very low risk of multiple sclerosis. In patients who bear these atypical features, the optic neuritis may not be part of a multifocal demyelinating central nervous system illness.

The difference in the risk profile between patients with and without brain MRI lesions is not surprising. Patients with MRI lesions already have imaging evidence of disseminated disease, the pathogenesis of which is almost certainly related to multiple sclerosis. Therefore,

there is no reason to expect to be able to identify true risk factors for future development of multiple sclerosis. However, the group of patients with optic neuritis and a normal brain MRI likely includes a subgroup destined to have multiple sclerosis and another subgroup not destined to have multiple sclerosis.

Regarding the predictive role of MRI lesions, the only comparable study^{11,15} enrolled 131 patients with an acute demyelinating event in which optic neuritis constituted half of the cohort. Ten-year follow-up was achieved in 81 patients (62%) and 12- to 16-year follow-up in 72 patients (55%). After 10 years, multiple sclerosis was present in 83% of those with enrollment MRI lesions and in 11% of those without enrollment

Writing Committee: *Lead authors:* Roy W. Beck, MD; Jonathan D. Trobe, MD; Pamela S. Moke, MSPH; Robin L. Gal, MSPH; Dongyuan Xing, MPH. *Contributing authors:* M. Tariq Bhatti, MD; Michael C. Brodsky, MD; Edward G. Buckley, MD; Georgia A. Chrousos, MD; James Corbett, MD; Eric Eggenberger, DO; James A. Goodwin, MD; Barrett Katz, MD; David I. Kaufman, DO; John L. Keltner, MD; Mark J. Kupersmith, MD; Neil R. Miller, MD; Sarkis Nazarian, MD; Silvia Orengo-Nania, MD; Peter J. Savino, MD; William T. Shults, MD; Craig H. Smith, MD; Michael Wall, MD.

Listed below are the investigators and clinical center staff active in the current phase of the study (I indicates investigator; C, coordinator; and T, technician).

Clinical Centers

University of Arkansas, Little Rock: Michael C. Brodsky, MD (I); Sarkis Nazarian, MD (I); Shirley Hankins (C). *Baylor College of Medicine, Houston, Tex:* Silvia Orengo-Nania, MD (I); George J. Hutton, MD (I); Ronald L. Gross, MD (I); Benita Slight (C); Pamela Frady (T). *Duke University, Durham, NC:* Edward G. Buckley, MD (I); E. Wayne Massey, MD (I); Malcom M. Anderson (C); Lois B. Duncan (T). *University of Florida, Gainesville:* M. Tariq Bhatti, MD (I); John Guy, MD (I); Melvin Greer, MD (I); Revonda Burke (C); Renae Preston (T). *Georgetown University, Washington, DC:* Georgia A. Chrousos, MD (I); Pamela Young Blake, MD (I); Sharlene Smith (C); Pat Kryzminski (T). *University of Illinois, Chicago:* James Goodwin, MD (I); Andrew Cross (C); Jessie Garcia (T). *University of Iowa, Iowa City:* Michael Wall, MD (I); Carmen Musser (C); Kim Woodward (T). *Wills Eye Hospital, Philadelphia, Pa:* Peter J. Savino, MD (I); Thomas Leist, MD (I); Diane Branciforte (C); Reginald Edwards (T). *Johns Hopkins University, Baltimore, Md:* Neil Miller, MD (I); David Irani, MD (I); Justin McArthur, MD (I); Stephen Reich, MD (I); Marianne Medura (C); Lula West (T). *University of Michigan, Ann Arbor:* Jonathan D. Trobe, MD (I); Wayne Cornblath, MD (I); Sharon Boyk (C); Cheryl Terpening (T). *Michigan State University, East Lansing:* David I. Kaufman, DO (I); Eric Eggenberger, DO (I); Sandra Holliday (C). *Beth Israel Medical Center, New York, NY:* Mark J. Kupersmith, MD (I); Gary Mandel (C, T). *Devers Eye Institute, Portland, Ore:* William T. Shults, MD (I); Leslie McAllister, MD (I); Reed Wilson, MD (I); Sue Swinford (C); Mary Dierkes (T); Joanne Fraser (T). *Swedish Medical Center, Seattle, Wash:* Craig H. Smith, MD (I); Dennis Kuder (C); Elizabeth Tran (T).

Coordinating Center

Jaeb Center for Health Research, Inc, Tampa, Fla: Pamela S. Moke, MSPH (Director); Roy W. Beck, MD, PhD; Robin L. Gal, MSPH; Craig Kollman, PhD; Raymond T. Kraker, MSPH; Dongyuan Xing, MPH; Julie Arends (Technician Certification—Devers Eye Institute).

Visual Field Reading Center

University of California, Davis: John L. Keltner, MD (Director); Chris A. Johnson, PhD (Discoveries in Sight, Devers Eye Institute); Kimberly E. Cello; Shannan Bandermann, MA; Daniel E. Redline.

MRI Reading Center

University Diagnostic Institute, Tampa: John A. Arrington, MD; F. Reed Murtagh, MD.

National Institutes of Health

National Eye Institute, Bethesda, Md: Donald Everett, MA.

Additional Physicians Who Conducted Study Examinations

George Aita, MD; Robert Armstrong, MD; Donald Barone, MD; James Bates, MD; W. W. Blessing, MB, PhD; Swaraj Bose, MD; Robert Burger, MD; Joanna Cooper, MD; Dennis Dewey, MD; Christina Diaz, MD; Philip Ente, MD; Edward Fox, MD; Benjamin Frishberg, MD; Jerry Gage, DO; Deborah Gelinis, MD; Allen Han, MD; Robert Herndon, MD; Mary Kerber, MD; Donald Kitt, MD; Lanning Kline, MD; John Livingstone, MD; Martha Lusser, MD; Sharon Lynch, MD; Joanne Lynn, MD; Julia Mikell, MD; Shanan Munoz, MD; Muhammad Nayer, MD; Nancy Newman, MD; Brad Oren, MD; Victoria Pelak, MD; Diana Reed, MD; David Richman, MD; Emily Riser, MD; Donald Roth, MD; Alfredo Sadun, MD; Antoine Samman, MD; Alan Sconzert, MD; Christopher Sheppard, MD; Dilip Thomas, MD; David Waitzman, MD; Thomas Whittaker, MD; Allen Zechow, MD; Steven Zuckerman, MD.

MRI lesions. Differences between these results and ours may be related to that study's smaller sample size and lower follow-up rate. That study found, as we did, that once there is at least 1 MRI lesion, an increasing number of lesions does not appreciably amplify the long-term risk of multiple sclerosis.

The eligibility criteria of our study were sufficiently broad that our results should be applicable to most patients seen with optic neuritis as an initial demyelinating event. Having incomplete data for 13% of the original cohort is unlikely to be a source of appreciable bias. However, because the patients with incomplete follow-up had a lower prevalence of MRI scans of the brain

with 1 or more lesions than did the patients with complete follow-up, our computed 10-year risk of multiple sclerosis could be a slight overestimate.

Our results are important to the clinician in several respects. First, they reaffirm the prognostic value of an MRI scan of the brain performed at the time of an initial episode of acute optic neuritis. The presence of a single at least 3-mm-diameter brain MRI white matter lesion markedly increases the risk of developing multiple sclerosis; higher numbers of lesions do not appreciably increase that risk. Second, they establish that even when MRI lesions are present, clinically defined multiple sclerosis does not develop within 10 years in more than 40%

of patients. Third, the results highlight the importance of an ophthalmologic examination for patients whose MRI of the brain is normal because ophthalmoscopy can identify features (severe optic disc swelling, hemorrhages, and exudates) associated with a very low risk of developing multiple sclerosis. This natural history information is a critical input for estimating a patient's 10-year multiple sclerosis risk and for weighing the benefit of initiating prophylactic treatment at the time of acute optic neuritis or other initial demyelinating events in the central nervous system.

Submitted for publication March 18, 2003; final revision received April 23, 2003; accepted May 1, 2003.

This study was supported by cooperative agreement U10 EY09435 from the National Eye Institute, National Institutes of Health, Bethesda, Md.

Corresponding author and reprints: Roy W. Beck, MD, PhD, Optic Neuritis Study Group Coordinating Center, Jaeb Center for Health Research, 15310 Amberly Dr, Suite 350, Tampa, FL 33647 (e-mail: ont@jaeb.org).

REFERENCES

1. Ebers GC. Optic neuritis and multiple sclerosis. *Arch Neurol.* 1985;42:702-704.
2. Beck RW, Arrington J, Murtagh FR, Cleary PA, Kaufman DI, for the Optic Neuritis Study Group. Brain magnetic resonance imaging in acute optic neuritis: experience of the Optic Neuritis Study Group. *Arch Neurol.* 1993;50:841-846.
3. Barkhof F, Filippi M, Miller DH, et al. Comparison of MRI criteria at first presentation to predict conversion to clinically definite multiple sclerosis. *Brain.* 1997;120:2059-2069.
4. Optic Neuritis Study Group. The 5-year risk of MS after optic neuritis: experience of the Optic Neuritis Treatment Trial. *Neurology.* 1997;49:1404-1413.
5. Cleary PA, Beck RW, Anderson MM Jr, Kenny DJ, Backlund JY, Gilbert PR. Design, methods, and conduct of the Optic Neuritis Treatment Trial. *Control Clin Trials.* 1993;14:123-142.
6. Optic Neuritis Study Group. The clinical profile of acute optic neuritis: experience of the Optic Neuritis Treatment Trial. *Arch Ophthalmol.* 1991;109:1673-1678.
7. Optic Neuritis Study Group. Visual function five years after optic neuritis: experience of the Optic Neuritis Treatment Trial. *Arch Ophthalmol.* 1997;115:1545-1552.
8. Beck RW, Cleary PA, Anderson MM, Jr, et al. A randomized, controlled trial of corticosteroids in the treatment of acute optic neuritis. *N Engl J Med.* 1992;326:581-588.
9. Poser CM, Paty DW, Scheinberg L, et al. New diagnostic criteria for multiple sclerosis: guidelines for research protocols. *Ann Neurol.* 1983;13:227-231.
10. Cox DR. Regression models and life-tables. *J R Stat Soc.* 1972;34:187-220.
11. Brex PA, Ciccarelli O, O'Riordan JI, Sailer M, Thompson AJ, Miller DH. A longitudinal study of abnormalities on MRI and disability from multiple sclerosis. *N Engl J Med.* 2002;346:158-164.
12. Rizzo JF III, Lessell S. Risk of developing multiple sclerosis after uncomplicated optic neuritis: a long-term prospective study. *Neurology.* 1988;38:185-190.
13. Rodriguez M, Siva A, Cross SA, O'Brien PC, Kurland LT. Optic neuritis: a population-based study in Olmsted County, Minnesota. *Neurology.* 1995;45:244-250.
14. Sandberg-Wollheim M, Bynke H, Cronqvist S, Holtas S, Platz P, Ryder LP. A long-term prospective study of optic neuritis: evaluation of risk factors. *Ann Neurol.* 1990;27:386-393.
15. O'Riordan JI, Thompson AJ, Kingsley DP, et al. The prognostic value of brain MRI in clinically isolated syndromes of the CNS: a 10-year follow-up. *Brain.* 1998;121:495-503.
16. Hutchinson WM. Acute optic neuritis and the prognosis for multiple sclerosis. *J Neurol Neurosurg Psychiatry.* 1976;39:283-289.
17. Francis DA, Compston DA, Batchelor JR, McDonald WI. A reassessment of the risk of multiple sclerosis developing in patients with optic neuritis after extended follow-up. *J Neurol Neurosurg Psychiatry.* 1987;50:758-765.