

High Angular Resolution Diffusion Imaging of the Human Brain

D.S. Tuch, R.M. Weisskoff, J.W. Belliveau, and V.J. Wedeen
Massachusetts General Hospital, NMR Center
Charlestown, Massachusetts, USA

Introduction — The use of a tensor to describe diffusion in anisotropic tissue such as white matter or cardiac muscle is predicated on the assumption of Gaussian diffusion (1, 2). The diffusion may, however, exhibit non-Gaussian behavior if the diffusion is restricted (3), or if there is slow exchange between partial volume components containing Gaussian diffusion. The 6 gradient direction sampling typical of standard tensor imaging experiments cannot resolve such spatially non-Gaussian diffusion, and thus higher angular resolution sampling is required. Here, we show that sampling the apparent diffusion coefficient at higher angular resolutions provides evidence for non-Gaussian diffusion in human brain white matter regions containing heterogeneous fiber orientations (4).

Theory — Non-Gaussian diffusion may arise from restricted diffusion (3), or from slow exchange between partial volume compartments of Gaussian diffusion. The former case follows from the fact that the displacement probability density function is simply the autocorrelation of the spin density which is not necessarily Gaussian (3). The latter type does not reflect true non-Gaussian diffusion in the medium, but is due rather to the non-linear partial voluming of the diffusion signal under slow-exchange conditions. This has the counter-intuitive implication that the maxima of the diffusion function do not correspond to the eigenvectors of the component tensors. It can be shown, however, that the diffusion function can be decomposed to obtain the true partial volume tensors through solution of a convex quadratic programming problem.

Methods — Two experiments were performed: circular diffusion gradient sampling in two dimensions, and uniform geodesic sampling in three dimensions. For the first experiment, coronal balanced-echo (5) diffusion measurements of a healthy adult male were taken at 3T (GE Signa) with TR/TE/ τ =4000/165/52, b =1812s/mm², 2 averages, and 3.125×3.125×5mm³ voxels. The diffusion gradient ($g = 10$ mT/m) was applied in 64 directions in a semicircle in the coronal plane. The second experiment obtained axial balanced-echo diffusion measurements of a healthy adult male at 3T (GE Signa) with TR/TE/ τ =2200/140/50ms, b =1077s/mm², 8 averages, and 3.125×3.125×3.1mm³ voxels. The gradient ($g = 10$ mT/m) directions were obtained from the 126 vertices of a 5-fold tessellated icosahedral hemisphere. The diffusion function was assumed to be symmetric in both cases. One T2-weighted image was obtained for each experiment in order to normalize for non-diffusive signal loss.

Results — Non-Gaussian diffusion ($p < .01$) was observed for both the two-dimensional (Fig. 1) and three-dimensional (Fig. 2) sampling schemes in regions known anatomically to contain multiple fiber orientations. The non-Gaussian behavior was evidenced by multiple local maxima in the diffusion function which is inexplicable in terms of classical Gaussian diffusion.

Discussion — High angular resolution sampling provides evidence for non-Gaussian diffusion in human brain white matter regions containing heterogeneous fiber populations. The ability to detect multiple fiber orientations within a voxel using high angular resolution sampling has a number of implications. Firstly,

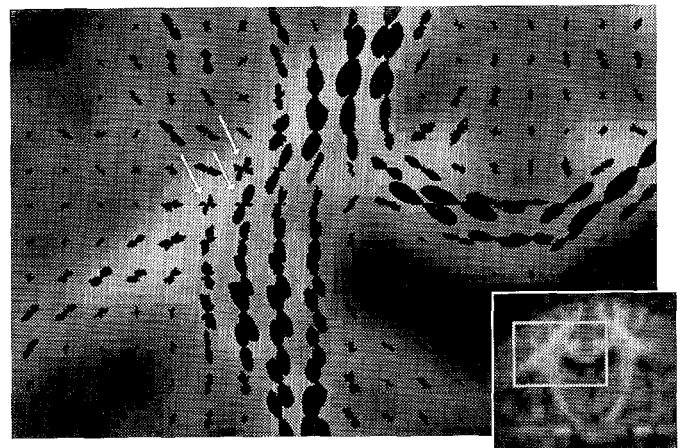


Figure 1: High angular resolution diffusion image with in-plane sampling. The orbitals depict the diffusion value as a function of angle with the minimum diffusion value per voxel subtracted out for visualization purposes. Gaussian diffusion is observed in the major white matter bundles, including the corticospinal tract (at the level of the internal capsule and the foot of the corona radiata) and the corpus callosum, but non-Gaussian diffusion is seen at the corona radiata lateral to the lateral ventricle and medial to the Sylvian fissure (arrows).




Figure 2: Axial diffusion image with three-dimensional high angular resolution sampling. Note the non-Gaussian diffusion at the intersection of the descending cortico-fugal and callosal fibers.

the technique may help identify anisotropy in regions previously thought to be isotropic. Secondly, the observed non-Gaussian diffusion function may provide insight into how fiber populations add under partial volume. Lastly, the resolution of fiber intersections will benefit computational or visual tracking of white matter fiber pathways.

References — 1. P.J. Baser, *et al. Biophys. J.* 66, 259-267, 1994. 2. T.G. Reese, *et al. Magn. Reson. Med.* 34, 786-791, 1995. 3. D.G. Cory and A.N. Garraway. *Magn. Reson. Med.* 14, 435-444, 1990. 4. D.S. Tuch, *et al. NeuroImage* 7, S708, 1998. 5. T.G. Reese, *et al. Proc. ISMRM* 6, 663, 1998.