

High-Frame-Rate, Contrast-enhanced Ultrasound Particle Image Velocimetry in the Abdominal Aorta: first human results

Stefan Engelhard, MSc^a; Jason Voorneveld, MSc^b; Hendrik J Vos, PhD^b; Jos JM Westenberg, PhD^c; Frank JH Gijzen, PhD^b; Pavel Taimr, MD^d; Michel Versluis, PhD^e; Nico de Jong, PhD^{b,f}; Johan G Bosch, PhD^b; Michel MPJ Reijnen, MD, PhD^a; Erik Groot Jebbink, PhD^{a,e}

^a Department of Vascular Surgery, Rijnstate Hospital, Arnhem, The Netherlands

^b Department of Biomedical Engineering, Thorax Center, Erasmus MC, Rotterdam, The Netherlands

^c Department of Radiology, Leiden University Medical Center, Leiden, The Netherlands

^d Gastroenterology & Hepatology, Erasmus MC, Rotterdam, The Netherlands

^e Physics of Fluids group, Technical Medical (TechMed) centre, University of Twente, Enschede, The Netherlands

^f Department of Imaging Physics, Faculty of Applied Sciences, Delft University of Technology, Delft, the Netherlands

Corresponding author: Stefan Engelhard, MSc

Department of Surgery, Rijnstate Hospital, Wagnerlaan 55, 6815 AD Arnhem, The Netherlands.

Tel: +31 610437035, e-mail: sengelhard@rijnstate.nl

Prior presentation:

Preliminary data were presented at the VEITH symposium, New York – NY – USA, 17-11-2017

Technical aspects were presented at the US Contrast Imaging symposium, Rotterdam, NL, 18-1-2018

Final outcomes were presented at the CX symposium, London – UK, 24-4-2018

Financial support:

This work was supported in part by ZonMw within the Innovative Medical Devices Initiative (IMDI) program (project Heart Failure and 4D Flow, project number 104003001).

Abstract

Purpose – To study the feasibility of high-frame-rate (HFR) contrast material-enhanced (CE) ultrasound particle image velocimetry (PIV), or echo PIV, in the abdominal aorta.

Materials and Methods – Fifteen healthy participants (six men; median age, 23 years [age range, 18–34 years]; median body mass index, 20.3 kg/m² [range, 17.3–24.9 kg/m²]) underwent HFR CE US. US microbubbles were injected at incremental doses (0.25, 0.5, 0.75, and 1.5 mL), with each dose followed by US measurement to determine the optimal dosage. Different US mechanical index values were evaluated (0.09, 0.06, 0.03, and 0.01) in a diverging wave acquisition scheme. PIV analysis was performed via pairwise cross-correlation of all captured images. Participants also underwent phase-contrast MRI. The echo PIV and phase-contrast MRI velocity profiles were compared via calculation of similarity index and relative difference in peak velocity.

Results – Visualization of the aortic bifurcation with HFR CE US was successful in all participants. Optimal echo PIV results were achieved with the lowest contrast agent dose of 0.25 mL in combination with the lowest mechanical indexes (0.01 or 0.03). Substantial bubble destruction occurred at higher mechanical indexes (≥0.06). Flow patterns were qualitatively similar in the echo PIV and MR images. The echo PIV and MRI velocity profiles showed good agreement (similarity index, 0.98 and 0.99; difference in peak velocity, 8.5% and 17.0% in temporal and spatial profiles, respectively).

Conclusion – Quantification of blood flow in the human abdominal aorta with US particle image velocimetry (echo PIV) is feasible. Use of echo PIV has potential in the clinical evaluation of aortic disease.

Abbreviations List

CE	contrast enhanced
HFR	High-Frame-Rate
PIV	Particle Image Velocimetry

Introduction

Imaging of endovascular flow patterns in the abdominal aorta is challenging of endovascular but clinically flow patterns relevant in the because abdominal of the relationship between local hemodynamics and the development of vascular diseases (1–3).

Conventional Doppler US enables a one-dimensional blood flow velocity estimate in the axial direction. However, because the aortoiliac bifurcation is perpendicular to the transducer, it is difficult to obtain reliable flow quantification with Doppler imaging. In the carotid artery and the heart, US particle image velocimetry (hereafter, echo PIV) has been used to obtain two-dimensional velocity vector fields of blood flow in the axial and lateral directions (4,5). With this technique, US images are acquired and used for PIV analysis. Recent developments in the use of high-frame-rate (HFR) contrast material-enhanced (CE) US have improved the possibilities of quantifying blood flow with echo PIV. However, flow velocities of approximately 1 m/sec, which can be found in the human abdominal aorta, have not been successfully quantified until recently (6).

In the abdominal aorta, US is complicated by loss of signal due to bowel gas or imaging depth, which could be compensated by using US contrast agents. However, little is known about the amount of contrast agent required for optimal PIV analysis. In vitro models at an imaging depth of 10 cm suggested the feasibility of abdominal echo PIV with HFR CE US (7). The objective of this study was to investigate the feasibility of echo PIV to visualize blood flow in the human abdominal aorta by using phase-contrast MRI as a reference.

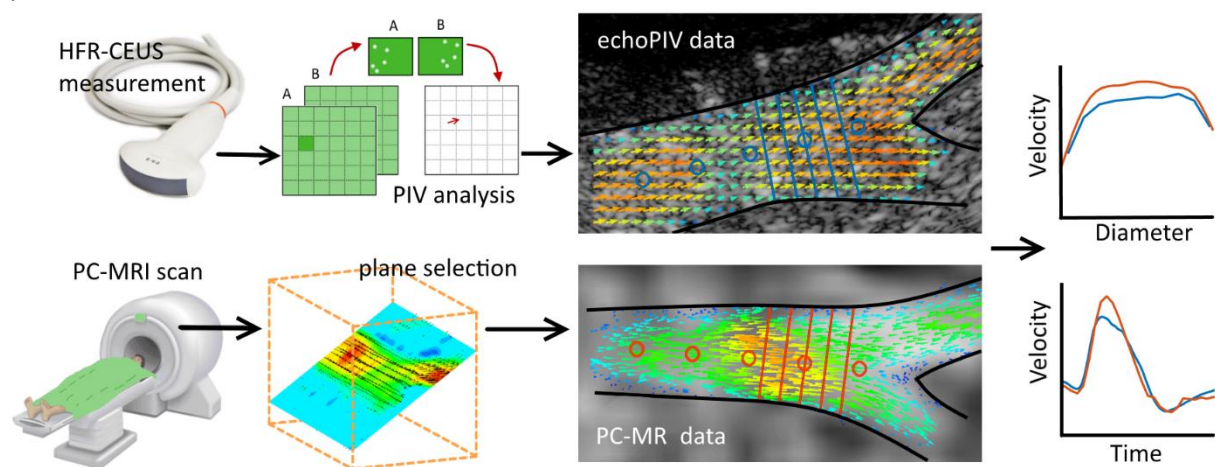


Figure 1: Overview of the measurement and registration method for the echo PIV and PC-MR data. Probe locations of temporal velocity profiles (circles) and spatial velocity profiles (lines) are shown in red (PC-MR) and blue (echo PIV).

Materials and Methods

This prospective within-subject exploratory study evaluated 15 healthy participants. US and MRI were performed in all participants in February and March 2017, with participants at rest in the supine position. Inclusion criteria were as follows: age of 18–35 years and body mass index of 25 kg/m² or less. Exclusion criteria were as follows: hypersensitivity to the excipients in the US contrast agent (SonoVue; Bracco, Milan, Italy), known history of cardiorespiratory diseases, uncontrolled systemic hypertension, pregnancy, and standard MRI exclusion criteria.

Volunteers who met the entry criteria were included in the study after they provided written informed consent. This study was conducted in accordance with Good Clinical Practice guidelines and was approved by an authorized institutional review board in the Netherlands (NL58025.078.16).

HFR CE Echo PIV

Echo PIV was performed with a fully programmable Vantage 256 US machine (Verasonics, Kirkland, Wash) with a curvilinear array abdominal probe (C5-2; ATL, Bothell, Wash). Before US, physical examination was performed and blood flow velocity in the distal abdominal aorta was measured with pulsed wave Doppler imaging by using an Epiq 7 US machine (Philips Healthcare, Best, the Netherlands).

A four-member research team performed the echo PIV measurements. The aortic bifurcation was visualized in a coronal oblique view by an experienced vascular technologist. The Vantage 256 US machine was controlled by a researcher (J.V.). Contrast agent was injected by a physician with experience in CE US examinations (P.T.). The Epiq 7 US machine was also used by a researcher (S.E.) for visual contrast monitoring in the left superficial femoral artery. A stable concentration of contrast agent was used for starting the HFR CE US measurements, and subsequent injections were given only after substantial washout of the agent.

For each measurement, images were captured for 2.5 seconds at 1000 frames per second using a three-angled diverging wave acquisition scheme. First, HFR measurement without contrast agent administration was performed. After this measurement, four incremental contrast agent doses were administered to each participant (0.25, 0.5, 0.75, and 1.5 mL) to investigate the optimal dose for PIV analysis. An overview of the measurement scheme is given in Table 1.

Mechanical index

Before the study, hydrophone pressure measurements were performed to guarantee that pressures in the ultrasound beam field were within safety limits (8) with the transducer at maximum transmitter voltage. Thereafter, transmitting voltage was set to 60% during the first participant measurements. Four measurement sessions were planned, with three or four participants per session. In each subsequent measurement session, the transmitter voltage was further reduced to investigate image contrast and microbubble behavior. The average mechanical index at a depth of 3–5 cm (depth of abdominal aorta) was calculated for each transmitter voltage used. By following this regimen, measurements were performed at mechanical indexes of 0.09, 0.06, 0.03, and 0.01 (Table 2).

Data analysis

Echo PIV data were processed offline. Singular value decomposition–based clutter suppression was applied to each of the three transmit angles individually (9). PIV analysis was performed by means of blockwise cross correlation between like-angled transmissions in each image pair by using a modified version of the open-source software PIVlab (V1.41; W. Thielicke) (10). The mean of the three resulting correlation maps was used for displacement estimation. A four-iteration cross-correlation approach was used, with a final block size of 7 3 6 mm and 75% overlap. A 15-frame temporal moving average filter and 5 3 3 Gaussian spatial filter were applied for smoothing of the obtained velocity data.

An extensive comparison of contrast agent doses, mechanical indexes, US acquisition schemes, and postprocessing methods that were used in this study is reported elsewhere (11).

Phase-contrast MRI

All participants underwent phase-contrast 3.0-T MRI (Ingenia; Philips Healthcare) by using a phased-array torso coil within 1 month before or after echo PIV measurements. Multisection two-dimensional survey acquisitions were obtained to localize the distal aorta and iliac arteries. Subsequently, a three-dimensional acquisition was performed with freebreathing retrospective vectorcardiography-gated gradientecho and echo planar imaging readout (repetition time msec/ echo time msec, 8.9/4.6; echo planar imaging factor, 5; flip angle, 10°). Standard four-point three-directional velocity encoding was

used with Venc (maximum velocity encoding) of 150 cm/sec (12). The acquisition volume captured the aortoiliac bifurcation, including renal and external iliac arteries, with 29 reconstructed 2-mm-thick sections, resulting in a voxel size of 1.8 3 1.8 3 2.0 mm. The cardiac cycle was reconstructed into 30 phases. True temporal resolution was 35.6 msec (ie, 4 3 the repetition time).

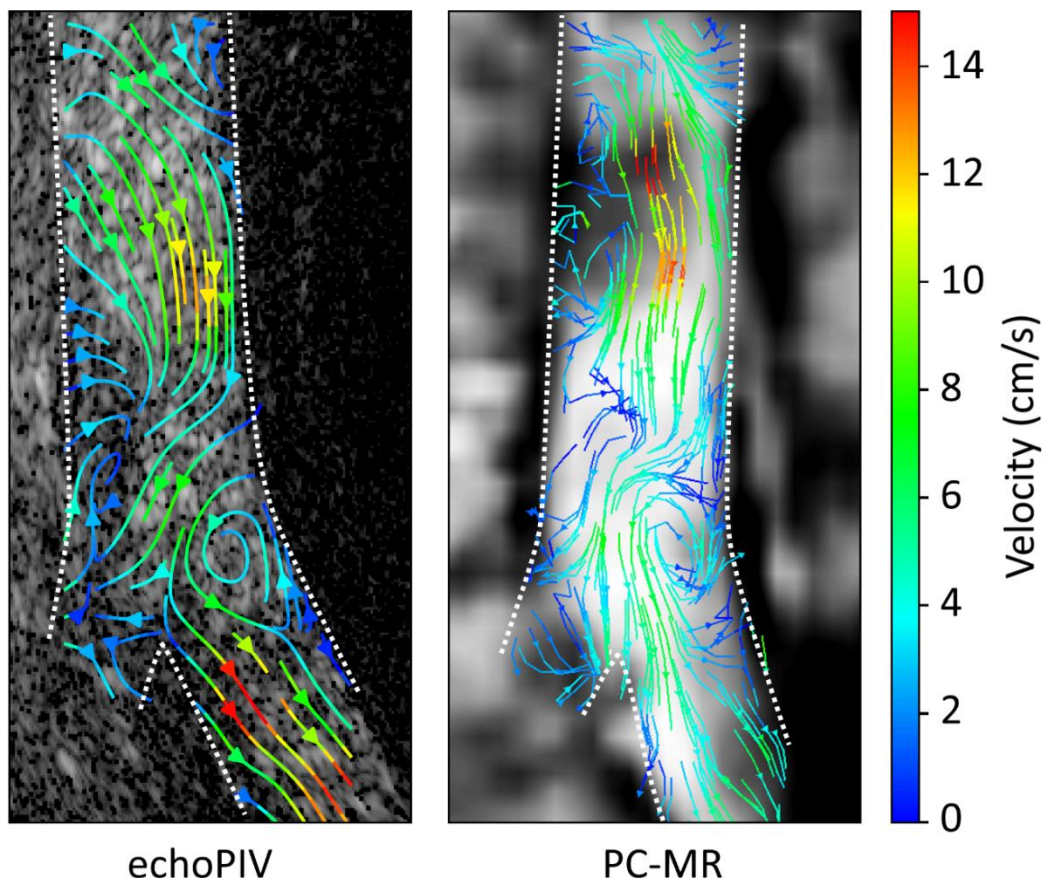


Figure 2: Streamline representation of blood flow velocities during early diastole in subject 7. Similar flow patterns can be observed in both datasets, including a slow recirculation zone near the origin of the left common iliac artery. This recirculation zone occurred during a longer time period in the PC-MR data (5 out of 30 phases), compared to the echo PIV data (10-15 milliseconds). The dashed white lines show an estimated delineation of the vessel wall.

Comparison of Echo PIV and Phase-contrast MRI

Quantitative comparisons of echo PIV and phase-contrast MRI velocity data were performed. For image registration, an in-house software package (MASS) was used to visualize the three-dimensional phase-contrast MRI velocity data in manually selected planes that showed anatomic dimensions similar to the echo PIV images. Qualitative comparison of the velocity images was performed.

To extract velocity profiles, the phase-contrast MRI data were imported into Tecplot 360 EX (2016 R1; Tecplot, Bellevue, Wash), and a plane was selected by using the previously mentioned method. Further processing and comparison of the data were performed by using Matlab (R2016a; MathWorks, Natick, Mass). Temporal velocity profiles were extracted from both data sets in five locations on the centerline of the aorta at 1-cm intervals proximal to the bifurcation apex (Fig 1). The time axis of the phase-contrast MRI data was matched to the echo PIV time axis. Spatial velocity profiles were extracted perpendicular to the centerline of the aorta in five locations 1–3 cm proximal to the bifurcation apex. Cosine similarity between the shape of the temporal and spatial velocity profiles of both data sets was used as a similarity index and was calculated as follows:

$$\frac{(V_{echoPIV}, V_{MRI})}{|V_{echoPIV}| |V_{MRI}|}$$

where $(V_{echoPIV}, V_{MRI})$ denotes the inner vector product and $|V_{echoPIV}| |V_{MRI}|$ is the vector length. Similarity index can range from 0 to 1, where a value of 1 means two curves are colinear. Difference in peak velocity was calculated relative to the phase-contrast MRI data. Bland-Altman analysis was performed for the temporal peak velocities.

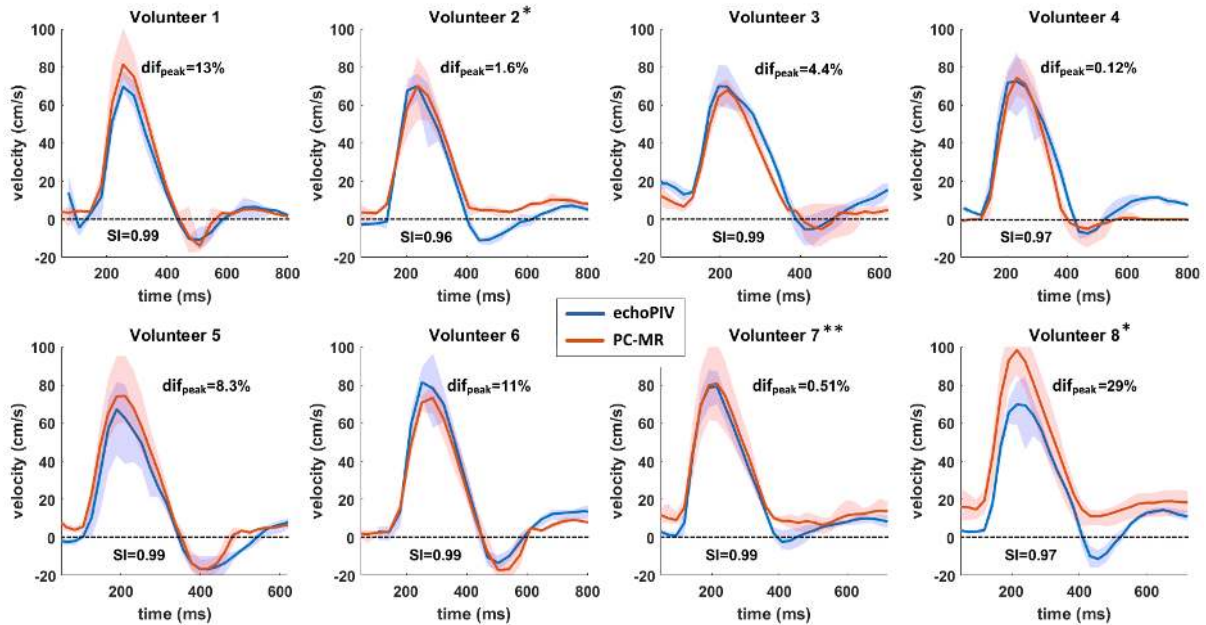


Fig 3: Temporal velocity profiles in 8 participants. The shaded areas represent the range of measured velocities in the 5 probed locations. Dif_{peak} = difference in peak velocity, relative to PC-MR data. SI = Similarity Index. * Participants where significant backflow was found in the echo PIV data, but not in the PC-MR data. ** subject where no significant backflow was found in either modality.

Results

Fifteen participants (six men) were included; their median age was 23 years (range, 18–34 years), and their median body mass index was 20.3 kg/m² (range, 17.3–24.9 kg/m²). Contrast agent injections and HFR CE US measurements were successful in all participants. Adequate echo PIV results (in terms of cross correlation) were achieved in all participants for all contrast agent doses (Movie 1 [online]). Without the US contrast agent, insufficient signal for PIV analysis remained after clutter suppression.

Mechanical Index

Mechanical indexes of 0.09 and 0.06 showed substantial destruction of contrast agent microbubbles in the abdominal aorta during echo PIV (Table 2). This resulted in contrast agent signals that were inadequate for PIV analysis during diastole. Bubble concentration was replenished during systole by new microbubbles entering the field of view. Contrast agent signal also decreased in the superficial femoral artery at the exact time of the HFR CE US measurements (Movie 2 [online]). With a mechanical index of 0.03, some bubble destruction was visible in the HFR CE US recordings, with no substantial signal decrease in the superficial femoral artery. Contrast agent signal during diastole was adequate for PIV analysis in these measurements. At a mechanical index of 0.01, no bubble destruction was observed. As a result of contrast agent destruction, only the measurements with mechanical indexes of 0.03 and 0.01, which were performed in eight study participants, were used for comparison of echo PIV and phase-contrast MRI (with 0.25 mL of contrast agent).

Flow assessment

Undisturbed forward blood flow was observed in all eight participants during systole for both modalities. During diastole, retrograde flow was observed with both modalities in all participants except participants 2, 7, and 8. In participants 2 and 8, only the echo PIV data showed backflow during diastole, while phase-contrast MRI data did not. The pulsed wave Doppler measurements agreed with the echo PIV measurements, showing a triphasic flow profile with a clear retrograde flow component. No significant retrograde flow was observed in participant 7 with either modality. In this participant, a period of relative blood stasis occurred during diastole. Flow patterns were similar in both the phase-contrast MRI and echo PIV data, including a recirculation zone near the origin of the left common iliac artery during diastole (Fig 2).

Velocity profiles

Temporal velocity profiles corresponded well between the echo PIV and phase-contrast MRI data sets (Fig 3). Mean similarity index was 0.98 (range, 0.96–0.99), and the mean difference in peak velocity was 8.5% (range, 0.09%–29%). Bland–Altman analysis is shown in Figure 4. Similar spatial velocity profiles were also found with both modalities

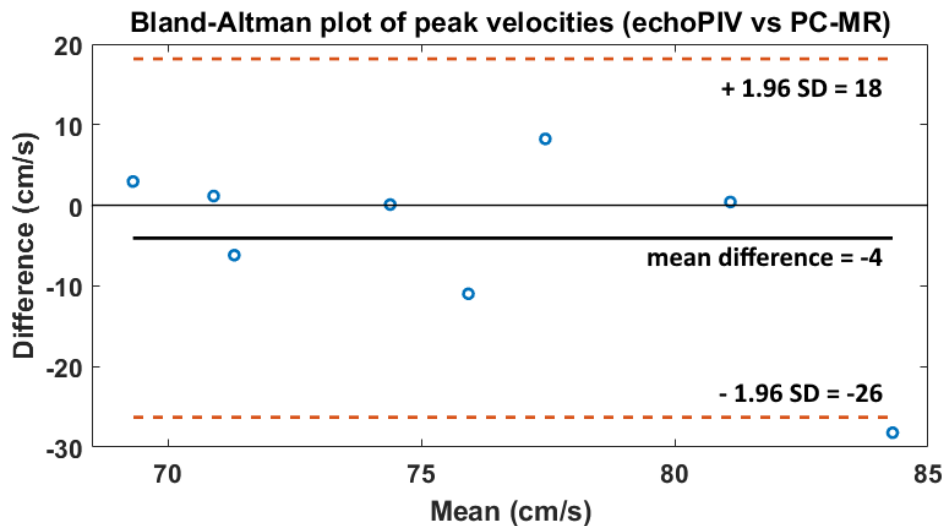


Fig 4: Bland-Altman plot of peak velocities in 8 participants.

The mean absolute difference between echo PIV and PC-MR peak velocities is -4 cm/s (echo PIV is 4 cm/s lower). The 95% confidence interval ranges from -26 to +18 cm/s. The negative mean difference is mainly caused by one outlier in the data (volunteer 8).

Discussion

This study shows that quantification of blood flow in the human abdominal aorta is possible with echo PIV, and velocity profiles and data correspond well with those seen with phase contrast MRI. This first-in-human study has demonstrated that assessment of flow patterns in the abdominal aorta is feasible, which can have major implications for the assessment of prognostic factors of vascular disease, indications for treatment, and clinical follow-up.

A large range of blood flow velocities, including velocities greater than 1 m/sec during systole, and very slow flow rates or blood stasis can be registered. In addition, two-dimensional vector fields of blood flow velocity can be used to evaluate flow disturbances, which is not possible with conventional Doppler imaging.

Analysis of the velocity profiles showed good overall agreement between the echo PIV and phase-contrast MRI data. Both techniques have similar spatial resolution (1.75 × 1.5 mm vector resolution and 2.6-mm US section thickness in echo PIV data versus 1.8 × 1.8 × 2.0 mm voxel size in phase-contrast MRI data), whereas the temporal resolution was 30 times higher for echo PIV (1000 frames per second in real time vs 30 phases per cardiac cycle with interleaved sampling in phase-contrast MRI data). Similar retrograde flow patterns were observed in six of eight participants studied. In participants 2 and 8, retrograde flow was observed in the echo PIV data and pulsed-wave Doppler measurements but not in the phase-contrast MRI data. This could indicate that flow quantification with echo PIV was more accurate in these participants because of a higher temporal resolution and no averaging of multiple heart cycles. However, the difference in flow patterns could also be explained by differences in body position or physiologic status of the participants during imaging.

Substantial bubble destruction occurred in the HFR CE US measurements with a mechanical index greater than or equal to 0.06. This caused a decrease in contrast agent signal that rendered echo PIV results unreliable during diastole. These results were unexpected because no bubble destruction was observed during in vitro testing with use of similar acquisition settings and maximum transmitter voltage (mechanical index < 0.15) (7). The reduced bubble stability in vivo could be attributed to several physiologic conditions (temperature, gas exchange, pressure) that were not accounted for in vitro (13–15). Image registration was performed by manual extraction of a two-dimensional plane from the phase-contrast MRI data to match the echo PIV data. The US insonification plane was not recorded and could therefore not be recreated in the volumetric phase-contrast MRI data. Neighbouring phase-contrast MRI planes were evaluated, showing clear differences in anatomic dimensions, whereas peak velocities showed differences of less than 10%. Thus, it is reasonable to assume that manual spatial matching of phase-contrast MRI and echo PIV data did not cause large differences in flow velocity.

In the echo PIV data, out-of-plane motion of US contrast agent and local imaging artefacts caused local decreases in correlation values and subsequent errors in the velocity vector fields. These errors were reduced by spatial smoothing, but this also removed details in the vector fields.

For echo PIV to become a clinically viable technique, further development is required in terms of ease of use, real-time data visualization, and calculation of derived flow parameters. Furthermore, prospective patient studies with echo PIV, in combination with long-term follow-up, are indicated to investigate the predictive value of these flow parameters.

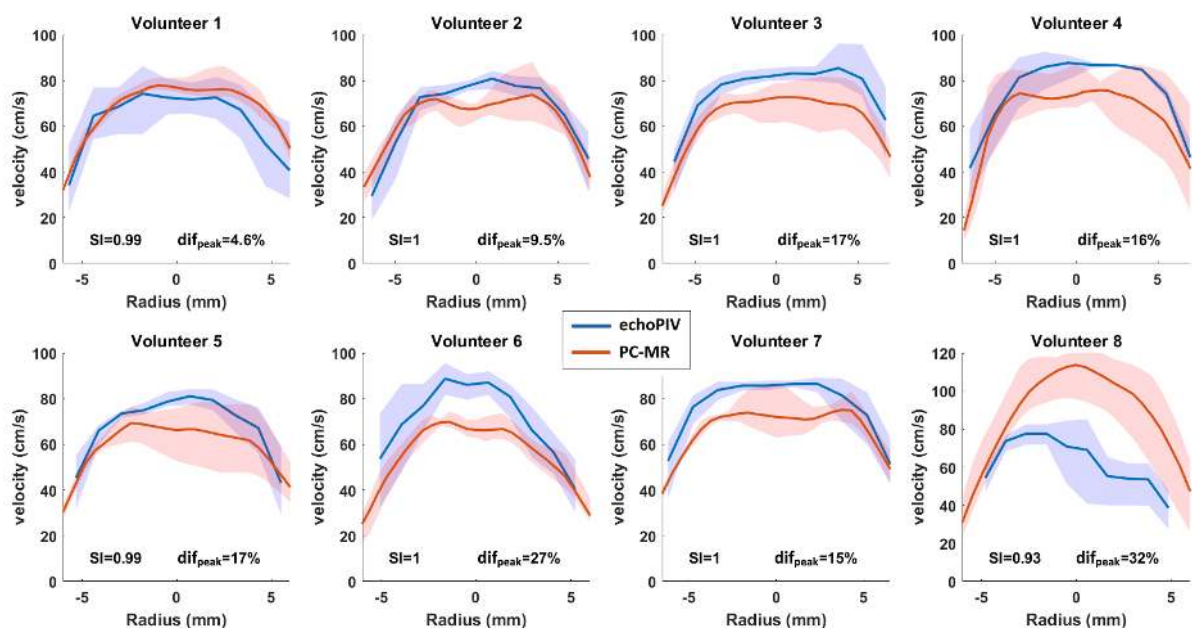


Fig 5: Spatial velocity profiles in 8 participants. The shaded areas represent the range of measured velocities in the 5 probe locations. Dif_{peak} = difference in peak velocity, relative to PC-MR data. SI = Similarity Index.

Conclusion

Quantification of blood flow in the abdominal aorta with echo PIV was performed in humans for the first time, demonstrating the feasibility of the technique. An optimal balance between image contrast and bubble concentration was found in a small cohort of healthy participants. The PIV velocity data showed good overall agreement with corresponding phase-contrast MRI data sets. Although it requires further development and validation, the echo PIV technique has great potential to enable quantitative diagnosis of vascular diseases and follow-up after treatment.

Acknowledgements

The authors thank Bastiaan Bongers for his contribution to the HFR-CEUS measurements and Pieter van den Boogaard for his contribution to the PC-MR scans.

References

1. Michel J-B, Martin-Ventura J-L, Egido J, Sakalihasan N, Treska V, Lindholt J, et al. Novel aspects of the pathogenesis of aneurysms of the abdominal aorta in humans. *Cardiovasc Res*. 2011. Available from: <http://cardiovascres.oxfordjournals.org/cgi/doi/10.1093/cvr/cvq337>
2. Greiner A, Mu H, Neuhauser B, Waldenberger P, Dessl A, Schocke MFH, et al. Does Stent Overlap Influence the Patency Rate of Aortoiliac Kissing Stents? *J Endovasc Ther*. 2005
3. Sharafuddin MJ, Hoballah JJ, Kresowik TF, Sharp WJ, Golzarian J, Sun S, et al. Long-term outcome following stent reconstruction of the aortic bifurcation and the role of geometric determinants. *Ann Vasc Surg* [Internet]. 2008 [cited 2015 Jun 9];22(3):346–57. Available from: <http://www.ncbi.nlm.nih.gov/pubmed/18411026>
4. Zhang F, Lanning C, Mazzaro L, Barker AJ, Gates PE, Strain WD, et al. In Vitro and Preliminary In Vivo Validation of Echo Particle Image Velocimetry in Carotid Vascular Imaging. *Ultrasound Med Biol* 2011. Available from: <http://linkinghub.elsevier.com/retrieve/pii/S0301562910006617>
5. Abe H, Caracciolo G, Kheradvar A, Pedrizzetti G, Khandheria BK, Narula J, et al. Contrast echocardiography for assessing left ventricular vortex strength in heart failure: A prospective cohort study. *Eur Heart J Cardiovasc Imaging*. 2013;14(11):1049–60.
6. Leow CH, Bazigou E, Eckersley RJ, Yu ACH, Weinberg PD, Tang M-X. Flow Velocity Mapping Using Contrast Enhanced High-Frame-Rate Plane Wave Ultrasound and Image Tracking: Methods and Initial in Vitro and in Vivo Evaluation. *Ultrasound Med Biol* [Internet]. 2015. Available from: <http://linkinghub.elsevier.com/retrieve/pii/S030156291500410X>
7. Voorneveld J, Kruizinga P, Vos HJ, Gijssen FJH, Groot Jebbink E, Van AFW. Native blood speckle vs ultrasound contrast agent for particle image velocimetry with ultrafast ultrasound – in vitro experiments. In: *IEEE International Ultrasonics Symposium Proceedings*. 2016.
8. United states Food and Drug Administration. Guidance for Industry and FDA Staff Information for Manufacturers Seeking Marketing Clearance of Diagnostic Ultrasound Systems and Transducers. 2008.
9. Demene C, Deffieux T, Pernot M, Osmanski B-F, Biran V, Gennisson J-L, et al. Spatiotemporal Clutter Filtering of Ultrafast Ultrasound Data Highly Increases Doppler and fUltrasound Sensitivity. *IEEE Trans Med Imaging*. 2015 Nov;34(11):2271–85.
10. Thielicke W, Stamhuis EJ. PIVlab – Towards User-friendly, Affordable and Accurate Digital Particle Image Velocimetry in MATLAB. *J Open Res Softw*. 2014;
11. Voorneveld J, Engelhard S, Vos HJ, et al. High frame rate contrast-enhanced ultrasound for velocimetry in the human abdominal aorta. *IEEE Trans Ultrason Ferroelectr Freq Control*
12. Garg P, Westenberg JJM, van den Boogaard PJ, Swoboda PP, Aziz R, Foley JRJ, et al. Comparison of fast acquisition strategies in whole-heart four-dimensional flow cardiac MR: Two-center, 1.5 Tesla, phantom and in vivo validation study. *J Magn Reson Imaging*. 2017
13. Mulvana H, Stride E, Hajnal J V., Eckersley RJ. Temperature dependent behavior of ultrasound

- contrast agents. *Ultrasound Med Biol.* 2010;36:925–34.
14. Kwan J, Borden M. Microbubble shell break-up and collapse during gas exchange. *Proc IEEE Ultrason Symp.* 2010;897–9.
 15. Brayman AA, Azadniv M, Miller MW, Meltzer RS. Effect of static pressure on acoustic transmittance of Albunex microbubble suspensions. *J Acoust Soc Am.* 1996;99:2403–8.

Tables

	Duration	Action
Examination 1: HFR-CEUS	5 min	- Physical examination and blood pressure
	5 min	- Instructions and visualisation of distal aorta - HFR control measurement (Verasonics machine)
	5 min	- Pulsed Wave Doppler measurement (Philips machine)
	5 min	- Insertion of venous cannula
	4 x 2-3 min	- US contrast agent injections (0.25, 0.5, 0.75 & 1.5 ml) - HFR-CEUS measurements (Verasonics machine)
Examination 2: PC-MR	10 min	- Instructions and scanning preparations
	1 hour	- PC-MR scanning

Table 1. Overview of activities for each study subject.

MI	# participants	Bubble destruction		Adequate contrast signal for PIV analysis
		HFR-CEUS images (Abdominal aorta)	Conventional US images (superficial femoral artery)	
0.09	4	Significant destruction	Significant destruction	no
0.06	3	Significant destruction	Significant destruction	no
0.03	4	Some loss of signal	No visible destruction	yes
0.01	4	No visible destruction	No visible destruction	yes

Table 2. Overview of MI and observations concerning bubble destruction. The velocity data of the participants measured with MI = 0.03 and 0.01 was used for comparison between echo PIV and PC-MR.

Supplemental video legends

Video 1:

Example of echo PIV velocity data subject 7. The video shows a single heartbeat in 15x slow-motion. Velocity vectors are color coded and move between frames, according to vector magnitude and direction.

Video 2:

Examples of conventional B-mode ultrasound recordings in the superficial femoral artery during High-frame-rate contrast-enhanced ultrasound (HFR-CEUS) measurements in the abdominal aorta, with different Mechanical Index (MI) levels. A: MI=0.06 and B: MI=0.01.