

# Higher-order aberrations after corneal collagen crosslinking for keratoconus and corneal ectasia

Steven A. Greenstein, MD, Kristen L. Fry, OD, MS, Matthew J. Hersh, Peter S. Hersh, MD

**PURPOSE:** To determine changes in higher-order aberrations (HOAs) after corneal collagen crosslinking (CXL).

**SETTING:** Cornea and refractive surgery practice.

**DESIGN:** Prospective randomized controlled clinical trial.

**METHODS:** Corneal and ocular HOAs were measured and analyzed using the Pentacam device and Ladarwave aberrometer, respectively, at baseline and 12 months after CXL.

**RESULTS:** Ninety-six eyes (64 keratoconus, 32 ectasia) of 73 patients had CXL. A fellow-eye control group comprised 42 eyes. The mean preoperative total anterior corneal HOAs, total coma, 3rd-order coma, and vertical coma were  $4.68 \mu\text{m} \pm 2.33$  (SD),  $4.40 \pm 2.32 \mu\text{m}$ ,  $4.36 \pm 2.30 \mu\text{m}$ , and  $4.04 \pm 2.27 \mu\text{m}$ , respectively. At 1 year, the mean values decreased significantly to  $4.27 \pm 2.25 \mu\text{m}$ ,  $4.01 \pm 2.29 \mu\text{m}$ ,  $3.96 \pm 2.27 \mu\text{m}$ , and  $3.66 \pm 2.22 \mu\text{m}$ , respectively (all  $P < .001$ ). There were no significant changes in posterior corneal HOAs. The mean preoperative total ocular HOAs, total coma, 3rd-order coma, trefoil, and spherical aberration were  $2.80 \pm 1.0 \mu\text{m}$ ,  $2.60 \pm 1.03 \mu\text{m}$ ,  $2.57 \pm 1.03 \mu\text{m}$ ,  $0.98 \pm 0.46 \mu\text{m}$ , and  $0.90 \pm 0.42 \mu\text{m}$ , respectively. At 1 year, the mean values decreased significantly to  $2.59 \pm 1.06 \mu\text{m}$ ,  $2.42 \pm 1.07 \mu\text{m}$ ,  $2.39 \pm 1.07 \mu\text{m}$ ,  $0.88 \pm 0.49 \mu\text{m}$ , and  $0.83 \pm 0.38 \mu\text{m}$ , respectively (all  $P = .01$ ). After CXL, HOAs were significantly improved compared with the control group. Changes in HOAs were not statistically associated with an improvement in visual acuity or most subjective visual symptoms, however.

**CONCLUSION:** Corneal and ocular HOAs decreased after CXL, suggesting an improvement in corneal shape.

**Financial Disclosure:** Dr. Hersh is medical monitor for Avedro, Inc. No author has a financial or proprietary interest in any material or method mentioned.

*J Cataract Refract Surg 2012; 38:292–302 © 2012 ASCRS and ESCRS*

Keratoconus and corneal ectasia after laser in situ keratomileusis (LASIK) are noninflammatory processes in which the corneal architecture deforms in association with thinning.<sup>1</sup> The progressive distortion of the cornea results in irregular astigmatism, progressive myopia, and increased higher-order aberrations (HOAs),<sup>2–6</sup> with consequent loss of visual function.

Recently, corneal collagen crosslinking (CXL) was introduced as a new therapy to mitigate the progression of these ectatic corneal disorders.<sup>7,8</sup> Findings in recent studies suggest that CXL can also have beneficial visual and optical effects,<sup>9–14</sup> with few reported complications.<sup>15–17</sup> In our previous reports of 1-year CXL outcomes,<sup>11,18</sup> patients had an improvement in corrected distance visual acuity (CDVA), uncorrected distance visual acuity (UDVA), maximum and average keratometry (K) values, and several quantitative indices of corneal topography.

In this study, to further assess optical quality after CXL, we evaluated the effect of CXL on HOAs by analyzing changes in anterior corneal HOAs, posterior corneal HOAs, and total ocular HOAs 1 year after treatment. In addition, changes in HOAs were correlated with changes in visual acuity (UDVA and CDVA) and patient-reported visual symptoms.

## PATIENTS AND METHODS

Patients with progressive keratoconus and ectasia after LASIK, were enrolled as part of a multicenter prospective randomized controlled clinical trial.<sup>A,B</sup> This study was approved and monitored by an investigational review board and complied with the U.S. Health Insurance Portability and Accountability Act. Informed consent was obtained from all patients.

The inclusion criteria included 14 years of age or older and axial topography consistent with keratoconus or corneal ectasia. Progressive keratoconus or ectasia was defined as

1 or more of the following changes over 24 months: an increase of 1.00 diopter (D) or more in the steepest K value, an increase of 1.00 D or more in manifest cylinder, or an increase of 0.50 D or more in manifest refraction spherical equivalent. Exclusion criteria included a history of corneal surgery (except previous intrastromal corneal ring segment removal), chemical injury, delayed epithelial healing, and a corneal pachymetry less than 300  $\mu\text{m}$ .

### Treatment Group

Collagen crosslinking was performed according to the methodology described by Wollensak et al.<sup>1</sup> Topical anesthesia was administered, and the corneal epithelium was removed by mechanical debridement over the central 9.0 mm. Riboflavin (0.1% in 20% dextran T500 solution, Medio-Cross, Peschke Meditrade GmbH) was then administered topically every 2 minutes for 30 minutes. After riboflavin administration, riboflavin absorption throughout the corneal stroma and anterior chamber was confirmed on slitlamp examination. Ultrasound (US) pachymetry was performed and if the cornea was less than 400  $\mu\text{m}$ , hypotonic riboflavin (0.1% in sterile water, Medio-Cross hypotonic) was administered, 1 drop every 10 seconds for 2-minute sessions, after which US pachymetry was performed to confirm that the stroma had swollen to more than 400  $\mu\text{m}$ . This was repeated until adequate corneal thickness was obtained.

The cornea was exposed to ultraviolet-A (UVA) 365 nm light (UV-X system, IROC AG) for 30 minutes at an irradiance of 3.0 mW/cm<sup>2</sup>. During UV exposure, riboflavin drops were continued every 2 minutes.

Postoperatively, antibiotic and corticosteroid drops were administered and a therapeutic soft contact lens (Accuvue Oasys, Vistakon) was placed. The contact lens was removed after epithelial healing, typically 3 to 5 days postoperatively. Antibiotic drops were continued for 1 week and corticosteroid drops for 2 weeks.

### Control Group

In this study, a fellow-eye control group was analyzed. This group comprised the fellow eyes of patients who did not have CXL bilaterally and included eyes with frank keratoconus or ectasia that did not have CXL, eyes with evidence of disease that did not meet the study's inclusion criteria, and

eyes with no evidence of disease. Anterior and posterior corneal HOAs were measured and analyzed at baseline and 12 months. Unlike the treated eyes, fellow eyes were not dilated at the 12-month follow-up examination. Therefore, ocular HOA data were not available for the control group.

### Higher-Order Aberrations Measurements

Anterior and posterior corneal aberrations over the central 6.5 mm were measured preoperatively and at 12 months postoperatively using the Pentacam device (Oculus Inc.). The device extrapolates anterior corneal HOA and posterior corneal HOA Zernike coefficients from corneal elevation data obtained by Scheimpflug imagery.

Ocular HOAs were measured through a 6.5 mm pupil using a Ladarwave wavefront aberrometer (Alcon Laboratories, Inc.). This Shack-Hartmann aberrometer measures total ocular HOAs. Measurements were performed after the eyes were dilated preoperatively and 12 months postoperatively. If ocular HOAs could not be measured after multiple attempts (usually on the basis of a markedly distorted cornea), the patient was removed from the ocular HOA analysis.

For corneal and ocular HOAs, the changes in total HOAs (3rd to 6th order), total coma (3rd and 5th order), 3rd-order coma, vertical coma, horizontal coma, spherical aberration (4th and 6th), and trefoil aberrations were analyzed.

### Visual Acuity and Symptoms

The UDVA and CDVA were measured preoperatively and 1 year postoperatively. High-contrast visual acuity measurements were obtained under controlled lighting conditions using a modified Lighthouse Early Treatment of Diabetic Retinopathy Study (ETDRS) visual acuity test (2nd edition) with Sloan letters. Patients were tested 4 m from the visual acuity chart. If patients could not read any letters at 4 m, they were tested at 2 m.

To further ascertain changes in visual function that occur after CXL, patients completed a subjective questionnaire on their visual symptoms. The questionnaire was administered preoperatively and at 1 year. Patients ranked symptoms on a scale from 1 to 5 (1 = none; 2 = mild; 3 = moderate; 4 = marked; 5 = severe). In this study, the visual symptoms analyzed included difficulty driving at night, glare, halos, and starbursts (Figure 1).

### Statistical Analysis

Statistical analysis was performed using PASW software (version 18, SPSS, Inc.). The change in the root-mean-square (RMS) wavefront error was analyzed in 3 groups: the entire cohort and subgroups stratified to a diagnosis of keratoconus or ectasia. A paired 2-tailed Student *t* test was used to analyze the postoperative changes compared with baseline values. An independent *t* test was used to compare measurement data 12 months postoperatively between the keratoconus subgroup and ectasia subgroup and between the treatment group and the control group.

To determine whether changes in HOAs were related to visual acuity outcomes, the relationship between the change in these aberrations between baseline and 12 months and the 1-year changes in CDVA and the UDVA were analyzed. Similarly, to determine whether changes in HOAs were related to visual symptoms, the relationship between the change

Submitted: February 14, 2011.

Final revision submitted: August 24, 2011.

Accepted: August 27, 2011.

From the Cornea and Laser Eye Institute–Hersh Vision Group (Greenstein, Fry, M. Hersh, P. Hersh), CLEI Center for Keratoconus, Teaneck, and the Department of Ophthalmology (Greenstein, P. Hersh) UMDNJ–New Jersey Medical School, Newark, New Jersey, USA.

Supported in part by Peschke Meditrade, GmbH, Zurich, Switzerland, and by an unrestricted grant to the Department of Ophthalmology, UMDNJ–New Jersey Medical School, from Research to Prevent Blindness, Inc., New York, New York, USA.

Corresponding author: Peter S. Hersh, MD, Cornea and Laser Eye Institute–Hersh Vision Group, CLEI Center for Keratoconus, 300 Frank W. Burr Boulevard, Teaneck, New Jersey 07666, USA. E-mail: phersh@vision-institute.com.

### PATIENT QUESTIONNAIRE

Please grade your experience with each of the following symptoms by checking within the appropriate boxes below, using a scale of 1 through 5 (1 being "none" and 5 being "severe").

Please grade each eye.

RIGHT EYE	None (1)	Mild (2)	Moderate (3)	Marked (4)	Severe (5)
Light Sensitivity					
Difficulty Driving at Night <i>(If you drive at night)</i>					
Reading Difficulty <i>(Requires glasses to read)</i>					
Double Vision					
Fluctuation in Vision					
Glare <i>(Scatter from bright light that decreases vision)</i>					
Halos <i>(Rings around lights)</i>					
Starbursts <i>(Star-shapes around lights)</i>					
Dryness					
Pain					
Foreign Body Sensation <i>(Feels like something is in your eye)</i>					
Other:					

LEFT EYE	None (1)	Mild (2)	Moderate (3)	Marked (4)	Severe (5)
Light Sensitivity					
Difficulty Driving at Night <i>(If you drive at night)</i>					
Reading Difficulty <i>(Requires glasses to read)</i>					
Double Vision					
Fluctuation in Vision					
Glare <i>(Scatter from bright light that decreases vision)</i>					
Halos <i>(Rings around lights)</i>					
Starbursts <i>(Star-shapes around lights)</i>					
Dryness					
Pain					
Foreign Body Sensation <i>(Feels like something is in your eye)</i>					
Other:					

Figure 1. Patient questionnaire.

in these aberrations between baseline and 12 months and the 1-year changes in reported visual symptoms were also analyzed using Pearson correlation coefficients. A *P* value less than 0.05 was used to determine statistical significance.

## RESULTS

Ninety-six eyes (64 in keratoconus subgroup; 32 in ectasia subgroup) of 73 patients had CXL and were followed for 1 year. Anterior corneal HOAs and posterior corneal HOAs were measured in all 96 eyes. Ocular HOAs were measured in 48 eyes (31 keratoconus,

17 ectasia). The fellow-eye control group comprised 42 eyes (26 keratoconus, 16 ectasia).

### Anterior Corneal Aberrations

The mean preoperative and 1-year postoperative anterior corneal HOAs are shown in Table 1 and Figure 2, top. The total anterior corneal HOAs improved by more than 1.0  $\mu\text{m}$  in 14 eyes (9 keratoconus, 5 ectasia) and by 0.0 to 1.0  $\mu\text{m}$  in 57 eyes (40 keratoconus, 17 ectasia). The total anterior corneal HOAs worsened by 0.0 to 1.0  $\mu\text{m}$  in 24 eyes (15 keratoconus,

**Table 1.** Anterior and posterior corneal HOAs in the treatment group.

Parameter	Mean ( $\mu\text{m}$ ) $\pm$ SD						
	Total HOAs	Total Coma*	3rd-Order Coma	Vertical Coma	Horizontal Coma	Trefoil	Spherical Aberrations
Anterior corneal HOAs (n = 96)							
Preop	4.68 $\pm$ 2.33	4.40 $\pm$ 2.32	4.36 $\pm$ 2.30	4.04 $\pm$ 2.27	1.26 $\pm$ 0.99	0.37 $\pm$ 0.36	1.40 $\pm$ 0.76
1 year postop	4.27 $\pm$ 2.25 <sup>†</sup>	4.01 $\pm$ 2.29 <sup>†</sup>	3.96 $\pm$ 2.27 <sup>†</sup>	3.66 $\pm$ 2.22 <sup>†</sup>	1.14 $\pm$ 0.95	0.42 $\pm$ 0.41	1.29 $\pm$ 0.60
Posterior corneal HOAs (n = 96)							
Preop	8.87 $\pm$ 5.05	8.15 $\pm$ 4.76	7.98 $\pm$ 4.67	7.24 $\pm$ 4.37	2.60 $\pm$ 2.37	1.00 $\pm$ 0.75	3.19 $\pm$ 2.24
1 year postop	8.70 $\pm$ 4.68	8.06 $\pm$ 4.52	7.92 $\pm$ 4.45	7.23 $\pm$ 4.20	2.54 $\pm$ 2.12	1.02 $\pm$ 0.82	2.99 $\pm$ 1.77
Ocular HOAs (N = 48)							
Preop	2.80 $\pm$ 1.00	2.60 $\pm$ 1.03	2.57 $\pm$ 1.03	2.17 $\pm$ 2.23	0.57 $\pm$ 0.94	0.98 $\pm$ 0.46	0.90 $\pm$ 0.42
1 year postop	2.59 $\pm$ 1.06 <sup>†</sup>	2.42 $\pm$ 1.07 <sup>†</sup>	2.39 $\pm$ 1.07 <sup>†</sup>	2.05 $\pm$ 2.11	0.56 $\pm$ 0.98	0.88 $\pm$ 0.49 <sup>†</sup>	0.83 $\pm$ 0.38 <sup>†</sup>

HOAs = higher-order aberrations  
 \*Combined 3rd and 5th orders  
<sup>†</sup>Statistically significant change

8 ectasia) and by more than 1.0  $\mu\text{m}$  in 1 eye (with ectasia) (Figure 2, bottom).

The mean changes in total HOAs, total coma (combined 3rd and 5th order), 3rd-order coma, and vertical coma were statistically significant, but the changes in

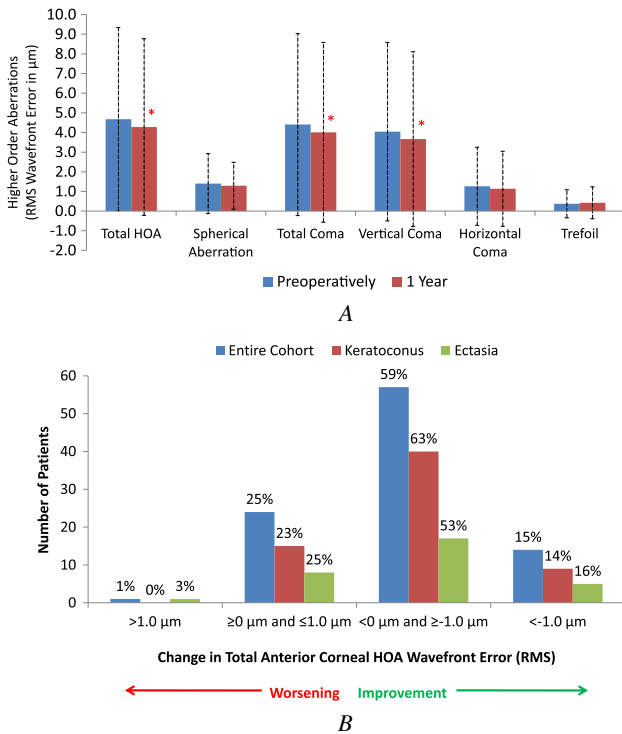
horizontal coma, trefoil, and spherical aberration were not.

**Posterior Corneal Aberrations**

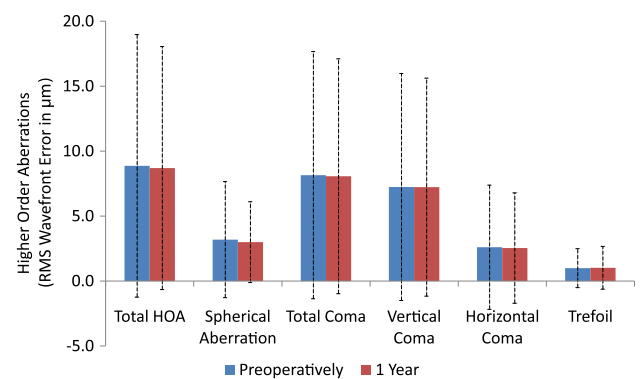
The mean preoperative and 1-year postoperative posterior corneal HOAs are shown in Table 1 and Figure 3. All but one decreased, but no change was statistically significant.

**Total Ocular Aberrations**

The mean preoperative and 1-year postoperative ocular HOAs are shown in Table 1 and Figure 4, top. The total ocular HOAs improved by more than 1.0  $\mu\text{m}$  in 5 patients (all keratoconus) and by 0.0 to 1.0  $\mu\text{m}$  in 28 patients (18 keratoconus, 10 ectasia). The total ocular HOAs worsened by 0.0 to 1.0  $\mu\text{m}$  in 15 patients (8 keratoconus, 7 ectasia) and by more than 1.0  $\mu\text{m}$  in no patient (Figure 4, bottom).

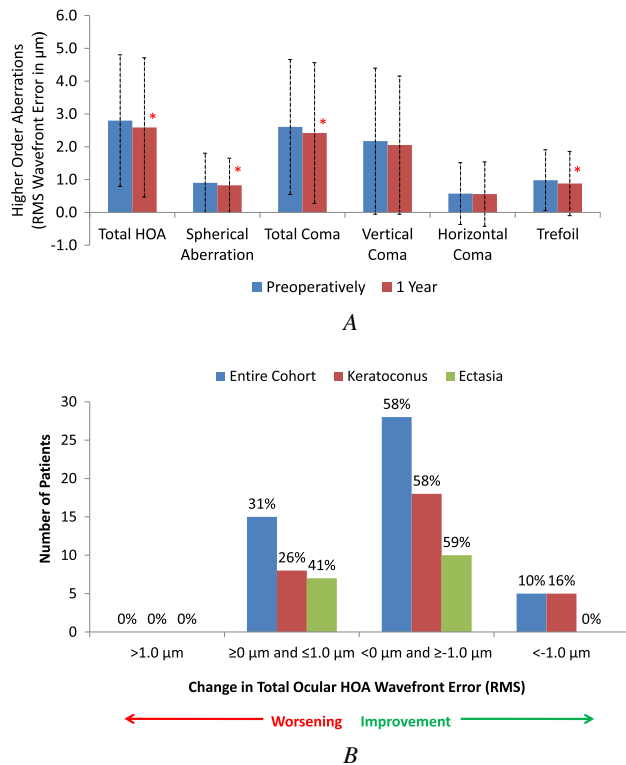


**Figure 2.** A: Anterior corneal HOAs (RMS wavefront error) preoperatively and at 1 year after CXL. Error bars represent 2 standard deviations from the mean. Asterisks indicate a significant change compared with preoperative measurements ( $P < .05$ ). B: Individual changes in anterior corneal HOA wavefront error between baseline and 1 year postoperatively (n = 96 eyes) (HOA = higher-order aberration; RMS = root mean square).



**Figure 3.** Posterior corneal HOAs (RMS wavefront error) preoperatively and at 1 year. Error bars represent 2 standard deviations from the mean ( $\mu\text{m}$ ) (HOA = higher-order aberration; RMS = root mean square).





**Figure 4.** A: Ocular HOAs (RMS wavefront error) preoperatively and at 1 year after CXL. Error bars represent 2 standard deviations from the mean. Asterisks indicate a significant change compared with preoperative measurements ( $P < .05$ ). B: Individual changes in ocular HOA wavefront error between baseline and 1 year postoperatively ( $n = 48$  eyes) (HOA = higher-order aberration; RMS = root mean square).

The mean changes in total HOAs, total coma, 3rd-order coma, trefoil, and spherical aberration were statistically significant, but the changes in vertical coma and horizontal coma were not.

### Keratoconus Subgroup Versus Ectasia Subgroup

Table 2 shows the individual anterior corneal, posterior corneal, and ocular HOA data in the keratoconus subgroup and the ectasia subgroup. In general, there were larger mean changes in anterior corneal HOAs and ocular HOAs in the keratoconus subgroup than in the ectasia subgroup (Figure 5). However, there was no statistically significant difference in the CXL-mediated changes in HOAs between the keratoconus subgroup and the ectasia subgroup.

### Clinical Correlation with Visual Acuity and Subjective Visual Function Symptoms

Analysis of all 96 eyes in the study showed significant improvement in logMAR UDVA and logMAR CDVA at 1 year (mean change  $-0.09 \pm 0.25$  lines

and  $-0.10 \pm 0.18$  lines, respectively; both  $P = .001$ ). Similarly, there was a significant improvement in the mean UDVA and CDVA in the 48 eyes included in the analysis of ocular HOAs (mean change  $-0.13 \pm 0.22$  lines and  $-0.12 \pm 0.19$  lines, respectively; both  $P < .001$ ). However, neither the improvement in UDVA nor the improvement in CDVA was significantly correlated with the improvement in ocular HOAs or anterior corneal HOAs after CXL (Table 3).

To further elucidate possible associations of post-CXL HOA changes with UDVA and CDVA, eyes were stratified to 2 groups; that is, those that had an improvement in HOAs and those in which HOAs worsened after CXL. Table 4 shows the preoperative and postoperative UDVA and CDVA measurements in these 2 groups. There were no significant between-group differences in anterior corneal HOAs (UDVA:  $P = .86$ ; CDVA:  $P = .15$ ) or ocular HOAs (UDVA:  $P = .62$ ; CDVA:  $P = .13$ ).

On the subjective symptom questionnaire, the mean preoperative rating (96 eyes) was  $3.1 \pm 1.3$  for difficulty driving at night,  $3.1 \pm 1.2$  for the presence of glare,  $2.9 \pm 1.4$  for the presence of starbursts (Figure 6). At 1 year, there was a significant decrease in reported glare ( $2.8 \pm 1.2$ ;  $P = .004$ ). There was a mean decrease in reported difficulty with night driving ( $2.9 \pm 1.3$ ), the presence of halos ( $2.7 \pm 1.3$ ), and the presence of starbursts ( $2.5 \pm 1.4$ ); however, these changes failed to reach statistical significance ( $P = .8$ ,  $P = .07$ , and  $P = .6$ , respectively). In the 48 eyes included in the ocular HOA analysis, the mean preoperative rating was  $3.1 \pm 1.4$  for difficulty driving at night,  $2.8 \pm 1.3$  for the presence of glare,  $2.7 \pm 1.4$  for the presence of halos, and  $2.3 \pm 1.4$  for the presence of starbursts. At 1 year, there was a mean decrease in reported difficulty with night driving ( $3.1 \pm 1.4$ ), the presence of glare ( $2.6 \pm 1.2$ ), the presence of halos ( $2.6 \pm 1.3$ ), and the presence of starbursts ( $2.5 \pm 1.4$ ); however, these changes failed to reach statistical significance ( $P = .8$ ,  $P = 0.3$ ,  $P = .6$ , and  $P = .2$ , respectively).

As with the visual acuity analysis, there was no correlation between an improvement in any HOA and an improvement in subjective visual function symptoms of night driving, glare, and halos after CXL (Table 5). However, there was a statistically significant correlation between the change in total ocular HOAs and the change in reported starbursts 1 year after CXL ( $r = 0.5$ ,  $P < .001$ ).

### Control Group

**Anterior Corneal Aberrations** The mean preoperative and 1-year postoperative anterior corneal HOAs are shown in Table 6. There was a mean increase in

**Table 2.** Higher-order aberrations in the keratoconus subgroup and ectasia subgroup.

Group/Parameter	Mean (μm) ± SD						
	Total HOA	Spherical Aberrations	Total Coma*	Primary Coma	Vertical Coma	Horizontal Coma	Trefoil Coma
<b>Keratoconus</b>							
Anterior corneal HOAs (n = 64)							
Preop	4.57 ± 2.09	1.34 ± 0.85	4.32 ± 2.01	4.28 ± 2.00	3.95 ± 1.96	1.26 ± 1.02	0.36 ± 0.35
1 year postop	4.11 ± 1.92 <sup>†</sup>	1.18 ± 0.61 <sup>†</sup>	3.88 ± 1.93 <sup>†</sup>	3.84 ± 1.91 <sup>†</sup>	3.53 ± 1.85 <sup>†</sup>	1.10 ± 0.94 <sup>†</sup>	0.45 ± 0.46
Posterior corneal HOAs (n = 64)							
Preop	8.83 ± 4.87	3.17 ± 2.25	8.13 ± 4.54	7.94 ± 4.45	7.17 ± 4.02	2.66 ± 2.59	0.98 ± 0.81
1 year postop	8.85 ± 4.45	3.00 ± 1.82	8.22 ± 4.27	8.07 ± 4.20	7.34 ± 3.90	2.65 ± 2.17	1.10 ± 0.86
Ocular HOAs (n = 31)							
Preop	2.83 ± 1.08	0.80 ± 0.40	2.69 ± 1.07	2.65 ± 1.07	2.34 ± 1.13	0.47 ± 0.37	0.93 ± 0.46
1 year postop	2.55 ± 1.17 <sup>†</sup>	0.73 ± 0.33	2.43 ± 1.16 <sup>†</sup>	2.39 ± 1.15 <sup>†</sup>	2.13 ± 1.14 <sup>†</sup>	0.40 ± 0.34	0.83 ± 0.52
<b>Ectasia</b>							
Anterior corneal HOAs (n = 32)							
Preop	4.89 ± 2.78	1.51 ± 0.57	4.57 ± 2.86	4.53 ± 2.85	4.22 ± 2.82	1.27 ± 0.95	0.40 ± 0.38
1 year postop	4.61 ± 2.79 <sup>†</sup>	1.50 ± 0.52	4.27 ± 2.89 <sup>†</sup>	4.21 ± 2.90 <sup>†</sup>	3.93 ± 2.84	1.21 ± 0.99	0.36 ± 0.26
Posterior corneal HOAs (n = 32)							
Preop	8.95 ± 5.17	3.22 ± 2.27	8.19 ± 5.24	8.05 ± 5.16	7.39 ± 5.06	2.48 ± 1.96	1.01 ± 0.63
1 year postop	8.38 ± 5.17 <sup>†</sup>	2.98 ± 1.70	7.74 ± 5.03	7.62 ± 4.98	7.02 ± 4.79	2.32 ± 2.04	0.86 ± 0.73
Ocular HOAs (n = 17)							
Preop	2.74 ± 0.87	1.09 ± 0.41	2.45 ± 0.97	2.42 ± 0.97	1.86 ± 1.04	0.77 ± 0.57	1.07 ± 0.46
1 year postop	2.67 ± 0.85	1.00 ± 0.42	2.41 ± 0.94	2.39 ± 0.94	1.91 ± 0.90	0.84 ± 0.61	0.97 ± 0.42

HOAs = higher-order aberrations

\*Combined 3rd and 5th orders

<sup>†</sup>Statistically significant change compared with preoperative measurements (*P* < .05)

all anterior corneal HOAs except trefoil at the 1-year examination, but none was statistically significant.

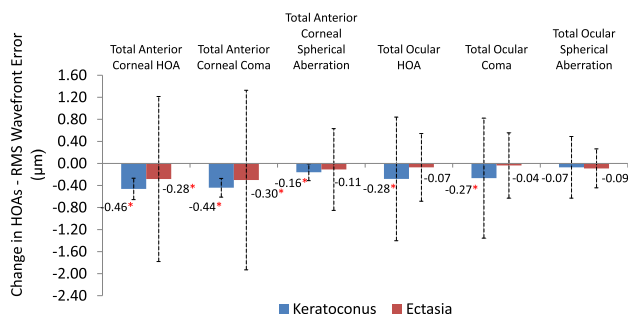
**Posterior Corneal Aberrations** The mean preoperative and 1-year postoperative posterior corneal HOAs are shown in Table 6. The mean increases in total posterior corneal HOAs, total coma, and 3rd-order coma were statistically significant, but the mean increases in

vertical coma, horizontal coma, trefoil, and spherical aberration were not.

**Treatment Versus Control Groups**

**Anterior Corneal Aberrations** Preoperatively, all anterior corneal HOAs were significantly higher in the treatment group than in the control group (all *P* < .001, except spherical, which was *P* = .009). At 1 year, all anterior corneal HOAs remained significantly higher in the treatment group than in the control group (all *P* < .001, except spherical, which was *P* = .004). At 1 year, however, there was a mean decrease in anterior corneal HOAs in the treatment group and a mean increase in anterior corneal HOAs in the control group. The differences in anterior corneal HOA changes between the treatment group and the control group were statistically significant over time (all *P* < .001 except coma and spherical, which were both *P* = .04). There was no statistically significant difference in the change in trefoil from baseline to 1 year between the treatment group and the control group (*P* = .2).

**Posterior Corneal Aberrations** Preoperatively, all posterior corneal HOAs in the treatment group were significantly higher than in the control group (all *P* < .001). At 1 year, all posterior corneal HOAs



**Figure 5.** Comparison of 1-year change in anterior corneal HOAs and ocular HOAs between patients with keratoconus and patients with corneal ectasia. Error bars represent 2 standard deviations from the mean. Asterisks indicate a significant change compared with preoperative measurements (*P* < .05) (HOA = higher-order aberration; RMS = root mean square).

**Table 3.** Correlation between HOAs and visual acuity measurements at 1 year.

Group/Parameter	Pearson Correlation Coefficient						
	Total HOA	Spherical Aberrations	Total Coma*	Primary Coma	Vertical Coma	Horizontal Coma	Trefoil Coma
Entire cohort							
UDVA							
Anterior corneal HOAs (n = 96)	0.6	-0.8	1.0	0.1	0.1	0.2 <sup>†</sup>	-0.3 <sup>†</sup>
Posterior corneal HOAs (n = 96)	0.1	-0.08	0.04	0.6	0.07	0.02	-0.07
Ocular HOAs (n = 48)	-0.2	-0.01	-0.2	-0.2	-0.2	-0.1	-0.1
CDVA							
Anterior corneal HOAs (n = 96)	0.03	-0.02	0.04	0.04	0.03	0.06	-0.01
Posterior corneal HOAs (n = 96)	0.03	0.1	0.02	0.01	-0.04	0.1	0.1
Ocular HOAs (n = 48)	0.04	0.02	0.05	0.07	0.05	-0.05	-0.04
Keratoconus							
UDVA							
Anterior corneal HOAs (n = 64)	0.1	0.01	0.1	0.1	0.1	0.4 <sup>†</sup>	-0.3 <sup>†</sup>
Posterior corneal HOAs (n = 64)	-0.02	-0.07	-0.01	0.01	0.01	0.07	-0.1
Ocular HOAs (n = 31)	-0.2	-0.1	-0.2	-0.2	-0.1	0.1	-0.2
CDVA							
Anterior corneal HOAs (n = 64)	0.1	-0.03	0.1	0.1	0.1	-0.01	0.05
Posterior corneal HOAs (n = 64)	0.1	0.1	0.1	0.05	0.02	0.1	-0.01
Ocular HOAs (n = 31)	-0.01	0.01	-0.01	-0.02	-0.02	-0.08	-0.09
Ectasia							
UDVA							
Anterior corneal HOAs (n = 32)	0.06	-0.3	0.1	0.2	0.2	-0.07	-0.4 <sup>†</sup>
Posterior corneal HOAs (n = 32)	0.01	-0.1	0.09	0.1	0.1	-0.2	-0.06
Ocular HOAs (n = 17)	0.01	0.2	-0.06	-0.07	-0.2	-0.2	0.2
CDVA							
Anterior corneal HOAs (n = 32)	-0.2	-0.03	-0.2	-0.1	-0.2	0.3	-0.2
Posterior corneal HOAs (n = 32)	-0.06	0.3	-0.1	-0.1	-0.2	0.1	0.4 <sup>†</sup>
Ocular HOAs (n = 17)	0.3	0.1	0.3	0.3	0.2	-0.1	0.2

CDVA = corrected distance visual acuity; HOAs = higher-order aberrations; UDVA = uncorrected distance visual acuity

\*Combined 3rd and 5th orders

<sup>†</sup>Statistically significant ( $P < .05$ )

remained significantly higher in the treatment group than in the control group (all  $P < .001$ ). At 1 year, there was a mean decrease in posterior corneal HOAs in the treatment group and a mean increase in posterior corneal HOAs in the control group. However, these differences between groups failed to reach statistical significance (total:  $P = .07$ ; total coma:  $P = .1$ ; 3rd-order coma:  $P = .1$ ; vertical coma:  $P = .2$ ; horizontal coma:  $P = .4$ ; trefoil:  $P = .09$ ; spherical:  $P = .08$ ).

## DISCUSSION

Increased anterior corneal HOAs, posterior corneal HOAs, and ocular HOAs are optical sequelae of keratoconus and corneal ectasia that contribute to the diminished visual function in eyes with these corneal disease processes.<sup>2,3,19,20</sup> Collagen crosslinking, although developed primarily to mitigate progression of ectatic corneal processes, has also been found to

improve visual acuity and corneal topography characteristics in some patients with keratoconus and ectasia.<sup>9-13,18,21</sup> These effects are likely secondary to changes in the cornea's optical architecture, a result of the direct CXL effects and the consequent wound-healing processes.<sup>22</sup> For example, in our previous report of 1-year CXL outcomes,<sup>11</sup> patients had an improvement in CDVA (from 20/45 to 20/34) and in UDVA (from 20/137 to 20/117). Moreover, the topography-derived maximum K value flattened by 1.7 D. As further evidence of CXL-mediated corneal architectural changes, we found that several corneal topography quantitative indices also improved after treatment.<sup>18</sup> Because optical aberrations are the predominant cause of vision dysfunction in keratoconus and ectasia, this study was designed to further elucidate the optical changes that occur after CXL.

In this study, a detailed analysis of HOAs showed significant improvements in ocular HOAs and

**Table 4.** Visual acuity measurements stratified by HOA changes after CXL.

Parameter	Eyes (n)	Snellen UDVA		Snellen CDVA		Mean Change (logMAR) $\pm$ SD	
		Preop	1 Year Postop	Preop	1 Year Postop	UDVA	CDVA
Anterior corneal HOAs							
Decreased	72	20/134	20/110	20/45	20/34	$-0.09 \pm 0.26$	$-0.12 \pm 0.19$
Increased	25	20/113	20/91	20/37	20/32	$-0.10 \pm 0.22$	$-0.06 \pm 0.14$
Ocular HOAs							
Decreased	33	20/119	20/85	20/41	20/29	$-0.15 \pm 0.24$	$-0.14 \pm 0.21$
Increased	15	20/80	20/61	20/31	20/27	$-0.11 \pm 0.19$	$-0.07 \pm 0.12$

CDVA = corrected distance visual acuity; HOAs = higher-order aberrations; UDVA = uncorrected distance visual acuity

anterior corneal HOAs 1 year after CXL. These findings corroborate results in previous studies,<sup>9,13,23</sup> which found general improvements in HOAs after CXL. In particular, we found that total HOAs and coma significantly improved after CXL when derived from the cornea alone and when measured as total ocular aberrations. Total anterior corneal HOAs improved in 74% of eyes, and ocular HOAs improved in 69% of eyes. In no case did ocular HOAs worsen by more than 1.0  $\mu\text{m}$ , and anterior corneal HOAs worsened by greater than 1.0  $\mu\text{m}$  in only 1 ectasia patient. Despite the worsening of anterior corneal HOAs in this patient, the UDVA remained stable (20/400) and the CDVA improved from 20/50 to 20/40; the patient reported subjective improvement in night driving, glare, halos, and starburst symptoms.

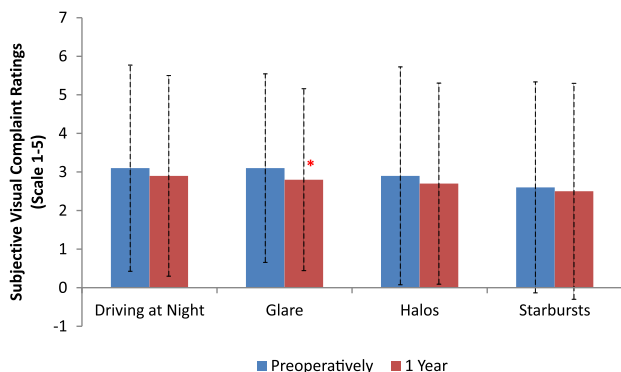
Although in general, visual acuity appears to improve after CXL, the mitigating factor of this improvement remains unclear. For instance, analyses of topography,<sup>18</sup> pachymetry,<sup>17</sup> corneal haze,<sup>22</sup> and corneal biomechanics<sup>24</sup> after CXL have failed to identify clinical characteristics that correlate with post-CXL visual acuity changes. As the proximate cause

of most visual impairment in keratoconus and ectasia, HOAs might be expected to predict improvement in vision after CXL. However, in this study, improvements in corneal aberrations and in total ocular aberrations after CXL did not appear to be associated with the improvements in UDVA or CDVA.

Aside from compromised visual acuity per se, increased HOAs also clinically manifest as subjective visual symptoms of glare, halos, and starbursts.<sup>25</sup> However, as with visual acuity outcomes, there did not appear to be any clinically relevant associations between the improvement in HOAs and the improvement in any of these visual symptoms after CXL, except an association of decreased total ocular HOAs with an improvement in reported starbursts. Additional study is required to further elucidate the effect of changing HOAs on visual function after CXL, perhaps also exploring possible associations with contrast sensitivity and low-contrast visual acuity.

To better ascertain differences in response to CXL, HOAs in a keratoconus subgroup and an ectasia subgroup were compared. In this analysis, there was no significant difference between the subgroups 1 year after CXL. Notwithstanding this finding, different trends observed in the 2 subgroups may be clinically enlightening. There was more improvement in anterior corneal HOAs and ocular HOAs in the keratoconus subgroup, a finding consistent with our previously reported CXL topography results.<sup>11,18</sup> It is unclear whether these findings suggest that ectatic corneas respond less to CXL than keratoconic corneas, whether differences in the preoperative topographic cone location in keratoconus corneas and ectatic corneas (unpublished data) contribute to this difference, or whether these findings are simply the statistical result of the smaller number of ectatic corneas in our study cohort. Further studies should be performed to elucidate differences in outcomes between eyes with keratoconus and eyes with ectasia after CXL.

Finally, the treatment group was compared with a fellow-eye control group. Ideally, the same number



**Figure 6.** Subjective questionnaire results for patients' visual symptoms preoperatively and at 1 year. Patients recorded symptoms on a scale from 1 to 5 (1 = none, 2 = mild, 3 = moderate, 4 = marked, 5 = severe). Error bars represent 2 standard deviations from the mean. Asterisks indicates a significant change compared with preoperative results ( $P < .05$ ).



**Table 5.** Correlation between HOAs and subjective visual symptoms ratings at 1 year.

	Pearson Correlation Coefficient						
	Total HOA	Spherical Aberrations	Total Coma*	Primary Coma	Vertical Coma	Horizontal Coma	Trefoil Coma
<b>Driving at night</b>							
Anterior corneal HOAs (n = 96)	-0.002	0.02	-0.02	-0.01	-0.03	0.06	0.04
Posterior corneal HOAs (n = 96)	0.01	-0.05	0.01	0.02	0.02	-0.1	0.1
Ocular HOAs (n = 48)	0.04	-0.09	0.06	0.2	0.08	0.1	0.03
<b>Glare</b>							
Anterior corneal HOAs (n = 96)	0.03	0.08	-0.001	-0.004	-0.02	0.07	-0.1
Posterior corneal HOAs (n = 96)	-0.01	0.03	-0.03	-0.05	-0.03	-0.1	-0.03
Ocular HOAs (n = 48)	0.04	-0.09	0.06	0.2	0.08	0.1	0.03
<b>Halos</b>							
Anterior corneal HOAs (n = 96)	0.04	0.05	0.02	0.02	-0.02	0.1	-0.05
Posterior corneal HOAs (n = 96)	0.1	0.1	0.1	0.1	0.1	-0.01	-0.06
Ocular HOAs (n = 48)	0.07	-0.08	0.1	0.1	0.1	0.2	-0.2
<b>Starbursts</b>							
Anterior corneal HOAs (n = 96)	0.2 <sup>†</sup>	0.2	0.2	0.2	0.2	0.1	-0.01
Posterior corneal HOAs (n = 96)	0.03	0.06	-0.01	-0.02	0.02	-0.01	-0.06
Ocular HOAs (n = 48)	0.5 <sup>†</sup>	0.4	0.5 <sup>†</sup>	0.5 <sup>†</sup>	0.5 <sup>†</sup>	0.1	0.2

CDVA = corrected distance visual acuity; HOAs = higher-order aberrations; UDVA = uncorrected distance visual acuity

\*Combined 3rd and 5th orders

<sup>†</sup>Statistically significant ( $P < .05$ )

of fellow eyes and treatment eyes would have been compared. However, the protocol for this trial allowed bilateral CXL treatment in patients who met the study criteria in both eyes. Thus, fellow eyes that had CXL before the 1-year examination were lost from the control group. Furthermore, because the fellow eye was not dilated at the 1-year follow-up examination, ocular HOA data in the control eyes were not available for comparison in this study. Notwithstanding this potential shortcoming, corneal HOAs generally worsened between baseline and 1 year in the control group. Moreover, the improvements in anterior corneal HOAs, total coma, 3rd-order coma, and vertical

coma in the CXL-treatment group were significantly different from the fellow-eye control group at 1 year.

In assessing the results in this study, it should be noted that the corneal aberration measurements were performed using Scheimpflug imagery of the Pentacam device. Topographic and pachymetric Pentacam measurements have been validated in other studies<sup>26-29</sup>; however, the accuracy and repeatability of Pentacam corneal wavefront measurements remain unclear. Muftuoglu et al.<sup>30</sup> report good repeatability of Pentacam Zernike coefficients in patients who had penetrating keratoplasty and Descemet-stripping automated endothelial keratoplasty; however,

**Table 6.** Anterior and posterior corneal HOAs in the control group.

Parameter	Mean ( $\mu\text{m}$ ) $\pm$ SD						
	Total HOAs	Total Coma*	3rd-Order Coma	Vertical Coma	Horizontal Coma	Trefoil	Spherical Aberrations
<b>Anterior corneal HOAs</b>							
Preop	1.80 $\pm$ 1.01	1.37 $\pm$ 1.12	1.34 $\pm$ 1.12	1.11 $\pm$ 1.00	0.55 $\pm$ 0.66	0.21 $\pm$ 0.20	1.00 $\pm$ 0.42
1 year postop	1.93 $\pm$ 1.10	1.50 $\pm$ 1.21	1.47 $\pm$ 1.20	1.25 $\pm$ 1.10	0.58 $\pm$ 0.66	0.19 $\pm$ 0.20	1.02 $\pm$ 0.45
<b>Posterior corneal HOAs</b>							
Preop	3.22 $\pm$ 2.15	2.46 $\pm$ 2.39	2.37 $\pm$ 2.37	1.85 $\pm$ 1.96	0.89 $\pm$ 1.58	0.52 $\pm$ 0.63	1.74 $\pm$ 0.49
1 year postop	3.48 $\pm$ 2.19 <sup>†</sup>	2.75 $\pm$ 2.40 <sup>†</sup>	2.67 $\pm$ 2.38 <sup>†</sup>	2.20 $\pm$ 2.05	0.92 $\pm$ 1.58	0.54 $\pm$ 0.45	1.81 $\pm$ 0.61

HOAs = higher-order aberrations

\*Combined 3rd and 5th orders

<sup>†</sup>Statistically significant change

Shankar et al.<sup>31</sup> found poor repeatability of calculated Zernike coefficients using data extrapolated from the Pentacam device. This limitation suggested an additional analysis of ocular HOAs using the Ladarwave aberrometer. The consistency of our anterior corneal and total ocular HOA findings suggests that the improvement in anterior corneal HOAs observed after CXL is generally correct.

A second limitation of this study was the incomplete ocular HOA data available for analysis. The Ladarwave aberrometer could not measure ocular HOAs in all patients. This is likely because of the extreme magnitude of HOAs in this patient population, which in some eyes exceeded the instrument's dynamic range. Unlike the Ladarwave aberrometer, the Pentacam device uses elevation data to extrapolate the Zernike coefficients; therefore, anterior corneal HOA and posterior corneal HOA data were available for all patients.

Finally, the protocol for this study required visual acuity to be measured with a modified Lighthouse ETDRS visual acuity test (2nd edition) with Sloan letters. Therefore, only high-contrast visual acuity data were available for analysis in this study. Previous studies<sup>32,33</sup> report that low-contrast visual acuity testing may be more sensitive when measuring the effect of HOAs on visual acuity. Further studies are required to determine the effect of HOAs on low-contrast visual acuity after CXL.

In conclusion, the clinical outcomes of CXL for the treatment of keratoconus and ectasia continue to be elucidated. In this study, we found that anterior corneal HOAs and ocular HOAs, in particular coma, improved after corneal CXL.


## REFERENCES

- Wollensak G, Spoerl E, Seiler T. Riboflavin/ultraviolet-A-induced collagen crosslinking for the treatment of keratoconus. *Am J Ophthalmol* 2003; 135:620–627
- Schlegel Z, Lteif Y, Bains HS, Gatinel D. Total, corneal, and internal ocular optical aberrations in patients with keratoconus. *J Refract Surg* 2009; 25:S951–S957
- Maeda N, Fujikado T, Kuroda T, Mihashi T, Hirohara Y, Nishida K, Watanabe H, Tano Y. Wavefront aberrations measured with Hartmann-Shack sensor in patients with keratoconus. *Ophthalmology* 2002; 109:1996–2003
- Jafri B, Li X, Yang H, Rabinowitz YS. Higher order wavefront aberrations and topography in early and suspected keratoconus. *J Refract Surg* 2007; 23:774–781
- Gobbe M, Guillon M. Corneal wavefront aberration measurements to detect keratoconus patients. *Cont Lens Anterior Eye* 2005; 28:57–66
- Alió JL, Shabayek MH. Corneal higher order aberrations: a method to grade keratoconus. *J Refract Surg* 2006; 22:539–545
- Vinciguerra P, Camesasca FI, Albè E, Trazza S. Corneal collagen cross-linking for ectasia after excimer laser refractive surgery: 1-year results. *J Refract Surg* 2010; 26:486–497
- Hafezi F, Kanellopoulos J, Wiltfang R, Seiler T. Corneal collagen crosslinking with riboflavin and ultraviolet A to treat induced keratectasia after laser in situ keratomileusis. *J Cataract Refract Surg* 2007; 33:2035–2040
- Vinciguerra P, Albè E, Trazza S, Rosetta P, Vinciguerra R, Seiler T, Epstein D. Refractive, topographic, tomographic, and aberrometric analysis of keratoconic eyes undergoing corneal cross-linking. *Ophthalmology* 2009; 116:369–378
- Raiskup-Wolf F, Hoyer A, Spoerl E, Pillunat LE. Collagen crosslinking with riboflavin and ultraviolet-A light in keratoconus: long-term results. *J Cataract Refract Surg* 2008; 34:796–801
- Hersh PS, Greenstein SA, Fry KL. Corneal collagen crosslinking for keratoconus and corneal ectasia: one year results. *J Cataract Refract Surg* 2011; 37:149–160
- Grewal DS, Brar GS, Jain R, Sood V, Singla M, Grewal SPS. Corneal collagen crosslinking using riboflavin and ultraviolet-A light for keratoconus; one-year analysis using Scheimpflug imaging. *J Cataract Refract Surg* 2009; 35:425–432
- Caporossi A, Mazzotta C, Baiocchi S, Caporossi T. Long-term results of riboflavin ultraviolet A corneal collagen cross-linking for keratoconus in Italy: The Siena Eye Cross Study. *Am J Ophthalmol* 2010; 149:585–593
- Caporossi A, Baiocchi S, Mazzotta C, Traversi C, Caporossi T. Parasurgical therapy for keratoconus by riboflavin-ultraviolet type A rays induced cross-linking of corneal collagen; preliminary refractive results in an Italian study. *J Cataract Refract Surg* 2006; 32:837–845
- Spoerl E, Mrochen M, Sliney D, Trokel S, Seiler T. Safety of UVA-riboflavin cross-linking of the cornea. *Cornea* 2007; 26:385–389
- Koller T, Mrochen M, Seiler T. Complication and failure rates after corneal crosslinking. *J Cataract Refract Surg* 2009; 35:1358–1362
- Greenstein SA, Shah VP, Fry KL, Hersh PS. Corneal thickness changes after corneal collagen crosslinking for keratoconus and corneal ectasia: one-year results. *J Cataract Refract Surg* 2011; 37:691–700
- Greenstein SA, Fry KL, Hersh PS. Corneal topography indices after corneal collagen crosslinking for keratoconus and corneal ectasia: one-year results. *J Cataract Refract Surg* 2011; 37:1282–1290
- Lim L, Wei RH, Chan WK, Tan DTH. Evaluation of higher order ocular aberrations in patients with keratoconus. *J Refract Surg* 2007; 23:825–828
- Nakagawa T, Maeda N, Kosaki R, Hori Y, Inoue T, Saika M, Mihashi T, Fujikado T, Tano Y. Higher-order aberrations due to the posterior corneal surface in patients with keratoconus. *Invest Ophthalmol Vis Sci* 2009; 50:2660–2665. Available at: <http://www.iovs.org/content/50/6/2660.full.pdf>. Accessed October 13, 2011
- Hafezi F, Mrochen M, Iseli HP, Seiler T. Collagen crosslinking with ultraviolet-A and hypoosmolar riboflavin solution in thin corneas. *J Cataract Refract Surg* 2009; 35:621–624
- Greenstein SA, Fry KL, Bhatt J, Hersh PS. Natural history of corneal haze after collagen crosslinking for keratoconus and corneal ectasia: Scheimpflug and biomicroscopic analysis. *J Cataract Refract Surg* 2010; 36:2105–2114
- Baumeister M, Klaproth OK, Gehmlich J, Bühren J, Kohnen T. Änderung des Wellenfrontfehlers der Hornhautvorderfläche nach Kollagenvernetzungsbehandlung (UV-Crosslinking) bei Keratokonus [Changes in corneal first-surface wavefront aberration after corneal collagen cross-linking in keratoconus]. *Klin Monatsbl Augenheilkd* 2009; 226:752–756
- Greenstein SA, Fry KL, Hersh PS. In vivo biomechanical changes after corneal collagen crosslinking for keratoconus

- and corneal ectasia: 1-year analysis of a randomized, controlled, clinical trial. In press, *Cornea* 2011
25. Seiler T, Kaemmerer M, Mierdel P, Krinke H-E. Ocular optical aberrations after photorefractive keratectomy for myopia and myopic astigmatism. *Arch Ophthalmol* 2000; 118:17–21. Available at: <http://archophth.ama-assn.org/cgi/reprint/118/1/17.pdf>. Accessed October 13, 2011
  26. Emre S, Doganay S, Yologlu S. Evaluation of anterior segment parameters in keratoconic eyes measured with the Pentacam system. *J Cataract Refract Surg* 2007; 33:1708–1712
  27. Bourges J-L, Alfonsi N, Laliberté J-F, Chagnon M, Renard G, Legeais J-M, Brunette I. Average 3-dimensional models for the comparison of Orbscan II and Pentacam pachymetry maps in normal corneas. *Ophthalmology* 2009; 116:2064–2071
  28. Miháltz K, Kovács I, Takács Á, Nagy ZZ. Evaluation of keratometric, pachymetric, and elevation parameters of keratoconic corneas with Pentacam. *Cornea* 2009; 28:976–980
  29. de Sanctis U, Missolungi A, Mutani B, Richiardi L, Grignolo FM. Reproducibility and repeatability of central corneal thickness measurement in keratoconus using the rotating Scheimpflug camera and ultrasound pachymetry. *Am J Ophthalmol* 2007; 144:712–718
  30. Muftuoglu O, Prasher P, Bowman RW, McCulley JP, Mootha VV. Corneal higher-order aberrations after Descemet's stripping automated endothelial keratoplasty. *Ophthalmology* 2010; 117:878–884.e6
  31. Shankar H, Taranath D, Santhirathelagan CT, Pesudovs K. Repeatability of corneal first-surface wavefront aberrations measured with Pentacam corneal topography. *J Cataract Refract Surg* 2008; 34:727–734
  32. Pepose JS, Applegate RA. Making sense out of wavefront sensing. *Am J Ophthalmol* 2005; 139:335–343
  33. Pesudovs K, Marsack JD, Donnelly WJ III, Thibos LN, Applegate RA. Measuring visual acuity—mesopic or photopic conditions, and high or low contrast letters? *J Refract Surg* 2004; 20:S508–S514

#### OTHER CITED MATERIAL

- A. Avedro, Inc. Corneal Collagen Cross-linking for Progressive Keratoconus (CXL). Identifier NCT00647699. Available at: <http://www.clinicaltrials.gov/ct2/show/record/NCT00647699?id=NCT00647699&rank=1>. Accessed October 13, 2011
- B. Avedro, Inc. Corneal Collagen Cross-Linking for Ectasia (CXL). Identifier NCT00674661. Available at: <http://www.clinicaltrials.gov/ct2/show/record/NCT00674661?id=NCT00674661&rank=1>. Accessed October 13, 2011



First author:

Steven A. Greenstein, MD

*Cornea and Laser Eye Institute—Hersh  
Vision Group, CLEI Center for  
Keratoconus, Teaneck,  
New Jersey, USA*