

Hippocampal capillaries in different age groups of chronically ethanol-intoxicated rats. Morphometrical studies

Michał Kraszpulski, Cecylia Tukaj, Teresa Wrzołkova

Laboratory of Electron Microscopy, Medical University of Gdańsk, Poland

[Received 28 February 2000; Revised 24 March 2000; Accepted 24 March 2000]

The influence of chronic ethanol intoxication on the terminal vascularization of particular hippocampal fields and layers was investigated in different age groups of rats. Thirty-six male Wistar rats aged 6 weeks were used in the study. For twelve months 24 of them drank only 25% ethanol — 12 starting at 6-week-age and 12 at 3-month-age. The control group of 12 rats drank only water. As an effect of long-term ethanol exposure on hippocampal capillaries we observed the increase in the terminal vessel diameter and the decrease in microvascular length, surface, and volume densities. These changes varied between different age groups and between particular hippocampal regions. The observed age and regional differentiation of ethanol-related microvascular changes did not correlate well with the damaging effects of alcohol on corresponding neuronal elements, which emphasizes the very complicated pathogenesis of ethanol-induced injuries.

key words: hippocampus, terminal vessels, chronic ethanol intoxication, morphometry

INTRODUCTION

Long-term ethanol consumption, among many other negative consequences, affects also the structure and function of the central nervous system. Many of these ethanol-related morphological injuries of the brain are reported in the hippocampus.

Hippocampus of mammals (including humans) is extremely vulnerable to the influence of alcohol and other toxic substances [23,26,31]. The generated changes are different in particular hippocampal regions [15,18,20,21,24] and the observed reactions can differentiate between various species [12,22], races [27,28], or sexes [10,30]. There are also many reports concerning the age-related differences in the hippocampal impairments induced by some pathological factors [4,7,25].

Chronic ethanol intoxication affects all the hippocampal components in various ways. The most often performed studies concern the impairments

of neurons, their processes and terminals; only a few refer to the ethanol-related changes in hippocampal terminal vessels [18,35]. Considering the general influence of alcohol on the vascular system of the brain and the blood-brain barrier permeability [9,16], it seems that much greater emphasis should be put on this problem.

The purpose of the presented study was to investigate, by means of morphometrical methods, the influence of chronic ethanol intoxication on the terminal vascularization of particular hippocampal fields and layers in different age groups of rats.

MATERIAL AND METHODS

Studies were performed on 36 male Wistar rats aged 6 weeks. For twelve months 24 of them drank only 25% ethanol — 12 starting at 6-week-age (young ethanol group — YEG) and 12 at 3-month-age (adult ethanol group — AEG). The control group of 12 rats

(CG) drank only water. All the animals were provided with free access to food — granulated chow Bacutil. At the end of the experiment Nembutal anesthesia was used and the tissues were fixed by transcardial perfusion with 4% paraformaldehyde and 1% glutaraldehyde with 0.3% CaCl₂ in 0.05M phosphate buffer, pH 7.4.

The paraformaldehyde-fixed brains were dissected into 1-mm-thick coronal slabs. The one taken at the optic chiasma level (Bregma 3.8 mm) was chosen, from which 6 specimens (3 from each hemisphere), representing all the studied hippocampal regions, were taken with the needle (Fig.1). These specimens were postfixed with buffered OsO₄ and, after dehydration, embedded in Epon 812.

To confirm that the specimens had been taken from the required area, brain slabs from which the needle specimens had been obtained were embedded in paraffin and sections cut from them were stained with hematoxylin and eosin. The visible holes in these sections enabled us to eliminate the incorrectly taken specimens.

The semiautomatic morphometrical analysis was carried out with the PICTOVAL projection microscope, IBM PC 386 computer, and WANG digitizer A1 by means of software designed in our Laboratory. The

analysis was performed at a final magnification of 900x (objective 20x, ocular 10x, plus projection post-magnification) on the semi-thin sections (1.5- μ m-thick), stained with toluidine blue.

As the first step of this analysis, the diameter of each vessel was calculated as the widest distance between the vessel walls perpendicular to the longest diameter of the vessel profile. Only the vessels <10 μ m in diameter were included in the study. Next the cross-sectional area of the parts of the hippocampal regions visible in the section, and the area and circumference of the 11,755 found terminal vessels' profiles were evaluated.

As a morphological manifestation of the blood supply we examined the surface density (S_V) of the terminal vessels — expressing the surface of the blood-brain exchange, and the volume density (V_V) — showing the capacity of the terminal vessels in the studied brain region. These parameters depend on the vessel size (represented here by their diameter) and length density (L_V) — representing the total length of the terminal vessels in the unit of tissue volume. The following formulas were used [34]:

$$L_V = 2 \frac{n}{A} \quad S_V = \frac{4}{\pi} x \frac{\sum_{i=1}^n b_i}{A}$$

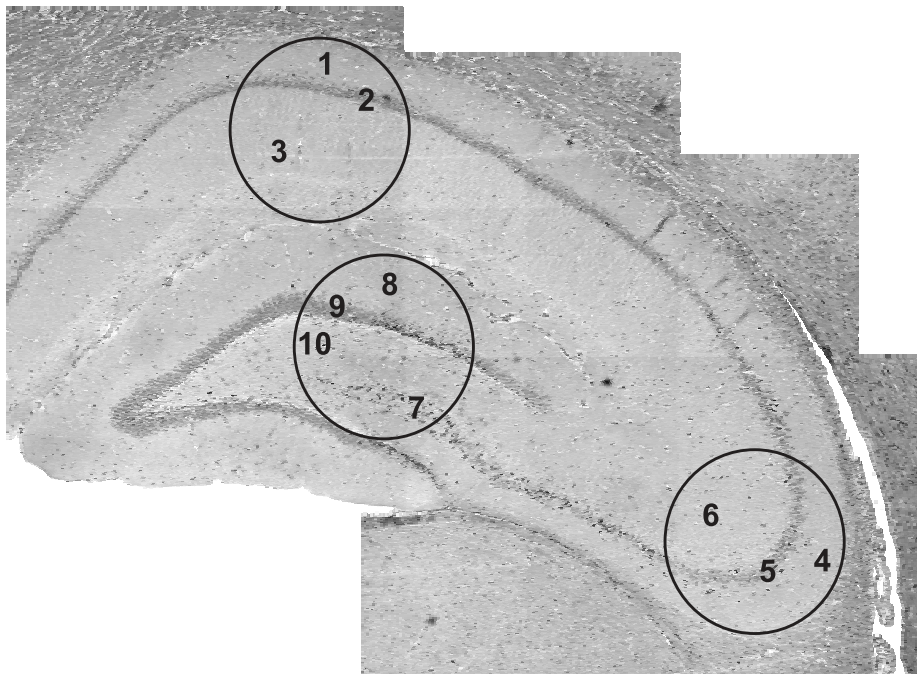


Figure 1. The analyzed hippocampal regions. Abbreviations: 1 — CA₁ sector, polymorphic layer; 2 — CA₁ sector, pyramidal layer; 3 — CA₁ sector, molecular layer; 4 — CA₃ sector, polymorphic layer; 5 — CA₃ sector, pyramidal layer; 6 — CA₃ sector, molecular layer; 7 — CA₄ sector, pyramidal layer; 8 — dentate gyrus, molecular layer; 9 — dentate gyrus, granular layer; 10 — dentate gyrus, polymorphic layer. Circles marked the places from which the needle specimens were taken.

where: n — number of the terminal vessels' profiles; A — area of the visible in the section part of the analyzed hippocampal region; i — consecutive number of analyzed profile; b_i — circumference of the profile i ; a_i — area of the profile i .

Statistical significance was verified by means of: t-test or modified t-test according to the F-test results of analysis of variance, Fisher-Pitman and Wilcoxon tests, Fisher randomization test for independent matched samples, and sign test. The accepted significance level $\alpha = 0.05$.

All numbers in the paper represent mean values \pm SD.

RESULTS

Statistical evaluation of the differences between individual rats as well as differences between the left and the right brain hemispheres showed that specimens within each of the studied groups of animals constituted a homogeneous population.

Sector CA₁

The terminal vessels in the pyramidal layer were significantly bigger in YEG in comparison to AEG and CG (Fig. 2A). The length density was statistically lower in both ethanol groups (Fig. 2B), but surface and volume densities only in AEG (Fig. 2C,D).

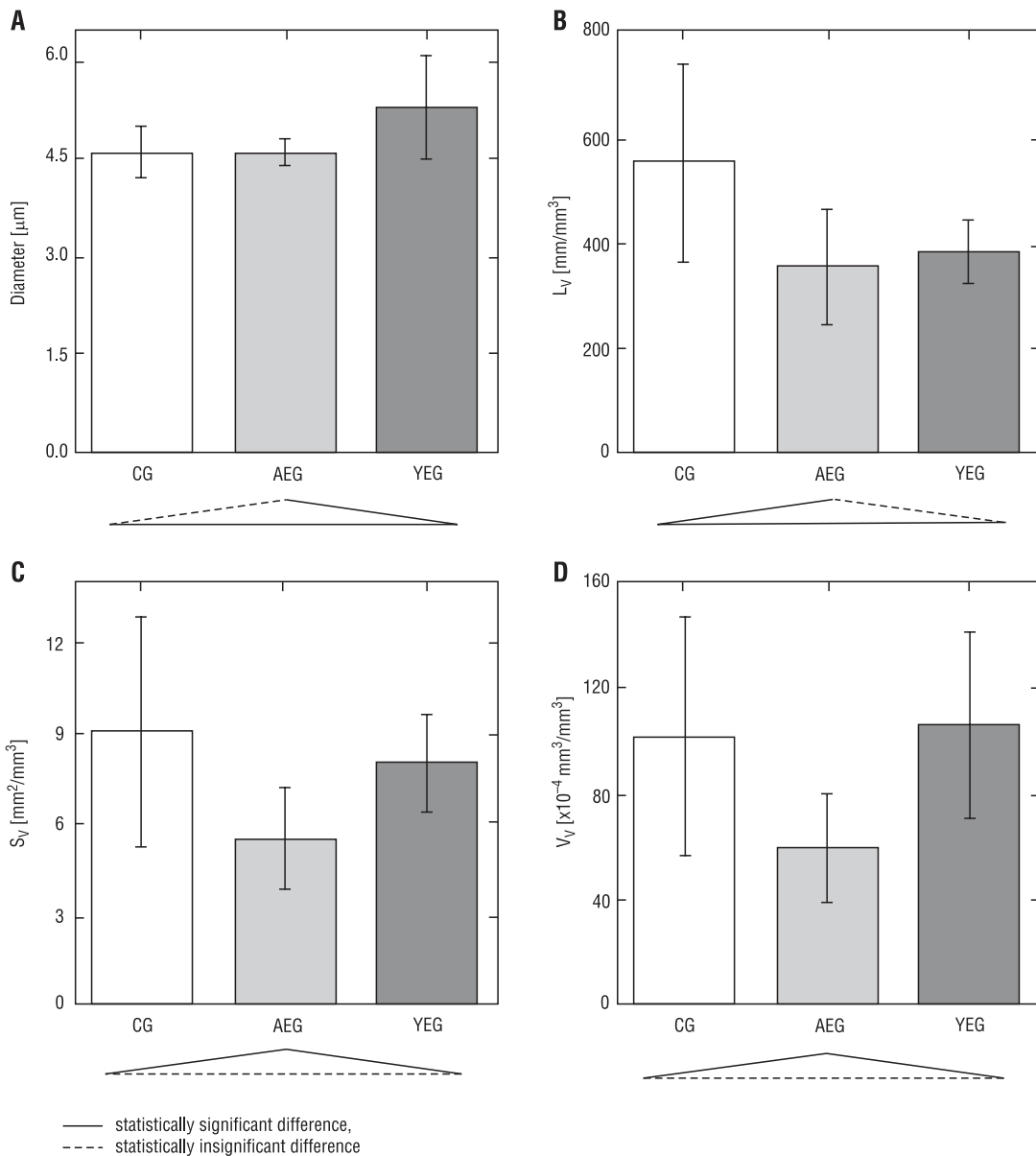


Figure 2. Parameters of the terminal vessels. CA₁ sector, pyramidal layer. A) terminal vessel diameter. B) length density. C) surface density. D) volume density.

The morphometrical parameters of the terminal vessels in the polymorphic and molecular layers were similar for all groups of rats, except the vessel diameter, which in the molecular layer was significantly bigger in YEG (Fig. 3).

Sector CA₃

The morphometrical parameters of the terminal vessels in the pyramidal and polymorphic layers were similar in all groups of rats.

In the molecular layer the terminal vessels were significantly bigger in both ethanol groups of animals in comparison to the control one (Fig. 4A). On the other hand the length density was statistically lower in these two groups (Fig. 4B), but the surface and the volume density only in AEG (Fig. 4C,D).

Sector CA₄

The morphometrical parameters of the terminal vessels in this sector did not statistically differentiate between particular groups of rats.

Dentate gyrus

The terminal vessels in the granular layer were significantly bigger in both ethanol groups of animals in comparison to the control one (Fig. 5A). On the other hand the length and the surface density were statistically lower in these groups (Fig. 5B,C), but the volume density only in AEG (Fig. 5D).

The morphometrical parameters of the terminal vessels in the polymorphic and molecular layers were not statistically different for the particular groups of rats. The one exception was the vessel diameter,

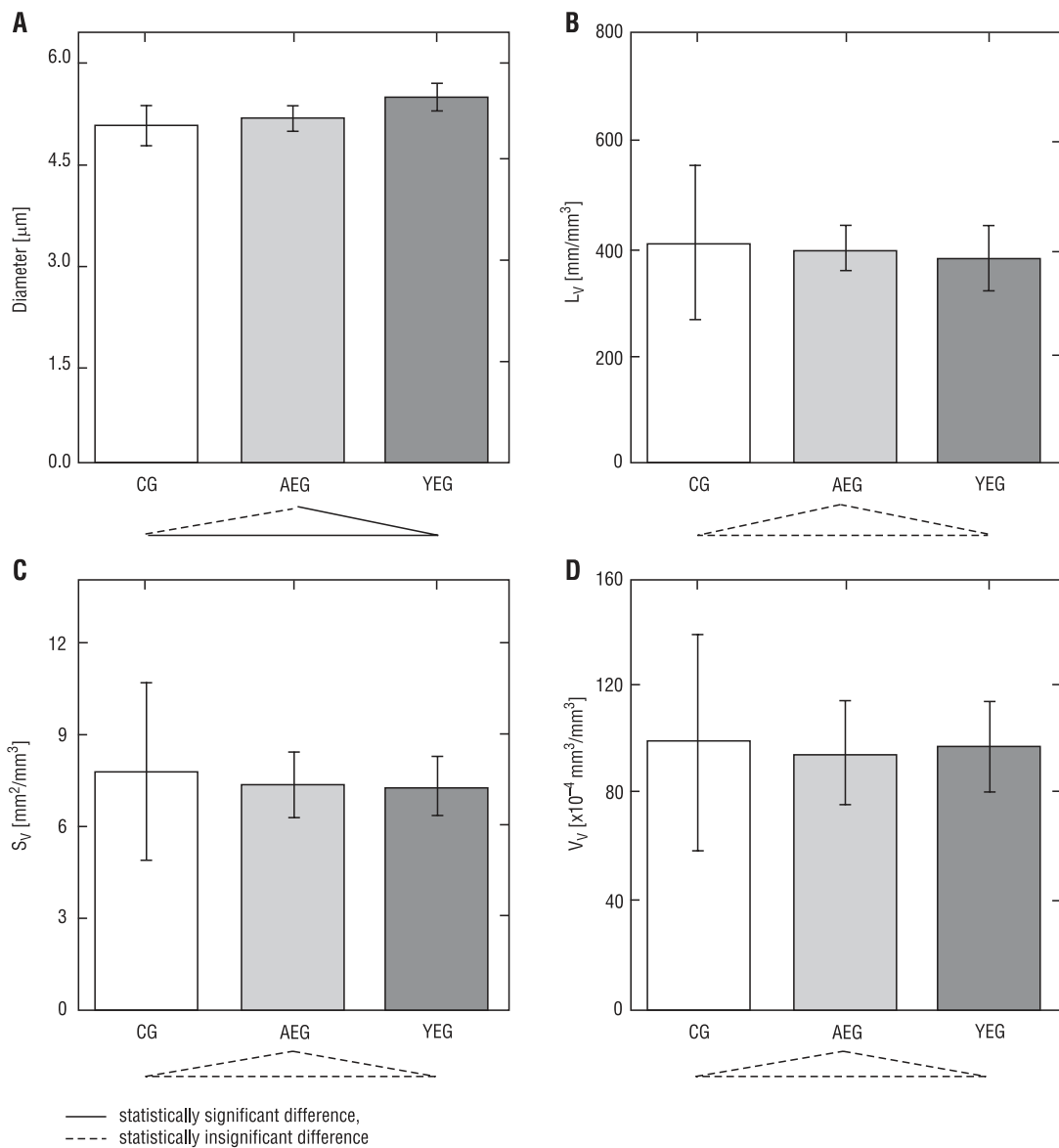


Figure 3. Parameters of the terminal vessels. CA₁ sector, molecular layer. A) terminal vessel diameter. B) length density. C) surface density. D) volume density.

which in the polymorphic layer was significantly bigger in YEG (Fig. 6).

DISCUSSION

The studies of the circulatory system and its reactivity have been usually performed in order to estimate the blood-tissue exchange. Investigators have been looking for changes in vessel structure or density. In rat hippocampus they have found among others age-related vascular impairments, with significant improvement after various pharmacological treatments [2,8,32,33]. Reduced density of terminal vascularization was observed in the hippocampus of people with Alzheimer's disease [11]. The different terminal vessel vulnerability for ischemia

or hypoxia was reported in particular hippocampal regions [6,14,29].

The presented results showed that also chronic ethanol intoxication had caused several changes in terminal vascularization of different layers of CA₁ and CA₃ hippocampal sectors and dentate gyrus. We observed a decrease in the microvascular length density and an increase in the vessel size. The interrelation between these two parameters was crucial for the level of the blood-brain exchange reduction, illustrated morphometrically by the decrease in the surface and volume densities of the terminal vascularization. Corresponding results were reported also in the other age group of rats — pups [18], showing the decrease in the density of the terminal vessels in

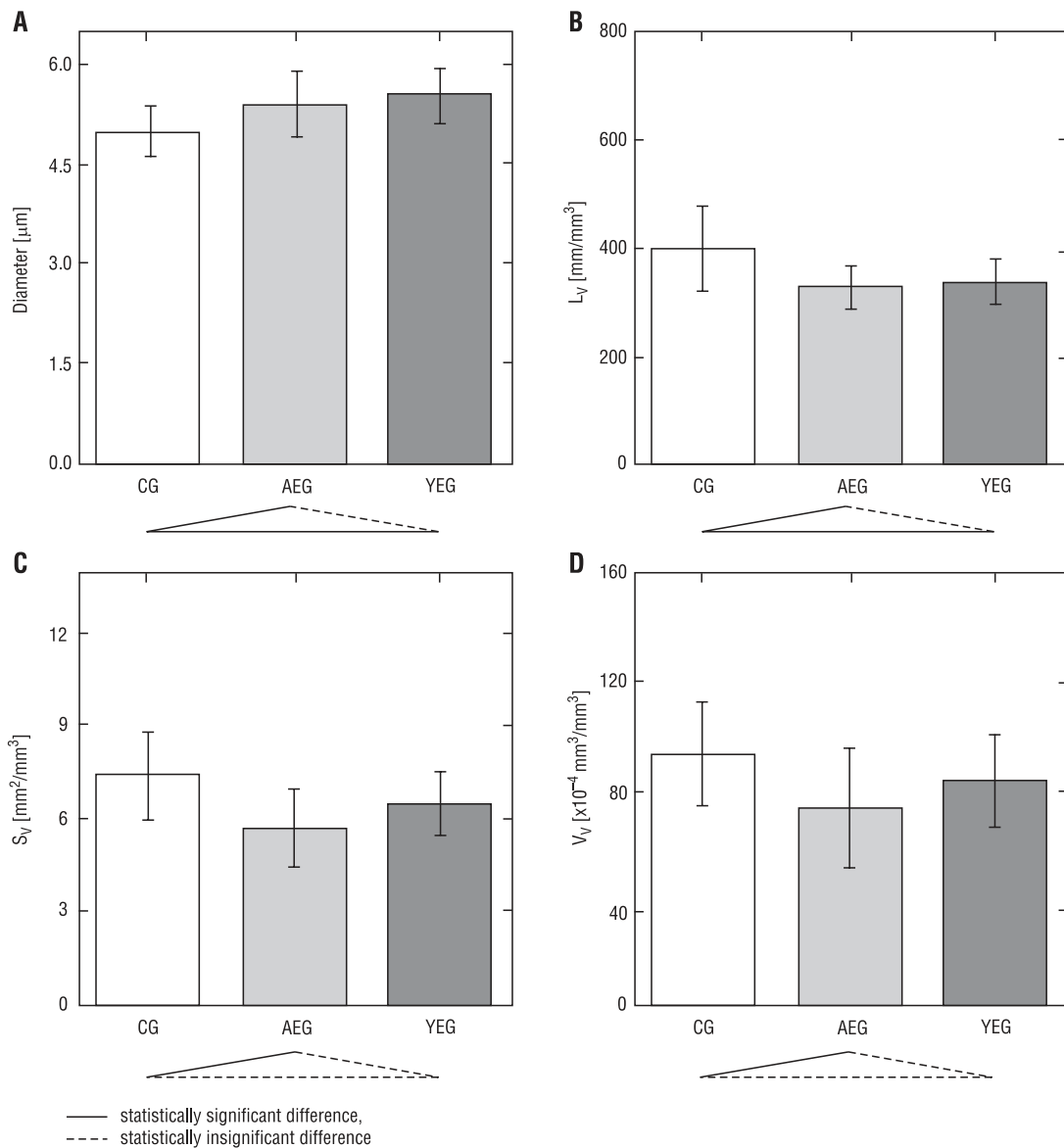


Figure 4. Parameters of the terminal vessels. CA₃ sector, molecular layer. A) terminal vessel diameter. B) length density. C) surface density. D) volume density.

dentate gyrus and their size increase in the hippocampus proper as an effect of ethanol intoxication.

The pathogenesis of the alcohol-related decrease in the terminal vessel length density could be explained by the direct influence of the ethanol on the terminal vessels. Considering however that natural capillary losses or increasing tissue demand are usually met by the development of new capillaries [3,19] an indirect effect seemed to be possible as well. The decrease in the terminal vascularization density would result in that case from the injury of angiogenesis mechanisms by chronic ethanol intoxication.

The increase demonstrated above in the terminal vessel size seemed to be the compensatory re-

sponse of the organism, neutralizing the losses of the capillaries in order to prevent the decrease in the blood-brain exchange. However the specificity of the blood-brain barrier limited the size of terminal vessels and 7–10 μm was usually admitted as the maximal diameter of brain capillaries [5,13]. Therefore such compensation for bigger vascular losses could be insufficient, resulting in the deficiency of blood-brain exchange.

The decrease in the morphometrical parameters illustrating the blood-brain exchange was significantly smaller in YEG than AEG, suggesting better plasticity of capillaries in younger animals. Our results suggested that between the sixth week and the third

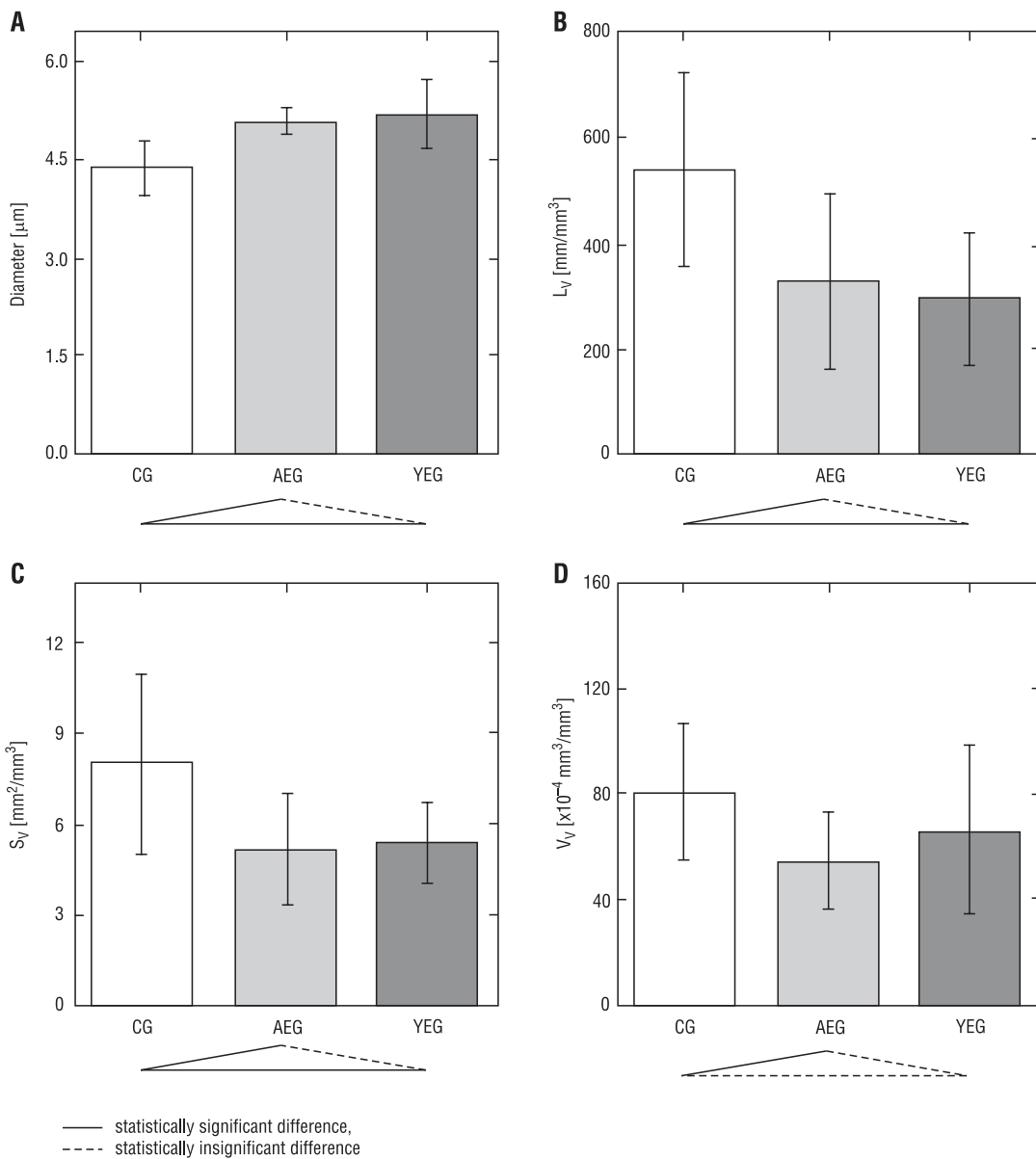


Figure 5. Parameters of the terminal vessels. Dentate gyrus, granular layer. A) terminal vessel diameter. B) length density. C) surface density. D) volume density.

month of life there was a modification of this plasticity, noticeable even after the one-year-period of ethanol intoxication.

The effect presented here of long-term ethanol exposure on brain capillaries varied between different age groups as well as between particular hippocampal regions. Moreover, this age and regional differentiation of observed changes did not correlate well with the damaging effects of alcohol on corresponding neuronal elements [4,20,27]. Therefore it would be rather difficult to assume direct connections between the terminal vascularization impairment and the neuronal death caused by chronic

ethanol intoxication. These discrepancies between the vascular and the cellular damage in the hippocampus bring into relief the very complicated pathogenesis of ethanol-induced injuries.

Our experimental model did not allow us to draw conclusions regarding the functional consequences of the long-term effects of alcohol on brain microvasculature. This question remains interesting — especially considering the existing relationship between alcohol consumption and stroke [1,16,17]. To solve such problems a great deal of fundamental data have to be accumulated using many various methods, among them also morphometry.

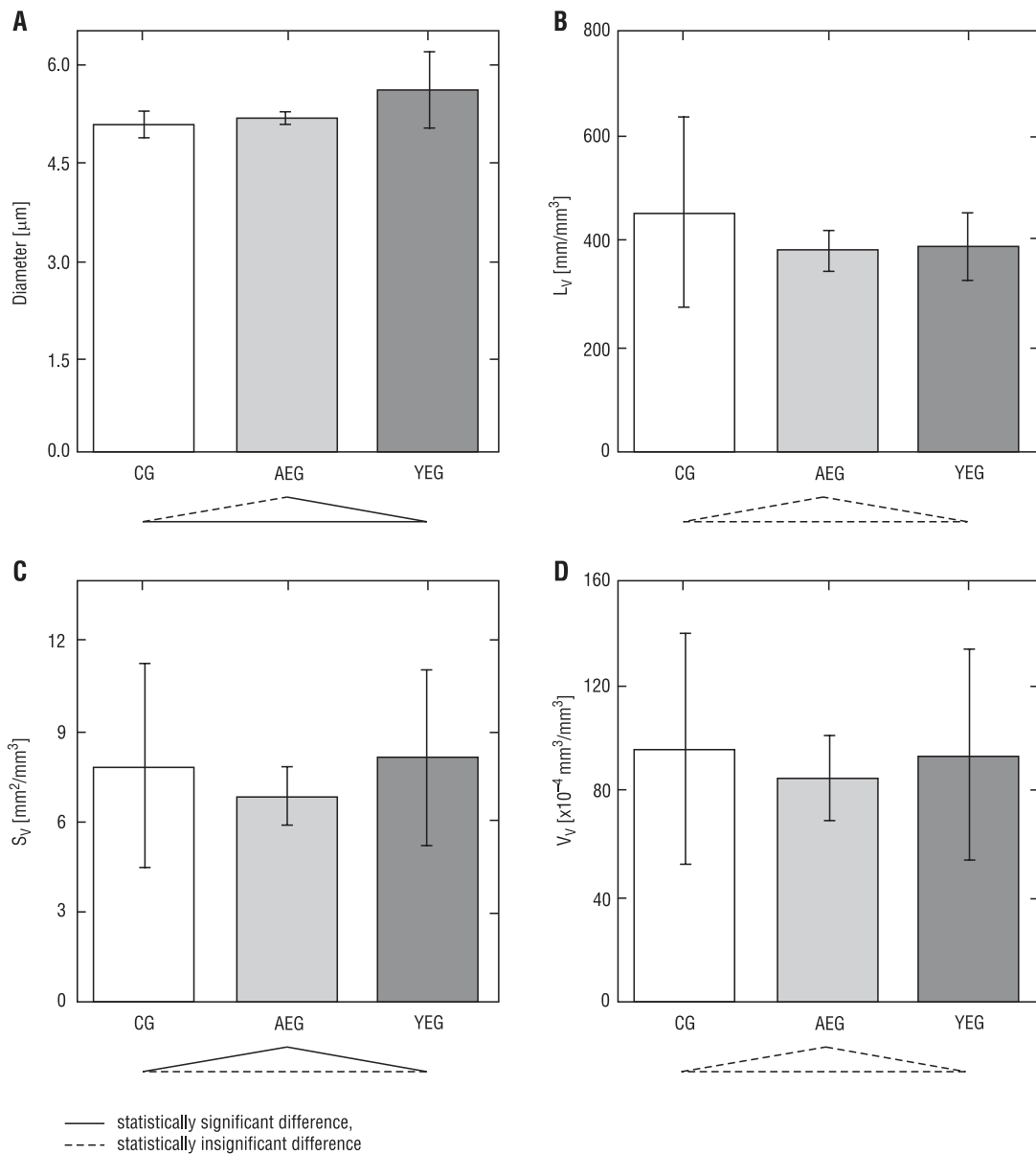


Figure 6. Parameters of the terminal vessels. Dentate gyrus, polymorphic layer. A) terminal vessel diameter. B) length density. C) surface density. D) volume density.

REFERENCES

1. Altura BM, Altura BT (1984) Alcohol, the cerebral circulation and strokes. *Alcohol*, 1: 325–331.
2. Amenta F, Cavallotti D, Del Valle M, Mancini M, Naves FJ, Vega JA, Zeng YC (1995) Age-related changes in brain microanatomy: sensitivity to treatment with the dihydropyridine calcium channel blocker darodipine (PY 108-068). *Brain Res Bull*, 36: 453–460.
3. Bär T (1983) Patterns of vascularization in the developing cerebral cortex. *Ciba Foundation Symposium*, 100: 20–36.
4. Bengoechea O, Gonzalo LM (1990) Effect of chronic alcoholism on the human hippocampus. *Histol Histochemol*, 5: 349–357.
5. Betz AL, Goldstein GW (1984) Brain capillaries. Structure and function. *Handbook of Neurochemistry*, 7: 465–483.
6. Boero JA, Ascher J, Arregui A, Rovainen C, Woolsey TA (1999) Increased brain capillaries in chronic hypoxia. *J Appl Physiol*, 86: 1211–1219.
7. Cristofol RM, Rodriguez-Farre E, Sanfeliu C (1993) Effects of γ and δ hexachlorocyclohexane isomers on inositol phosphate formation in cerebral cortex and hippocampus slices from developing and adult rat. *Neurotoxicology*, 14: 451–458.
8. de Jong GI, de Weerd H, Schuurman T, Traber J, Luiten PGM (1990) Microvascular changes in aged rat forebrain. Effects of chronic nimodipine treatment. *Neurobiol Aging*, 11: 381–389.
9. De Witte P, Gewiss M, Heidbreder C (1989) Cortical microvascular changes in chronological aging, cortical insults and chronic alcohol intoxication in rats. Effects of antihypoxic drug on this phenomenon. *Alcohol*, 6: 423–430.
10. Devaud LL, Morrow AL (1999) Gender-selective effects of ethanol dependence on NMDA receptor subunit expression in cerebral cortex, hippocampus and hypothalamus. *Eur J Pharmacol*, 369: 331–334.
11. Fischer VW, Siddiqi A, Yusufaly YTI (1990) Altered angioarchitecture in selected areas of brains with Alzheimer's disease. *Acta Neuropathol*, 79: 672–679.
12. Frotscher M, Soriano E, Leranth C (1992) Cholinergic and GABAergic neurotransmission in the fascia dentata: electron microscopic immunocytochemical studies in rodents and primates. In: Ribak CE, Gall CM, Mody I (eds.). *The dentate gyrus and its role in seizures*. Elsevier, Amsterdam, New York, Oxford, pp. 65–78.
13. Fung YC (1980) Structural mechanics of microvasculature. In: Gross JF, Popel A (eds.). *Mathematics of microcirculation phenomena*. Raven Press, New York, pp. 1–16.
14. Gadamski R, Mossakowski MJ (1992) Asymmetric damage of the CA1 sector of Ammon's horn after short-term forebrain ischemia in mongolian gerbils. *Neuropat Pol*, 30: 209–219.
15. Goodman JH, Sloviter RS (1993) Cocaine neurotoxicity and altered neuropeptide Y immunoreactivity in the rat hippocampus; a silver degeneration and immunocytochemical study. *Brain Res*, 616: 263–272.
16. Hillbom M (1999) Oxidants, antioxidants, alcohol and stroke. *Front Biosci*, 4: e67–e71.
17. Hillbom M, Juvela S, Karttunen V (1998) Mechanisms of alcohol-related strokes. *Novartis Found Symp*, 216: 193–204.
18. Kelly SJ, Mahoney JC, West JR (1990) Changes in brain microvasculature resulting from early postnatal alcohol exposure. *Alcohol*, 7: 43–47.
19. Kuschinsky W, Paulson OB (1992) Capillary circulation in the brain. *Cerebrovasc Brain Metab Rev*, 4: 261–286.
20. Lukoyanov NV, Madeira MD, Paula-Barbosa MM (1999) Behavioral and neuroanatomical consequences of chronic ethanol intake and withdrawal. *Physiol Behav*, 66: 337–346.
21. Manji HK, Etcheberrigaray R, Chen G, Olds JL (1993) Lithium decreases membrane-associated protein kinase C in hippocampus: selectivity for the α isozyme. *J Neurochem*, 61: 2303–2310.
22. Nitsch R, Leranth C (1993) Calretinin immunoreactivity in the monkey hippocampal formation - II. Intrinsic GABAergic and hypothalamic non-GABAergic systems: an experimental tracing and co-existence study. *Neuroscience*, 55: 797–812.
23. Oderfeld-Nowak B (1983) Badania procesów reinercji po uszkodzeniu mózgu - hipokamp jako struktura modelowa. In: *Nowe metody w badaniach mózgu*. Ossolineum, Wrocław, Warszawa, Kraków, Gdańsk, Łódź, pp. 297–318.
24. Okada M, Sakaguchi T, Kawasaki K (1995) Correlation between anti-ubiquitin immunoreactivity and region-specific neuronal death in N-methyl-D-aspartate-treated rat hippocampal organotypic cultures. *Neurosci Res*, 22: 359–366.
25. Pyapali GK, Turner DA, Wilson WA, Swartzwelder HS (1999) Age and dose-dependent effects of ethanol on the induction of hippocampal long-term potentiation. *Alcohol*, 19: 107–111.
26. Ryabinin AE (1998) Role of hippocampus in alcohol-induced memory impairment: implications from behavioral and immediate early gene studies. *Psychopharmacology*, 139: 34–43.
27. Scheetz AJ, Markham JA, Fifkova E (1988) Astrocyte proliferation precedes a decrease in basket cells in the dentate fascia following chronic ethanol treatment in mice. *Brain Res*, 460: 246–252.
28. Schuerger RJ, Balaban CD (1995) N-(2-chloroethyl)-N-ethyl-2-bromobenzylamine (DSP-4) has differential efficacy for causing central noradrenergic lesions in two different rat strains: comparison between Long-Evans and Sprague-Dawley rats. *J Neurosci Methods*, 58: 95–111.
29. Shinnou M, Ueno M, Sakamoto H, Ide M (1998) Blood-brain barrier damage in reperfusion following ischemia in the hippocampus of the Mongolian gerbil brain. *Acta Neurol Scand*, 98: 406–411.
30. Standley CA, Mason BA, Cotton DB (1995) Differential regulation of seizure activity in the hippocampus of male and female rats. *Am J Obstet Gynecol*, 173: 1160–1165.
31. Tanaka H (1998) Fetal alcohol syndrome: a Japanese perspective. *Ann Med*, 30: 21–26.

32. Topple A, Fikova E, Baumgardner D, Cullen-Dockstader KTI (1991) Effect of age on blood vessels and neurovascular appositions in the CA1 region of the rat hippocampus. *Neurobiol Aging*, 12: 211–217.
33. Topple A, Fikova E, Cullen-Dockstader K (1990) Effect of age on blood vessels and neurovascular appositions in the rat dentate fascia. *Neurobiol Aging*, 11: 371–380.
34. Weibel ER (1979) *Stereological Methods. Practical Methods for Biological Morphometry*. Academic Press, New York.
35. Wrzołkowa T, Łukaszyk I, Rudzińska-Kisiel T, Kraszpulski M (1992) Terminal Vessels of Dentate Gyrus in Chronically Alcohol-Intoxicated Rats. *Alcohol*, 9: 271–274.