

Histological and biological evolution of human premalignant breast disease

D C Allred^{1,2}, S K Mohsin^{1,2} and S A W Fuqua^{1,3}

¹The Breast Center, Baylor College of Medicine, Houston, Texas 77030, USA

²Department of Pathology, Baylor College of Medicine, Houston, Texas 77030, USA

³Department of Molecular and Cellular Biology, Baylor College of Medicine, Houston, Texas 77030, USA

(Requests for offprints should be addressed to D C Allred, Breast Center, Baylor College of Medicine, One Baylor Plaza, MS600, Houston, Texas 77030, USA; Email: dcallred@breastcenter.tmc.edu)

Abstract

Most human invasive breast cancers (IBCs) appear to develop over long periods of time from certain pre-existing benign lesions. Of the many types of benign lesions in the human breast, only a few appear to have significant premalignant potential. The best characterized of these include atypical hyperplasias and *in situ* carcinomas and both categories are probably well on along the evolutionary pathway to IBC. Very little is known about earlier premalignant alterations. All types of premalignant breast lesions are relatively common but only a small proportion appear to progress to IBC. They are currently defined by their histological features and their prognosis is imprecisely estimated from indirect epidemiological evidence. Although lesions within specific categories look alike, they must possess underlying biological differences causing some to remain stable and others to progress. Recent studies suggest that they evolve by highly diverse genetic mechanisms and research into these altered pathways may identify specific early defects that can be targeted to prevent premalignant lesions from developing or becoming cancerous. It is far more rational to think that breast cancer can be prevented than cured once it has developed fully. This review discusses histological models of human premalignant breast disease that provide the framework for scientific investigations into the biological alterations behind them and examples of specific biological alterations that appear to be particularly important.

Endocrine-Related Cancer (2001) 8 47–61

Introduction

Invasive breast cancer (IBC) is one of the most common and lethal malignant neoplasms affecting women in Western cultures. The majority of IBCs are thought to develop over long periods of time from certain pre-existing benign lesions. There are many types of benign lesions in the human breast and only a few appear to have significant premalignant potential. The best characterized premalignant lesions recognized today are referred to as atypical ductal hyperplasia (ADH), atypical lobular hyperplasia (ALH), ductal carcinoma *in situ* (DCIS), and lobular carcinoma *in situ* (LCIS). All these lesions possess some malignant properties such as a relative loss of growth control, but they lack the ability to invade and metastasize and, in this sense, are premalignant.

Several types of evidence point to this handful of lesions as being important precursors of human IBC (Table 1). For example, pathologists recognized many years ago that they were on a histological continuum between normal epithelium in terminal duct lobular units (TDLUs) and IBC (Foote &

Stewart 1945, Wellings & Jensen 1973, Wellings *et al.* 1975) and that they were much less common in non-cancerous breasts than in breasts with synchronous IBC (Foote & Stewart 1945, Wellings & Jensen 1973, Wellings *et al.* 1975, Alpers & Wellings 1985). Other studies showed that women with a history of atypical hyperplasias and *in situ* carcinomas had approximately 5- and 10-fold increased relative risks, respectively, of eventually developing IBC (Page *et al.* 1982, 1985, Dupont & Page 1985, Palli *et al.* 1991, London *et al.* 1992, Dupont *et al.* 1993). The elevated risks associated with ADH, ALH, and LCIS are bilateral, suggesting that they may only be markers rather than precursors of IBC (Page & Dupont 1993). However, these lesions are frequently multifocal and bilateral (Foote & Stewart 1945, Wellings & Jensen 1973, Wellings *et al.* 1975) which, in light of their histological continuity with IBC and increased incidence in cancerous breasts, suggests that they may be both risk factors as well as precursors. DCIS is usually a unifocal disease and the associated risk for developing IBC is primarily ipsilateral, consistent with the notion that DCIS is a relatively advanced and committed precursor. The most compelling evidence that

Table 1 General types of evidence supporting the idea that invasive breast cancers arise from certain pre-existing benign lesions over long periods of time

Evidence	ADH	ALH	DCIS	LCIS
On a histological continuum between TDLUs and IBC	Yes	Yes	Yes	Yes
Less common in non-cancerous breasts than in breasts with synchronous IBC	Yes (5% vs <50%)	Yes	Yes	Yes
Risk factors for developing IBC	Yes (5-fold)	Yes (5-fold)	Yes (10-fold)	Yes (10-fold)
Shared genetic alterations with synchronous IBC	Yes	Yes	Yes	Yes

all these lesions may be precursors comes from recent studies showing that they share identical genetic abnormalities with synchronous ipsilateral IBC (O'Connell *et al.* 1998). Over the past twenty years or so, all of this evidence has culminated in a histological model of human breast cancer evolution which proposes that stem cells in normal TDLUs give rise to atypical hyperplasias (ADH and ALH), which progress to *in situ* carcinomas (DCIS and LCIS), which eventually develop into invasive and metastatic disease (Fig. 1).

There are many morphological differences between TDLUs and atypical hyperplasias and there are no unequivocal intermediate lesions between them. In the early 1970s, Wellings and co-workers proposed that a common alteration of TDLUs which they called 'atypical lobules type A' (ALA) may be involved in the transition from TDLUs to ADH and beyond (Wellings *et al.* 1975). ALAs, which are referred to as unfolded lobules (ULs), among other names, in today's terminology, resemble TDLUs in overall architecture but are much larger due to the proliferation and accumulation (i.e. hyperplasia) of the epithelial cells lining their acini. The structure of normal TDLUs themselves varies considerably as a function of hormonal status (e.g. menstruation, pregnancy, etc.) and they are grouped into four histological categories (types I through IV) on a continuum of differentiation towards lactation (Russo *et al.* 1987, 1992). Type I TDLUs, the least differentiated, have relatively high proliferation rates and are somewhat more common in cancerous breasts, suggesting that they may preferentially give rise to early growth alterations with premalignant potential such as ULs (Dickson & Russo 2000). Once developed, ULs have the potential to evolve along several diverse pathways including to microcystic disease, to a common type of hyperplastic lesion referred to as usual ductal hyperplasia (UDH), as well as to ADH. Furthermore, these pathways appear to be relatively mutually exclusive. Although UDH has been shown to be a weak risk factor for developing IBC (approximately twofold) (Page & Dupont 1993), it does not fit well on the histological continuum to IBC and thus may be a side branch on the evolutionary tree through shared ancestry with ULs rather than an important precursor of IBC.

In contrast to ADH, which seems to develop from ULs,

ALH appears to arise directly within normal appearing TDLUs as small mildly atypical epithelial cells which begin to fill and partially distend the ducts and acini, and there is some speculation that this may occur preferentially in relatively well differentiated type II TDLUs (Russo & Russo 1997). If the cells accumulate until the spaces are distended to a large extent, the lesions are referred to as LCIS. Thus, the evolutionary pathways of lobular lesions (i.e. ALH and LCIS) seem to be different from those of ductal lesions (i.e. ADH and DCIS) and lobular lesions are less common. In a sense, the terms 'ductal' and 'lobular' are misleading because they imply an origin and localization to either ducts or lobules when, in fact, all types of premalignant breast lesions can occupy both locations and ultimately appear to arise from stem cells in TDLUs (Rudland 1993) or in ULs which themselves arise from TDLUs. Wellings and colleagues also appreciated the distinct histological evolution of lobular lesions which they referred to as 'atypical lobules type B' (ALB) (Wellings & Jensen 1973, Wellings *et al.* 1975). ALH and LCIS are bilateral risk factors for developing IBC and the IBCs that eventually develop are as likely to be infiltrating lobular carcinomas (ILCs) as non-lobular subtypes (Page *et al.* 1986). However, when they are found in a breast with synchronous IBC, the latter is usually an ILC or an invasive lesion with prominent lobular features. Taken together, ALH and LCIS appear to be markers of widespread genetic damage to breast epithelium (i.e. risk factors) as well as precursor lesions.

This linear histological model of breast cancer evolution undoubtedly oversimplifies a very complex process. For example, it is quite possible that some IBCs arise directly from morphologically normal appearing cells. In addition, many premalignant lesions do not progress to IBC during the average lifespan of a woman, so progression is non-obligatory. Some lesions may even revert to less advanced phenotypes. The histological appearances of premalignant lesions within specific categories are very similar (by definition), so there must be underlying biological abnormalities causing some to remain stable and others to progress. Despite its shortcomings, however, this model has been very useful as a framework for scientific studies into the biological causes of tumor progression, which may eventually lead to strategies for breast cancer prevention. There have been hundreds of studies during the past decade

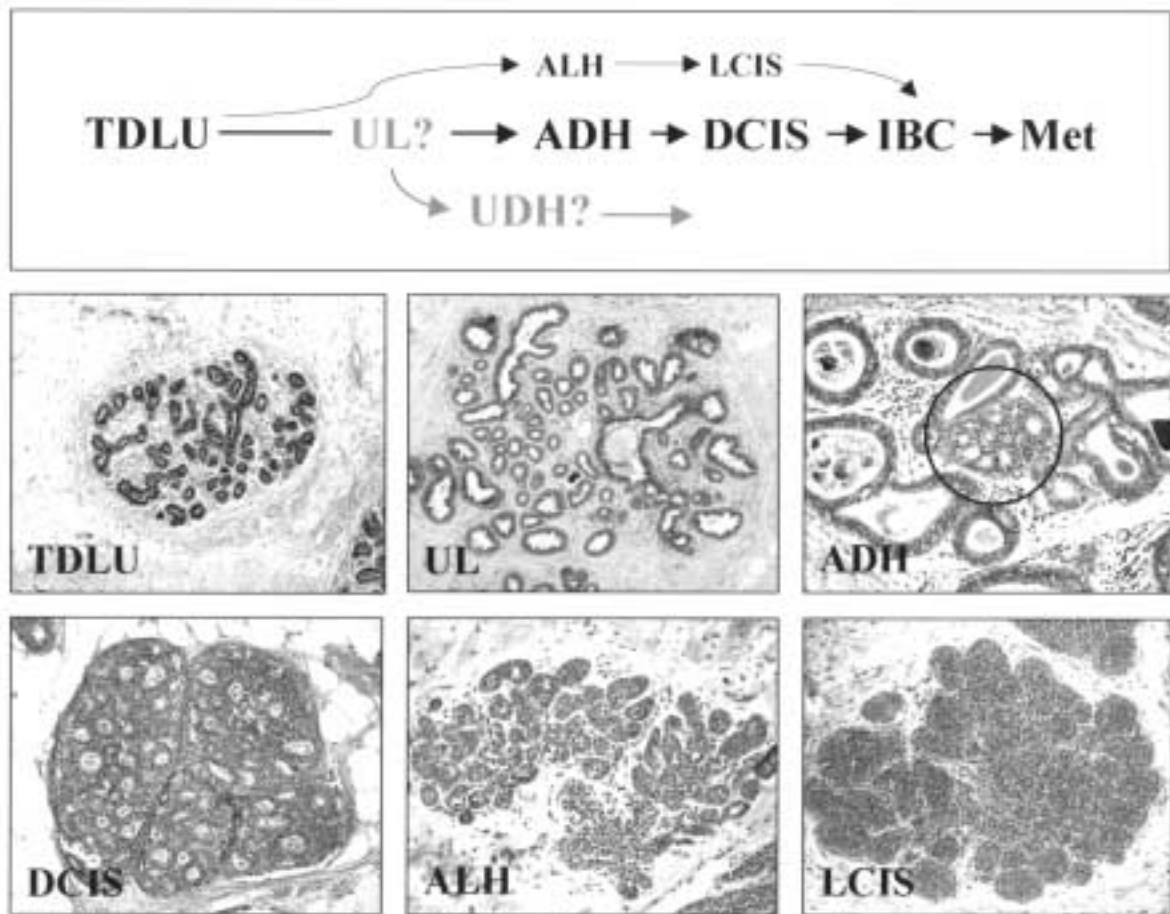


Figure 1 Histological model of breast cancer evolution and representative photomicrographs of important premalignant lesions. Terminal duct lobular units (TDLUs) are thought to be the major stem cell compartment giving rise to all types of premalignant breast lesions. Unfolded lobules (ULs) are TDLUs that are greatly expanded due to hyperplasia of their lining epithelium and may represent the earliest morphologically recognizable premalignant change. Atypical ductal hyperplasias (ADHs) are small clonal outgrowths of low-grade epithelium (circle) that often arise in ULs. Ductal carcinoma *in situ* (DCIS) are large outgrowths of epithelium that greatly distend ductal and lobular spaces and vary on a histological continuum from low to high grade lesions. Atypical lobular hyperplasias (ALHs) represent relatively normal sized TDLUs that are partially filled by low grade neoplastic epithelium. Lobular carcinoma *in situ* (LCIS) represent TDLUs that are greatly distended by cells that are cytologically identical to those of ALH. ALH and LCIS are essentially the same disease on a quantitative continuum.

evaluating dozens of biological pathways in premalignant breast disease. This review discusses a few that appear to be particularly important and that have been studied in a relatively comprehensive manner.

Growth characteristics of premalignant breast disease

Even though microscopic in size, all types of premalignant breast lesions are ‘tumors’ which expand TDLUs and proximal ducts to many times their normal size (Fig. 2). Many studies, using a variety of techniques, have measured the magnitude of proliferation in TDLUs and premalignant

lesions (Table 2). Proliferation in TDLUs averages only about 2% overall (Meyer 1977, Ferguson & Anderson 1981, Joshi *et al.* 1986, Longacre & Bartow 1986, Russo *et al.* 1987, Going *et al.* 1988, Potten *et al.* 1988, Kamel *et al.* 1989, Schmitt 1995, Visscher *et al.* 1996, Mohsin *et al.* 2000a). In premenopausal women, the rate fluctuates with the menstrual cycle and is twofold higher in the luteal than in the follicular phase (Potten *et al.* 1988). The association between hormonal status and proliferation emphasizes the importance of estrogen and progesterone as mitogens for normal breast epithelium (Pike *et al.* 1993). Proliferation has not been evaluated in ULs with the exception of one preliminary study reporting an average rate

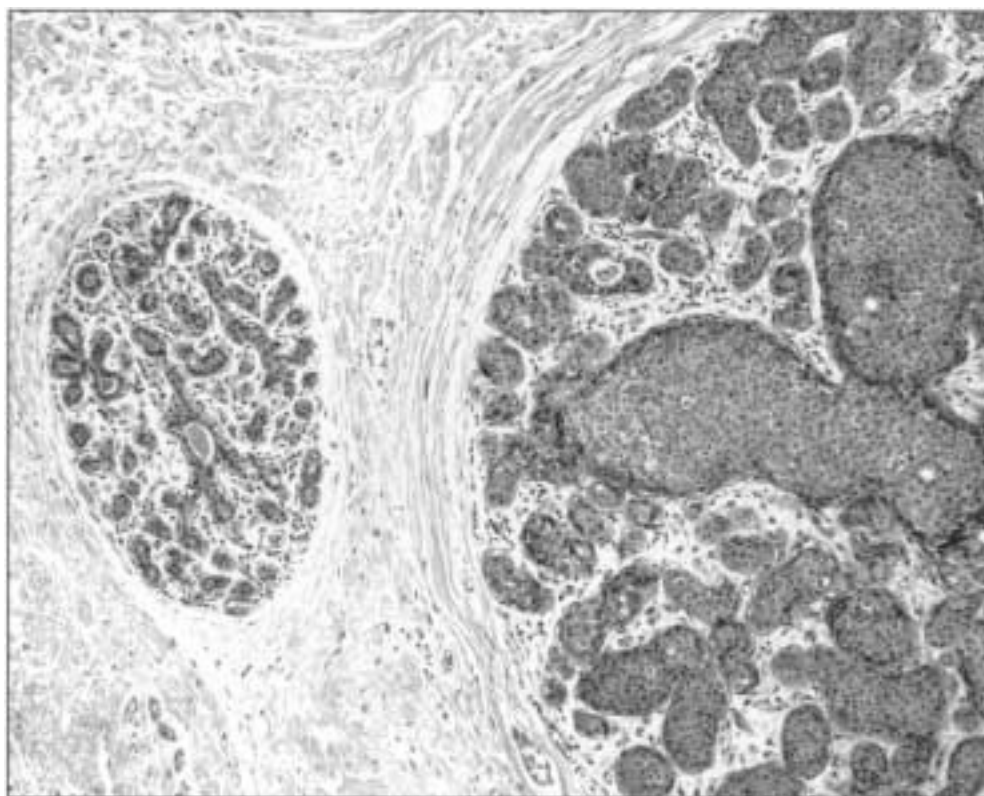


Figure 2 All types of premalignant breast lesions are ‘tumors’ which expand terminal duct lobular units (TDLUs) and proximal ducts to many times their normal size. This example shows a normal TDLU on the left compared with one being distended by ductal carcinoma *in situ* (DCIS) on the right.

Table 2 Growth (proliferation and apoptosis) in premalignant breast lesions

	TDLU	UL	ADH	DCIS	ALH	LCIS
Average % proliferation	2%	5%	5%	15%	low	2%
Average % apoptosis	0.6%	low	0.3%	5%	low	low

of about 5%, which is still two- to threefold higher than in normal TDLUs (Mohsin *et al.* 2000a). Studies of ADH also observed rates averaging about 5% (De Potter *et al.* 1987, Hoshi *et al.* 1995, Mohsin *et al.* 2000a). Proliferation has been studied more extensively in DCIS than in any other type of premalignant breast lesion (Meyer 1986, Locker *et al.* 1990, Bobrow *et al.* 1994, Poller *et al.* 1994, Zafrani *et al.* 1994, Albonico *et al.* 1996, Berardo *et al.* 1996a, Mohsin *et al.* 2000a). Rates average about 5% in histologically low-grade ‘non-comedo’ DCIS compared with 20% in high-grade ‘comedo’ lesions. The widespread practice of dichotomizing DCIS into non-comedo and comedo subtypes is misleading in the sense that, similar to IBC, DCIS shows tremendous histological diversity along a continuum ranging from very well to very poorly differentiated, and grading systems have been developed which more accurately convey

this diversity (Berardo *et al.* 1996a). Proliferation is proportional to differentiation along this histological continuum with rates averaging as low as 1% in the lowest grade to more than 70% in the highest grade lesions (Bobrow *et al.* 1994, Berardo *et al.* 1996a). Proliferation has not been formally studied in ALH but is probably similar to LCIS where the reported average is about 2% (Fisher *et al.* 1996, Rudas *et al.* 1997, Libby *et al.* 1998, Querzoli *et al.* 1998).

The overall growth of premalignant breast lesions can be viewed simplistically as a balance between cell proliferation and cell death. On average, the cells in all types of premalignant lesions proliferate faster than normal cells in TDLUs (Fig. 3), contributing to their positive growth imbalance. Much less is known about cell death in this setting (Table 2). One preliminary study reported significantly lower rates of apoptosis in ADH compared with TDLUs in the same breasts (0.3% vs 0.6% respectively), suggesting that the growth of ADH may be the result of both increased proliferation and decreased cell death compared with normal cells (Prosser *et al.* 1997). However, a few studies have reported rates of apoptosis in DCIS that are up to 10-fold higher than typically seen in normal cells (Bodis *et al.* 1996, Harn *et al.* 1997, Prosser *et al.* 1997), yet DCIS have a large positive growth imbalance, suggesting that the

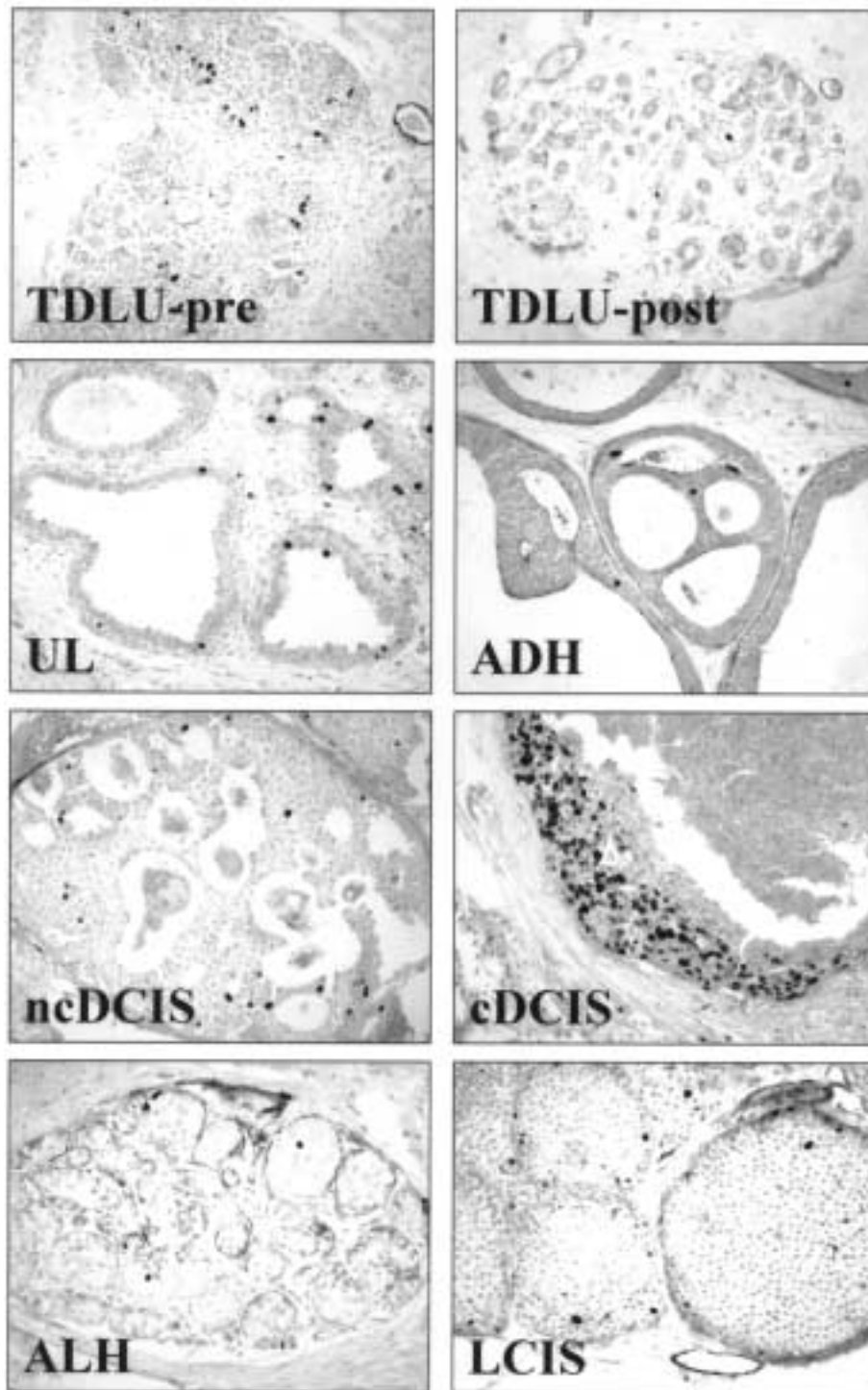


Figure 3 Examples of typical proliferation rates in premalignant breast lesions as assessed by immunohistochemistry using the Ki67 antibody (small dark nuclei represent dividing cells). Terminal ductal lobular units (TDLUs) in premenopausal (pre) women usually contain more proliferating cells than TDLUs in postmenopausal (post) women due to the mitogenic effects of estrogen. Unfolded lobules (ULs), atypical ductal hyperplasias (ADHs), and low-grade 'non-comedo' ductal carcinoma *in situ* (ncDCIS) contain, on average, two to three times more proliferating cells than normal TDLUs. Typically, a large proportion of cells are proliferating in high-grade 'comedo' DCIS (cDCIS). Proliferation is usually quite low in atypical lobular hyperplasia (ALH) and lobular carcinoma *in situ* (LCIS).

relationship between cell proliferation and death may not always be accurately portrayed by the static methods used to measure these dynamic processes. Like proliferation, apoptosis seems to vary with histological differentiation in DCIS, being much lower in non-comedo than comedo lesions (averaging about 1% vs 5% respectively) (Prosser *et al.* 1997). Disturbances of the equilibrium between cell proliferation and cell death probably result from alterations of several normal growth-regulating mechanisms including those involving sex hormones, oncogenes, tumor suppressor genes, and many other as yet unknown genetic and epigenetic abnormalities, some examples of which are discussed below.

Hormones and receptors in premalignant breast disease

Estrogen, mediated through the estrogen receptor (ER), plays a central role in regulating the growth and differentiation of normal breast epithelium (Henderson *et al.* 1988, Pike *et al.* 1993). It stimulates cell proliferation and regulates the expression of other genes including the progesterone receptor (PgR). PgR then mediates the mitogenic effect of progesterone, further stimulating proliferation (Henderson *et al.* 1988, Pike *et al.* 1993). Many additional factors collectively referred to as 'coactivators' and 'corepressors' have been discovered recently which appear to modulate the functions of these hormones and receptors, including their mitogenic activity (Horwitz *et al.* 1996).

Several studies have assessed ER expression in normal breast epithelium and premalignant lesions (Table 3). Most were immunohistochemical studies focusing presumably on ER-alpha, although the potential cross-reactivity for ER-beta of all the different antibodies used in these studies is not entirely clear. Mindful of this qualification, studies of normal TDLUs reported that nearly all (over 90%) express ER, but in a minority of cells (averaging about 30%) for all ages combined (Allegra *et al.* 1979, Peterson *et al.* 1986, Ricketts *et al.* 1991, Schmitt 1995, Mohsin *et al.* 2000a). In premenopausal women the average proportion of ER-positive cells in TDLUs is somewhat lower (about 20%) and varies with the menstrual cycle, being twice as high during the follicular phase as during the luteal phase (Ricketts *et al.* 1991). Proliferation in TDLUs peaks during the luteal phase (Potten *et al.* 1988), suggesting that the normal mitogenic effect of estrogen may be partially delayed, or indirect and mediated by downstream interactions

such as that between progesterone and PgR. The average proportion of ER-positive cells in TDLUs in postmenopausal women is somewhat higher (about 50%) and stable in the absence of hormone replacement therapy (Mohsin *et al.* 2000a). Very little is known about ER expression in ULs, although one preliminary study reported that virtually all express the receptor in over 90% of cells (Mohsin *et al.* 2000a). A few studies have evaluated ER in ADH and collectively agree that nearly all lesions express very high levels in nearly all cells (Barnes & Masood 1990, Schmitt 1995, Mohsin *et al.* 2000a). Many studies have evaluated ER in DCIS and, on average, about 75% of all cases express the receptor (Giri *et al.* 1989, Helin *et al.* 1989, Masood 1990, Pallis *et al.* 1992, Chaudhuri *et al.* 1993, Poller *et al.* 1993b, Zafrani *et al.* 1994, Leal *et al.* 1995, Albonico *et al.* 1996, Barnes & Berardo *et al.* 1996a, Bose *et al.* 1996, Karayiannakis *et al.* 1996, Mohsin *et al.* 2000a). Expression varies with histological differentiation, being highest in non-comedo lesions, where up to 100% show expression in over 90% of cells, and lowest in comedo lesions, where only about 30% show expression in a minority of cells. ER is not expressed in about 25% of DCIS and these are predominantly high-grade comedo lesions. Over 90% of LCIS express high levels of ER in nearly all cells (Giri *et al.* 1989, Pertschuk *et al.* 1990, Pallis *et al.* 1992, Fisher *et al.* 1996, Rudas *et al.* 1997, Libby *et al.* 1998, Querzoli *et al.* 1998), which is probably similar in ALH although formal studies are lacking.

Prolonged estrogen exposure is an important risk factor for developing IBC, perhaps by allowing random genetic alterations to accumulate in normal cells stimulated to proliferate (Henderson *et al.* 1988), which may also be true for cells in premalignant lesions. The very high levels of ER observed in nearly all premalignant lesions (Fig. 4) may contribute to their increased proliferation relative to normal cells by allowing them to respond more effectively to any level of estrogen, even the low concentrations observed in postmenopausal women (Mohsin *et al.* 2000a). In addition to increased levels of expression, however, there may be other alterations of ER resulting in increased growth. For example, proliferation in TDLUs occurs predominantly in ER-negative epithelium (Clarke *et al.* 1997, Russo *et al.* 1999), whereas the majority of dividing cells in premalignant lesions are ER positive (Shocker *et al.* 1999), so the normal compartmentalization of hormonally regulated growth appears to be disrupted early on. As another example, one recent study measured proliferation in TDLUs and premalignant lesions from the same breasts in a large number of patients stratified by menopausal status (Mohsin *et al.* 2000a). Proliferation rates in TDLUs were nearly threefold lower in postmenopausal compared with premenopausal women, consistent with the expected mitogenic effect of estrogen in normal cells. In contrast, the difference in proliferation in premalignant lesions stratified by menopausal status was less than half that of normal cells, again

Table 3 Estrogen receptor expression in premalignant breast lesions

	TDLU	UL	ADH	DCIS	ALH	LCIS
% Containing ER-positive cells	90%	95%	95%	75%	high	95%
Average % ER-positive cells	30%	90%	90%	45%	high	90%

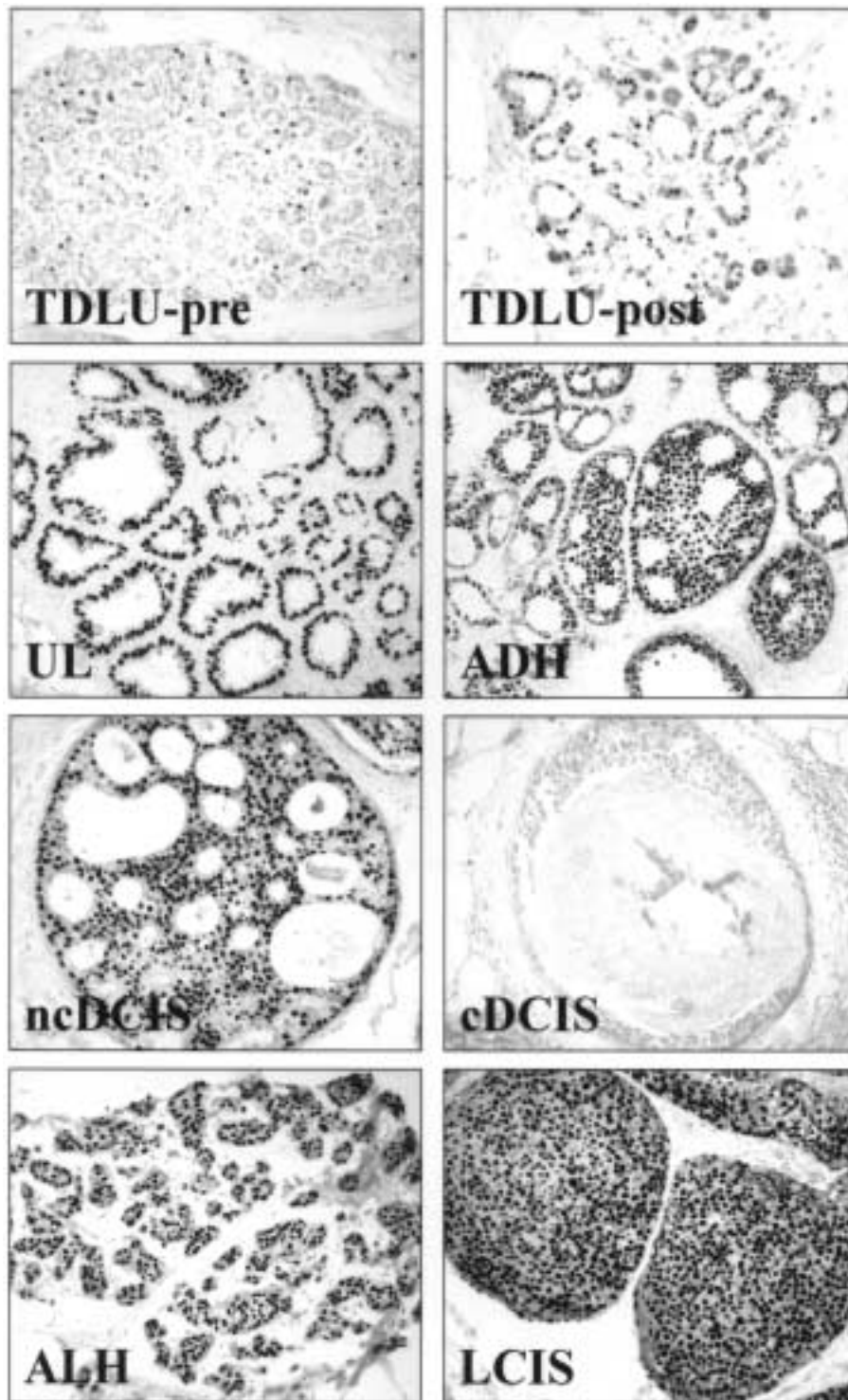


Figure 4 Examples of typical estrogen receptor (ER) expression in premalignant breast lesions as assessed by immunohistochemistry (small dark nuclei are ER-positive cells). Terminal duct lobular units (TDLUs) in premenopausal (pre) women usually contain relatively few ER-positive cells. In contrast, the majority of cells in TDLUs of postmenopausal (post) women express ER. Most premalignant breast lesions show very high levels of ER in nearly all cells, including unfolded lobules (ULs), atypical ductal hyperplasias (ADHs), low grade ‘non-comedo’ ductal carcinoma *in situ* (ncDCIS), atypical lobular hyperplasias (ALHs), and lobular carcinoma *in situ* (LCIS). The only significant exception is high grade ‘comedo’ DCIS (cDCIS) which often show low or no ER expression.

demonstrating that the hormonal regulation of proliferation in these lesions is fundamentally abnormal. Another particularly interesting recent study (Fuqua *et al.* 2000) found a somatic mutation in the ER gene in 30% of hyperplastic breast lesions (UDH) which, when transfected into breast cancer cell lines, showed much higher transcriptional activity and proliferation than wild-type ER at very low concentrations of estrogen such as seen in postmenopausal women (Fig. 5). The mutated ER also showed increased binding to the co-activator TIF-2, which may partially explain its increased functional responsiveness to estrogen. Whatever the mechanisms, the hypersensitivity to estrogen associated with this mutation may play a very important role in the early development and progression of premalignant breast disease.

Oncogenes and tumor suppressor genes in premalignant breast disease

In addition to proliferation and ER, a large number of other biological characteristics have been evaluated in human

pre-malignant breast disease, but the majority of studies have been small and have not been validated (see reviews: Berardo *et al.* 1996b, Allred *et al.* 1997, Libby *et al.* 1999, Allred & Mohsin 2000). Exceptions include the erbB2 oncogene and p53 tumor suppressor gene, which have both been evaluated in a large number of studies.

erbB2 is amplified and/or overexpressed in 20–30% of IBCs (Ravdin & Chamness 1995). These abnormalities are associated with increased proliferation, poor clinical outcome, and altered responsiveness to various types of adjuvant therapies (De Potter 1994, Ravdin & Chamness 1995, DiGiovanna 1999). erbB2 may also promote cell motility (De Potter & Quatacker 1993, De Potter 1994), which could contribute to the ability of tumor cells overexpressing erbB2 to invade and metastasize. Nearly all studies of erbB2 in premalignant breast disease have used immunohistochemistry to detect overexpression of the oncoprotein, which is highly correlated with gene amplification (Venter *et al.* 1987). Overexpression has not been observed in TDLUs (De Potter *et al.* 1989, Allred *et al.*

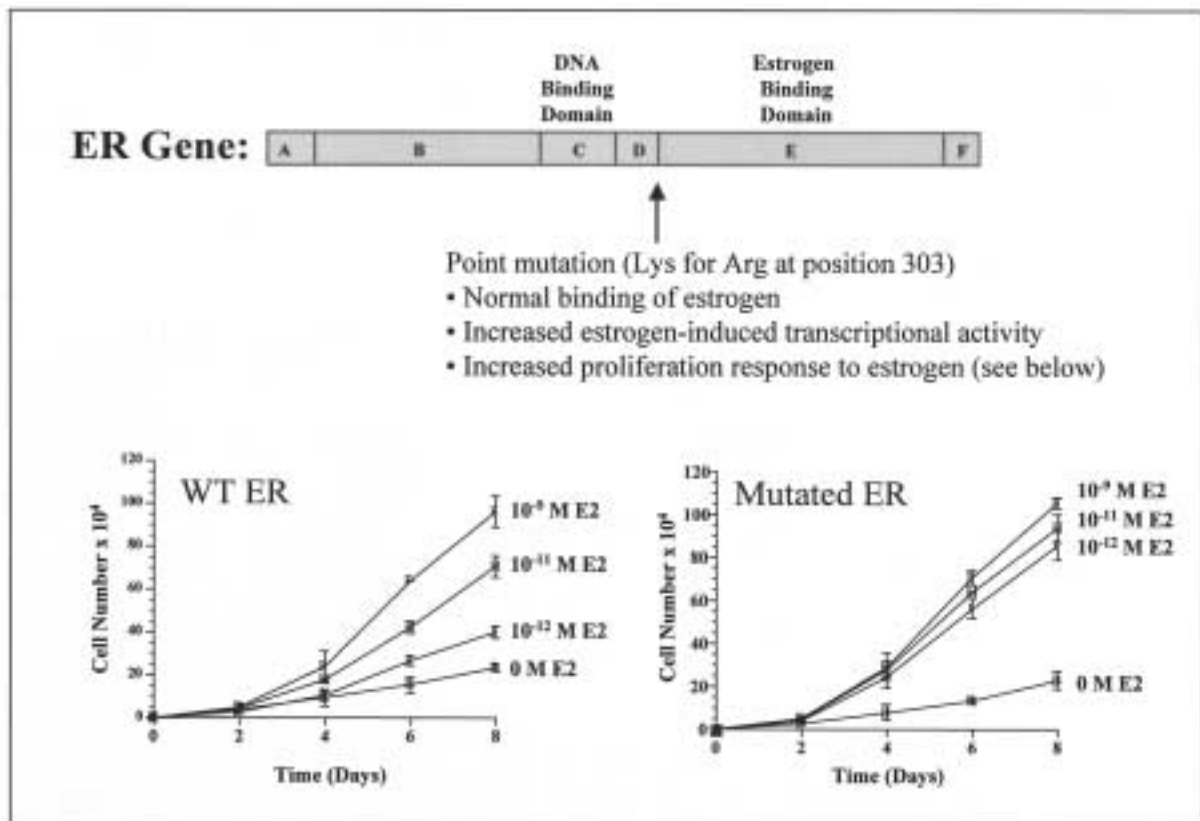


Figure 5 Somatic point mutation (Lys for Arg at position 303) of the estrogen receptor (ER) gene identified in a high proportion of hyperplastic breast lesions that results in functional 'hypersensitivity' to estrogen. The mutated ER has normal binding affinity for estrogen but, when transfected into breast cancer cell lines, results in markedly increased transcriptional activity and proliferation in response to estrogen. In the growth curves shown, note the much higher rates of growth at very low estrogen (E2) concentrations in the cells transfected with mutated compared with wild type (WT) ER. These phenomena, especially the increased proliferation, could be very important in the early development of premalignant breast lesions and their progression to cancer.

1992) and it has been detected only rarely in ADH (Gusterson *et al.* 1988, De Potter *et al.* 1989, Lodato *et al.* 1990, Allred *et al.* 1992). Many studies have evaluated *erbB-2* in DCIS (van de Vijer *et al.* 1988, Bartkova *et al.* 1990, Lodato *et al.* 1990, Ramachandra *et al.* 1990, Barnes *et al.* 1991, Walker *et al.* 1991, Allred *et al.* 1992, Barnes *et al.* 1992a, Schimmelpenninck *et al.* 1992, Somerville *et al.* 1992, De Potter *et al.* 1993, 1995, Tsuda *et al.* 1993, Bobrow *et al.* 1994, Poller *et al.* 1994, Zafrani *et al.* 1994, Leal *et al.* 1995, Albonico *et al.* 1996, Berardo *et al.* 1996a). The average incidence of amplification and/or overexpression was about 10% in non-comedo compared with 60% in comedo lesions. However, as with many other biological features in DCIS, alterations of *erbB2* vary directly with differentiation on a histological continuum (Berardo *et al.* 1996a). Studies of *erbB2* in ALH have not been published, although several have addressed LCIS and reported abnormalities in about 2% (Gusterson *et al.* 1988, Lodato *et al.* 1990, Ramachandra *et al.* 1990, Porter *et al.* 1991, Somerville *et al.* 1992, Midulla *et al.* 1995, Fisher *et al.* 1996). Just how alterations of *erbB-2* lead to the development and progression of premalignant breast disease is not entirely clear, although both the increased proliferation and motility of cells associated with overexpression may contribute. Whatever the mechanisms, the absence of overexpression in normal TDLUs and ADH, compared with the relatively high rate in DCIS, suggests that alterations of *erbB2* are an important event in early malignant transformation.

p53 also appears to play an important role in the evolution of premalignant breast disease. This tumor suppressor gene is mutated in about 30% of IBCs, which is associated with generally aggressive biological features and poor clinical outcome (Elledge & Allred 1994, Chang *et al.* 1995). Most are missense point mutations resulting in an inactivated but stabilized protein that accumulates to very high levels in the cell nucleus (Davidoff *et al.* 1991a). Hence, measuring protein levels is a relatively easy and accurate surrogate assay for detecting mutations and most studies of premalignant disease have used immunohistochemistry to assess p53 status. With the exception of morphologically 'normal' breast epithelium in Li-Fraumeni patients with inherited mutations (Barnes *et al.* 1992b), abnormalities of p53 have not been reported in TDLUs (Bartek *et al.* 1990, Davidoff *et al.* 1991b, Eriksson *et al.* 1994, Rajan *et al.* 1997). p53 also appears to be normal in nearly all ADH (Bartek *et al.* 1990, Umekita *et al.* 1994, Chitemere *et al.* 1996). Similar to *erbB2*, many studies have assessed p53 in DCIS (Walker *et al.* 1991, Poller *et al.* 1993a, Tsuda *et al.* 1993, Bobrow *et al.* 1994, Eriksson *et al.* 1994, O'Malley *et al.* 1994, Zafrani *et al.* 1994, Leal *et al.* 1995, Schmitt 1995, Albonico *et al.* 1996, Berardo *et al.* 1996a, Bose *et al.* 1996, Chitemere *et al.* 1996, Siziopikou *et al.* 1996, Rajan *et al.* 1997) and found alterations to correlate directly with histological differentiation, being quite rare (about 5%) in

low-grade non-comedo lesions, and relatively common (about 40%) in high-grade comedo lesions. Abnormalities of p53 have been detected in only about 5% of LCIS (Domagala *et al.* 1993, Younes *et al.* 1995), which is probably similar to ALH. Mutations of p53 may contribute to the development and progression of premalignant breast disease by several mechanisms, including interference with DNA repair through loss of an important G1 cell-cycle checkpoint, leading to replication of a damaged DNA template and genetic instability, and also perhaps by clonal expansion through inhibition of programmed cell death (Levine 1997).

Most of the biological abnormalities responsible for the development and progression of premalignant breast lesions are still unknown. Recent genetic studies demonstrate that their biological evolution is very complex. Many recent studies have assessed allelic imbalance (AI) by loss of heterozygosity (LOH) analysis or comparative genomic hybridization (CGH) (Table 4). These methods can identify the general chromosomal locations of non-functional tumor suppressor genes (through losses) or amplified oncogenes (through gains) that may be important in the development of premalignant disease.

Studies of AI in premalignant lesions from non-cancerous breasts (i.e. without synchronous IBC) are an ideal setting to identify genetic alterations that may be important in the early development of these lesions. Those assessing atypical hyperplasias (ADH and ALH) have shown that up to 50% contain one or more AIs among more than 30 genetic loci distributed over 10 chromosomes that have been evaluated so far (Lakhani *et al.* 1995b, Rosenberg *et al.* 1996, 1997, Chauqui *et al.* 1997, Nayar *et al.* 1997, O'Connell *et al.* 1998). Not surprisingly, AIs were more common in non-invasive carcinomas (DCIS and LCIS) than in hyperplasias. Nearly all DCIS showed at least one AI among more than 100 genetic loci on 17 chromosomes studied so far, consistent with the notion that they represent a relatively late stage of evolution (Radford *et al.* 1993, 1995a, O'Connell *et al.* 1994, 1998, Aldaz *et al.* 1995, Munn *et al.* 1995, Stratton *et al.* 1995, Fujii *et al.* 1996a,b, Man *et al.* 1996, Chappell *et al.* 1997, Waldman *et al.* 2000). LCIS has also shown multiple gains and losses involving at least 8 chromosomes (Lakhani *et al.* 1995a, Nayar *et al.* 1997, Lu *et al.* 1998). In contrast to atypical hyperplasias, which usually show only one or two imbalances individually, *in situ* carcinomas typically demonstrate many, especially comedo DCIS which in one study had as many as eight in a single lesion (O'Connell *et al.* 1998). The highest rates of AI in DCIS approach 80% and involve loci on chromosomes 16q, 17p, and 17q, suggesting that altered genes in these regions may be particularly important in the development of DCIS. The genetic diversity of DCIS and LCIS assessed by LOH and CGH rivals the complexity observed in IBC.

Several studies have evaluated AI in premalignant lesions from non-cancerous breasts compared with

Table 4 General chromosomal locations of allelic imbalances (gains and losses) in premalignant breast lesions from studies assessing loss of heterozygosity and comparative genomic hybridization

Category	Losses	Gains
ADH	1q, 2p, 6q, 9p, 11p, 11q, 13q, 14q, 16q, 17p, 17q, Xq	Unknown
ALH	11q, 16p, 16q, 17p, 22q	6q
DCIS	1p, 1q, 2p, 2q, 3p, 3q, 4p, 6p, 6q, 7p, 7q, 8p, 8q, 9p, 11p, 11q, 12p, 13q, 14q, 15q, 16p, 16q, 17p, 17q, 18q, 21q	1q, 3q, 6p, 6q, 8q, 17q, 20q, Xq
LCIS	11q, 13q, 16p, 16q, 17p, 17q, 22q	6q

histologically similar lesions from cancerous breasts as a strategy to identify alterations which might be important in the progression to invasive disease (Allred & Mohsin 2000). Following this strategy, one recent study of a marker on chromosome 11p (D11S988) showed rates of LOH increasing from 10% to 20% in UDH, 10% to 40% in ADH, and 20% to 70% in DCIS (O'Connell *et al.* 1998). The gene for cyclin D1 resides near this locus, suggesting that alteration of its function may be important in tumor progression, although many other genes in this region are probably also involved. In the same study, comedo DCIS showed significant increases in LOH at several other loci including D2S362 on 2q (10% to 40%), D13S137 on 13q (10% to 40%), and D17S597 on 17q (5% to 40%), suggesting that high-grade DCIS is particularly unstable genetically and that several alterations may be important in tumor progression.

Studies of AI in premalignant breast lesions from cancerous breasts also provide an opportunity to assess shared alterations with synchronous IBC as an indication of their evolutionary relatedness. In one recent study (O'Connell *et al.* 1998) assessing LOH at 15 loci on 12 chromosomes, 50% of ADH shared their LOH phenotypes with synchronous IBC, providing novel and compelling genetic evidence that ADH is a direct precursor of IBC. Many studies of DCIS and a few of LCIS have shown that nearly all lesions share several identical AIs with synchronous IBC, providing convincing if not surprising evidence that they too are evolutionarily related (Radford *et al.* 1995b, Stratton *et al.* 1995, Zhuang *et al.* 1995, Fujii *et al.* 1996a, Ahmadian *et al.* 1997, Dillon *et al.* 1997, O'Connell *et al.* 1998). Synchronous DCIS and IBC may occasionally show distinct AIs, suggesting that there may also be divergent aspects to their evolution (Fujii *et al.* 1996a).

An interesting study by Deng and colleagues (Deng *et al.* 1996) noted that histologically normal TDLUs shared LOH for markers on 3p, 11p, and 17p with closely adjacent IBC, while TDLUs farther away in the same breast did not, suggesting that even normal appearing epithelium may have genotypic abnormalities associated with an elevated risk for developing breast cancer.

Studies of LOH, CGH, and many other methodologies over the past decade provide crude but compelling evidence that IBC evolves from premalignant lesions by highly diverse genetic and epigenetic mechanisms. Hopefully, future studies will provide more detailed information about specific mechanisms which can be manipulated to prevent the development and progression of premalignant disease. Progress in the past has been hampered by a reliance on correlative studies of small archival tissue samples from patients that are difficult to obtain – due in part to a lack of appropriate cell lines and animals to support mechanistic studies. Fortunately, cell lines and animal models are beginning to emerge to support the mechanistic studies necessary for more fundamental progress (Allred & Medina 2000), such as the MCF10AT cell line that can mimic certain aspects of ADH and DCIS (Dawson *et al.* 1996, Shekhar *et al.* 1998).

Prognostic factors in premalignant breast disease

Premalignant lesions are very common and they are being diagnosed more frequently due to increasing public awareness and screening mammography. They are currently defined by their histological features and their prognosis is imprecisely estimated based on indirect epidemiological evidence (Page & Dupont 1993). While lesions within specific categories look alike histologically, there must be underlying biological differences causing a subset to progress to IBC. Studies identifying biological prognostic factors in premalignant disease are beginning to emerge.

For example, preliminary results from two recent studies suggest that increased levels of ER in normal breast epithelium (Khan *et al.* 1998) and certain premalignant lesions (UL, ADH, and DCIS) (Mohsin *et al.* 2000b) may be associated with a two- to threefold increased risk of developing IBC, and assessing ER status may eventually be important in clinical management. Its most promising role may be in identifying patients with high-risk premalignant lesions who might benefit from hormonal therapy. In the recent National Surgical Adjuvant Breast Project (NSABP) P-1 chemoprevention clinical trial (Fisher *et al.* 1998),

patients with a history of ADH receiving tamoxifen experienced a dramatic decrease (85%) in breast cancer incidence. Nearly all ADH express very high levels of ER, suggesting that highly ER-positive premalignant lesions may be particularly susceptible to hormonal therapy. The success of this trial is proof-of-principle that targeting biological alterations in premalignant disease is a rational strategy for the chemoprevention of breast cancer.

erbB2 and p53 may also become useful prognostic factors in managing patients with premalignant breast disease, based on recent studies suggesting that patients with benign breast lesions showing low levels of amplification of the erbB2 gene (Stark *et al.* 2000), or slightly elevated levels of p53 protein (Rohan *et al.* 1998), have a two- to threefold increased relative risk of developing IBC.

The transforming growth factor-beta (TGF- β) pathway may also be important. TGF- β s are important growth suppressing factors in normal breast epithelium and their activity is mediated by specific receptors, including TGF- β -RII in particular. Most normal breast epithelia express high levels of TGF- β -RII and an interesting recent study showed that reduced levels of this receptor in UDH added an additional threefold risk of developing IBC in patients with this type of lesion (Gobbi *et al.* 1999). Given that UDH may not be a major precursor of IBC, it will be important to validate this study in other lesions with more direct premalignant potential, such as ADH.

Far less is known about prognostic factors in premalignant disease than in IBC, although knowledge in this area is increasing rapidly. No single factor so far appears to be particularly powerful in predicting the development of IBC, and panels of multiple factors will probably be more useful. This should not be surprising, given the high degree of biological complexity in these lesions. High priority should be given to identifying additional prognostic factors because success in identifying and treating high-risk premalignant disease has the potential to prevent the majority of lethal invasive breast cancers.

Acknowledgements

This work was supported by NIH grants PO1 CA 30195, P50 CA 58183, and RO1 CA 72038.

References

- Ahmadian M, Wistuba II, Fong KM, Behrens C, Kodagoda DR, Saboorian MH, Shay J, Tomlinson GE, Blum J, Minna JD & Gazdar AF 1997 Analysis of the FHIT gene and FRA3B regions in sporadic breast cancer preneoplastic lesions and familial breast cancer probands. *Cancer Research* **57** 3664–3668.
- Albonico G, Querzoli P, Feretti S, Magri E & Nenci I 1996 Biophenotypes of breast carcinoma *in situ* defined by image analysis of biological parameters. *Pathology, Research and Practice* **192** 117–123.
- Alldred DC, Chen T, Sahin A, Cunningham J & Bondy M 1995 Comparative allelotyping of *in situ* and invasive human breast cancer: high frequency of microsatellite instability in lobular breast carcinomas. *Cancer Research* **55** 3976–3981.
- Allegra JC, Lippman ME, Green L, Barlock A, Simon R, Thompson EB, Hugg KK & Griffin W 1979 Estrogen receptor values in patients with benign breast disease. *Cancer* **44** 228–231.
- Allred DC & Medina D 2000 Introduction: models of premalignant breast disease. *Journal of Mammary Gland Biology Neoplasia* **5** 339–340.
- Allred DC & Mohsin SK 2000 Biological features of human premalignant breast disease. In *Diseases of the Breast*, pp 355–366. Eds JR Harris, ME Lippman, M Morrow & CK Osborne. Philadelphia: Lippincott Williams and Wilkins.
- Allred DC, Clark GM, Molina R, Tandon AK, Schnitt SJ, Gilchrist KW, Osborne CK, Tormey DC & McGuire WL 1992 Overexpression of HER-2/neu and its relationship with other prognostic factors change during the progression of *in situ* to invasive breast cancer. *Human Pathology* **23** 974–979.
- Allred DC, Berardo DM, Prosser J & O'Connell P 1997 Biologic and genetic features of *in situ* breast cancer. In *Ductal Carcinoma In Situ of the Breast*, pp 37–47. Ed. MJ Silverstein. Baltimore: Williams & Wilkins.
- Alpers CE & Wellings SR 1985 The prevalence of carcinoma *in situ* in normal and cancer-associated breasts. *Human Pathology* **16** 796–807.
- Barnes R & Masood S 1990 Potential value of hormone receptor assay in carcinoma *in situ* of breast. *American Journal of Clinical Pathology* **94** 533–537.
- Barnes DM, Meyer JS, Gonzalez JG, Gullick WJ & Millis RR 1991 Relationship between c-erbB-2 immunoreactivity and thymidine labeling index in breast carcinoma *in situ*. *Breast Cancer Research Treatment* **18** 11–17.
- Barnes DM, Bartkova J, Camplejohn RS, Gullick WJ, Smith PJ & Millis RR 1992a Overexpression of the c-erbB-2 oncoprotein: why does this occur more frequently in ductal carcinoma *in situ* than in invasive mammary carcinoma and is this of prognostic significance? *European Journal of Cancer* **28** 644–648.
- Barnes DM, Hanby AM, Gillett CE, Mohammed S, Hodgson S, Bobrow LG, Leigh IM, Purkis T, MacGeoch C, Spurr ND, Bartek J, Vojtesek B, Pickett SM & Lane DP 1992b Abnormal expression of wild type p53 protein in normal cells of a cancer family patient. *Lancet* **340** 259–263.
- Bartek J, Bartkova J, Vojtesek B, Staskova Z, Rejthar A, Kovarik J & Lane DP 1990 Patterns of expression of the p53 tumor suppressor in human breast tissues and tumours *in situ* and *in vitro*. *International Journal of Cancer* **46** 839–844.
- Bartkova J, Barnes DM, Millis RR & Gullick WJ 1990 Immunohistochemical demonstration of c-erbB-2 protein in mammary ductal carcinoma *in situ*. *Human Pathology* **21** 1164–1167.
- Berardo M, Hilsenbeck SG & Allred DC 1996a Histological grading of noninvasive breast cancer and its relationship to biological features. *Laboratory Investigations* **74** 68.
- Berardo MD, O'Connell POC & Allred DC 1996b Biologic characteristics of premalignant and preinvasive breast disease. In *Hormone-Dependent Cancer*, pp 1–23. Eds JR Pasqualini & BS Katzenellenbogen. New York: Marcel Dekker Inc.
- Bobrow LG, Happerfield LC, Gregory WM, Springall RD & Millis RR 1994 The classification of ductal carcinoma *in situ* and its

- association with biological markers. *Seminars in Diagnostic Pathology* **11** 199–207.
- Bodis S, Siziopikou KP, Schitt SJ, Harris JR & Fisher DE 1996 Extensive apoptosis in ductal carcinoma *in situ* of the breast. *Cancer* **77** 1831–1835.
- Bose S, Lesser ML, Norton L & Rosen PP 1996 Immunophenotype of intraductal carcinoma. *Archives of Pathology and Laboratory Medicine* **120** 81–85.
- Chang F, Syrjanen S & Syrjanen K 1995 Implications of the p53 tumor-suppressor gene in clinical oncology. *Journal of Clinical Oncology* **13** 1009–1022.
- Chappell SA, Walsh T, Walker RA & Shaw JA 1997 Loss of heterozygosity at chromosome 6q in preinvasive and early invasive breast carcinomas. *British Journal of Cancer* **75** 1324–1329.
- Chaudhuri B, Crist KA, Mucci S, Malafa M & Chaudhuri PK 1993 Distribution of estrogen receptor in ductal carcinoma *in situ* of the breast. *Surgery* **113** 134–137.
- Chauqui RF, Zhuang Z, Emmert-Buck MR, Liotta LA & Merino MJ 1997 Analysis of loss of heterozygosity on chromosome 11q13 in atypical ductal hyperplasia and *in situ* carcinoma of the breast. *American Journal of Pathology* **150** 297–303.
- Chitemere M, Andersen TI, Hom R, Karlsen F, Borresen A-L & Nesland JM 1996 TP53 alterations, atypical ductal hyperplasia and ductal carcinoma *in situ* of the breast. *Breast Cancer Research Treatment* **41** 103–109.
- Clarke RB, Howell H, Potten CS & Anderson E 1997 Dissociation between steroid receptor expression and cell proliferation in the human breast. *Cancer Research* **57** 4987–4991.
- Davidoff AM, Humphrey PA, Iglehart JD & Marks JR 1991a Genetic basis for p53 overexpression in human breast cancer. *PNAS* **88** 5006–5010.
- Davidoff AM, Kerns B-JM, Pence JC, Marks JR & Iglehart JD 1991b p53 alterations in all stages of breast cancer. *Journal of Surgical Oncology* **48** 260–267.
- Dawson PJ, Wolman SR, Tait L, Heppner GH & Miller FR 1996 MCF10AT: a model for the evolution of cancer from proliferative breast disease. *American Journal of Pathology* **148** 313–319.
- De Potter CR 1994 The neu-oncogene: more than a prognostic factor? *Human Pathology* **25** 1264–1268.
- De Potter CR & Quatacker J 1993 The p185/erbB2 protein is localized on cell organelles involved in cell motility. *Clinical and Experimental Metastasis* **11** 453–461.
- De Potter CR, Praet MM, Slavin RE, Verbeeck P & Roels HJ 1987 Feulgen DNA content and mitotic activity in proliferative breast disease: a comparison with ductal carcinoma *in situ*. *Histopathology* **7** 1307–1319.
- De Potter CR, van Daele S, van de Vijer MJ, Pauwels C, Maertens G, De Boever J, Vandekerckhove D & Roels H 1989 The expression of the neu oncogene product in breast lesions and in normal fetal and adult human tissues. *Histopathology* **15** 351–362.
- De Potter CR, Foschini MP, Schelfhout AM, Schroeter CA & Eusebi V 1993 Immunohistochemical study of neu protein overexpression in clinging *in situ* duct carcinoma of the breast. *Virchows Archiv. A: Pathology. Pathologische Anatomie* **422** 375–380.
- De Potter CR, Schelfhout A-M, Verbeeck P, Lakhani SR, Brunken R, Schroeter CA, Van Den Tweel JG, Schauer AJ & Sloane JP 1995 neu-Overexpression correlates with extent of disease in large cell ductal carcinoma *in situ* of the breast. *Human Pathology* **26** 601–606.
- Deng G, Lu Y, Zlotnikov G, Thor AD & Smith HS 1996 Loss of heterozygosity in normal tissue adjacent to breast carcinomas. *Science* **274** 2057–2059.
- Dickson RB & Russo J 2000 Biochemical control of breast development. In *Diseases of the Breast* pp 19–20. Eds JR Harris, ME Lippman, M Morrow & CK Osborne. Philadelphia: Lippincott Williams and Wilkins.
- DiGiovanna MP 1999 Clinical significance of HER-2/neu overexpression. *Principles & Practice of Oncology Updates* **13** (9 & 10), 1–10; 1–14.
- Dillon EK, de Boer WB, Papadimitriou JM & Turbett GR 1997 Microsatellite instability and loss of heterozygosity in mammary carcinoma and its probable precursors. *British Journal of Cancer* **76** 156–162.
- Domagala W, Markiewski M, Kubiak R, Bartkowiak J & Osborn M 1993 Immunohistochemical profile of invasive lobular carcinoma of the breast: predominantly vimentin and p53 protein negative cathepsin D and oestrogen receptor positive. *Virchows Archiv. A. Pathological Anatomy and Histopathology* **423** 497–502.
- Dupont WD & Page DL 1985 Risk factors for breast cancer in women with proliferative breast disease. *New England Journal of Medicine* **312** 146–151.
- Dupont WD, Parl FF, Hartmann WH, Brinton LA, Winfield AC, Worrel JA, Schuyler AP & Plummer WD 1993 Breast cancer risk associated with proliferative breast disease and atypical hyperplasia. *Cancer* **71** 1258–1265.
- Elledge RM & Allred DC 1994 The p53 tumor suppressor gene in breast cancer. *Breast Cancer Research Treatment* **32** 39–47.
- Eriksson ET, Schmmpelning H, Aspenblad U, Zetterberg A & Auer GU 1994 Immunohistochemical expression of the mutant p53 protein and nuclear DNA content during the transition from benign to malignant breast disease. *Human Pathology* **25** 1228–1233.
- Ferguson DJP & Anderson TJ 1981 Morphological evaluation of cell turnover in relation to the menstrual cycle in the ‘resting’ human breast. *British Journal of Cancer* **44** 177–181.
- Fisher ER, Costantino J, Fisher B, Palekar AS, Paik SM, Suarez CM & Wolmark N 1996 Pathologic findings from the National Surgical Adjuvant Breast Project (NSABP) protocol B-17. *Cancer* **78** 1403–1416.
- Fisher B, Costantino JP, Wickerham DL, Redmond CK, Kavanah M, Cronin WM, Vogel V, Robidoux A, Dimitrov N, Atkins J, Daly M, Wieand S, Tan-Chiu E, Ford L, Wolmark N & Investigators of the NSABP 1998 Tamoxifen for prevention of breast cancer: report of the National Surgical Adjuvant Breast and Bowel Project P-1 study. *Journal of the National Cancer Institute* **90** 1371–1388.
- Footo FW & Stewart FW 1945 Comparative studies of cancerous versus noncancerous breasts. *Annals of Surgery* **121** 197–222.
- Fujii H, Marsh C, Cairns P, Sidransky D & Gabrielson E 1996a Genetic divergence in the clonal evolution of breast cancer. *Cancer Research* **56** 1493–1497.
- Fujii H, Szumel R, Marsh C, Zhou W & Gabrielson E 1996b Genetic progression histologic grade and allelic loss in ductal carcinoma *in situ* of the breast. *Cancer Research* **56** 5260–5265.
- Fuqua SAW, Witschke C, Zhang ZX, Borg A, Castles CG, Friedrichs WE, Hopp T, Hilsenbeck S, Mohsin S, O’Connell P & Allred DC 2000 A hypersensitive estrogen receptor-alpha

- mutation in premalignant breast lesions. *Cancer Research* **60** 4026–4029.
- Giri DD, Dundas AC, Nottingham JF & Underwood JCE 1989 Oestrogen receptors in benign epithelial lesions and intraductal carcinomas of the breast: an immunohistological study. *Histopathology* **15** 575–584.
- Gobbi H, Dupont WD, Simpson JF, Plummer WDJ, Schuyler PA, Olson SJ, Arteaga CL & Page DL 1999 Transforming growth factor-beta and breast cancer risk in women with mammary epithelial hyperplasia. *Journal of the National Cancer Institute* **91** 2096–2101.
- Going JJ, Anderson TJ, Battersby S & Macintyre CCA 1988 Proliferative and secretory activity in human breast during natural and artificial cycles. *American Journal of Pathology* **130** 193–204.
- Gusterson BA, Machin LG, Gullick WJ, Gibbs NM, Powles TJ, Elliott C, Ashley S, Monaghan P & Harrison S 1988 c-erbB-2 expression in benign and malignant breast disease. *British Journal of Cancer* **58** 453–457.
- Harn HJ, Shen KL, Yueh KC, Ho LI, Yu JC, Chiu SC & Lee WH 1997 Apoptosis occurs more frequently in intraductal carcinoma than in infiltrating duct carcinoma of human breast cancer and correlates with altered p53 expression: detected by terminal-deoxynucleotidyl-transferase-mediated dUTP-FITC nick end labelling (TUNEL). *Histopathology* **31** 534–539.
- Helin HJ, Helle MJ, Kallioneimi OP & Isona JJ 1989 Immunohistochemical determination of estrogen and progesterone receptors in human breast carcinoma: correlation with histopathology and DNA flow cytometry. *Cancer* **63** 1761–1767.
- Henderson BE, Ross R & Bernstein L 1988 Estrogens as a cause of human cancer: the Richard and Hindau Rosenthal Foundation Award Lecture. *Cancer Research* **48** 246–253.
- Horwitz KB, Jackson TA, Bain DL, Richer JK, Takimoto GS & Tung L 1996 Nuclear receptor coactivators and corepressors. *Molecular Endocrinology* **10** 1167–1177.
- Hoshi K, Tokunaga M, Mochizuki M, Ohtake T, Katagata N, Wakasa H & Suzuki T 1995 Pathological characterization of atypical ductal hyperplasia of the breast. *Japanese Journal of Cancer Chemotherapy* **22** (Suppl. 1) 36–41.
- Joshi K, Smith JA, Perusinghe N & Monaghan P 1986 Cell proliferation in the human mammary epithelium: differential contribution by epithelial and myoepithelial cells. *American Journal of Pathology* **124** 199–206.
- Khan SA, Rogers MAM, Khurana KK, Meguid MM & Numann PJ 1998 Estrogen receptor expression in benign breast epithelium and breast cancer risk. *Journal of the National Cancer Institute* **89** 37–42.
- Kamel OW, Franklin WA, Ringus JC & Meyer JS 1989 Thymidine labeling index and Ki-67 growth fraction in lesions of the breast. *American Journal of Pathology* **134** 107–113.
- Karayiannakis AJ, Bastounis EA, Chatzigianni EB, Makri GG, Alexiou D & Karamanakos P 1996 Immunohistochemical detection of oestrogen receptors in ductal carcinoma *in situ* of the breast. *European Journal of Surgical Oncology* **22** 578–582.
- Lakhani SR, Collins N, Sloane JP & Stratton MR 1995a Loss of heterozygosity in lobular carcinoma *in situ*. *Journal of Clinical Pathology: Molecular Pathology* **48** M74–M78.
- Lakhani SR, Collins N, Stratton MR & Sloane JP 1995b Atypical ductal hyperplasia of the breast: clonal proliferation with loss of heterozygosity on chromosomes 16q and 17p. *Journal of Clinical Pathology* **48** 611–615.
- Leal CB, Schmitt FC, Bento MJ, Maia NC & Lopes CS 1995 Ductal carcinoma *in situ* of the breast. Histologic categorization and its relationship to ploidy and immunohistochemical expression of hormone receptors p53 and c-erbB-2 protein. *Cancer* **75** 2123–2131.
- Levine AJ 1997 p53 the cellular gatekeeper for growth and division. *Cell* **88** 323–331.
- Libby AL, O'Connell P & Allred DC 1998 Lobular carcinoma *in situ*: biological features including loss of heterozygosity. *Modern Pathology* **11** A112.
- Libby AL, Zellars RC, O'Connell P & Allred DC 1999 Biological characteristics of premalignant breast disease. In *Molecular Pathology of Early Cancer*, pp 79–95. Eds S Strivastava & A Gazdar. Amsterdam: IOS Press.
- Locker AP, Horrocks C, Gilmour AS, Ellis IO, Dowle CS, Elston CW & Blamey RW 1990 Flow cytometric and histological analysis of ductal carcinoma *in situ* of the breast. *British Journal of Surgery* **77** 564–567.
- Lodato RF, Maguire Jr HC, Greene MI, Weiner DB & LeVolsi VA 1990 Immunohistochemical evaluation of c-erbB-2 oncogene expression in ductal carcinoma *in situ* and atypical ductal hyperplasia of the breast. *Modern Pathology* **3** 449–454.
- London SJ, Connolly JL, Schnitt SJ & Solditz GA 1992 A prospective study of benign breast disease and the risk of breast cancer. *JAMA* **267** 941–944.
- Longacre TA & Bartow SA 1986 A correlative morphologic study of human breast and endometrium in the menstrual cycle. *American Journal of Surgical Pathology* **10** 382–393.
- Lu Y-L, Osin P, Lakhani SR, Di Palma S, Gusterson BA & Shipley JM 1998 Comparative genomic hybridization analysis of lobular carcinoma *in situ* and atypical lobular hyperplasia and potential roles for gains and losses of genetic material in breast neoplasia. *Cancer Research* **58** 4721–4727.
- Man S, Ellis IO, Sibbering M, Blamey RW & Brook JD 1996 High levels of allele loss at the FHIT and ATM genes in non-comedo ductal carcinoma *in situ* and grade I tubular invasive breast cancers. *Cancer Research* **56** 5484–5489.
- Meyer JS 1977 Cell proliferation in normal human breast duct fibroadenomas and other ductal hyperplasias measured by nuclear labeling with tritiated thymidine. *Human Pathology* **8** 67–81.
- Meyer JS 1986 Cell kinetics of histologic variants of *in situ* breast carcinoma. *Breast Cancer Research Treatment* **7** 171–180.
- Midulla C, Giovagnoli MR, Valli C & Vecchione A 1995 Correlation between ploidy status ERB-B2 and P53 immunohistochemical expression in primary breast carcinoma. *Analytical Quantitative Cytology and Histology* **17** 157–162.
- Mohsin SK, Hilsenbeck SG & Allred DC 2000a Estrogen receptors and growth control in premalignant breast disease. *Modern Pathology* **13** 28A (Abstract No. 145).
- Mohsin SK, Hilsenbeck SG & Allred DC 2000b Estrogen receptors and prognosis in premalignant breast disease. *Modern Pathology* **13** 28A (Abstract No. 146).
- Munn KE, Walker RA & Varley JM 1995 Frequent alterations of chromosome 1 in ductal carcinoma *in situ* of the breast. *Oncogene* **10** 1653–1657.
- Nayar R, Zhuang Z, Merino MJ & Silverberg SG 1997 Loss of heterozygosity on chromosome 11q13 in lobular lesions of the breast using tissue microdissection and polymerase chain reaction. *Human Pathology* **28** 277–282.

- O'Connell P, Pekkel V, Fuqua S, Osborne CK & Allred DC 1994 Molecular genetic studies of early breast cancer evolution. *Breast Cancer Research Treatment* **32** 5–12.
- O'Connell P, Pekkel V, Fuqua SAW, Osborne CK & Allred DC 1998 Analysis of loss of heterozygosity in 399 premalignant breast lesions at 15 genetic loci. *Journal of the National Cancer Institute* **90** 697–703.
- O'Malley FP, Vnencak-Jones CL, Dupont WD, Parl F, Manning S & Page DL 1994 p53 mutations are confined to the comedo type ductal carcinoma *in situ* of the breast: immunohistochemical and sequencing data. *Laboratory Investigation* **71** 67–72.
- Page DL & Dupont WD 1993 Anatomic indicators (histologic and cytologic) of increased breast cancer risk. *Breast Cancer Research Treatment* **28** 157–166.
- Page DL, Dupont WD, Rogers LW & Landenberger M 1982 Intraductal carcinoma of the breast: follow-up after biopsy only. *Cancer* **49** 751–758.
- Page DL, Dupont WD, Rogers LW & Rados MS 1985 Atypical hyperplastic lesions of the female breast: a long-term follow-up study. *Cancer* **55** 2698–2708.
- Page DL, Dupont WD & Rogers LW 1986 Breast cancer risk of lobular-based hyperplasia after biopsy: 'ductal' pattern lesions. *Cancer Detection and Prevention* **9** 441–448.
- Palli D, del Turco MR, Simoncini R & Bianchi S 1991 Benign breast disease and breast cancer: a case-control study in a cohort in Italy. *International Journal of Cancer* **47** 703–706.
- Pallis L, Wilking N, Cedermarck B, Rutqvist LE & Skoog L 1992 Receptors for estrogen and progesterone in breast carcinoma *in situ*. *AntiCancer Research* **12** 2113–2115.
- Pertschuk LP, Kim DS, Nayer K, Feldman JG, Eisenberg KB, Carter AC, Rong ZT, Thelmo WL, Fleisher J & Greene GL 1990 Immunocytochemical estrogen and progesterin receptor assays in breast cancer with monoclonal antibodies. *Cancer* **66** 1663–1670.
- Peterson OW, Hoyer PE & van Deurs B 1986 Frequency and distribution of estrogen receptor-positive cells in normal nonlactating human breast tissue. *Journal of the National Cancer Institute* **77** 343–349.
- Pike MC, Spicer DV, Dahmouh L & Press MF 1993 Estrogens, progestins, normal breast cell proliferation and breast cancer risk. *Epidemiologic Reviews* **15** 17–35.
- Poller DN, Roberts EC, Bell JA, Elston CW, Blamey RW & Ellis IO 1993a p53 protein expression in mammary ductal carcinoma *in situ*: relationship to immunohistochemical expression of estrogen receptor and c-erbB-2 protein. *Human Pathology* **24** 463–468.
- Poller DN, Snead DRJ, Roberts EC, Galea M, Bell JA, Gilmour A, Elston CW, Blamey RW & Ellis IO 1993b Oestrogen receptor expression in ductal carcinoma *in situ* of the breast: relationship to flow cytometric analysis of DNA and expression of the c-erbB-2 oncoprotein. *British Journal of Cancer* **68** 156–161.
- Poller DN, Silverstein MJ, Galea M, Locker AP, Elston CW, Blamey RW & Ellis IO 1994 Ductal carcinoma *in situ* of the breast: a proposal for a new simplified histological classification association between cellular proliferation and c-erbB-2 protein expression. *Modern Pathology* **7** 257–262.
- Porter PL, Garcia R, Moe R, Corwin DJ & Gown AM 1991 c-erbB-2 oncogene protein in *in situ* and invasive lobular breast neoplasia. *Cancer* **68** 331–334.
- Potten CS, Watson RJ, Williams GT, Tickle S, Roberts SA, Harris M & Howell A 1988 The effect of age and menstrual cycle upon proliferative activity of the normal human breast. *British Journal of Cancer* **58** 163–170.
- Prosser J, Hilsenbeck SG, Fuqua SAW, O'Connell P, Osborne CK & Allred DC 1997 Cell turnover (proliferation and apoptosis) in normal epithelium and premalignant lesions in the same breast. *Laboratory Investigation* **76** 24A (Abstract No. 119).
- Querzoli P, Albonico G, Ferretti S, Rinaldi R, Beccati D, Corcione S, Indelli M & Nenci I 1998 Modulation of biomarkers in minimal breast carcinoma: a model for human breast carcinoma progression. *Cancer* **83** 89–97.
- Radford DM, Fair K, Thompson AM, Ritter JH, Holt M, Steinbrueck T, Wallace M, Well SA & Donis-Keller HR 1993 Allelic loss on chromosome 17 in ductal carcinoma *in situ* of the breast. *Cancer Research* **53** 2947–2950.
- Radford DM, Fair KL, Phillips NJ, Ritter JH, Steinbrueck T & Holt MS 1995a Allelotyping of ductal carcinoma *in situ* of the breast: deletion of loci on 8p 13q 16q 17p and 17q. *Cancer Research* **55** 3399–3405.
- Radford DM, Phillips NJ, Fair KL, Ritter JH, Holt M & Donis-Keller H 1995b Allelic loss and the progression of breast cancer. *Cancer Research* **55** 5180.
- Rajan PB, Scott DJ, Perry RH & Griffith CDM 1997 p53 protein expression in ductal carcinoma *in situ* (DCIS) of the breast. *Breast Cancer Research Treatment* **42** 283–290.
- Ramachandra S, Machin L, Ashley S, Monaghan P & Gusterson BA 1990 Immunohistochemical distribution of c-erbB-2 in *in situ* breast carcinoma: a detailed morphological analysis. *Journal of Pathology* **161** 7–14.
- Ravdin PM & Chamness GC 1995 The c-erbB-2 proto-oncogene as a prognostic and predictive marker in breast cancer: a paradigm for the development of other macromolecular markers – a review. *Gene* **159** 19–27.
- Ricketts D, Turnbull L, Tyall G, Bakhshi R, Rawson NSB, Gazet JC, Nolan C & Coombes RC 1991 Estrogen and progesterone receptors in the normal female breast. *Cancer Research* **51** 1817–1822.
- Rohan TE, Hartwick W, Miller AB & Kandel RA 1998 Immunohistochemical detection of c-erbB-2 and p53 in benign breast disease and breast cancer risk. *Journal of the National Cancer Institute* **90** 1262–1269.
- Rosenberg CL, de las Morenas A, Huang K, Cupples A & Faller DV 1996 Detection of monoclonal microsatellite alterations in atypical breast hyperplasia. *Journal of Clinical Investigation* **98** 1095–1100.
- Rosenberg CL, Larson PS, Romo JD, De Las Morenas A & Faller DV 1997 Microsatellite alterations indicating monoclonality in atypical hyperplasias associated with breast cancer. *Human Pathology* **28** 214–219.
- Rudas M, Neumayer R, Gnatt M, Mittelbock M, Jakesz R & Reiner A 1997 p53 protein expression cell proliferation and steroid hormone receptors in ductal and lobular *in situ* carcinomas of the breast. *European Journal of Cancer* **33** 39–44.
- Rudland PS 1993 Epithelial stem cells and their possible role in the development of the normal and diseased breast. *Histology and Histopathology* **8** 385–404.
- Russo J & Russo IH 1997 Role of differentiation in the pathogenesis and prevention of breast cancer. *Endocrine-Related Cancer* **4** 7–21.
- Russo J, Calaf GRL & Russo IH 1987 Influence of age and gland topography on cell kinetics of normal breast tissue. *Journal of the National Cancer Institute* **78** 413–418.

- Russo J, Rivera R & Russo IH 1992 Influence of age and parity on the development of the human breast. *Breast Cancer Research Treatment* **23** 211–218.
- Russo J, Ao X, Grill C & Russo IH 1999 Pattern of distribution of cells positive for estrogen receptor alpha and progesterone receptor in relation to proliferating cells in the mammary gland. *Breast Cancer Research Treatment* **53** 217–227.
- Schimmelpenninck H, Eriksson ET, Pallis L, Skoog L, Cedermark B & Auer GU 1992 Immunohistochemical c-erbB-2 proto-oncogene expression and nuclear DNA content in human mammary carcinoma *in situ*. *American Journal of Clinical Pathology* **97** (Suppl.) S48–S52.
- Schmitt FC 1995 Multistep progression from an oestrogen-dependent growth towards an autonomous growth in breast carcinogenesis. *European Journal of Cancer* **31A** 2049–2052.
- Shekhar MPV, Nangia-Makker P, Wolman SR, Tait L, Heppner GH & Visscher DW 1998 Direct action of estrogen on sequence of progression of human preneoplastic breast disease. *American Journal of Pathology* **152** 1129–1132.
- Shocker BS, Jarvis C, Clarke RB, Anderson E, Hewlett J, Davies MPA, Sibson DR & Sloane JP 1999 Estrogen receptor-positive proliferating cells in the normal and precancerous breast. *American Journal of Pathology* **155** 1811–1815.
- Siziopikou KP, Prioleau JE, Harris JR & Schnitt SJ 1996 Bcl-2 expression in the spectrum of preinvasive breast lesions. *Cancer* **77** 499–506.
- Somerville JE, Clarke LA & Biggart JD 1992 c-erbB-2 overexpression and histological type of *in situ* and invasive breast carcinomas. *Journal of Clinical Pathology* **45** 16–20.
- Stark A, Hulka BS, Joens S, Novotny D, Thor AD, Wold LE, Schell MJ, Melton III LJ, Liu ET & Conway K 2000 HER-2/neu amplification in benign breast disease and the risk of subsequent breast cancer. *Journal of Clinical Oncology* **18** 267–274.
- Stratton MR, Collins N, Lakhani SR & Sloane JP 1995 Loss of heterozygosity in ductal carcinoma *in situ* of the breast. *Journal of Pathology* **175** 195–201.
- Tsuda H, Iwaya K, Fukutomi T & Hirohashi S 1993 P53 mutations and c-erbB-2 amplification in intraductal and invasive breast carcinomas of high histologic grade. *Japanese Journal of Cancer Research* **84** 394–401.
- Umekita Y, Takasaki T & Yoshida H 1994 Expression of p53 protein in benign epithelial hyperplasia, atypical ductal hyperplasia, non-invasive and invasive mammary carcinoma: an immunohistochemical study. *Virchows Archiv* **424** 491–494.
- van de Vijver MJ, Peterse JL, Mooi WJ, Wiseman P, Lomans J, Dalesio O & Nusse R 1988 neu-Protein overexpression in breast cancer: association with comedo-type ductal carcinoma *in situ* and limited prognostic value in stage II breast cancer. *New England Journal of Medicine* **319** 1239–1245.
- Venter DJ, Tuzi NL, Kumar S & Gullick WJ 1987 Overexpression of the c-erbB-2 oncoprotein in human breast carcinomas: immunohistological assessment correlates with gene amplification. *Lancet* **2** 69–72.
- Visscher DW, Gingrich DS, Buckley J, Tabaczka P & Crissman JD 1996 Cell cycle analysis of normal atrophic and hyperplastic breast epithelium using two-color multiparametric flow cytometry. *Analytical Cellular Pathology* **12** 115–124.
- Waldman FM, DeVries S, Chew KL, Moore DH, Kerlikowske K & Ljung B-M 2000 Chromosomal alterations in ductal carcinomas *in situ* and their *in situ* recurrences. *Journal of the National Cancer Institute* **92** 313–320.
- Walker RA, Dearing SJ, Lane DP & Varley JM 1991 Expression of p53 protein in infiltrating and *in situ* breast carcinomas. *Journal of Pathology* **165** 203–211.
- Wellings SR & Jensen HM 1973 On the origin and progression of ductal carcinoma in the human breast. *Journal of the National Cancer Institute* **50** 1111–1118.
- Wellings SR, Jensen HM & Marcum RG 1975 An atlas of subgross pathology of the human breast with special reference to possible precancerous lesions. *Journal of the National Cancer Institute* **55** 231–243.
- Younes M, Lebovitz RM, Bommer KE, Cagle PT, Morton D, Khan S & Laucirica R 1995 p53 accumulation in benign breast biopsy specimens. *Human Pathology* **26** 155–158.
- Zafrani B, Leroyer A, Fourquet A, Laurent M, Torphilm D, Validire P & Sastre-Garau A 1994 Mammographically detected ductal *in situ* carcinoma of the breast analyzed with a new classification. A study of 127 cases: correlation with estrogen and progesterone receptors, p53 and c-erbB-2 proteins and proliferative activity. *Seminars in Diagnostic Pathology* **11** 208–214.
- Zhuang Z, Merino MJ, Chuaqua R, Liotta LA & Emmert-Buck MR 1995 Identical allelic loss on chromosome 11q13 in microdissected *in situ* and invasive human breast cancer. *Cancer Research* **55** 467–471.