

History and evolution in total ankle arthroplasty

Nikolaos E. Gougoulias^{†‡}, Anil Khanna^{†‡}, and Nicola Maffulli[†]

[†]Department of Trauma and Orthopaedic Surgery, Keele University School of Medicine, Thornburrow Drive, Hartshill Stoke on Trent, Staffordshire ST4 7QB, UK, and [‡]Department of Orthopaedic Surgery, University Hospital North Staffordshire, Stoke on Trent ST4 7LN, UK

Introduction: The current study provides an overview of history and evolution in total ankle arthroplasty.

Methods: We conducted a comprehensive literature search without limitations to language. Information from any source, providing evidence of the use ankle of prostheses (e.g. biomechanical testing, cadaveric implantations or clinical use) was evaluated. Data regarding biomechanical concepts, design considerations, published results (patient numbers, surgical method, follow-up, complications and survival rates) were collected.

Results: Only level IV studies were found. Mobile-bearing prostheses are mainly used in Europe, and fixed-bearing implants are mainly used in the USA. The current designs' failure rate is 10–12% at ~5 years. Survival rates vary among different institutions. Increased surgeons' experience is associated with better outcomes.

Discussion: Biomechanical studies and review of previous implant failures has led to the development of a new generation of implants.

Conclusions: Results show that ankle arthroplasty is a viable alternative for the management of ankle arthritis in selected patients.

Keywords: ankle/arthroplasty/replacement/arthritis/joint replacement

Introduction

Accepted: October 15,
2008

Correspondence to Prof.
Nicola Maffulli
Department of Trauma
and Orthopaedic Surgery,
Keele University School
of Medicine,
Thornburrow Drive,
Hartshill, Stoke on Trent,
Staffordshire ST4 7QB, UK
E-mail: osa14@keele.ac.uk

Primary osteoarthritis is less common in the ankle, compared with the knee and hip joints, but arthritis secondary to trauma occurs frequently.¹ Non-operative management includes analgesics and anti-inflammatory medication, activities modification, physiotherapy, orthotics (bracing) and intra-articular injections.¹ Surgical management of end-stage arthritis of the ankle joint has traditionally been by arthrodesis, which is considered the 'gold standard'.^{1,2} Minimally invasive, possibly arthroscopically assisted, ankle fusion has recently gained

popularity.¹⁻³ Ankle replacement is an alternative to arthrodesis in selected patients (Fig. 1).^{1,2} The advantage of replacing the ankle using a prosthesis is preservation of movement and function. This may also result in improvements in gait including reduction of limp, and protection of other joints.⁴⁻⁸ The major complications associated with failure of ankle arthroplasty are infections and loosening of the components. Absolute contraindications for ankle arthroplasty include acute and chronic foot infections, an insensate foot, Charcot's arthropathy, avascular necrosis of the talus, inadequate leg foot musculature, paralysis and severe tibiotalar malposition and lower limb deformities.² Relative contraindications include younger age, heavy physical work, high body mass index, diabetes and smoking. In the presence of ipsilateral knee osteoarthritis requiring surgery, a knee replacement should be considered before an ankle arthroplasty, to restore the limb's mechanical axis.² The ideal candidate for total ankle arthroplasty (TAA) is a reasonably mobile middle-to-old-aged patient, with normal or low body mass index, good bone stock and minimal deformities, with multiple joint arthritis (e.g. rheumatoid arthritis), without neurovascular impairment of the lower leg. Ankle arthrodesis, on the other hand, can be, more safely, performed in cases with deformity, paralysis, neuropathy and talus avascular necrosis in patients of any age and body type.^{1,9} The presence of infection, poor soft tissue envelope, co-existing medical problems and smoking carry, however, a higher risk for non-union.⁹

During the past 30 years, initial attempts at TAA largely failed. The stimulus for TAA derives from partial dissatisfaction with ankle

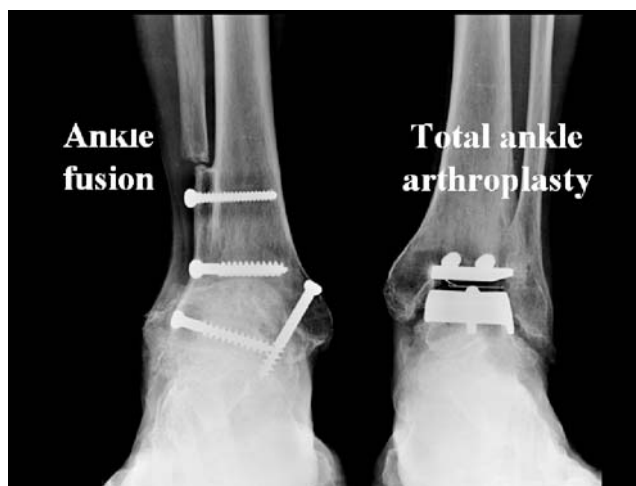

Fig. 1 Right ankle arthrodesis and left ankle arthroplasty performed sequentially in a patient with bilateral ankle osteoarthritis.

arthrodesis^{10–13} and the success of total hip and knee arthroplasties.¹⁴ Ankle arthrodesis has often been associated with high complication and reoperation rates, with overloading of the adjacent joints,¹⁵ frequently already arthritic,¹⁶ leading to further degeneration in the long term.¹¹ Furthermore, loss of ankle joint motion leads to abnormal gait patterns and causes restriction on patients' activities.¹⁷ A successful ankle replacement, on the other hand, provides a near-normal gait pattern in terms of kinematics of the knee, ankle and tarsal joints.⁴ A gait analysis study⁵ comparing ankle replacement and arthrodesis showed that the ankle replacement group had greater movement at the ankle, symmetrical timing of gait and restored ground reaction force pattern, although gait was slower. An isolated ankle fusion in the younger patient may thus progress into a pantalar fusion with its increased limitations and morbidity, whereas maintenance of high level of activities is a constant demand of modern lifestyle, even after disabling trauma and idiopathic joint degeneration.¹

The frequent failure of ankle implants may be related to surgeons' and designers' inability to restore adequately the critical stabilizing role of the ligaments, to poor reproduction of the normal mechanics of the ankle joint and to the lack of involvement of the underlying subtalar joint in the coupled pattern of motion of the entire ankle complex.^{12,15,18} Although the ankle is a challenging joint to be replaced, there is clearly space for the development of improved implants and techniques. A systematic review of intermediate and long-term outcomes for total ankle replacement found excellent or good results in 82% of patients who received a newer generation ankle device compared with 72% if undergoing ankle fusion.¹⁰ In terms of design, moving from the original tibial polyethylene components (Fig. 2), most of the recent two-component designs include a metal-backed tibial component (Fig. 3A). Three-component designs are based on the 'mobile bearing' concept (Figs 3B and 4).^{12,19–21} A meta-analysis on new generation mobile-bearing implants showed that the weighed 5 year prosthesis survival rate was 90.6%.²² Ankle replacement systems now include various materials and shapes of fixation elements. Pegs, long or short stems and cylindrical or rectangular bars have been used. Replacement of medial and lateral gutters varies between different designs. Furthermore, cemented and cementless (bone ingrowth dependent) implant fixation has been used.

The current study provides an overview of history and evolution in TAA. It describes ankle prosthesis designs and biomechanical concepts. It briefly reviews the results of early designs, and focuses on identifying elements of evolution in total ankle prostheses, describing prostheses in use today, their individual characteristics and clinical outcomes.

'Old generation' implants

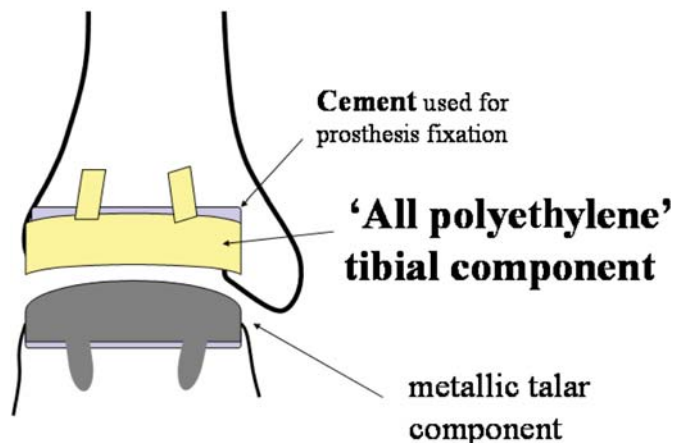


Fig. 2 'Old generation' ankle replacements consisted of a polyethylene tibial component and a metallic talar component. Cement was used for implant stabilization.

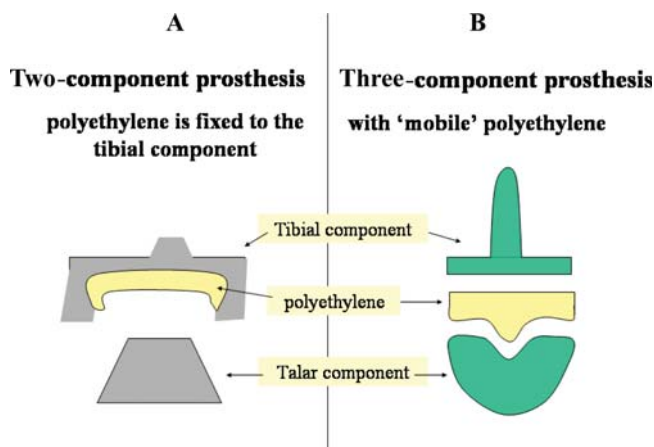


Fig. 3 Modern ankle replacement consists of metallic tibial and talar components, stabilized with or without cement. A 'meniscus-like' polyethylene component is either fixed to the tibial component (A) or is mobile articulating with both components (B).

Methods

We conducted a comprehensive literature search of Medline, Cochrane, Embase and CINAHL databases. All articles relevant to the subject, published from 1 January 1966 to 1 May 2008, were retrieved, and their bibliographies searched for further references. No language restrictions were applied to the search, including non-peer-reviewed journals, to make any possible information on ankle arthroplasty available. In addition, an internet search was carried out using the Google

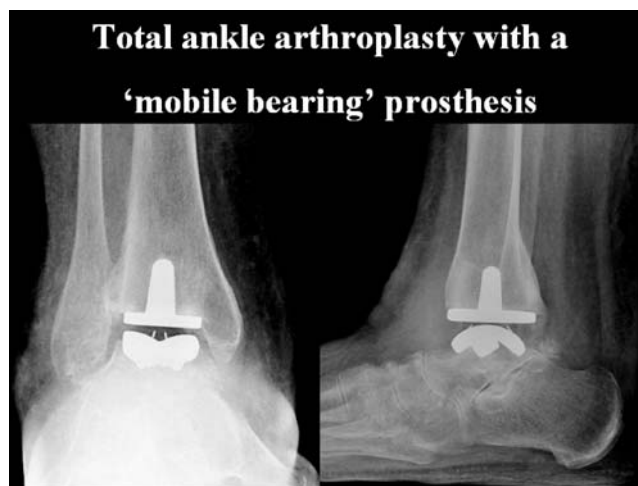


Fig. 4 Radiographic appearance of a 'mobile-bearing' ankle replacement.

search engine, and the electronic contents of several key journals were searched. The Journal of Bone and Joint Surgery (American and British Volumes), Foot and Ankle International, Foot Ankle Clinics of North America, Journal of Foot and Ankle Surgery, Foot Ankle Surgery, The Foot, Techniques in Foot Ankle Surgery, Fuss Sprunggelenk (German), Orthopade (German), the Lippincott Williams and Wilkins journal database and the ScienceDirect database were searched directly. Furthermore, abstracts of presentations at the American Academy of Orthopaedic Surgeons (AAOS), the American Orthopaedic Foot and Ankle Society (AOFAS) and the British Orthopaedic Foot Ankle Society (BOFAS) meetings, from 2005 onwards, were retrieved to increase the availability of information of prostheses in use. Databases search was performed using the keywords: 'ankle and arthroplasty'. Search of the German journals databases was also performed using keywords: 'OSG; Oberes Sprunggelenk; Sprunggelenkprothese'. Further search of the Google search engine was performed using the commercial names of specific implants (e.g. Agility, TNK, LCS, BP, Buechel-Pappas, STAR, ESKA, RAMSES, SALTO, HINTEGRA, Alphanorm, AES, Mobility, BOX, Zenith) and key authors names (e.g. Alvine FG, Buechel FF, Pappas MJ, Kofoed H, Bonnin M, Hintermann B, Wood PLR, Rippstein P, Rudigier J, Giannini S, Tillmann K, Asencio J). The Food and Drug Administration (FDA) website was searched for any information available regarding implants receiving clearance for use in the USA, or undergoing clinical trial. Information from any source, providing evidence of the existence of a prosthesis and the status of its use (e.g. biomechanical testing, cadaveric implantations or clinical use), was evaluated and presented in the 'Results' section.

Studies presenting results of ankle arthroplasty implants presently in use underwent further evaluation. Avoiding double counting of ankle replacements (several studies reporting results from the same institution at different time intervals and with different numbers of prostheses recruitment), we evaluated studies with the latest reports available. Two investigators (N.G. and A.K.) extracted the year of publication, type of study (randomized control trial, prospective trial or retrospective case series), the approach used, the total number of patients and ankles, follow-up, the outcome measures used, the complication and reoperation rate, patients' satisfaction, the survival rate of prostheses with revision or ankle fusion as an endpoint. For the most widely used prostheses with sufficient follow-up (>2 years on average), we produced tables summarizing results. Failures and survival of the prosthesis (considering revision of at least one of the components or arthrodesis as an endpoint) were evaluated.

The 'Results' section is divided in two parts: Part 1 reports the 'historical designs' (i.e. prostheses whose use has not been documented since 1998 or whose abandonment has been documented). Part 2 focuses on the ankle prostheses presently in use. When summarizing the results of different studies for each implant, failures and survival of prostheses were calculated only for studies providing follow-up data. Further calculations were made regarding patients' age, preoperative diagnosis (post-traumatic osteoarthritis, idiopathic osteoarthritis, inflammatory arthritis, other causes of arthritis), wound problems, deep infections, intraoperative fractures, other complications, for the studies providing relevant data. Mean values were weighted depending on the sample size for each study.

Results

Part 1: historical designs

The first TAA was performed in 1970 by Lord and Marrotte.²³ A long-stem tibial component (similar to a femoral prosthesis) coupled with a polyethylene talar component that replaced the body of the talus was used, combined with subtalar fusion. After 10 years, 12 of the 25 arthroplasties had failed; only 7 results could be considered satisfactory. The use of the prosthesis was abandoned.²⁴ It was realized that an ankle prosthesis should not simply be a hinge (flexion–extension) device due to the amount of rotation required at the ankle.²³

The St. Georg prosthesis (semiconstrained), implanted through a lateral approach, was used in Sweden in 1973, but was abandoned after eight ankle replacements.^{25,26} Other authors²⁷ followed 15

St. Georg ankle replacements for a mean of 10 years. Eleven early and 32 late complications were identified.

The Imperial College of London Hospital (ICLH) implant (two-component, constrained design, cemented, polyethylene tibial implant) was designed to prevent medial and lateral subluxation of the talar component by elevation of the medial and lateral walls of the tibial component.²⁸⁻³⁰ Pain when walking was common. Only 11 of 62 ankle replacements yielded satisfactory results and a 47% survival rate at 5.5 years follow-up was reported by the designers of the prosthesis who used it from 1972 to 1981.³¹ The major complications included wound healing problems, talar collapse and loosening of the components. On basis of on their experience, Bolton-Maggs *et al.*³¹ stated that 'it is a matter of time before all prosthesis fail and require arthrodesis'.

The Irvine total ankle (non-constrained) implant (Howmedica, Rutherford, NJ, USA) was used in California, USA, in the 1970s.³² The Irvine ankle arthroplasty was one of the few early designs that attempted to recreate closely the anatomy of the talus. The designers took anatomical measurements of 32 tali to establish the shape of the talus to try and reproduce this in their implant.³² It was initially thought that it would allow motion in the sagittal and coronal planes and allow axial rotation. However, it was realized later that rotation of the components placed increasing stress on the surrounding ligaments.³³ Early results (9 month follow-up) documented two failures after 28 implants were inserted. Wound healing problems and malalignment were frequent problems.³³ No further report regarding this prosthesis ever followed.

A constrained implant, the CONAXIAL Beck-Steffe prosthesis, showed 60% loosening at 5 years and up to 90% loosening at 10 years.³⁴

The Mayo Total Ankle Replacement was designed as a constrained design by Dr Stauffer in the 1970s. It was a highly congruent two-component (polyethylene tibia implant) fixed with cement. Intermediate results were encouraging.³⁵ A more recent study³⁶ reviewed 204 ankle replacements in 179 patients at the Mayo Clinic from 1974 to 1988. Only 19% of the patients were considered to have a good result, while 36% were considered as failures and required implant removal. The results were worse in younger patients. There was radiographic evidence of loosening of 8 tibial components and 57 talar components. Complications occurred after 19 arthroplasties, and 94 additional reoperations were necessary. The overall cumulative rate of survival at 5, 10 and 15 years was 79, 65 and 61%, respectively.^{36,37} On the basis of these findings, the authors recommended against the use of constrained implants.

A different (incongruous surface) two-component (polyethylene tibial component) cemented total ankle prosthesis was designed and implanted in 50 patients (Newton Ankle Implant, Howmedica, Rutherford, NJ, USA). The tibial component was a portion of a cylinder and the talar component was a portion of a sphere with a slightly smaller radius. Incongruity resulted in high polyethylene wear. High rates (75%) of aseptic loosening were observed, although this was not directly related to patients' symptoms. At an average of 3 years, 38% of 34 prostheses implanted in patients with primary osteoarthritis were left *in situ*. Based on these results, the author concluded that preoperative malalignment, previous sepsis, talus avascular necrosis, prednisolone therapy in rheumatoid patients and failed ankle fusion are contraindications for ankle arthroplasty.³⁸

Non-constrained designs by incongruent articular surfaces [Richard Smith ankle arthroplasty (Dow Corning, Arlington, TN, USA)] showed only slightly better results, with loosening rates of 14% and 29% after 2²⁷ and 7 years,³⁹ respectively. Results regarding this prosthesis have not been reported after 1994.

The Bath-Wessex total ankle implant was a two-component (polyethylene tibia implant) non-constrained design fixed with cement. Its use has been documented in 72 ankle replacement surgeries from 1984 to 1996.⁴⁰ The clinical survival had decreased from 83% at 5 years to 66% at 10 years. Radiographical survival (no radiolucency) of the tibial component had decreased from 68% to 53%, whereas the relevant values for the talar component were 43% and 18%. This implant has been abandoned.

The Thompson–Richard prosthesis (TPR), a two-component semi-constrained cemented implant, was introduced in 1976. The polyethylene tibial component had a concave articular surface with a lip on each side to restrict side-to-side movement of the talar component. This allowed only plantar- and dorsiflexion. Shear forces could only be transmitted to the bone cement interface. As a result, radiographic evaluation showed a high rate of radiolucency (52%) in 30 cemented TPR prostheses, with a low (69%) satisfaction rate at 5 year follow-up, although only two implants were removed at this stage.⁴¹ Similar results were reported by other authors at a longer follow-up. Although survival rate for this prosthesis was high (87% at 12 years) in 27 ankles, a high rate of radiolucency for the tibial component (53%), combined with patients' dissatisfaction and painful prostheses was reported.⁴² Another study⁴³ reported that two of six implants were converted to arthrodesis after a mean of 7.2 years, whereas the functional score in the remaining ankles was low (Kofoed score of 52). The Norwegian Joint Registry⁴⁴ reported a 19% revision rate at 7.7 year

follow-up in 32 ankle arthroplasties implanted from 1994 to 1997. The use of this prosthesis has not been documented after 1997.

The 'New Jersey' and low contact stress (LCS) TAA was developed by Frederick Buechel, an Orthopaedic Surgeon, and Michael Pappas, a Bioengineer. The 'New Jersey' or 'Cylindrical' TAA was first implanted in 1974. It consisted of a cylindrical surface ultrahigh molecular weight polyethylene (UHMWPE) talar component and a mortized cobalt–chromium alloy tibial component both stabilized with cement and dual fixation fins.³³ The fate of this design was similar to other implants of its era. Although the clinical results were disappointing, due to its lack of axial rotation and degree of restraint, it did incorporate some important design features that have become almost standard in current replacements. The addition of a polyethylene 'meniscus' in 1978 led to the evolution to the LCS prosthesis, first implanted in 1981.^{45,46} The LCS [later evolved as the 'Buechel–Pappas' (BP)] was the first three-component total ankle implant, introducing the 'mobile-bearing' joint replacement concept in ankle arthroplasty (Fig. 3B). The 'mobile-bearing concept' was first applied in knee arthroplasty in the 1970s, by Prof. John O'Connor, a bio-engineer, and Mr John Goodfellow, an Orthopaedic Surgeon, in Oxford.²⁰ A mobile polyethylene implant sliding on a metallic tibial platform was used to replace one or both compartments of the knee, preferably in the presence of intact cruciate ligaments. Their work influenced Buechel and Pappas in the USA, who developed the New Jersey Knee Replacement System, later named LCS knee system,²¹ still in use today. The 'mobile-bearing' implants allow congruity of the 'articulating' surfaces, to overcome the high contact stresses that cause increased polyethylene wear and to eliminate constrained forces that cause mechanical loosening of the prosthesis components.²¹

Part 2: designs presently in use

The new generation implants presently in use can be classified (a) as two- or three-component designs and (b) as fixed or mobile-bearing designs (Tables 1–3). With the exception of the TNK ceramic/metallic ankle arthroplasty (Table 2), all other implants include a UHMWPE component. In the Agility, INBONE, Eclipse, SALTO Talaris and ESKA ankle implants, this is fixed to the tibial component (Table 1). Thus, these prostheses, although consisting of three pieces (tibial, talar and polyethylene), act as two-component implants. The polyethylene is fixed within the tibial component upon insertion of the prosthesis into the ankle and has no independent movement (fixed-bearing). Hence, the distinctions between three-piece versus two-piece and fixed

Table 1 Fixed-bearing, two-component ankle arthroplasty implants.

Prosthesis	Designer(s)/origin	Use	Since	Constrained	Materials	Cement fixation	Individual properties
Agility ^{51,52}	Alvine (Iowa, USA)	USA/New Zealand/Switzerland	1984	Semi-	Ti tibia and talus (first 20); Ti tibia, CoCr talus	Yes/No	Fusion of distal tibiofibular syndesmosis Talus 'slides' from side to side
INBONE ⁶¹	Riley (USA)	USA/New Zealand	1989 2005	Semi- Non-	Ti tibia, CoCr talus Ti tibia, CoCr talus	No No	Most widely marketed in USA Long tibial stem; convex talus with long stem
Eclipse ⁴⁸	USA	USA	2007	Non-	CoCr (tibia and talus)/ Ti plasma spray coating	Yes	
SALTO Talaris ⁶²	Bonnin (Lyon, France)	USA	2006	Non-	CoCr with dual Ti-HA coating	No	Variant of the three-component design used in Europe
ESKA ⁶⁴⁻⁶⁶	Rudigier (Offenburg, Germany)	Germany	1990	Non-		No	Lateral approach/fibula osteotomy

Table 2 The TNK prosthesis (three generations).

Prosthesis	Designer(s)/origin	Use	Since	Constrained	Materials	Cement fixation	Individual properties
TNK ^{67,68}	Takakura (Kashihara, Japan)	Japan	1975	Non-	316 stainless steel tibia, PE talus	Yes	
			1980		Alumina ceramic talus	Yes/no	Ceramic talar component
			1991		Alumina ceramic HA coated talus	Yes/no	Flat PE with medial recess fixed to tibia

versus mobile-bearing implants is important for two reasons. This distinction is important for two reasons. First, the US FDA classifies them as two-piece implants. Second, they function quite differently in absorbing the rotational forces within the ankle during motion than do implants with mobile bearings.^{12,13,18,19,47-49} In the USA, given FDA restrictions, mainly two-component designs are in use.⁵⁰ All other prostheses have adopted the mobile bearing three-component concept (Table 3). The Salto prosthesis, originally used as a three-component mobile-bearing implant, has developed a fixed-bearing design for use in the USA, due to FDA restrictions. Differences between mobile-bearing designs include the type of fixation (pegs, fins, screws), the shape and conformity of the talar component and the replacement of the talar facets.^{18,47}

Two-component designs

The Agility total ankle replacement (DePuy, Warsaw, IN, USA)

It is designed to absorb rotational forces by allowing a space between the medial and lateral sides of the talar component resting against the bearing (Fig. 5, Table 1). The talar component, which slides from side to side, is slightly wider anteriorly than posteriorly, which theoretically makes it more stable in dorsiflexion than in plantar flexion. Operative technique includes application of a transarticular external fixator during the procedure. Fusion of the distal tibiofibular syndesmosis is desired to stabilize the tibial component. In the USA, at the present time, the Agility implant (DePuy) is the most widely marketed and used ankle prosthesis. The implant is classified by the FDA as a class II prosthesis, and was the only FDA-approved ankle implant in the USA until 2007.⁵⁰

The developers of the prosthesis published their results (Table 4) in 1998⁵¹ and in 2004.⁵² A delay in syndesmosis union predicted the appearance of tibial lysis and was associated with higher disability scores.⁵² The same authors published a review article in the German literature.⁵³ The failure rate (revision or arthrodesis) was 6.6% in 686 cases from 1995 to 2004, compared with 11% in 132 TARs from

Table 3 Mobile-bearing, three-component ankle arthroplasty implants.

Prosthesis	Designer(s)/Origin	Use	Since	Constrained	Materials	Cement fixation	Individual properties
STAR ^{47,77}	Kofoed (Denmark)	Europe Europe Europe/New Zealand/ USA	1981 1984 1990	Non- Non- Non-	CoCr with HA coating (double since 1999)	Yes Yes No	Talar facets covered by implant
LCS ^{46,72}	Buechel–Pappas (New Jersey, USA)	USA	1981	Non-	CoCrMo, porous coated	No	Tibial stem, 7° anterior inclination Talus: one fixation fin
Buechel–Pappas (BP) ^{49,72}		USA, Europe	1989	Non-	Ti alloy (tibia, talus) TiN (Ultracoat [®]): ceramic coating BioCoat [®] : 3 layers porous coating	No	Tibial stem 7° anterior inclination Talus: Deep sulcus– more stable, dual fin fixation Increased thickness tibia platform Ultracoat [®] : to reduce wear BioCoat [®]) for bone ingrowth Allows inversion, eversion Tibial central fin with hollow end Talar facets covered Talo-fibular facet replacement Talus: Smaller medial radius Allows inversion, eversion Medial, lateral tibial edges Spheroid upper talar surface (multiple axes rotation) Fixation: four large and four small pegs (tibia and talus)
SALTO ⁶³	Bonnin (Lyon, France)	France	1997	Non-	CoCr with dual Ti-HA coating	No	Tibial central fin with hollow end Talar facets covered Talo-fibular facet replacement Talus: Smaller medial radius Allows inversion, eversion Medial, lateral tibial edges Spheroid upper talar surface (multiple axes rotation) Fixation: four large and four small pegs (tibia and talus)
Ramses ^{97,98}	Mendolia et al. (France)	France	1989	Non-	CoCr, Smooth surface	Yes	Medial, lateral tibial edges Spheroid upper talar surface (multiple axes rotation) Fixation: four large and four small pegs (tibia and talus)
Ramses ^{97,98}		France/New Zealand	2000	Non-	CoCr, with HA coating	No	

HINTEGRA ⁹⁹	Hintermann (Basel, Switzerland)	Switzerland/ Scandinavia/Canada/ South America	2000	Non-	CoCr with dual Ti-HA coating	No	Screw fixation Talar facets covered Talus: Smaller medial radius No inversion–eversion
AES ^{47,107}	Asencio (Nimes, France)	Europe	1999	Non-	CoCr with HA coating	No	(BP-type prosthesis) Tibial stem anteriorly bowed, modular Talar facets covered
Mobility ⁴⁷	Rippstein (Zurich, Switzerland), Wood (Writhington, UK), Coetzee (Minnesota, USA)	Europe/New Zealand/ USA	2002	Non-		No	(BP-type prosthesis) Tibial stem
Alphanorm ^{48,117}	Tillman (Bad Bramsted, Germany)	Germany	1996	Non-	CoCr, Ti coating	No	(BP-type prosthesis) Tibial stem 90°/no inclination
BOX ^{111–113}	Rizzoli Institute (Bologna, Italy), O'Connor (Oxford, UK)	Italy	2003	Non-	Not reported	No	Normal ankle kinematics Upper PE surface concave/ not flat
German Ankle System ¹¹⁵	Richter (Coburg, Germany)	Germany	2007	Non-	CrMo, ceramic coating, BONIT [®]	No	Upper PE surface concave/ not flat CAS technology
Zenith ¹¹⁶	Winson (Bristol, UK), Frank (Leverkusen, Germany)	UK		Non-	Ti, BONIT [®] coating Deep sulcus talar implant with two pegs	No	(BP-type prosthesis) Tibial stem
TARIC ¹¹⁸	Schill, Rehart, Fink (Germany)	Germany	2006	Non-	Tibia and talus: Ti coating; HA coating optional	No	Two fixation pegs tibia and talus Optional talar facets coverage
CCI ¹¹⁹	Doets (Netherlands)	Netherlands	2003	Non-	Cobalt Chromium alloy; Ti nitride coating	No	Two talar pegs One small tibial peg

Agility: a fixed-bearing (two-component) ankle prosthesis

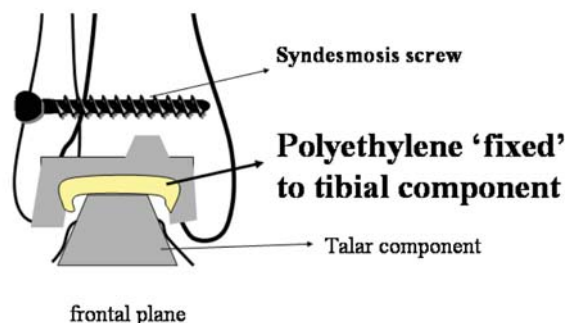


Fig. 5 The Agility prosthesis, a two-component design, requires tibio-fibular fixation.

1984 to 1994.⁵² Regarding the latter 686 cases, however, no follow-up or survivorship analysis data were provided.⁵³ These results have not been reproduced by other surgeons.^{54–56} Kopp *et al.*⁵⁶ focused on clinical outcome, complications and radiographic signs of loosening. The AOFAS score improved from 33.6 preoperatively to 83.3 post-operatively. SF-36 assessment score was 49.5, close to mean of the US general population. Early radiolucencies and subsidence did not affect intermediate clinical results. The prosthesis has been used outside the USA as well. The New Zealand Joint Arthroplasty Register data were published in 2007.⁵⁷ The only study from Europe (Switzerland) was published in the German literature.⁵⁸

The most recent report⁵⁹ (presentation at the 2007 AAOS Annual Meeting) is a prospective cohort study reporting a 24% complication rate in 113 prostheses (with 19 patients lost to follow-up) followed more than 3 years. In 67 patients with complete data, the average AOFAS score improved from 44 preoperatively to 77 at 6 months and 79 at 3 years. The average total MFA (Musculoskeletal Functional Assessment Injury and Arthritis Survey) score decreased (improved) from 38 to 18. Visual analogue pain scores decreased from 8 to 2. Ankle range of motion improved on average by 5°, and 95% of patients were satisfied. Syndesmosis non-union occurred in 7 of 94 cases (7.4%), whereas six failures (four fusions and two revisions) were reported in the 94 patients available for follow-up, leaving a survivorship rate of 94.7% (favourable scenario) to 93.6% (unfavourable scenario) for 113 ankles with more than 3 years follow-up.⁵⁹

Overall, five studies^{52,54–56,60} reported on wound complications (32 in 503 ankle replacements, 5.1%) and deep infections (8 in 503 ankle replacements, 1.6%). Intraoperative malleolar fractures reported in two

Table 4 Agility ankle replacement: results.

Author	Year	Study type	From	To	Age	F-up	F-up range	Ankles	Failure rate	Survivorship analysis	Syndesmosis nonunion	Comments/other
Knecht <i>et al.</i> ⁵²	2004	Prospective cohort	1983	1994	61	9	7–16	132	10.6%	63% at 10 yrs	8%	Designer 76% Radiolucency, 14% subsidence
Hurowitz <i>et al.</i> ⁵⁴	2007	Retrospective cohort	1998	2002	54.5	3.3	2–5.9	65	32.3%	67% at 6 yrs		
Spirt <i>et al.</i> ⁵⁵	2004	Retrospective cohort	1995	2001	53.5	2.8	0.3–6.3	306	10.8%	80% at 5 yrs		42% reoperation rate
Kopp <i>et al.</i> ⁵⁶	2006	Retrospective cohort	1998	2002	63	3.7	2.2–5.3	43	5.0%	–	7.5%	85% Radiolucency, 45% subsidence
Schubert <i>et al.</i> ⁶⁰	2006	Retrospective cohort			57.6	2	0.5–4.2	50	16.0%	–	12%	
Vienne <i>et al.</i> ⁵⁸	2004	Prospective cohort	1999	2003	58	2.4	1.5–3.7	36	2.8%	–		
Hosman <i>et al.</i> ⁵⁷	2007	NJR	2000	2005		2.8	0.6–6.3	117	7.7%	–		New Zealand NJR
Mean or total					56.4	3.9		749	11.7%			

F-up, follow-up; NJR, National Joint Register; yrs, years (age and follow-up in years).

studies,^{54,60} occurred in 15 of 93 ankles (16.1%). Two studies^{52,55} reported on reoperations performed in 135 of 429 cases (31.5%).

The INBONE™ ankle (INBONE Technologies Inc, Boulder, CO, USA)

This is the only TAA with an intramedullary alignment system design (Table 1). Over 200 INBONE™ ankle replacements have been performed in the USA.⁶¹ No results are available.

The eclipse total ankle implant (Kinetikos Medical Inc., CA, USA)

In 2007, the FDA⁵⁰ cleared the Eclipse ankle, a fixed tibia/meniscus polyethylene insert and a talar insert designed for cemented fixation (Table 1). No results are available.

The SALTO Talaris™ anatomic ankle (Tornier)

It is used in the USA since December 2006.⁶² No results are available. It is a variant of the SALTO™ ankle replacement, a three-component mobile-bearing design (Table 3), used in Europe since 1997 (Fig. 6).⁶³

The ESKA ankle prosthesis (ESKA, Lubeck, Germany)

It is a two-component implant designed for cementless implantation (Fig. 7, Table 1). It has a shallow groove on the talar component that is congruous to the UHMWPE bearing attached to the tibial component and is able to control rotational forces. The inventor of the prosthesis prospectively followed his patients and published his results in 2001⁶⁴ and longer term results in 2004⁶⁵ and 2005⁶⁶ (Table 5). Improved ankle range of motion, reduction in pain and ability to walk

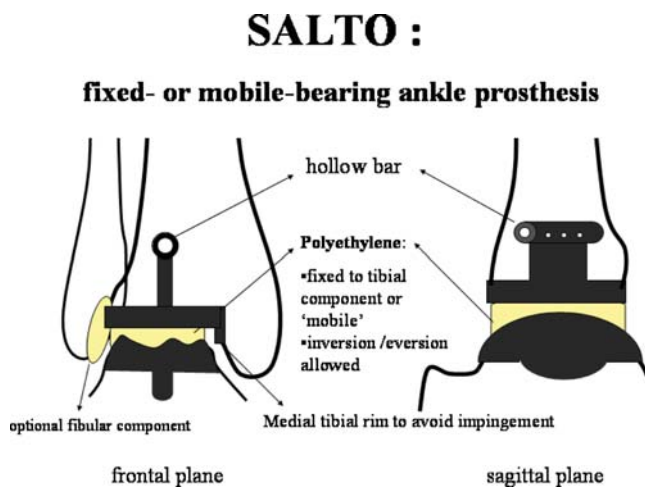


Fig. 6 The SALTO ankle prosthesis ‘fixed-bearing’ version is used in the USA, whereas the original ‘mobile-bearing’ design is used in Europe.

ESKA :

fixed-bearing (two-component) ankle prosthesis

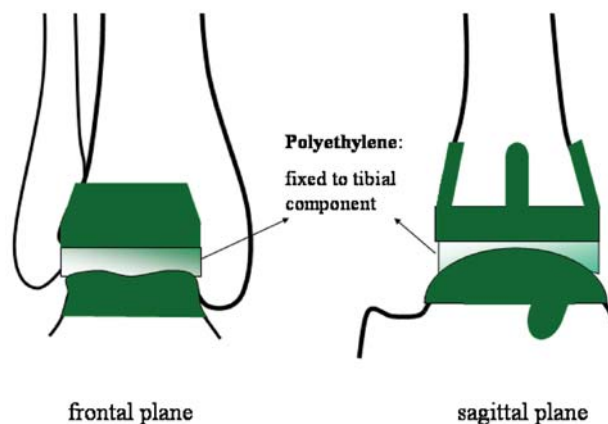


Fig. 7 The ESKA prosthesis consists of two components.

long distances postoperatively have been reported. The postoperative Kofoed score did not deteriorate over time. Of 12 TARs performed 10–15 years before, 8 (67%) remained *in situ* (two early deep infections, two aseptic loosening). In 20 implants inserted 5–10 years before, 3 were revised, leaving 17 (85%) *in situ* functioning well. None of the implants with a follow-up 1–5 years failed.⁶⁶ No results from independent authors have been published.

The TNK prosthesis (Dr Yoshino Takakura, Nara, Japan)

The TNK has been developed by Dr Takakura in Japan since 1975 (early version).^{67,68} Modifications included mainly improvements in biomaterials (Table 2). Dr Takakura and his colleagues prospectively followed their patients, and published their experience with the TNK prosthesis in English⁶⁸ and German.⁶⁹ Their first- and second generation implants were associated with loosening and subsidence in most patients. Results have improved with the third (current) generation implant (Table 6). They generally recommend cement fixation of the talar component in rheumatoid arthritis, since talar component loosening was very common in most rheumatoid ankles with prostheses fixed without cement. Patients satisfaction rate was higher in osteoarthritis compared with rheumatoid arthritis.^{68,69} Poor clinical and radiographic outcomes were reported in two studies with the TNK used in rheumatoid patients in Japan.^{70,71} On 123 ankle replacements,^{69–71} 76 (62%) were performed in rheumatoid patients, wound complications occurred in 4.9% and deep infection in 1.6%. Intraoperative fractures were reported in 5 of the 102 ankles (4.9%) in two studies.^{69,70}

Table 5 Ankle arthroplasty results for the ESKA, Ramses, Salto, HINTEGRA, AES, Mobility™, BOX prostheses.

Author	Year	Publication	Study type	Prosthesis	From	To	F-up	Ankles	Failure rate	Comments/Other
Rudigier <i>et al.</i> ⁶⁶	2005	TFAS	Prospective cohort	ESKA	1990	2004	Most 1–5	137	5.8%	Designer: no mean f-up reported
Mendolia <i>et al.</i> ⁹⁸	2005	TFAS	Retrospective cohort	Ramses	1989	1993	10–14	73	16.4%	Designer: Radiolucency in 61%; cemented version
Hosman <i>et al.</i> ⁵⁷	2007	Acta Orthop	NJR	Ramses	2000	2005	1.5	11	2	Cementless version
Bonnin <i>et al.</i> ⁶³	2004	CORR	Prospective cohort	SALTO	1997	2000	2.9	98	2.2%	Designer: Two lost to f-up
Hintermann <i>et al.</i> ^{99*}	2004	CORR	Prospective cohort	HINTEGRA	2000	2002	1.7	127	18.8	Designer; high early failure rate 115 reoperations; failure rate decreased after 2003
Hintermann <i>et al.</i> ^{101*}	2006	Orthopaede	"		2000	2004	3	278	14.4	
Fevang <i>et al.</i> ⁴⁴	2007	Acta Orthop	NJR		2004			6	0	
Henricson <i>et al.</i> ⁸⁰	2007	Acta Orthop	NJR		2002	2006		29	14.4%	
Henricson <i>et al.</i> ⁸⁰	2007	Acta Orthop	NJR	AES	2002	2006		69	12%	
Fevang <i>et al.</i> ⁴⁴	2007	Acta Orthop	NJR		2004			3	0	
Patsalis ¹⁰⁶	2004	FussSprung	Prospective cohort		2002	2004	0.7	15	0	
Strudee <i>et al.</i> ¹⁰⁷	2006	Abstract (meeting)	Prospective cohort		2002	2006	18	137	0	Incl. deformed ankles; 14% reoperations
Hosman <i>et al.</i> ⁵⁷	2007	Acta Orthop	NJR	Mobility	2000		0.7	29	0	
Henricson <i>et al.</i> ⁸⁰	2007	Acta Orthop	NJR					23		
Huber and Rippstein ¹⁰⁸	2006	Abstract (meeting)	Prospective cohort				>1	42	2.4%	Designer: 41/42 satisfied
Catani <i>et al.</i> ¹¹⁴	2008	Poster (meeting)	Prospective cohort	BOX	2003	2007	3	75	0	Designer: Good clinical results; no radiolucencies

F-up, follow-up; NJR, National Joint Register; Age & follow-up counted in years.

*Same case series.

Table 6 TNK prosthesis results.

Author	Year	Study type	From	To	Age	F-up	Ankles	Failure rate	Radiographic loosening	Comments/other
Tanaka and Takakura ⁶⁹	2006	Prospective cohort	1975	1984			30	23%	All ankles <i>in situ</i> loose	Designer: first generation
			1984	1990			60	8.3%	77%	Second generation: 50% loose at 5 years
			1991	2000	58	5.2	70	4.3%	33%	Cemented in 22/62 High radiolucency rate
Nishikawa <i>et al.</i> ⁷⁰	2004	Retrospective cohort	1984	2000		6	32	23%	75%	Rheumatoid Cemented Many lost to f-up Poor AOFAS in 12/21
Nagashima <i>et al.</i> ⁷¹	2004	Retrospective cohort	1998	2002		2.8	21	–	52%	Rheumatoid Do not provide failure rate

F-up: follow-up; age and follow-up in years.

Three-component designs

The BP total ankle replacement [Endotec, Orange, NJ (USA) and Wright-Cremascoli Orthopedics (a division of Wright Medical Technologies, Europe)]

In 1989, the LCS prosthesis was modified to the BP prosthesis (Fig. 8).⁴⁹ Its upper surface is flat, whereas its lower surface conforms to the trochlear surface, thereby providing unconstrained, sliding cylindrical motion with LCS on the bearing surfaces, allowing inversion, eversion motion^{49,72,73} (Table 3). Over the years, several modifications regarding design and biomaterials have been made (Table 3). The inventors of the prosthesis have published their long-term results (Table 7). Two consecutive series of patients were evaluated during a 20 year interval using the New Jersey Orthopaedic Hospital ankle scoring scale to determine clinical outcome and overall implant survivorship with revision as an endpoint. In the initial series of 40 ankle replacements, a shallow-sulcus design was used. Clinical results after 2–20 years (mean 12 years) were 70% good to excellent, 5% fair and 25% poor. Postoperative total arc ankle motion ranged from 10° to 47° total arc (mean 25°). A deep-sulcus design was used after 1990. Clinical results after 2–12 years (mean 5 years) were 88% good to excellent, 5% fair and 7% poor, in a series of 75 ankle replacements. Postoperative ankle motion ranged from 10° to 50° total arc (mean, 29°). High survivorship rates were reported.⁷³ The results have closely been reproduced by independent surgeons.^{74,75} Doets *et al.*⁷⁵ published the largest series and the longest follow-up of BP prostheses provided

Buechel–Pappas:

a three-component ankle prosthesis

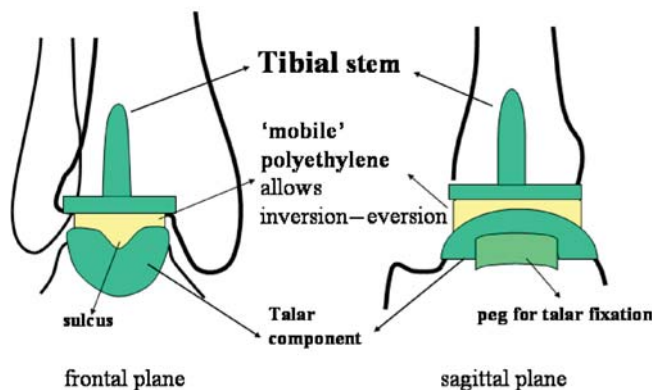


Fig. 8 The tibial stem and the deep sulcus of the talar component accommodating a matching polyethylene surface, allowing inversion/eversion motion, are characteristic features of the Buechel–Pappas ankle replacement.

Table 7 Buechel–Pappas ankle replacement: results.

Author	Year	Study type	From	To	Age	F-up	Ankles	Failure rate	Survivorship analysis	Radiographic loosening	Comments/other
Buechel <i>et al.</i> ⁷³	2004	Prospective cohort	1981	1988	55	12	40	27.5%	74% at 20 yrs	15%	Designer: shallow sulcus design
			1991	2000	49	5	75	8.0%	92% at 12 yrs	11%	Deep sulcus design
Su <i>et al.</i> ¹²⁹	2004	Retrospective cohort	1994	2001	50	4.4	19	5.3%	–	11.5%	
Doets <i>et al.</i> ⁷⁵	2006	Prospective cohort	1988	1999		7.6	93	16.1%	84% at 8 yrs	21%	Improved survival with deep sulcus design
San Giovanni <i>et al.</i> ⁷⁴	2006	?	1990	1997	61	8.3	31	6.5%	93.4% at 8 yrs	18%	89% satisfaction; 29% complications
Ali <i>et al.</i> ⁷⁶	2007	?	1990	2005	69	5	35	2.9%	–	0	97% satisfaction rate
Henricson <i>et al.</i> ⁸⁰	2007	NJR data	2000	2006	–	–	92	17.4%	–		Swedish NJR
Mean or total					56.6	6.3	253 (345)	9.9% (11.9%)		16%	Excl NJR (incl NJR)

F-up, follow-up; NJR, National Joint Register; Age and follow-up counted in years; yrs, years.

by independent researchers. They used 19 LCS implants with a 60% survivorship at 10 years, whereas in 74 BP (deep sulcus version) implants a 90% at 12 years survivorship was reported. Wound complications were recorded in 26 ankles (9.7%) and deep infections in 8 (3%). Intraoperative fractures were recorded in 45 of 234 cases (9.2%) in four studies.⁷³⁻⁷⁶

The Scandinavian Total Ankle Replacement (STAR) (Waldmar Link, Hamburg, Germany)

The STAR (Fig. 9) is one of the most widely used ankle prostheses. The first design was introduced by Dr Kofoed in 1978, with the first prosthesis implanted in 1981 (Table 3), consisted of a metallic talar component that covered the medial and lateral talar surfaces, articulating with a polyethylene tibial component (two-component congruent unconstrained design). Both were fixed with bone cement.^{47,77-80} Results of this prosthesis revealed a 12 year survival rate of 70%.⁷⁷ A 'meniscus' polyethylene was introduced in 1986.⁷⁸ Two anchorage bars on the tibial platform enhance fixation to the tibial bone. The concave talar component has a longitudinal ridge, which is congruent with the distal surface of the mobile meniscus. Dorsi- and plantarflexion at the meniscal talar interface, but no talar tilt, are allowed. Rotation is allowed at the (flat) meniscal tibial interface.⁴⁷ From 1990, a bioactive surface coating for cementless implantation was introduced, and from 1999 a double coating. Clinical results showed that cement fixation was

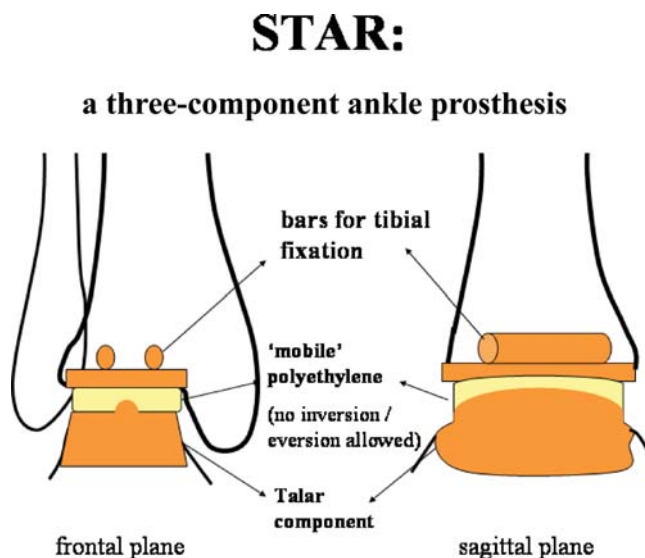


Fig. 9 The STAR prosthesis uses two bars for tibial component fixation. No inversion/eversion is allowed.

less successful.⁷⁹ An impressive 95.4% survival rate for the uncemented design (prostheses implanted between 1990 and 1995) reported by the developer of the implant⁷⁹ has not been reproduced by others (Table 8).^{44,57,80-94} Earlier results of a multicenter European study⁹⁵ of 131 cementless ankle implants revealed a 87.3% survivorship at 7 years. All failures occurred within 2 years of surgery. A Swedish group of surgeons^{82,83} reported significantly higher survivorship for the latter 31 ankle replacements they performed (88% at 5 years and 65% at 10 years), compared with the first 20 (65% at 5 years and 37% at 10 years) using the single-coated STAR prosthesis. They also reported a 98% prosthesis survivorship at 5 years using 58 double-coated STAR prostheses. Surgeons' experience influenced results.⁸³ Intraoperative fractures were recorded in five studies: 29 fractures occurred in 468 ankles (5.3%). Wound complications occurred in 36 of 615 ankles (eight studies) (5.9%) and deep infections in 3 of 788 (eight studies) (0.4%). Radiographic loosening was recorded in 34 of 376 ankles (9%) in six studies with mean follow-up 3.8 years. The latest report on results with the STAR prosthesis was presented at the 75th Annual AAOS Meeting. A prospective medium term follow up study of 165 STAR total ankle replacements followed for a mean of 3.2 years (1-8 years) revealed a cumulative survival of 90% at 5 years.⁹⁴ The senior author had previously published his results in his first 50 ankle replacements.⁹²

The SALTO prosthesis (Tornier SA, Saint Ismier, France)

This implant (Fig. 6) has some design similarities with the BP: the polyethylene has a flat upper surface and conforms to the congruent surface of the talar component with a longitudinal sulcus, allowing varus/valgus motion in the coronal plane at the ankle joint level (Table 3). In addition, a medial metallic rim on the tibial component aims to prevent medial impingement and a polyethylene implant on the fibula can articulate with the talar component (talofibular joint replacement). The only available clinical results come from the developers of the prosthesis (Table 5), with at least a 94.9% survival rate. Functional outcome was similarly very encouraging, without any differences between rheumatoid and patients with idiopathic osteoarthritis.⁶³ Longer-term follow-up results were presented by the same group at the American Orthopaedic Foot and Ankle Society 22nd Annual Summer Meeting in 2006.⁹⁶ No independent results have been published regarding the Salto prosthesis.

The RAMSES Ankle Replacement (Laboratoire Fournitures Hospitalieres, Heimsbrunn, France)

The Ramses was developed in 1989 by a group of foot and ankle specialists in France, known as the Talus Group.⁹⁷ From 1989 to 2000

Table 8 STAR prosthesis: results.

Author	Year	Study type	From	To	Age	F-up	Ankles	Failure rate	Survivorship analysis	Radiographic loosening	Comments / Other
Kofoed ⁷⁹	2004	Prospective cohort	1990	1995	58	9.5	25	4%	95.4% at 12 yrs	4%	Designer
Schill <i>et al.</i> ⁴²	1998	Prospective cohort	1984	1996	–	3.1	22	6%	93.4% at 5 yrs	–	
Carlsson <i>et al.</i> ^{83*}	2006	Prospective cohort	1993	1999	57	10	51	29.4%	70% at 10 yrs	–	Data incl. in NJR**
			1999	2005	56	3.6	58	1.7%	98% at 5 yrs	4.2%	Data incl. in NJR**
Anderson <i>et al.</i> ^{82*}	2003	Prospective cohort	1993	1999	57	4.3	51	23.5%	70% at 5 yrs	16%	Data incl. in NJR**
Natens <i>et al.</i> ⁸⁴	2003	Prospective cohort	1996	1999	–	1.3	26	0%	–	–	Short follow-up
Wood and Deakin ^{85**}	2003	Prospective cohort	1993	2000	59.6	3.8	200	7%	87.9% at 8 yrs	4.8%	64% ossification
Wood <i>et al.</i> ^{86**}	2008	Prospective cohort	1993	2000	59.6	–	200	12%	80.3% at 10 yrs	12.5%	
Valderabano <i>et al.</i> ⁸⁷	2004	Prospective cohort	1996	1999	56	3.7	68	13.2%	87% at 5 yrs	–	43% ossification
Lohdi <i>et al.</i> ⁸⁸	2004	Retrospective cohort	1997	2001	68	–	30	3.3%	–	–	Mean f-up not reported
Hagena <i>et al.</i> ⁸⁹	2005	Prospective cohort	1997	2003	58	–	147	7.5%	–	–	Mean f-up not reported
Murnaghan <i>et al.</i> ⁹¹	2005	Retrospective cohort	–	–	60	2.2	22	9.1%	–	27%	
Kumar and Dhar ⁹²	2007	Prospective cohort	1999	2003	63	3	50	6%	–	–	Presented on 165 ankles*
Schutte <i>et al.</i> ⁹³	2008	Retrospective cohort	1999	2004	57	2.3	49	8.2%	–	24.5%	
Hosman <i>et al.</i> ⁵⁷	2007	NJR data	2000	2005	–	3.6	45	6.7%	–	–	New Zealand NJR
Fevang <i>et al.</i> ⁴⁴	2007	NJR data	1994	2006	61	3.1	216	9.7%	–	–	Norway NJR
Henricson <i>et al.</i> ^{80***}	2007	NJR data	1993	2006	–	–	303	23.4%	–	–	Swedish NJR
In 13 studies						3.9	939	9.9%			Follow-up reported
In 12 studies					59.3						Mean age reported

F-up, follow-up; NJR, National Joint Register; age and follow-up counted in years.

*Same case series.

**Same case series.

***Data included in NJR NJR: Swedish NJR report (Henricson *et al.*⁶⁹).

all prostheses were cemented. Since 2000, only uncemented implants were used (Table 3). A total of about 350 Ramses prostheses have been implanted by the inventors' group.⁹⁸ The results can only be retrieved from the New Zealand Joint Arthroplasty Register⁵⁷ (Table 5).

The HINTEGRA TAA (Newdeal SA, Lyon, France)

It consists of a flat tibial component, a polyethylene inlay and a convex conic talar component with a smaller medial radius. Both the talar and tibial components have ventral shields for screw fixation^{47,99} (Fig. 10, Table 3). Side borders on the talar component hold the polyethylene inlay in position and should prevent dislocation. This prosthesis has been used since 2000 in Europe^{47,99}, since 2004 in Canada and, according to the manufacturers, more than 1000 prostheses have been implanted in Brazil since 2005.¹⁰⁰

The inventors of the HINTEGRA prosthesis prospectively reviewed the outcome of their surgeries, and published their short and midterm results in English⁹⁹ and German.¹⁰¹ The results revealed 39 major complications (in 278 implantations) and 18 failures, 13 of which occurred in 2000. Failure rate dropped after 2003. Of 15 talar components loosening complications requiring revision surgery, 14 were of the early version (HA coated), which was later improved.¹⁰¹ Their latest report was presented at the 75th Annual AAOS Meeting in San Francisco, USA, in March 2008. Overall survivorship in 340 primary TAR at 6 years was 98.2%, being 97.9% for the talar component and 98.8% for the tibial component.¹⁰² Dr Hintermann and his colleagues have

HINTEGRA:

mobile-bearing (three-component) ankle prosthesis

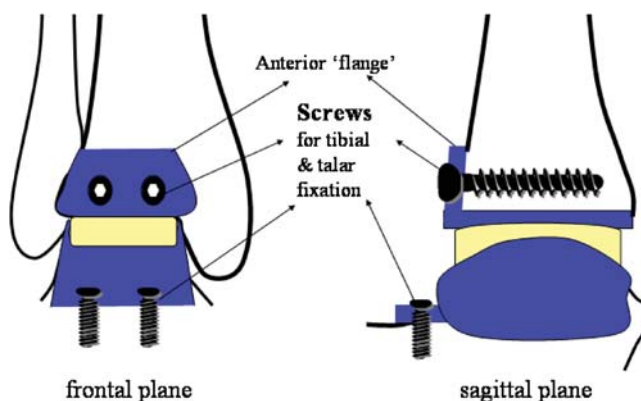


Fig. 10 Screw fixation is a characteristic element of the HINTEGRA prosthesis. Talar component side rims aim to prevent polyethylene dislocation.

also prospectively followed and reported on 37 consecutive revision TAR using the HINTEGRA implant, not requiring any other revision surgeries at a mean of 3.6 years (1.2–6.4 years) follow-up.¹⁰³ The same implant has been used by the same group in 19 cases of ankle fusions or attempted ankle fusion. A report of this prospective study at 3.5 years follow-up (2–6.2 years) showed no failures, with satisfactory clinical results, which were, however, inferior compared with those of primary TAR.¹⁰⁴

Ankle Evolutive System (AES) (Biomet Merck, The Netherlands)

This BP-type implant has a modular tibial stem and allows hemi-replacement of the medial tibiotalar and talofibular joints, respectively⁴⁷ (Table 3). The designer of the prosthesis has presented his short-term results in 2001 in a meeting in France.¹⁰⁵ In an anecdotal report of 240 ankle replacements performed by Dr Asencio from 1999 to 2004, including complex cases requiring realignment procedures, a 5% revision rate was reported.⁴⁷ The AES system has been used in Scandinavia since 2002.^{44,80} Two surgeons have reported their short-term results with the AES prosthesis^{106,107} (Table 5).

The Mobility ankle system (DePuy)

The Mobility Total Ankle System (BP-type) was developed by a team of experienced ankle arthroplasty surgeons (Table 3). Dr Rippstein, one of the designers, presented his preliminary results in an International meeting in 2006.¹⁰⁸ The use of the prosthesis was documented in the New Zealand⁵⁷ and the Swedish Arthroplasty Register⁸⁰ (Table 5). The Mobility prosthesis is currently being used in the USA as part of a prospective, randomized, multicentre (several USA centres), single-blind, controlled clinical investigation, started in January 2007 and estimated to be completed by January 2010, to determine the safety and efficacy of the cementless Mobility™ Total Ankle System compared with the Agility™ LP Total Ankle Prosthesis.¹⁰⁹

BOX (Bologna, Oxford) Total Ankle Replacement

The BOX (Bologna Oxford) Total Ankle Replacement is a new generation mobile-bearing prosthesis (Table 3). It was designed after a collaboration of the Rizzoli Orthopaedic Institute, Bologna, Italy (Prof. Giannini, Prof. Catani and Dr Leardini) and Oxford University (Prof. O'Connor). The BOX Total Ankle is used clinically in pilot centres in Italy. Original research studies of the designers of this prosthesis focus on movement and stability of the ankle and aim in providing detailed understanding of the role of the ligaments in controlling and limiting joint movement.^{110,111} The designers claim that it maintains complete congruency during the entire arc of motion and closely resembles

normal ankle biomechanics. A four-bar linkage model was developed from this initial study that also showed that both rolling and sliding motions take place at the talocrural joint.^{112,113} They presented a poster in the 75th Annual AAOS Meeting with their experience with this new design¹¹⁴ (Table 5).

The German Ankle System (R-Innovation Coburg Germany)

This new three-component 'mobile-bearing' variant has been developed by Prof. Richter and his colleagues in Coburg, Germany (Table 3). A porous coating with titanium plasma sprayed surface with an additional layer of calcium phosphate (BONIT[®] coating) is used to accelerate bone ongrowth to the implant surface. All components can be used for either side. The system includes computer-assisted (CAS) guided implantation as an option. This model has been used in comparison to the HINTEGRA ankle replacement and to the non-replaced cadaveric ankle, in a robot-based cadaver test. The investigators concluded that the German Ankle System prosthesis had less of an effect on resulting forces, torques and motions during partial weight-bearing passive ankle motion. This might improve function and minimize loosening during the clinical use.¹¹⁵ No clinical results are available.

The ZENITH total ankle replacement system (Corin, UK)

The Zenith TAR system has been designed in collaboration with Mr Ian Winson (Bristol, UK) and Dr Frank (Leverkusen, Germany) (Table 3). BONIT[®] coating is used to accelerate bone ongrowth to the implant surface. It resembles the BP design. The medial and lateral talar surfaces are not replaced.¹¹⁶ No clinical results are available.

The Alphanorm total ankle replacement

The Alphanorm prosthesis (BP-type) has been used by Prof. Tillman (Germany) since 1996.¹¹⁷ The medial and lateral talar surfaces are not replaced (Table 3). Dr. Tillman has not published his results.

The TARIC prosthesis

The developers (Dr Schill, Dr Rehart and Prof. Fink from Germany) have used this implant (Table 3) in cadavers, and planed its clinical use.¹¹⁸

The CCI evolution total ankle prosthesis

This mobile-bearing prosthesis is in clinical use in the Netherlands since 2003, and in Germany and Switzerland since 2005. At present, no reports of results with this design are available.¹¹⁹

Discussion

Ankle kinematics and ankle arthroplasty designs: general considerations

The anatomical configuration with high congruency of the ankle joint and the complex dynamic nature of the ankle axis of rotation has important implications in the design of total ankle prostheses.¹²⁰ Motion at the ankle joint is a complex motion in three planes, mainly dorsiflexion and plantarflexion, but also eversion, inversion, internal rotation and external rotation.^{121,122} The design of an ankle joint prosthesis should either replicate exactly the original anatomical geometry of both the ligamentous structures and the articular surfaces, or should restore compatible function of the ligaments and articular surfaces, but with slightly non-anatomical shapes of the articular surfaces. The use of fully congruous surfaces in two-component designs may be the cause of loosening of cylindrical and spherical designs. Considering the different types of prostheses, the highest failure rates were produced by the constrained designs.^{34,36} The constrained designs were expected to provide better resistance to wear and surface deformation as a result of better pressure distribution, but an inadequate restoration of the characteristic three-planar rotation and gliding ankle motion did not fulfil those expectations.^{18,123} Loosening rates of first-generation two-component designs are as bad as 60% and 90% after 5 and 10 years, respectively.³⁴ Incongruent surfaces in total ankle replacements would lead to high local stresses and pressures and therefore increase polyethylene wear. Congruent surfaces have the advantage that when a load is applied, it is more favourably distributed across the surfaces, thus increasing wear resistance. Congruent designs are therefore required to provide greater stability and resistance to wear. The use of a mobile-bearing implant has been intended to solve the dilemma combining congruence with minimally constrained components to enable the soft tissues to control physiological motion at the joint.^{46,49} The use of cement fixation in all early designs has been abandoned in the 1980s. The increased stresses applied to the bone–cement interface in those biomechanically ‘immature’ ankle implants and the less understood cement pressurization process lead to failures.^{123,124} Cementless fixation proved more successful.⁷⁹ Improved biomaterials that enhance bone ingrowth and thus prosthesis fixation are being manufactured, and cementless fixation in ankle arthroplasty is the ‘gold standard’ at present (Tables 1–3). As improved bone–implant fixation is essential for long-term prosthesis survival, the issue of fixation method has been addressed. A study¹²⁵ which investigated the bone strength at the distal tibia and proximal talus using an osteopenetrometer to take bone strength measurements at 2 mm sections showed that the bone strength

was significantly higher in the talus (40% on average) and that in both the talus and tibia the strength rapidly decreased below the surface. They concluded that if the resection was more than 4 mm deep the surface will be significantly less resistant to compressive loads. Kofoed^{78,79} also noted that only the most distal 1–1.5 cm of the tibia is solid subchondral bone. Above this level, the bone marrow is loose and fatty and not a stable location to fix either a cemented or uncemented prosthesis.^{78,79} This applies to the design of the Agility and the STAR prostheses that do not rely on a stem for tibial component fixation, and has been adapted by some of the newer designs (HINTEGRA) that uses screw fixation, whereas the BOX ankle replacement has two anchorage bars similar to the STAR prosthesis. The BP prosthesis was the first of the new generation implants that relies on a longer tibial stem. This has been adopted by some newer designs (Salto, Alphanorm, AES, MobilityTM, Zenith). Smaller tibial pegs for tibial fixation are used by the RAMSES, ESKA, German Ankle System and TARIC ankle replacements. The clinical significance of this element is discussed in the following sections. The finding that the talus is stronger than the tibia reflects the fact that talar component loosening was less common than tibial loosening both in the first- and modern-generation ankle replacements.^{36,73,79} It also shows that minimal bone resection is required for the bone–implant interface to remain firm.^{47,126}

The main differences between the STAR and the HINTEGRA compared with the BP-type implants (AES, MobilityTM, Alphanorm, Zenith) is the allowance of inversion–eversion at the ankle joint level by the latter designs. Theoretically, this should avoid edge loading of the polyethylene meniscus and provide decreased wear rates and improved survival of the prosthesis.^{49,73} The literature cannot provide evidence to answer this debate. However, the coupling of the inversion–eversion motion at the level of the normal ankle joint and the subtalar joint has recently been investigated by two MRI studies.^{127,128} The three-dimensional subtalar kinematics demonstrated that the talus and calcaneus do not move as a single unit and most calcaneal–tibial supination occurred at the talocrural joint.¹²⁸ The inversion motion at the ankle joint should therefore also be an important element for the replaced ankle.

Replacement of the medial and lateral talar facets is another difference among total ankle implants. Currently, it is not known which patients are best treated by replacing the superior tibiotalar joint alone, and which will benefit from replacement of the talofibular and medial tibiotalar joints as well.

‘Darwinian’ selection in TAA eliminated the constrained implants and abandoned cement fixation. The addition of a polyethylene ‘meniscus’ (fixed- or mobile-bearing) can be characterized as the

transformation, which allowed reproduction of more normal ankle kinematics and higher prostheses' survival rates.^{22,73–75,79,85} The advantageous effect of mobile-bearing over fixed-bearing designs can still be debated, based on the published clinical results available. However, all newly developed ankle replacement implants have incorporated the mobile-bearing concept with minor modifications. The above evolution does not fully apply in the USA clinical practice, due to FDA restrictions on three-component mobile-bearing designs.⁵⁰

Interpretation of results

Since only level IV studies are available, different factors can influence interpretation of the results. Frequently, studies describe the use of different versions of an implant, as evolution adds new elements in their design or materials they contain. This can be important, since an improved surface coating, for example, can influence long-term results. Nevertheless, length of follow-up is crucial in the process of drawing conclusions, since most current implants provide very satisfactory short-term results. Outcome measures are important. Different clinical outcome scores have been used in different studies (AOFAS, Kofoed score, New Jersey score, Ankle Osteoarthritis Scale). In some studies, the above measurements were undertaken only postoperatively. One study used an SF-36 questionnaire. This makes comparisons difficult.

We focused on extracting the failure rates, with revision of any of the components or fusion considered as such, the need of reoperations and the wound and deep infections in the studies mentioned. Results in short- or intermediate-term studies can also be misleading and surgeons' familiarity with the procedure has to be mentioned given the learning curve effect. Nevertheless, longevity of ankle replacements and wound-associated complications are the main concerns of their use. Given the lack of randomized, controlled trials, any conclusion regarding better outcomes of one implant over another should be made with extreme caution. Published results from the prosthesis inventors' unit can be biased and reflect the higher familiarity with the implant. Upon all, the reproducibility of results by independent surgeons is of great importance.

Discussion on specific implants/ankle replacement designs

The Agility prosthesis

The major concern is the need of syndesmosis union for a successful long-lasting ankle replacement. The association of syndesmosis-delayed

union and non-union with short- or midterm failures has been reported in several studies.^{51–56} Furthermore, implantation of the Agility prosthesis requires more extensive bone removal,⁴⁸ possibly compromising future revision options. In terms of ankle kinematics, this semi-constrained design does not replicate normal ankle motion, as the ankle ‘slides’ from side to side during rotation and dorsi- and plantar-flexion motion. This raises concerns regarding increased wear debris production. The published results show an 11.7% failure rate at a 2.8-year follow-up. However, studies by authors other than the developers of the prosthesis, providing survivorship analysis at a longer follow-up, show rates of 80% at 5 years⁵⁵ and 67% at 6 years.⁵⁴

The TNK prosthesis

The TNK ankle is similar to previous two-component prostheses that failed because of excessive shear forces and torque transfer to the prosthesis, bone interface. Although reported failure rates are not discouraging, high loosening rates have been reported.^{67–71} Furthermore, it requires extensive bone removal on the tibial side, leaving the mechanically supramalleolar tibial cancellous bone⁴⁷ for fixation. Fixation is also questionable, since the osseointegration performance of HA-coated ceramic material is not known. As a result, high radiographic loosening rates in low demand (rheumatoid) patients have been reported.^{70,71}

The ESKA ankle prosthesis

A possible factor against the spread in the use of the ESKA prosthesis outside the inventors’ institution is its design for implantation through a lateral approach with fibular osteotomy. Most Foot and Ankle Specialists are probably much more familiar with anterior ankle approaches, and would not easily adopt the ESKA implant. The results published by the developer of the prosthesis show an 78% implant survival rate in 32 ankles with follow-up more than 5 years⁶⁶ (Table 5). This includes the learning curve, and longer follow-up results in the subsequent cases (no failures in 72 ankle replacements followed for 1–5 years)⁶⁶ would be of value.

Other two-component designs

The INBONE, Eclipse and SALTO Talaris (variant of the SALTO ankle replacement used in Europe) prostheses have been developed for use in the USA given the FDA restrictions on three-component designs.⁵⁰ The long-stem of the INBONE implant raises concerns.

The BP and BP-type implants

The main concern regarding the BP implant and all implants having a tibial stem (SALTO, AES, MobilityTM) to facilitate fixation is

weakening of the anterior tibial cortex, as an anterior cortical window has to be produced for insertion of the component. Load transmission in the weakened anterior cortex in the supramalleolar area is a concern for the early postoperative period. Doets *et al.*⁷⁵ reported four distal tibia fractures at the level of the tip of the stem within 6 months of surgery. This raises concerns regarding early migration that could lead to loosening in the mid-term. Nelissen *et al.*¹²⁶ documented early migration of the tibial component of the BP prosthesis, which, however, stabilized thereafter. Higher wear rates reported for the shallow sulcus BP prosthesis may not only be related to ankle kinematics but also to the quality of polyethylene (gamma sterilization in air in the earlier designs).^{73,75} Independent researchers reported survival rates of the BP prosthesis approximating 90% at 4 years, remaining unchanged thereafter up to 10 years of follow-up.⁷⁵ Other independent authors⁷⁴ also reported high survivorship rates in the long-term (93.4% at 8.3 years). The results were far better with the newer generation BP prosthesis compared with the previous design, the LCS.⁷⁵ The LCS prosthesis survival rates approximated 60% at 10 years, including the surgeons' learning curve.

The BP, AES, Mobility and Zenith prostheses do not replace the talar facets. The developers of the BP implant did not find that absence of talar component side flanges clinically relevant. The thought was to maintain the malleolar–talar articulations to allow normal tibiofibular rotation.⁷³ The results on the AES^{44,57,80,104–106} and Mobility^{TM44,57,80,107} ankle implants provide only short-term outcomes, and, although encouraging, are premature for analysis and reliable interpretation. An ongoing FDA-trial¹⁰⁸ evaluating the outcome of the MobilityTM ankle prosthesis compared with the Agility prosthesis will be of great value when results are available.

The SALTO ankle replacement

The keel and the hollow bar used for fixation of the tibial component may create bending moments during load transmission, questioning breakage in the long term. Furthermore, the hollow bar on the keel of the tibial component of the Salto prosthesis could produce an entry point into the distal tibia for particles, and thus for particle-induced osteolysis. Similar to the STAR prosthesis, concerns have been expressed regarding the tibial component's small dimensions relative to the tibial plafond.⁵⁰ The short-term results published by its developers are promising.⁶³

The STAR prosthesis

The concerns regarding the small dimension of the tibial component of the STAR prosthesis, related with the tibial plafond, are supported by

high rates (47–62%) of periarticular ossification reported in the literature.^{85–87} The lack of circumferential bone support makes the tibial component prone to subsidence (sinking) in the distal tibia cancellous bone and to osseous overgrowth. Furthermore, motion only in one axis, due to the non-anatomic cylindrical shape of the talus, may produce load transfer to the medial side and overstress the medial ligaments and capsule.⁴⁷ Valderabano *et al.*⁸⁷ reported tilting of the tibial component in 9 of 68 ankles (13%) within the first 3 months, without progression thereafter. This can be the result of shear forces and imperfect apposition of tibial prosthesis and bone initially. With time, remodelling of the trabecular bone possibly prevented further progression. The STAR prosthesis allows internal/external rotation at the planar floating bearing–tibial interface, but does not allow for pronation/supination, which occurs in the intact human ankle complex. The clinical implication would be edge loading of the ‘meniscus’. This was reported⁸⁵ and was associated with preoperative varus/valgus malalignment. The results from the use of the STAR prosthesis—the most widely used ankle prosthesis in Europe since 1991—have been encouraging. Recently (April 2007), its use in the USA has received FDA clearance.^{13,50} The use of a double-coated type of implant since 2000 has been associated with better survivorship.^{79,83} However, surgeons’ experience has been increasing at the same time, possibly contributing to the better results with the double-coated STAR implant.

The Ramses prosthesis

Concerns about the Ramses ankle implant are the wide talar bone resection, compromising future revision options and the thin tibial loading platform (long-term fatigue possible). In addition, frontal plane stability relies entirely on the medial and lateral ligamentous structures. This does not correspond to normal ankle biomechanics, where frontal plane stability relies mainly on joint congruency.⁴⁷ Chronic overstress may cause pain, instability and impingement. The results published by the developers of the prosthesis refer to the cemented version used before 2000. A 17.4% failure with 39% radiographic loosening rates, after more than 10 years of follow-up,⁹⁸ has probably caused the turn towards non-cemented fixation since 2000.

The HINTEGRA total ankle replacement

As the distal tibia metaphyseal cancellous bone has been associated with poor quality more than a few millimetres proximal to the joint, an important element in the rationale of the HINTEGRA prosthesis design was minimal tibial bone resection.^{47,99} On the other hand, screw fixation was required to compensate for the lack of stems (BP-type implants) or anchorage bars (STAR prosthesis). Screw fixation

raises concerns. In the early postoperative phase, before bone ingrowth provides adequate stability, loosening of the screws could be possible. Unique about this prosthesis is the anterior tibial flange to reduce postoperative heterotopic ossification and soft-tissue adherence. A series of studies on kinematics after implantation of the HINTEGRA prosthesis has provided very promising results.^{6–8} However, inversion–eversion and rotational motion is not allowed, possibly causing higher stresses at the bone–implant interface. The prosthesis clinical outcome has to be evaluated after longer follow-up studies will be available. The inventors' initial report on 122 ankle arthroplasties at 18.9 months follow-up revealed a high early complication rate.⁸⁶ Subsequent surgeries have been more successful at a longer follow-up.^{101,102}

Other designs

The New German Ankle System has provided data on biomechanics and their ability to closely restore normal ankle motion after implantation in cadavers.¹¹⁵ The developers of the BOX ankle replacement have published the results of extensive biomechanical research,^{110–112} and recently presented promising clinical results.¹¹⁴ The designers claim that it maintains complete congruency during the entire arc of motion and closely resembles normal ankle biomechanics. A four-bar linkage model was developed from this initial study and showed that both rolling and sliding motions take place at the talocrural joint.^{112,113} Long-term results have to provide evidence on their clinical success.

Comparing results

Taking into consideration all limitations that could lead to inappropriate conclusions (e.g. short follow-up or follow-up period not clearly defined, publication only by designer of prosthesis), it is only appropriate to compare failure rates between the Agility, STAR and BP prostheses. The BP and STAR prostheses have comparable failure rates, but studies presenting BP implant results have a longer follow-up period (Tables 7 and 8). The Agility prosthesis shows a relatively higher failure rate at a shorter follow-up (Table 4).

Surgeons' experience: a key factor

A crucial factor that directly influences outcomes of TAA is surgeons' familiarity with the procedure. Many studies showed that their early cases results were inferior.^{51,52,54,75,80–83,101,107} The Swedish Joint Arthroplasty Registry data⁸⁰ are self-explanatory: three surgeons had performed more than 40 ankle replacements each, excluding cemented

and infected ankle replacements. Separate survival curves for their 30 first procedures and the procedures performed thereafter were constructed. The 5-year survival increased from 0.70 (0.57–0.77) for the first 90 cases, to 0.86 (0.80–0.93) for the following 132 cases ($P = 0.01$).

The current trend in ankle arthroplasty

Based on the results, a universal expansion of indications cannot be supported. Increasing familiarity with the procedure among individual surgeons has probably expanded its application. Some recent studies include high rates of patients with posttraumatic arthritis and malalignment.^{96,99,101,102} Although malalignment has been considered a relative contraindication for ankle replacement,^{85,86} more surgeons attempt this procedure after correcting the deformities (e.g. subtalar or triple fusions, calcaneal osteotomies).

In Europe, three-component mobile-bearing designs are the 'gold standard' in ankle arthroplasty. In the USA, the STAR and BP implants have been used as part of clinical trials. After the STAR prosthesis received FDA approval in April 2007³⁸ and the MobilityTM ankle replacement has now been enrolled in a trial,¹⁰⁹ the trend towards the three-component mobile-bearing implants will probably spread across the Atlantic.

Uncemented fixation has been adopted by most surgeons since the 1990s, and is the 'gold standard' today. Ankle prostheses in the current decade are being designed based on previous biomechanical studies and other clinically successful design concepts. Decreased bone resection to allow better bone quality for prosthesis fixation and improved surface biomaterials are key elements of newer designs. Stem tibial component fixation, versus pegs, bars, fins, is a controversial issue. The same applies to the replacement or not of the medial tibiotalar and tibiofibular joints. The results in the outcome studies do not provide definitive answers to this debate.

The literature review shows a trend towards the use of three-component BP-type designs in Europe: the Swedish Arthroplasty Register⁸⁰ data showed that BP-type implants (including the AES since 2003 and the MobilityTM since 2005) are increasingly popular in Swedish Orthopaedic surgeons. As a result, they accounted for more than half of ankle arthroplasties in Sweden in 2003, and more than two-thirds in 2004 and 2005. The use of the STAR in Sweden accounted for almost 100% of ankle replacements from 1993 to 2001. A gradual decline was observed from 80% in 2002 to approximately 30% in 2005.⁸⁰

Conclusion

Evidence-based knowledge regarding results of ankle arthroplasty comes from level IV studies only. Diligent study of normal ankle biomechanics and review of previous implant failures has led to the development of a new generation of implants. This improvement, coupled with improved cementless fixation, has led to prosthetic designs with decreased failure rates. The ‘revolution’ was the addition of a polyethylene ‘meniscus’ in the artificial ankle joint, allowing congruent motion, more normal ankle kinematics and decreased load stresses and wear rates. Increased awareness and adequate surgeons’ training are probably the key factors to transform TAA to a promising alternative to ankle arthrodesis. Appropriate patients’ selection remains a cornerstone for a successful ankle replacement. Extension of the indications to younger age groups with more active life-styles and to ankles with deformities is the challenge for the future.

References

- 1 Rhys TH, Daniels TR (2003) Ankle arthritis. Current concepts review. *J Bone Joint Surg Am*, **85A**, 923–936.
- 2 Jackson MP, Singh D (2003) Total ankle replacement. *Curr Orthop*, **17**, 292–298.
- 3 Gougoulias NE, Aggathangelidis F, Parsons SW (2007) Arthroscopic ankle arthrodesis. *Foot Ankle Int*, **28**, 695–706.
- 4 Piriou P, Culpan P, Mullins M (2008) Ankle replacement versus arthrodesis: a comparative gait analysis study. *Foot Ankle Int*, **29**, 3–9.
- 5 Doets HC, van Middelkoop M, Houdijk H, Nelissen RG, Veeger HE (2007) Gait analysis after successful mobile bearing total ankle replacement. *Foot Ankle Int*, **28**, 313–322.
- 6 Valderrabano V, Hintermann B, Nigg B, Stefanyshyn D (2003) Kinematic changes after fusion and total replacement of the ankle—part 1: range of motion. *Foot Ankle Int*, **24**, 881–887.
- 7 Valderrabano V, Hintermann B, Nigg B, Stefanyshyn D, Stergiou P (2003) Kinematic changes after fusion and total replacement of the ankle—part 2: movement transfer. *Foot Ankle Int*, **24**, 889–896.
- 8 Valderrabano V, Hintermann B, Nigg B, Stefanyshyn D, Stergiou P (2003) Kinematic changes after fusion and total replacement of the ankle—part 3: talar movement. *Foot Ankle Int*, **24**, 897–900.
- 9 Abidi NA, Gruen GS, Conti S (2000) Ankle arthrodesis. Indications and techniques. *J Am Acad Orthop Surg*, **8**, 200–209.
- 10 Haddad SL, Coetzee JC, Estok R, Fajrbach K, Banel D, Nalysnyk L (2007) Intermediate and long-term outcomes of total ankle arthroplasty and ankle arthrodesis. A systemic review of the literature. *J Bone Joint Surg*, **89A**, 1899–1905.
- 11 Coester LM, Saltzman CL, Leupold J, Pontarelli W (2001) Long-term results following ankle arthrodesis for posttraumatic arthritis. *J Bone Joint Surg*, **83A**, 219–228.
- 12 Guyer AJ, Richardson EG (2008) Current concepts review: total ankle arthroplasty. *Foot Ankle Int*, **29**, 256–264.
- 13 Chou LB, Coughlin MT, Hansen S Jr et al. (2008) Osteoarthritis of the ankle: the role of arthroplasty. *J Am Acad Orthop Surg*, **16**, 249–259.
- 14 Learmonth I, Young C, Rorebeck C (2007) The operation of the century: total hip replacement. *Lancet*, **370**, 1508–1519.

- 15 Wu WL, Su FC, Cheng YM, Huang PJ, Chou YL, Chou CK (2000) Gait analysis after ankle arthrodesis. *Gait Posture*, **11**, 54–61.
- 16 Sheridan BD, Robinson DE, Hubble MJW, Winson IG (2006) Ankle arthrodesis and its relationship to ipsilateral arthritis of the hind- and midfoot. *J Bone Joint Surg*, **88B**, 206–207.
- 17 Nelissen RGHH, Doets HC, Meskers C (1998) The value of ankle prostheses—a gait analysis approach. In Kofoed H (ed.) *Current Status of Ankle Arthroplasty*. Berlin: Springer, 72–77.
- 18 Giannini S, Leardini T, O'Connor JJ (2000) Total ankle replacement: review of the designs and of the current status. *Foot Ankle Surg*, **6**, 77–88.
- 19 Easley ME, Vertullo CJ, Urban WC, Nunley JA (2002) Total ankle arthroplasty. *J Am Acad Orthop Surg*, **10**, 157–167.
- 20 Goodfellow JW, O'Connor JO (1979) The mechanics of the knee and prosthesis design. *J Bone Joint Surg (Br)*, **60B**, 358–368.
- 21 Buechel FF, Pappas MJ (1989) New Jersey low contact stress knee replacement system. Ten-year evaluation of meniscal bearings. *Orthop Clin North Am*, **20**, 147–177.
- 22 Stengel D, Bauwens K, Ekkernkamp A, Cramer J (2005) Efficacy of total ankle replacement with meniscal-bearing devices: a systematic review and meta-analysis. *Arch Orthop Trauma Surg*, **125**, 109–119.
- 23 Lord G, Marotte JH (1973) Total ankle prosthesis. Technique and first results. Apropos of 12 cases. *Rev Chir Orthop Reparatrice Appar Mot*, **59**, 139–151.
- 24 Lord G, Marotte JH (1980) Total ankle replacement. *Rev Chir Orthop Reparatrice Appar Mot*, **66**, 527–530.
- 25 Buchholz HW, Engelbrecht E, Siegel A (1973) Totale Sprunggelenks endoprothese Model St. George. *Chirurg*, **44**, 241–245.
- 26 Engelbrecht E (1975) Ankle endoprosthesis model “St.Georg”. *Z Orthop*, **113**, 546–548.
- 27 Hay SM, Smith TWD (1994) Total ankle arthroplasty: a long term review. *Foot*, **4**, 1–5.
- 28 Kempson GE, Freeman MA, Tuke MA (1975) Engineering considerations in the design of an ankle joint. *Biomed Eng*, **10**, 166–180.
- 29 Freeman MA, Kempson MA, Tuke MA (1979) Total replacement of the ankle with the ICLH prosthesis. *Int Orthop*, **2**, 237–331.
- 30 Alvine FG (2000) Total ankle arthroplasty. In Myerson MS (ed.) *Foot and Ankle Disorders*. Philadelphia: Saunders, 1085–1102.
- 31 Bolton-Maggs BG, Sudlow RA, Freeman MA (1985) Total ankle arthroplasty. A long-term review of the London Hospital experience. *J Bone Joint Surg*, **67B**, 785–790.
- 32 Waugh TR, Evanski PM, McMaster WC (1976) Irvine ankle arthroplasty: prosthetic design and surgical technique. *Clin Orthop*, **114**, 180–184.
- 33 Evanski PH, Waugh TR (1977) Management of arthritis of the ankle. An alternative of arthrodesis. *Clin Orthop*, **122**, 110–115.
- 34 Wynn AH, Wilde AH (1992) Long-term follow up of the Conaxial (Beck-Steffee) total ankle arthroplasty. *Foot Ankle*, **3**, 303–306.
- 35 Stauffer RN and Segal NM (1981) Total ankle arthroplasty: four years' experience. *Clin Orthop*, **160**, 217–221.
- 36 Kitaoka HB, Patzer GL, Strup DMI *et al.* (1994) Survivorship analysis of the Mayo total ankle arthroplasty. *J Bone Joint Surg*, **76A**, 974–979.
- 37 Kitaoka HB, Patzer GL (1996) Clinical results of the Mayo total ankle arthroplasty. *J Bone Joint Surg*, **78A**, 1658–1664.
- 38 Newton SEI (1982) Total ankle arthroplasty. Clinical study of fifty cases. *J Bone Joint Surg*, **64A**, 104–111.
- 39 Kirkup J (1985) Richard Smith ankle arthroplasty. *J R Soc Med*, **78**, 301–304.
- 40 Carlsson AS, Henricson A, Linde Lr, Nilsson JA, Redlund-Johnel L (2001) A 10-year survival analysis of 69 Bath and Wessex ankle replacements. *Foot Ankle Surg*, **71**, 39–44.
- 41 Jensen NC, Kroner K (1992) Total ankle joint replacement: a clinical follow-up. *Orthopedics*, **15**, 236–239.
- 42 Schill S, Biehl C, Thabe H (1998) Ankle prostheses. Mid-term results after Thompson-Richard sand STAR prostheses. *Orthopaede*, **27**, 183–187.

- 43 Wood PLR, Clough TM, Jari S (2000) Comparison of two total ankle replacements. *Foot Ankle Int*, **21**, 546–550.
- 44 Fevang BTS, Lie SA, Havelin LI, Brun JG, Skredderstuen A, Furnes O (2007) 257 ankle arthroplasties performed in Norway between 1994 and 2005. *Acta Orthop*, **78**, 575–583.
- 45 Pappas MJ, Buechel FF, DePalma AF (1976) Cylindrical total ankle joint replacement: surgical and biomechanical rationale. *Clin Orthop*, **118**, 82–92.
- 46 Buechel FF, Pappas MJ, Iorio LJ (1988) New Jersey low contact stress total ankle replacement: biomechanical rationale and review of 23 cementless cases. *Foot Ankle*, **8**, 279–290.
- 47 Hintermann B (2004) *Total Ankle Arthroplasty: Historical Overview, Current Concepts and Future Perspectives*. Wien, New York: Springer.
- 48 Feldman MH, Rockwood J (2004) Total ankle arthroplasty: a review of 11 current ankle implants. *Clin Podiatr Med Surg*, **21**, 393–406.
- 49 Buechel FF, Pappas MJ (1992) Survivorship and clinical evaluation of cementless, meniscal-bearing total ankle replacements. *Semin Arthroplasty*, **3**, 43–50.
- 50 US Food and Drug Administration Center for Devices and Radiological Health (2008) Summary of the Orthopaedic and Rehabilitation Devices Panel Meeting – 24 April 2007. Available at: <http://www.fda.gov/cdrh/panel/summary/ortho-04207.html> (Accessed 27 March 2008).
- 51 Pyevich MT, Saltzman CL, Callaghan JJ, Alvine FG (1998) Total ankle arthroplasty: a unique design. Two to twelve-year follow-up. *J Bone Joint Surg Am*, **80**, 1410–1420.
- 52 Knecht SI, Estin M, Callaghan JJ et al. (2004) The Agility total ankle arthroplasty. Seven to sixteen-year follow-up. *J Bone Joint Surg Am*, **86**, 1161–1171.
- 53 Alvine FG, Conti SF (2006) The AGILITY ankle: mid- and long-term results. *Orthopaede*, **2006**, **35**, 521–526.
- 54 Hurowitz EJ, Gould JS, Fleising GS, Fowler R (2007) Outcome analysis of Agility total ankle replacement with prior adjunctive procedures: two to six year follow up. *Foot Ankle Int*, **28**, 308–312.
- 55 Sprit AA, Assal M, Hansen ST Jr (2004) Complications and failure after total ankle arthroplasty. *J Bone Joint Surg*, **86A**, 1172–1179.
- 56 Kopp FJ, Patel MM, Deland JT, O'Malley MJ (2006) Total ankle arthroplasty with the Agility prosthesis: clinical and radiographic evaluation. *Foot Ankle Int*, **27**, 97–103.
- 57 Hosman AH, Mason RB, Hobbs T, Rothwell AG (2007) A New Zealand national joint registry review of 202 total ankle replacements followed for up to 6 years. *Acta Orthop*, **78**, 584–591.
- 58 Vienne P, Nothdurft P (2004) Agility total ankle replacement: indications, surgical technique and results. *Fuss Sprungg*, **2**, 17–28.
- 59 Coetzee JC (2007) Prospective outcome study on the Agility Total ankle replacement: minimum 3 year follow-up. AAOS Annual Meeting Podium Presentation 071.
- 60 Schubert JM, Patel S, Zarutsky E (2006) Perioperative complications of the Agility Total Ankle Replacement in 50 initial consecutive cases. *J Foot Ankle Surg*, **45**, 139–146.
- 61 www.inbone.com (Accessed 11 February 2008).
- 62 www.tornier-us.com (Accessed 8 February 2008).
- 63 Bonnin M, Judet T, Colombier JA, Buscayret F, Graveleau N, Piriou P (2004) Midterm results of the Salto total ankle prosthesis. *Clin Orthop Relat Res*, **424**, 6–18.
- 64 Rudigier J, Grundei H, Menzinger F (2001) Prosthetic replacement of the ankle in posttraumatic arthrosis: 10-year experience with cementless ESKA ankle prosthesis. *Eur J Trauma*, **27**, 66–74.
- 65 Rudigier J, Grundei H, Menzinger (2004) Total ankle replacement—14 year experience with the cementless ESKA ankle prosthesis. *Fuss Sprungg*, **2**, 65–75.
- 66 Rudigier J (2005) Ankle replacement by the cementless ESKA endoprosthesis. *Techn Foot Ankle Surg*, **4**, 125–136.
- 67 Takakura Y, Tanaka Y, Sugimoto K et al. (1990) Ankle arthroplasty. A comparative study of cemented metal and uncemented ceramic prostheses. *Clin Orthop*, **252**, 209–216.
- 68 Takakura Y, Tanaka Y, Kumai T et al. (2004) Ankle arthroplasty using three generations of metal and ceramic prostheses. *Clin Orthop*, **424**, 130–136.
- 69 Tanaka Y, Takakura Y (2006) The TNK ankle. Short- and mid-term results. *Orthopaede*, **35**, 546–551.

- 70 Nishikawa M, Tomita T, Fujii M *et al.* (2004) Total ankle replacement in rheumatoid arthritis. *Int Orthop*, **28**, 123–126.
- 71 Nagashima M, Takahashi H, Kakumoto S, Miyamoto Y, Yoshino S (2004) Total ankle arthroplasty for deformity of the foot in patients with rheumatoid arthritis using the TNK ankle system: clinical results of 21 cases. *Mod Rheumatol*, **14**, 48–53.
- 72 Buechel FF, Pappas MJ. Biomechanics and rationale: the Buechel–Pappas total ankle replacement system. www.endotec.com (Accessed 12 February 2008).
- 73 Buechel FF Sr, Buechel FF Jr, Pappas MJ (2004) Twenty-year evaluation of cementless mobile-bearing total ankle replacements. *Clin Orthop Rel Res*, **424**, 19–26.
- 74 San Giovanni TP, Keblish DJ, Thomas WH, Wilson MG (2006) Eight-year results of a minimally constrained total ankle arthroplasty. *Foot Ankle Int*, **27**, 418–426.
- 75 Doets HC, Brand R, Nelissen RG (2006) Total ankle arthroplasty in inflammatory joint disease with use of two mobile-bearing designs. *J Bone Joint Surg*, **88A**, 1272–1284.
- 76 Ali MS, Higgins GA, Mohamed M (2007) Intermediate results of Buechel–Pappas unconstrained uncemented total ankle replacement for osteoarthritis. *J Foot Ankle Surg*, **46**, 16–20.
- 77 Kofoed H (1995) Cylindrical cemented ankle arthroplasty. *Foot Ankle Int*, **16**, 474–479.
- 78 Kofoed H, Sorensen TS (1998) Ankle arthroplasty for rheumatoid arthritis and osteoarthritis. *J Bone Joint Surg*, **80B**, 328–332.
- 79 Kofoed H (2004) Scandinavian Total Ankle Replacement (STAR). *Clin Orthop Rel Res*, **424**, 73–80.
- 80 Henricson A, Skoog A, Carlsson A (2007) The Swedish Ankle Arthroplasty Register: an analysis of 531 arthroplasties between 1993 and 2005. *Acta Orthop*, **78**, 569–574.
- 81 Henricson A, Agren PH (2007) Secondary surgery after total ankle replacement. The influence of preoperative hindfoot alignment. *Foot Ankle Surg*, **13**, 41–44.
- 82 Anderson T, Montgomery F, Carlsson A (2003) Uncemented STAR total ankle prosthesis. *J Bone Joint Surg*, **85A**, 321–329.
- 83 Carlsson A (2006) Single- and double-coated star total ankle replacements: a clinical and radiographic follow-up study of 109 cases. *Orthopaede*, **35**, 527–532.
- 84 Natens P, Dereymaeker G, Abbara M, Matricali G (2003) Early results after four years experience with the S.T.A.R. uncemented total ankle prosthesis. *Acta Orthop Belg*, **69**, 49–58.
- 85 Wood PLR, Deakin S (2003) Total ankle replacement: the results in 200 ankles. *J Bone Joint Surg*, **85B**, 34–41.
- 86 Wood PLR, Prem H, Sutton C (2008) Total ankle replacement. Medium-term results in 200 Scandinavian total ankle replacements. *J Bone Joint Surg*, **90B**, 605–609.
- 87 Valderabano V, Hintermann B, Dick W (2004) Scandinavian Total Ankle Replacement. *Clin Orthop Rel Res*, **424**, 47–56.
- 88 Lodhi Y, McKenna J, Herron M, Stephens MM (2004) Total ankle replacement. *Irish Med J*, **97**, 104–105.
- 89 Hagena FW, Christ R, Kettrukat M (2003) Total ankle arthroplasty. *Fuss Sprungg*, **1**, 48–55.
- 90 Christ RM, Hagena FW (2005) Complications and revision surgery in total ankle arthroplasty. *Fuss Sprungg*, **3**, 112–121.
- 91 Murnaghan JM, Warnock DS, Henderson SA (2005) Total ankle replacement. Early experience with STAR prosthesis. *Ulster Med J*, **74**, 9–13.
- 92 Kumar A, Dhar S (2007) Total ankle replacement: early results during learning period. *Foot Ankle Surg*, **13**, 19–23.
- 93 Schutte BG, Louwerens MD (2008) Short-term results of our first 49 Scandinavian Total Ankle Replacements. *Foot Ankle Int*, **29**, 124–127.
- 94 Dhar S, Hobson S (2008) The STAR total ankle replacement: prospective, medium term results of 165 cases. AAOS 75th Annual Meeting Podium Presentation, No 267. San Francisco, CA.
- 95 Schernberg F (1998) Current results of ankle arthroplasty: European multi-center study of cementless ankle Arthroplasty. In Kofoed H (ed.) *Current Status of Ankle Arthroplasty*. New York: Springer-Verlag, 41–46.

- 96 Bonnin M, Judet T, Piriou P *et al.* (2006) Total ankle prosthesis: five to eight year results. Presented at the American Orthopaedic Foot and Ankle Society 22nd Annual Summer Meeting, 14–16 July 2006. La Jolla, CA.
- 97 Mendolia G, Talus Group. The Ramses ankle replacement: design–surgical technique result, results in first 38 cases. The French Orthopedic Web Journal. Available at: www.maitrise-orthop.com (Accessed 28 January 2007).
- 98 Mendolia G, Coillard JY, Cermolacce C, Determe P (The Talus Group) (2005) Long-term (10 to 14 years) results of the Ramses total ankle arthroplasty. *Techn Foot Ankle Surg*, **4**, 160–173.
- 99 Hintermann B, Valderrabano V, Dereymaeker G, Dick W (2004) The HINTEGRA ankle: rationale and short-term results of 122 consecutive ankles. *Clin Orthop Relat Res*, **424**, 57–68.
- 100 Company announces Hintegra Total Ankle Prosthesis implantations in Brazil. Available at: www.newsrx.com (Assessed 2 February 2008).
- 101 Hintermann B, Valderrabano V, Knupp M, Horisberger M (2006) The HINTEGRA ankle: short- and mid-term results. *Orthopaede*, **35**, 533–545.
- 102 Hintermann B, Barg A, Knupp M (2008) Mid- to long-term survivorship of HINTEGRA total ankle. AAOS 75th Annual Meeting Podium Presentations, San Francisco, CA.
- 103 Hintermann B, Barg A (2008) Revision arthroplasty for failed total ankles. AAOS 75th Annual Meeting Podium Presentations, San Francisco, CA.
- 104 Knupp M, Hintermann B (2008) Conversion of ankle arthrodesis into total ankle arthroplasty. AAOS 75th Annual Meeting Podium Presentations, San Francisco, CA.
- 105 Asencio JG (2001) The A.E.S .total ankle. Proceedings of the International Day of Foot and Ankle Surgery. Nimes (France): Societe Francaise du pied, p 20–21.
- 106 Patsalis T (2004) The AES ankle prosthesis indication—technique and preliminary results. *Fuss Sprungg*, **2**, 38–44.
- 107 Strudee SW, Harris NJ, Farndon M (2006) A prospective clinical and radiological review of 137 AES total ankle replacements over a 4-year period in a single centre. Presented at the BOFAS Meeting in Crewe, UK. Available at: www.bofas.org.uk (Accessed 11 February 2008).
- 108 Huber M, Rippstein P (2006) The step from arthrodesis to arthroplasty—early results with the Mobility ankle prosthesis. Presented in European Rheumatoid Arthritis Surgical Society. Pfäffikon, Switzerland, 25–27 May 2006.
- 109 www.clinicaltrials.gov (Assessed 3 February 2008).
- 110 Leardini A, O'Connor JJ, Catani F, Giannini S (2004) Mobility of the human ankle and the design of total ankle replacement. *Clin Orth Rel Res*, **424**, 39–46.
- 111 BOX Total Ankle Replacement (www.finsbury.org) (Accessed 28 January 2008).
- 112 Leardini A, O'Connor JJ, Catani F, Giannini S (1999) Kinematics of the human ankle complex in passive flexion; a single degree of freedom system. *J Biomech*, **32**, 111–118.
- 113 Leardini A, O'Connor JJ, Catani F, Giannini S (1999) A geometric model of the human ankle joint. *J Biomech*, **32**, 585–591.
- 114 Catani F, Romagnoli M, Bianchi L *et al.* (2008) Intra- and post-operative validation measurements from a new design of ankle prosthesis. 75th AAOS Annual Meeting Poster Presentations, P215, San Francisco, CA.
- 115 Richter M, Zech S, Westphal R, Klimesch Y, Gosling T (2007) Robotic cadaver testing of a new total ankle prosthesis model (German Ankle System). *Foot Ankle Int*, **28**, 1276–1286.
- 116 The ZENITH total ankle replacement system. Available at: www.corin.co.uk (Accessed 11 February 2008).
- 117 Tillmann K (2003) Endoprothetik am oberen Sprunggelenk *Orthopaede*, **32**, 179–187.
- 118 Schill S, Rehart S, Fink B (2006) Endoprothetik am rheumatischen oberen Sprunggelenk. *Fuss Sprungg*, **4**, 98–105.
- 119 CCI Evolution, mobile bearing ankle prosthesis. Available at: <http://www.vanstraten.net> (Accessed 22 September 2008).
- 120 Deland JT, Morris GD, Sung IH (2000) Biomechanics of the ankle joint. A perspective on total ankle replacement. *Foot Ankle Clin*, **5**, 747–759.

- 121 Siegler S, Chen J, Schneck CD (1988) The three-dimensional kinematics and flexibility characteristics of the human ankle and Subtalar joints. Part I. *Kinematics*, *J Biomech Eng*, **110**, 364–373.
- 122 Lundberg A, Svennson OK, Bylund C *et al.* (1989) Kinematics of the ankle/foot complex. Part 3: influence of the leg rotation. *Foot Ankle*, **9**, 304–309.
- 123 Vickerstaff JA, Miles AW, Cunningham JL (2007) A brief history of ankle replacement and a review of the current status. *Med Eng Phys*, **29**, 1056–1064.
- 124 Conti SF, Wong YS (2001) Complications of total ankle replacement. *Clin Orthop*, **391**, 105–114.
- 125 Hvid I, Rasmussen O, Jensen NC, Nielsen S (1985) Trabecular bone strength profiles at the ankle joint. *Clin Orthop*, **199**, 306–312.
- 126 Nelissen RG, Doets HC, Valstar ER (2006) Early migration of the tibial component of the Buechel-Pappas total ankle prosthesis. *Clin Orthop Relat Res*, **448**, 146–151.
- 127 Siegler S, Udupa JK, Ringleb SI *et al.* (2005) Mechanics of the ankle and subtalar joints revealed through a 3D quasi-static stress MRI technique. *J Biomech*, **38**, 567–578.
- 128 Sheehan FT, Seisler AR, Siegel KL (2007) *In vivo* talocrural and subtalar kinematics: a non-invasive 3D dynamic MRI study. *Foot Ankle Int*, **28**, 323–335.
- 129 Su EP, Kahn B, Figgie MP (2004) Total ankle replacement in patients with rheumatoid arthritis. *Clin Orthop Rel Res*, **424**, 32–38.