

Rapid communication

HMG-CoA reductase inhibitor attenuates experimental autoimmune myocarditis through inhibition of T cell activation

Ryoko Wakizono Azuma, Jun-ichi Suzuki, Masahito Ogawa, Hideki Futamatsu, Noritaka Koga, Yasuyuki Onai, Hisanori Kosuge, Mitsuaki Isobe*

Department of Cardiovascular Medicine, Tokyo Medical and Dental University, 1-5-45 Yushima, Bunkyo-ku, Tokyo 113-8519, Japan

Received 8 June 2004; received in revised form 28 August 2004; accepted 16 September 2004

Available online 18 October 2004

Time for primary review 17 days

Abstract

Objective: This study tested the hypothesis that 3-hydroxy-3-methyl-glutaryl coenzyme A (HMG-CoA) reductase inhibitor affects T cell-mediated autoimmunity through inhibition of nuclear factor- κ B (NF κ B) and reduces the severity of experimental autoimmune myocarditis (EAM).

Methods: EAM was induced in Lewis rats by immunization with myosin. High-dose or low-dose fluvastatin or vehicle was administered orally for 3 weeks to rats with EAM.

Results: Fluvastatin reduced the pathophysiological severity of myocarditis. Fluvastatin inhibited expression of NF κ B in the nuclei of myocardium in EAM. Fluvastatin reduced production of Th1-type cytokines, including interferon (IFN)- γ and interleukin (IL)-2, and inhibited expression of inflammatory cytokine mRNAs in the myocardium. Infiltration of CD4-positive T cells into the myocardium and T cell proliferative responses were suppressed by fluvastatin. Plasma lipid levels did not differ between the groups.

Conclusions: Fluvastatin ameliorates EAM by inhibiting T cell responses and suppressing Th1-type and inflammatory cytokines via inactivation of nuclear factor- κ B, and this activity is independent of cholesterol reduction.

© 2004 European Society of Cardiology. Published by Elsevier B.V. All rights reserved.

Keywords: HMG-CoA reductase inhibitor; Myocarditis; Nuclear factor- κ B; Cytokine; T cell response; Inflammation; Immunology

1. Introduction

Myocarditis is characterized by myocyte necrosis and degeneration with mononuclear cell infiltration [1]. Myocarditis can lead to sudden death [2], and 5–10% of patients with myocarditis may develop dilated cardiomyopathy (DCM) [3,4], a major cause of morbidity and mortality among young adults [5]. Because the pathogenesis of myocarditis remains unclear, treatment is not directed at the disease itself but instead at managing the symptoms [6]. However, there is substantial evidence

suggesting that autoimmune responses to heart antigens, particularly cardiac myosin, after viral infection contribute to the disease process [6,7].

Experimental autoimmune myocarditis (EAM) in rats is an animal model of human giant cell myocarditis and postmyocarditis DCM [8]. EAM in rats is reported to be a CD4-positive T cell-mediated disease and is thought to be related to Th1 responses in the acute phase [9]. Cytokines secreted from activated T cells are recognized as having important roles in the pathogenesis of EAM [10].

A recent study revealed that nuclear factor- κ B (NF κ B) plays a crucial role in EAM in rats [11]. Activation of NF κ B leads to transcription of adhesion molecules, cytokines, and chemokines and activates T cells, which promote the inflammation involved in myocardial injury in EAM

* Corresponding author. Tel.: +81 3 5803 5951; fax: +81 3 5803 0238.

E-mail address: isobemi.cvm@tmd.ac.jp (M. Isobe).

[11,12]. Therefore, blockade of NF κ B inhibits T cell activation and production of essential cytokines [12,13]. NF κ B has also been reported to affect EAM through regulation of a number of genes necessary for T cell responses [11,14].

Statins are inhibitors of 3-hydroxy-3-methyl-glutaryl coenzyme A (HMG-CoA) reductase and are widely used to reduce lipid levels in blood; they have also been shown to reduce cardiovascular morbidity and mortality [15,16]. Because the cardiovascular protective effects of statins have also been observed in patients with normal cholesterol levels, it has been proposed that statins have a broad range of cholesterol-independent protective effects [17,18]. Statins are reported to ameliorate inflammatory diseases in murine autoimmune models by inhibiting Th1 responses [19] and to influence cell activation through inhibition of NF κ B [20,21]. Therefore, statins could be useful for modulating T cell immunity through inhibition of NF κ B in EAM. In this study, we found that fluvastatin ameliorated EAM by inhibiting T cell activation and suppressing inflammatory cytokines via inactivation of NF κ B. These effects extended beyond reduction of cholesterol levels.

2. Methods

2.1. Induction of EAM in rats

Acute EAM was induced in 7-week-old Lewis rats by immunization with porcine cardiac myosin as previously described [22].

2.2. Treatment

Fluvastatin was kindly provided by Tanabe Seiyaku (Osaka, Japan). Rats with EAM were divided into three groups. High-dose fluvastatin (7.5 mg/kg per day, group H, $n=6$), low-dose fluvastatin (3.75 mg/kg per day, group L, $n=6$), or vehicle (group C, $n=6$) was mixed with the rat chow for 3 weeks from day 0 to day 21 after immunization. We examined plasma total cholesterol, triglyceride, and fluvastatin levels in the three groups at day 21. All animals were maintained in accordance with the Guide for the Care and Use of Laboratory Animals published by the U.S. National Institutes of Health (NIH Publication No. 85–23, revised 1996). The protocol was approved by the Animal Research Committee of Tokyo Medical and Dental University.

2.3. Echocardiography

Transthoracic echocardiography was performed on animals on day 21. An echocardiographic machine with a 7.5-MHz transducer (Nemio, Toshiba, Tokyo, Japan) was used for M-mode left ventricular echocardiographic recordings. Two-dimensional targeted M-mode echocardiograms were obtained along the short axis of the left

ventricle at the level of the papillary muscles. Left ventricular diameter at diastole (LVDD) and at systole (LVDS) were determined from M-mode echocardiograms over three consecutive cardiac cycles according to the leading edge method of the American Society for Echocardiography [23,24], and fractional shortening (LVFS) was derived.

2.4. Histological examination

Peak inflammation induced by macrophages and CD4-positive T cells is expected to occur in EAM around day 21 after immunization [10]. Thus, we killed the animals on day 21. The hearts were harvested immediately, sliced transversely, and stained with hematoxylin and eosin. The area of myocardium and surrounding tissue containing inflammatory cells and myocardial necrosis, and thus affected by myocarditis, was determined with a computer-assisted analyzer (Scion Image Beta 4.0.2, Scion, Frederick, MD). The myocarditis-affected area ratio (affected area/total area expressed as a percentage) was calculated as described previously [22]. All data were obtained blindly by two independent observers and averaged.

2.5. Immunohistochemistry

Midventricular slices of the heart were embedded in the OCT compound. Immunohistochemistry for surface markers was performed as described previously [25]. Primary antibodies were anti-CD4 (OX35, PharMingen, San Diego, CA) and anti-CD8 (OX8, PharMingen). We then classified the CD4- or CD8-positive cell area ratios (anti-CD4- or -CD8-positive cell infiltration area/total area as a percentage) into the following five grades: 1, 0–10%; 2, 10–30%; 3, 30–50%; 4, 50–80%; 5, more than 80%. The mean score of the three sections was recorded as the immunohistochemistry score. Two observers scored the immunohistochemistry scores blindly.

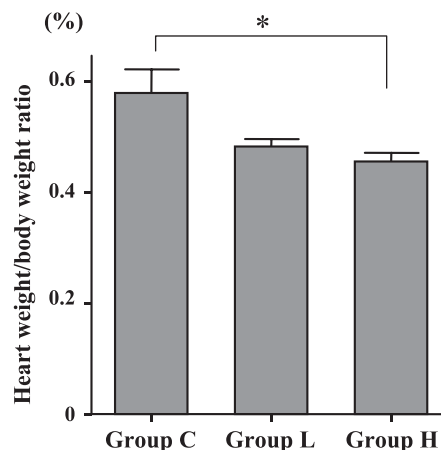


Fig. 1. Heart weight/body weight ratio. The heart weight/body weight ratio was significantly lower in group H than in group C. * $P<0.05$.

2.6. Western blotting

The myocardial lysates (10 µg protein/lane) were separated by electrophoresis on 12% SDS-PAGE and then transferred electrophoretically onto nitrocellulose membrane. The membrane was incubated with primary antibody against NFκB p65 (Santa Cruz Biotechnology, Santa Cruz, CA) or against actin (Chemicon International, Temecula, CA). The blot was reacted with secondary antibody (Amersham Biosciences, Piscataway, NJ) and developed with ECL

reagent (Amersham Biosciences). Enhanced chemiluminescence was detected with the LAS-1000 (Fujifilm, Tokyo, Japan).

2.7. Ribonuclease protection assay (RPA)

Total mRNA was extracted from myocardium with TRIzol (Life Technologies, Rockville, MD), and cytokine mRNA levels were measured by RPA as described previously [22].

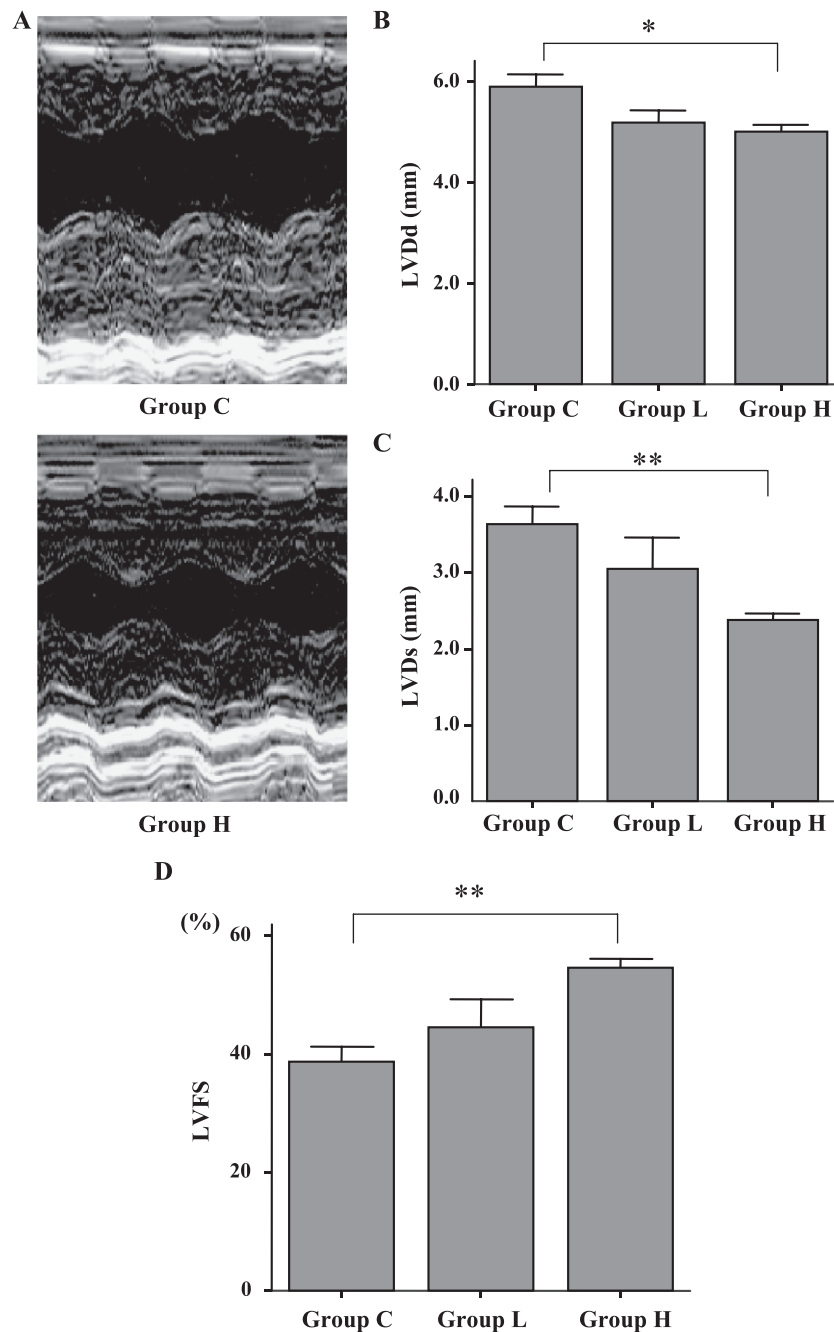


Fig. 2. Echocardiographic findings. (A) M-mode echocardiograms from group C and group H rats on day 21. LVDD (B), LVDs (C), and LVFS (D) on day 21. * $P < 0.05$, ** $P < 0.01$.

2.8. T cell proliferation assay

Spleen cells were isolated from rats with myocarditis on day 18. Cells (5×10^5 /well) were cultured in 96-well plates with 50 $\mu\text{g}/\text{mL}$ purified porcine heart myosin (Sigma, St. Louis, MO). Stock solutions of fluvastatin sodium (Tanabe Seiyaku) were dissolved in distilled water. Fluvastatin sodium was added to each well at various concentrations. Cultures were incubated at 37 °C under 5% CO_2 for 3 days. T cell proliferation was assessed by MTT assay with Cell Counting Kit-8 (Dojindo, Tokyo, Japan). Cell proliferation was expressed as the optical density [26].

2.9. Enzyme-linked immunosorbent assay (ELISA)

Supernatants were collected from cultures used for T cell proliferation assays. Concentrations of interferon (IFN)- γ , interleukin (IL)-2, IL-4, and IL-10 were determined with an ELISA kit (BioSource International, Camarillo, CA) according to the manufacturer's instructions.

2.10. Statistical analysis

Values are given as mean \pm S.E.M. Results were compared between groups by ANOVA followed by Scheffé's

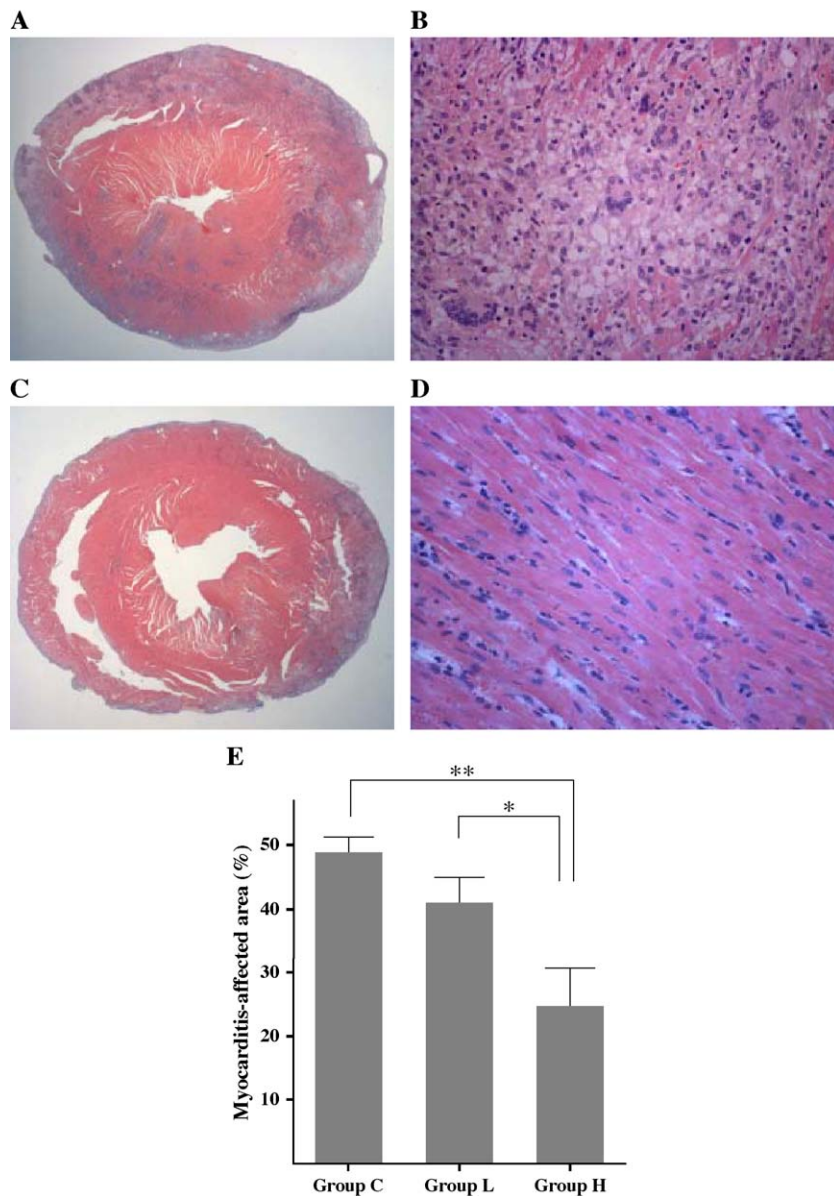


Fig. 3. Representative cross-sections of hearts. (A) Histopathologic findings of specimen obtained from the midportion of the left ventricle of a control rat (group C). (B) Severe myocarditis lesion, including giant cells (group C). (C) Cross-section of a heart from a rat treated with high-dose fluvastatin (group H). (D) Little infiltration by inflammatory cells (group H). (E) Myocarditis-affected area ratios in the respective groups. Original magnification in (A) and (C) is $\times 10$. Original magnification in (B) and (D) is $\times 400$. * $P < 0.05$, ** $P < 0.01$.

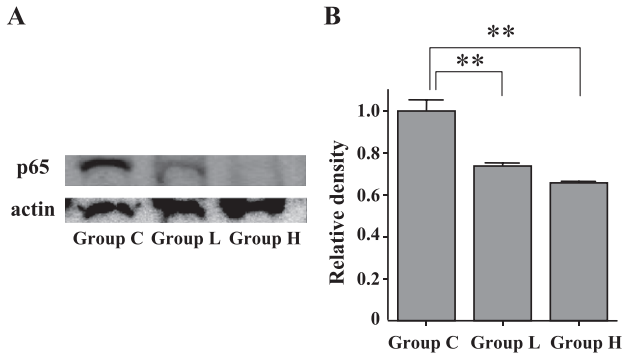


Fig. 4. Expression of nuclear p65 protein in myocardium by Western blotting. (A) Levels of nuclear p65 protein from myocardium in group C, group L, and group H. (B) Levels of nuclear p65 from myocardium normalized to those of group C. $**P<0.01$.

test (SPSS, Chicago, IL). Differences were considered statistically significant at $P<0.05$.

3. Results

3.1. Improvement in heart weight/body weight ratio and cardiac function; plasma total cholesterol, triglyceride, and fluvastatin concentrations

No rat died prior to day 21. On day 21, the hearts of group C rats were enlarged and contained large grayish areas with

massive pericardial effusion. The hearts of group H rats were slightly enlarged and showed small grayish areas on the surface. The heart weight/body weight ratio of group H was significantly lower than that of group C (Fig. 1). Echocardiography revealed that LVDD, LVDs, and LVFS in group H were improved significantly compared with those in group C (Fig. 2A to D). The plasma total cholesterol level was 70.0 ± 4.5 ng/mL in group C, 70.6 ± 6.0 ng/mL in group L, and 72.5 ± 1.4 ng/mL in group H. There was no significant difference in the plasma total cholesterol level between the groups. Similar findings were observed for the plasma triglyceride level (60.1 ± 7.2 ng/mL in group C, 59.6 ± 6.8 ng/mL in group L, and 56.5 ± 3.2 ng/mL in group H). The plasma fluvastatin concentration did not differ significantly between group L and group H (58.7 ± 19.7 ng/mL and 84.7 ± 11.6 ng/mL, respectively).

3.2. Reduction of the myocarditis-affected areas by fluvastatin

Severe inflammatory lesions were observed in the hearts of group C rats (Fig. 3A). These lesions were composed of extensive myocardial necrosis and showed infiltration by mononuclear cells, polymorphonuclear neutrophils, and multinucleated giant cells (Fig. 3B). In contrast, hearts of group H rats showed little infiltration by inflammatory cells and little myocardial necrosis (Fig. 3C and D). The ratio of

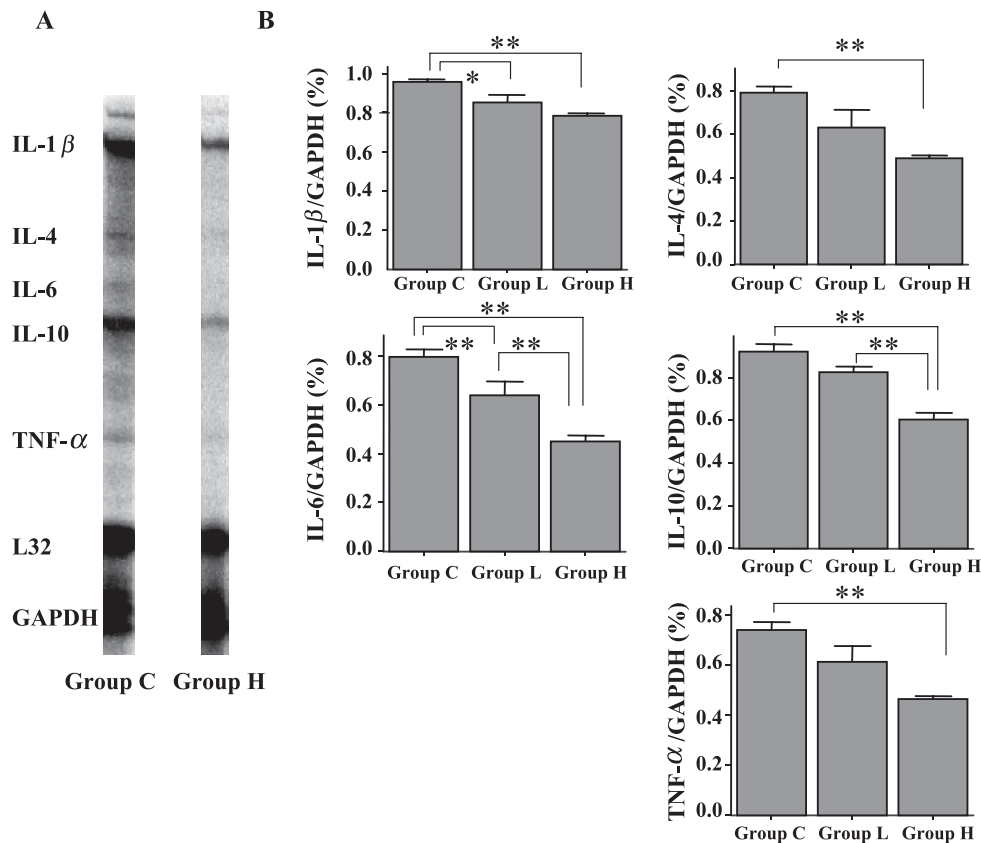


Fig. 5. Expression of cytokine mRNAs in heart. (A) Representative RPA findings on day 21 in group H and group C. (B) Levels of mRNA normalized to those of GAPDH. Data are the mean of six independent experiments. $*P<0.05$, $**P<0.01$.

the myocarditis-affected area was significantly smaller in group H than in group C (Fig. 3E). The effect of fluvastatin tended to be dose-dependent, and the ratio of the myocarditis-affected area differed significantly between group L and group H (Fig. 3E).

3.3. Inhibition of activation of myocardial NF κ B in EAM

To evaluate NF κ B activity, we examined expression of nuclear p65 protein in myocardium of rats with EAM by Western blotting (Fig. 4A). As shown in Fig. 4B, p65 levels in the nuclei of myocardium in group L ($n=6$) and group H ($n=6$) were significantly lower than those in group C. The effect of fluvastatin tended to be dose-dependent, but the difference between group L and group H was not statistically significant.

3.4. Suppression of expression of mRNAs for inflammatory cytokines

Levels of mRNAs encoding IL-4, IL-6, IL-10, IL-1 β , and tumor necrosis factor (TNF)- α were significantly lower in group H than in group C (Fig. 5A and B).

3.5. Reduction of Th1-type cytokines by fluvastatin

We performed ELISA of supernatants collected from T cell proliferation assays. Production of Th1-type cytokines,

including IFN- γ and IL-2, was significantly lower in the fluvastatin group (10^{-6} mol/L; $n=4$ for each cytokine) than in the control group ($n=4$; Fig. 6A and B). Production of Th2-type cytokines, including IL-4 and IL-10, in the fluvastatin group (10^{-6} mol/L; $n=4$ for each cytokine) was also lower than that in the control group ($n=4$; Fig. 6C and D).

3.6. Immunohistochemistry findings

The immunohistochemistry score of infiltrating CD4-positive T cells was lower in group H than in group C (Fig. 7A, B, and E). The score for infiltrating CD8-positive T cells did not differ significantly between group C and group H (Fig. 7C, D, and F).

3.7. Suppression of cell proliferation

We used cell proliferation assays to evaluate the antiinflammatory effects of fluvastatin on antigen-induced proliferation of T cells. T cell proliferation was suppressed by fluvastatin in a dose-dependent manner (Fig. 8).

4. Discussion

In this study, fluvastatin reduced the histological and functional severity of EAM. This reduction was not

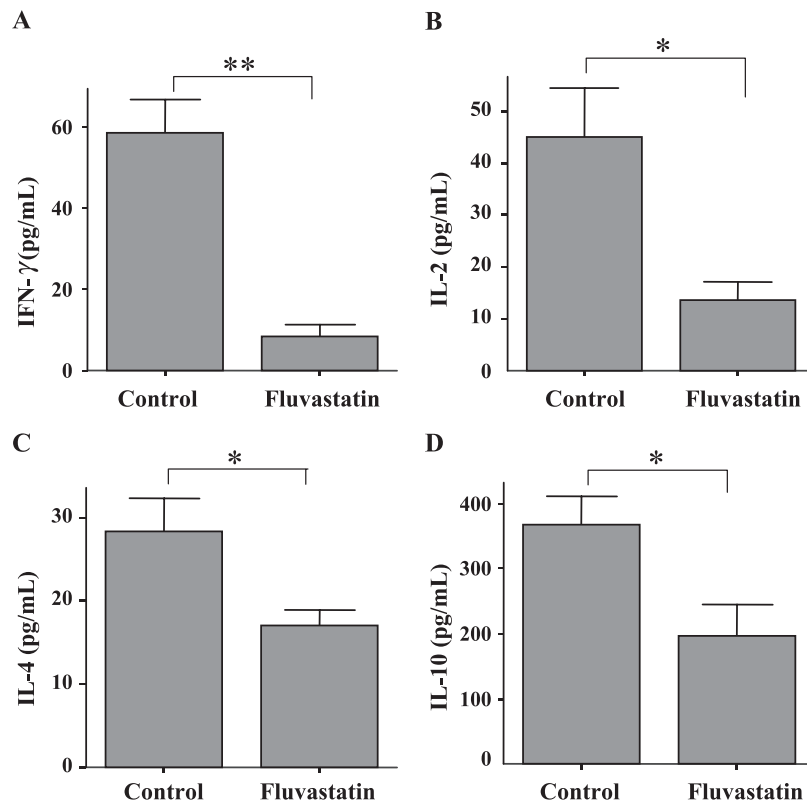


Fig. 6. ELISA. (A) and (B) Splenocytes from rats treated with fluvastatin produced significantly less Th1-type cytokines (IFN- γ and IL-2) after restimulation with cardiac myosin than were produced in the control group. (C) and (D) Levels of Th2-type cytokines (IL-4 and IL-10) in splenocytes from rats treated with fluvastatin were lower than those of the control group. * $P<0.05$, ** $P<0.01$.

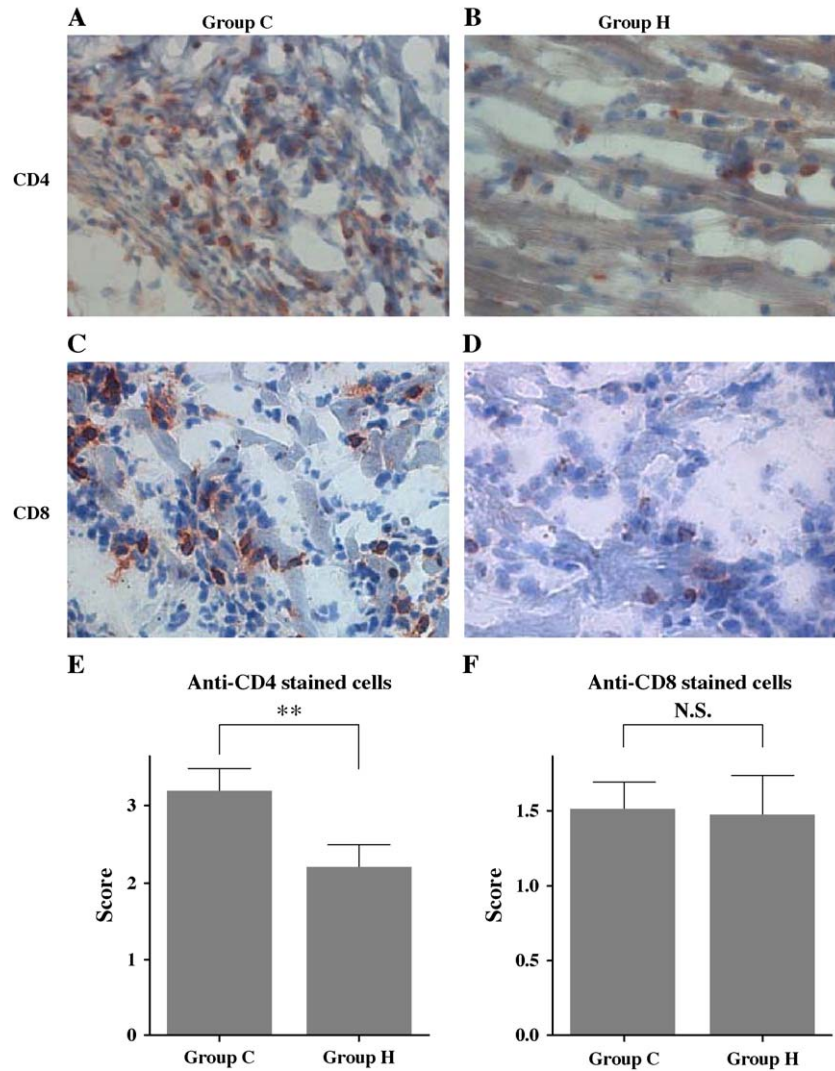


Fig. 7. Immunohistochemistry for T cell subsets. (A) CD4 epitopes stained (reddish-brown) in group C. (B) CD4 staining in group H. (C) CD8 staining (reddish-brown) in group C. (D) CD8 staining in group H [(A) to (D), magnification $\times 400$]. (E) CD4-positive cell area ratios (number of anti-CD4-positive cells in infiltration area/entire area as a percentage). (F) CD8-positive cell area ratios (number of anti-CD8-positive cells in infiltration area/entire area as a percentage). Scores were assigned as follows: 1, 0–10%; 2, 10–30%; 3, 30–50%; 4, 50–80%; 5, more than 80%. ** $P < 0.01$, N.S., not significant.

associated with plasma lipid concentrations but was associated with cytokine production in response to antigen stimulation both in vivo and in vitro. We investigated possible involvement of NF κ B in statin-induced amelioration of EAM.

NF κ B is a rapid-response transcription factor that regulates expression of genes encoding cytokines, chemokines, and adhesion molecules [13]. Blockade of NF κ B inhibits activation of T cells [12,13]. NF κ B exists in the cytoplasm as a heterodimer of a 50-kDa (p50) and a 65-kDa (p65) subunit associated with an inhibitory protein of the I κ B family. When cells are stimulated, the I κ B inhibitory protein is phosphorylated, and it dissociates from the NF κ B heterodimer. Free NF κ B then translocates into the nucleus [13]. A previous study revealed that NF κ B plays a pivotal role in the regulation of myocardial damage in EAM [11]. In addition, recent studies suggest that statins possess antiinflammatory proper-

ties that involve inhibition of NF κ B [20]. Therefore, we investigated the effect of fluvastatin on the activation of NF κ B as reflected by p65 in myocardium with EAM. We found by Western blotting that fluvastatin inhibited expression of p65 in the nuclei of myocardium with EAM.

NF κ B increases expression of the genes encoding many cytokines in inflammatory diseases [13]. NF κ B binding sequences have been found in the promoter regions of cytokine genes associated with T cell activation and inflammatory responses, including IL-2, IL-6, TNF- α , and IL-2 receptor [12]. The proinflammatory cytokines IL-1 β and TNF- α both activate and are activated by NF κ B [13]. In the pathogenesis of EAM, cytokines play an important role. During the inflammatory phase of EAM, Th1-type cytokines and proinflammatory cytokines, including IL-2, IFN- γ , IL-1 β , and TNF- α , are produced [10]. Suppression of proinflammatory cytokines, such as IL-6, IL-1 β , and TNF- α , that

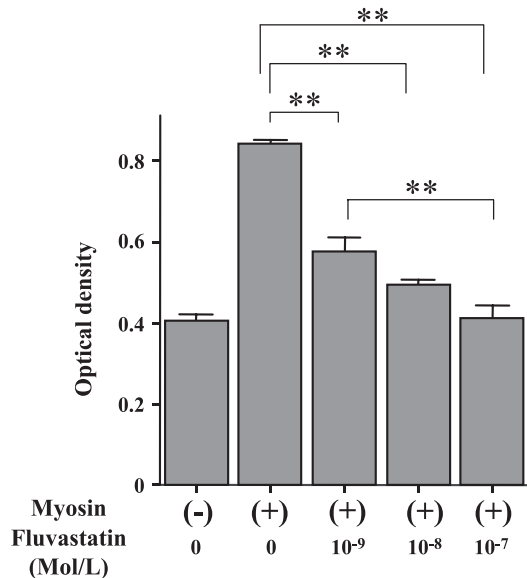


Fig. 8. Effects of fluvastatin on antigen-induced proliferation of splenocytes. Splenocytes were isolated on day 18 from rats with EAM. Various concentrations of fluvastatin sodium were added to each well in the fluvastatin group. Cultures were incubated for 3 days. Fluvastatin suppressed T cell proliferation. ** $P < 0.01$.

produce Th1-type cytokines prevents development of EAM [27]. This study shows that fluvastatin decreases expression of proinflammatory cytokine mRNAs, including those for IL-6, IL-1 β , and TNF- α . Our findings are consistent with those of previous studies showing that IL-6, IL-1 β , and TNF- α are inhibited by statins [28–30]. In this study, production of Th1-type cytokines, including IFN- γ and IL-2, was inhibited by fluvastatin, but this was not accompanied by an increase in production of IL-4 and IL-10, which are Th2-type cytokines. This result contrasts with reports that atorvastatin increased Th2 response while suppressing Th1 response in an experimental encephalomyelitis model [31,32]. Our result is consistent with previous reports that statin suppresses Th2-type cytokines as well as Th1-type cytokines in murine allergic asthma [33]. Some studies have also shown that a decrease in Th1-type cytokines is not associated with increased Th2-type cytokines in murine models treated with statins [18,19]. In our present study, the antiinflammatory effect of fluvastatin was mediated at least in part through suppressive T cell activity unrelated to suppression and augmentation of Th1 and Th2 responses.

In addition to the findings that CD4-positive T cell infiltration was decreased by fluvastatin, we observed in vitro that myosin-specific T cell proliferation was decreased by fluvastatin in a dose-dependent manner. These results suggest that fluvastatin affects activation and proliferation of T cells, especially CD4-positive T cells, and ameliorates EAM. These results are consistent with those of a recent study showing that statin affects T cell responses in a murine model [19].

The results of this study suggest that the effects of fluvastatin on EAM may be associated with inhibition of

NF κ B activation, which might result in the inactivation of T cells and the reduction of inflammatory cytokine levels. Although statins suppress NF κ B through inhibition of I κ B α phosphorylation [20], we were unable to detect phosphorylated I κ B α in this study, probably due to its fast turnover and degeneration in vivo [34].

The doses of fluvastatin used in this study were high relative to those used in clinical trials. However, the plasma fluvastatin concentration in our rats was lower than that observed in humans after oral administration of fluvastatin (40 mg/day) [35]. In addition, the fluvastatin doses used in this study are comparable to those commonly used in rat and mouse studies [36,37] because there is rapid up-regulation of HMG-CoA reductase in response to statin treatment in rodents [38].

It is notable that no significant reduction in plasma lipids was observed in our study. The rats used in our study were normocholesterolemic. It has been reported that plasma lipids do not change in normocholesterolemic rats treated with statins [36,37], which is consistent with our present result. Additionally, this study indicates that the immunomodulatory effects of fluvastatin in EAM occur at doses below the optimal lipid-lowering dose required in normocholesterolemic rats.

This study showed for the first time that fluvastatin reduces the severity of EAM in rats. This effect includes improved cardiac function and is associated with suppression of T cell response along with reduction of Th1-type cytokines and myocardial inflammatory cytokines, possibly through inhibition of NF κ B activation. These beneficial effects of fluvastatin in EAM extend beyond lowering of lipid concentrations. Thus, fluvastatin could have therapeutic potential for myocarditis in humans. Further studies are needed to clarify and evaluate the clinical usefulness of fluvastatin for treatment of myocarditis.

Acknowledgements

This study was supported by grants from the Vehicle Racing Commemorative Foundation and the Organization for Pharmaceutical Safety and Research. We thank Noriko Tamura for excellent technical assistance.

References

- [1] Pisani B, Taylor DO, Mason JW. Inflammatory myocardial diseases and cardiomyopathies. *Am J Med* 1997;102:459–69.
- [2] Feldman AM, McNamara D. Myocarditis. *N Engl J Med* 2000;343:1388–98.
- [3] Kawai C. From myocarditis to cardiomyopathy: mechanisms of inflammation and cell death: learning from the past for the future. *Circulation* 1999;99:1091–100.
- [4] Parrillo JE, Aretz HT, Palacios I, Fallon JT, Block PC. The results of transvenous endomyocardial biopsy can frequently be used to diagnose myocardial diseases in patients with idiopathic heart failure.

- Endomyocardial biopsies in 100 consecutive patients revealed a substantial incidence of myocarditis. *Circulation* 1984;69:93–101.
- [5] Drory Y, Turetz Y, Hiss Y, Lev B, Fisman EZ, Pines A, et al. Sudden unexpected death in persons less than 40 years of age. *Am J Cardiol* 1991;68:1388–92.
 - [6] Brown CA, O'Connell JB. Myocarditis and idiopathic dilated cardiomyopathy. *Am J Med* 1995;99:309–14.
 - [7] Lauer B, Padberg K, Schultheiss HP, Strauer BE. Autoantibodies against human ventricular myosin in sera of patients with acute and chronic myocarditis. *J Am Coll Cardiol* 1994;23:146–53.
 - [8] Kodama M, Matsumoto Y, Fujiwara M, Masani F, Izumi T, Shibata A. A novel experimental model of giant cell myocarditis induced in rats by immunization with cardiac myosin fraction. *Clin Immunol Immunopathol* 1990;57:250–62.
 - [9] Fuse K, Kodama M, Ito M, Okura Y, Kato K, Hanawa H, et al. Polarity of helper T cell subsets represents disease nature and clinical course of experimental autoimmune myocarditis in rats. *Clin Exp Immunol* 2003;134:403–8.
 - [10] Okura Y, Yamamoto T, Goto S, Inomata T, Hirono S, Hanawa H, et al. Characterization of cytokine and iNOS mRNA expression in situ during the course of experimental autoimmune myocarditis in rats. *J Mol Cell Cardiol* 1997;29:491–502.
 - [11] Yokoseki O, Suzuki J, Kitabayashi H, Watanabe N, Wada Y, Aoki M, et al. cis Element decoy against nuclear factor-kappaB attenuates development of experimental autoimmune myocarditis in rats. *Circ Res* 2001;89:899–906.
 - [12] Ginn-Pease ME, Whisler RL. Redox signals and NF-kappaB activation in T cells. *Free Radic Biol Med* 1998;25:346–61.
 - [13] Barnes PJ, Karin M. Nuclear factor-kappaB: a pivotal transcription factor in chronic inflammatory diseases. *N Engl J Med* 1997;336:1066–71.
 - [14] Morishita R, Sugimoto T, Aoki M, Kida I, Tomita N, Moriguchi A, et al. In vivo transfection of cis element "decoy" against nuclear factor-kappaB binding site prevents myocardial infarction. *Nat Med* 1997;3:894–9.
 - [15] Randomised trial of cholesterol lowering in 4444 patients with coronary heart disease: the Scandinavian Simvastatin Survival Study (4S). *Lancet* 1994;344:1383–9.
 - [16] Serruys PW, de Feyter P, Macaya C, Kokott N, Puel J, Vrolix M, et al. Fluvastatin for prevention of cardiac events following successful first percutaneous coronary intervention: a randomized controlled trial. *JAMA* 2002;287:3215–22.
 - [17] Takemoto M, Liao JK. Pleiotropic effects of 3-hydroxy-3-methylglutaryl coenzyme A reductase inhibitors. *Arterioscler Thromb Vasc Biol* 2001;21:1712–9.
 - [18] Hakamada-Taguchi R, Uehara Y, Kuribayashi K, Numabe A, Saito K, Negoro H, et al. Inhibition of hydroxymethylglutaryl-coenzyme A reductase reduces Th1 development and promotes Th2 development. *Circ Res* 2003;93:948–56.
 - [19] Leung BP, Sattar N, Crilly A, Prach M, McCarey D.W, Payne H, et al. A novel anti-inflammatory role for simvastatin in inflammatory arthritis. *J Immunol* 2003;170:1524–30.
 - [20] Hilgendorff A, Muth H, Parviz B, Staubitz A, Haberbosch W, Tillmanns H, et al. Statins differ in their ability to block NF-kappaB activation in human blood monocytes. *Int J Clin Pharmacol Ther* 2003;41:397–401.
 - [21] Dechend R, Fiebeler A, Lindschau C, Bischoff H, Muller D, Park JK, et al. Modulating angiotensin II-induced inflammation by HMG Co-A reductase inhibition. *Am J Hypertens* 2001;14:55S–61S.
 - [22] Futamatsu H, Suzuki J, Kosuge H, Yokoseki O, Kamada M, Ito H, et al. Attenuation of experimental autoimmune myocarditis by blocking activated T cells through inducible costimulatory molecule pathway. *Cardiovasc Res* 2003;59:95–104.
 - [23] Sahn DJ, DeMaria A, Kisslo J, Weyman A. Recommendations regarding quantitation in M-mode echocardiography: results of a survey of echocardiographic measurements. *Circulation* 1978;58:1072–83.
 - [24] Litwin SE, Katz SE, Morgan JP, Douglas PS. Serial echocardiographic assessment of left ventricular geometry and function after large myocardial infarction in the rat. *Circulation* 1994;89:345–54.
 - [25] Kosuge H, Suzuki J, Gotoh R, Koga N, Ito H, Isobe M, et al. Induction of immunologic tolerance to cardiac allograft by simultaneous blockade of inducible co-stimulator and cytotoxic T-lymphocyte antigen 4 pathway. *Transplantation* 2003;75:1374–9.
 - [26] Ratcliffe NR, Hutchins J, Barry B, Hickey WF. Chronic myocarditis induced by T cells reactive to a single cardiac myosin peptide: persistent inflammation, cardiac dilatation, myocardial scarring and continuous myocyte apoptosis. *J Autoimmun* 2000;15:359–67.
 - [27] Matsui Y, Inobe M, Okamoto H, Chiba S, Shimizu T, Kitabatake A, et al. Blockade of T cell costimulatory signals using adenovirus vectors prevents both the induction and the progression of experimental autoimmune myocarditis. *J Mol Cell Cardiol* 2002;34:279–95.
 - [28] Node K, Fujita M, Kitakaze M, Hori M, Liao JK. Short-term statin therapy improves cardiac function and symptoms in patients with idiopathic dilated cardiomyopathy. *Circulation* 2003;108:839–43.
 - [29] Ito T, Ikeda U, Shimpo M, Ohki R, Takahashi M, Yamamoto K, et al. HMG-CoA reductase inhibitors reduce interleukin-6 synthesis in human vascular smooth muscle cells. *Cardiovasc Drugs Ther* 2002;16:121–6.
 - [30] Inoue I, Goto S, Mizotani K, Awata T, Mastunaga T, Kawai S, et al. Lipophilic HMG-CoA reductase inhibitor has an anti-inflammatory effect: reduction of mRNA levels for interleukin-1beta, interleukin-6, cyclooxygenase-2, and p22phox by regulation of peroxisome proliferator-activated receptor alpha (PPARalpha) in primary endothelial cells. *Life Sci* 2000;67:863–76.
 - [31] Youssef S, Stuve O, Patarroyo JC, Ruiz PJ, Radosevich JL, Hur EM, et al. The HMG-CoA reductase inhibitor, atorvastatin, promotes a Th2 bias and reverses paralysis in central nervous system autoimmune disease. *Nature* 2002;420:78–84.
 - [32] Aktas O, Waiczies S, Smorodchenko A, Dorr J, Seeger B, Prozorovski T, et al. Treatment of relapsing paralysis in experimental encephalomyelitis by targeting Th1 cells through atorvastatin. *J Exp Med* 2003;197:725–33.
 - [33] McKay A, Leung BP, McInnes IB, Thomson NC, Liew FY. A novel anti-inflammatory role of simvastatin in a murine model of allergic asthma. *J Immunol* 2004;172:2903–8.
 - [34] Haudek SB, Bryant DD, Giroir BP. Differential regulation of myocardial NF kappa B following acute or chronic TNF-alpha exposure. *J Mol Cell Cardiol* 2001;33:1263–71.
 - [35] Tse FL, Jaffe JM, Troendle A. Pharmacokinetics of fluvastatin after single and multiple doses in normal volunteers. *J Clin Pharmacol* 1992;32:630–8.
 - [36] Katoh M, Kurosawa Y, Tanaka K, Watanabe A, Doi H, Narita H. Fluvastatin inhibits O2- and ICAM-1 levels in a rat model with aortic remodeling induced by pressure overload. *Am J Physiol Heart Circ Physiol* 2001;281:H655–60.
 - [37] Fischetti F, Carretta R, Borotto G, Durigutto P, Bulla R, Meroni PL, et al. Fluvastatin treatment inhibits leucocyte adhesion and extravasation in models of complement-mediated acute inflammation. *Clin Exp Immunol* 2004;135:186–93.
 - [38] Kita T, Brown MS, Goldstein JL. Feedback regulation of 3-hydroxy-3-methylglutaryl coenzyme A reductase in livers of mice treated with mevinolin, a competitive inhibitor of the reductase. *J Clin Invest* 1980;66:1094–100.