

# Homocysteine and brain atrophy on MRI of non-demented elderly

T. den Heijer,<sup>1,2</sup> S. E. Vermeer,<sup>1,2</sup> R. Clarke,<sup>4</sup> M. Oudkerk,<sup>3</sup> P. J. Koudstaal,<sup>2</sup> A. Hofman<sup>1</sup> and M. M. B. Breteler<sup>1</sup>

<sup>1</sup>Department of Epidemiology and Biostatistics, and <sup>2</sup>Department of Neurology, Erasmus Medical Center, Rotterdam, <sup>3</sup>Department of Radiology, Academic Hospital Groningen, Groningen, The Netherlands and <sup>4</sup>Clinical Trial Service Unit, University of Oxford, Oxford, UK

Correspondence to: M. Breteler, Department of Epidemiology and Biostatistics, Erasmus Medical Center, PO Box 1738, 3000 DR Rotterdam, The Netherlands  
E-mail: [breteler@epib.fgg.eur.nl](mailto:breteler@epib.fgg.eur.nl)

## Summary

Patients with Alzheimer's disease have higher plasma homocysteine levels than controls, but it is uncertain whether higher plasma homocysteine levels are involved in the early pathogenesis of the disease. Hippocampal, amygdalar and global brain atrophy on brain MRI have been proposed as early markers of Alzheimer's disease. In the Rotterdam Scan Study, a population-based study of age-related brain changes in 1077 non-demented people aged 60–90 years, we investigated the association between plasma homocysteine levels and severity of hippocampal, amygdalar and global brain atrophy on MRI. We used axial T<sub>1</sub>-weighted MRIs to visualize global cortical brain atrophy (measured semi-quantitatively; range 0–15) and a 3D HASTE (half-Fourier acquisition single-shot turbo spin echo) sequence in 511 participants to measure hippocampal and amygdalar volumes. We had non-

fasting plasma homocysteine levels in 1031 of the participants and in 505 of the participants with hippocampal and amygdalar volumes. Individuals with higher plasma homocysteine levels had, on average, more cortical atrophy [0.23 units (95% CI 0.07–0.38 units) per standard deviation increase in plasma homocysteine levels] and more hippocampal atrophy [difference in left hippocampal volume –0.05 ml (95% CI –0.09 to –0.01) and in right hippocampal volume –0.03 ml (95% CI –0.07 to 0.01) per standard deviation increase in plasma homocysteine levels]. No association was observed between plasma homocysteine levels and amygdalar atrophy. These results support the hypothesis that higher plasma homocysteine levels are associated with more atrophy of the hippocampus and cortical regions in elderly at risk of Alzheimer's disease.

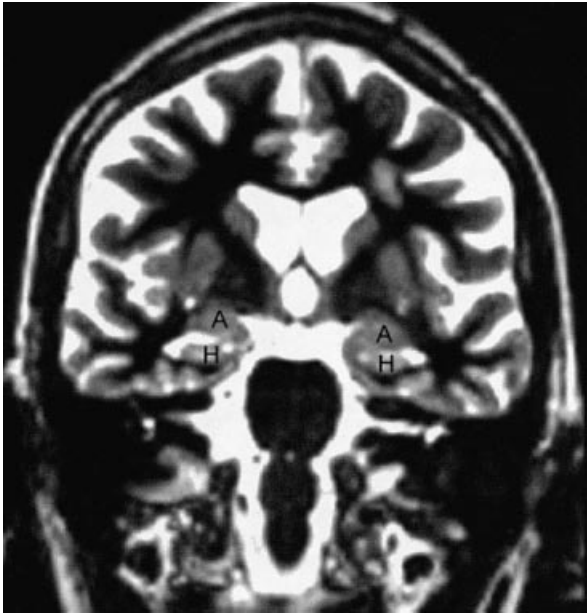
**Keywords:** homocysteine; atrophy; hippocampus; amygdala; dementia

**Abbreviations:** DSM = Diagnostic and Statistical Manual; HASTE = half-Fourier acquisition single-shot turbo spin echo

## Introduction

Patients with Alzheimer's disease or cognitive impairment have higher plasma homocysteine levels than cognitively unimpaired older subjects (Clarke *et al.*, 1998; McCaddon *et al.*, 1998; Lehmann *et al.*, 1999). Recently, a high plasma homocysteine level was shown to be a strong, independent risk factor for the development of Alzheimer's disease (Seshadri *et al.*, 2002). Elevated plasma total homocysteine level has emerged as a vascular risk factor (Refsum *et al.*, 1998), and vascular factors may play an important role in the pathogenesis of Alzheimer's disease (Breteler, 2000). Furthermore, homocysteine has direct neurotoxic effects on hippocampal and

cortical neurons (Lipton *et al.*, 1997; Kruman *et al.*, 2000). In Alzheimer patients, homocysteine was associated with atrophy of the medial temporal lobe and patients with higher homocysteine levels had a more rapid rate of atrophy over time (Clarke *et al.*, 1998). Since Alzheimer's disease is characterized by a long prodromal period, its aetiology may be better investigated in relation to early preclinical markers of the disease. Hippocampal, amygdalar and global brain atrophy on MRI may serve as such early markers (Cuenod *et al.*, 1993; Jack *et al.*, 2000; Fox *et al.*, 2001). The aim of this study was to investigate the association between plasma homocysteine



**Fig. 1** Coronal slice on which the hippocampus (H) and amygdala (A) are depicted.

levels and these brain MRI outcomes as putative early markers of Alzheimer's disease in a non-demented older population.

## Material and methods

### Study sample

This study is based on data collected in the Rotterdam Scan Study, a population-based cohort study, designed to investigate the determinants and consequences of age-related brain changes in the elderly (Breteler, 2000). In 1995–1996, we randomly selected 1904 elderly participants (aged 60–90 years) stratified by gender and age (5 years) from two ongoing population-based cohort studies: the Rotterdam Study (Hofman *et al.*, 1991) and the Zoetermeer Study (Hofman *et al.*, 1983). The presence of dementia was assessed in a stepwise approach as used in the Rotterdam Study (Ott *et al.*, 1998). First, participants were screened with the Mini-Mental State Examination and the Geriatric Mental State Schedule. Those scoring <26 on the Mini-Mental State Examination or >0 on the Geriatric Mental State Schedule were additionally assessed with the CAMDEX (Cambridge Examination for Mental Disorders of the Elderly) interview (Roth *et al.*, 1988). Subjects thereafter suspected to be demented were examined by a neurologist. Finally, an expert panel reviewing all relevant information decided whether an individual was to be considered demented or not, based on criteria of the Diagnostic and Statistical Manual (DSM)-III-R. Additionally, persons who were blind or had contraindications for MRI were excluded, leaving 1717 persons eligible. A total of 1077 individuals participated (participation rate of 63%) and gave written informed consent to a protocol, which was approved

by the medical ethics committee of Erasmus Medical Center, Rotterdam, The Netherlands.

### MRI acquisition

All 1077 participants underwent an axial T<sub>1</sub>-, T<sub>2</sub>- and proton density-weighted brain MRI scan in a 1.5-tesla unit [Philips (*n* = 514) and Siemens (*n* = 563)] (de Groot *et al.*, 2000). For the 563 subjects originating from the Rotterdam Study (Hofman *et al.*, 1991), we added a 3D half-Fourier acquisition single-shot turbo spin echo (HASTE) sequence to the protocol (inversion time 440 ms, repetition time 2800 ms, 128 contiguous sagittal slices of 1.2 mm, matrix 192 × 256, field of view 256 × 256). Two HASTE modules were sequentially acquired after the inversion pulse (effective echo time of 29 and 440 ms), of which the first was used for the volumetric assessments of the hippocampus and amygdala. Of the 563 participants, 52 developed claustrophobia, leaving 511 participants with a HASTE sequence.

### Hippocampal and amygdalar volumes

The HASTE sequence was used to reconstruct coronal slices (contiguous 1.5 mm slices) perpendicular to the long axis of the hippocampus (Fig. 1). The left and right hippocampus and amygdala were manually traced using a mouse-driven cursor based on a reference atlas (Duvernoy, 1998). Tracing proceeded from posterior to anterior, starting at the slice where the crux of the fornices was in full profile. The in-plane boundaries of the hippocampus were defined to include the subiculum, the CA1 through CA4 sectors of the hippocampus proper, and the gyrus dentatus. Tracing of the amygdala included all of its nuclei. As the anterior boundary of the amygdala is poorly defined in nature, we defined this to be the slice at the rostral extreme of the temporal stem. Volumes (ml) were calculated [sum of areas (mm<sup>2</sup>) × 1.5 mm/1000]. We measured the midsagittal area (cm<sup>2</sup>) by tracing the margin of the inner table of the skull in order to have a proxy for total intracranial volume (Cuenod *et al.*, 1993). Two readers, who were blinded to clinical information, measured the 511 scans. Intra- and inter-reader studies based on 14 random scans showed good reproducibility. Intrarater intraclass correlation coefficients for the left and right hippocampus were *r* = 0.93 and *r* = 0.90, and interrater intraclass correlation coefficients were *r* = 0.87 and *r* = 0.83, respectively. For the left and right amygdala the intrarater intraclass correlation coefficients were *r* = 0.82 and *r* = 0.78, the interrater intraclass correlation coefficients were *r* = 0.80 and *r* = 0.77, respectively.

### Global brain atrophy rating

The severity of global brain atrophy was scored on T<sub>1</sub>-weighted hard copies, blinded to clinical information, based

**Table 1** Characteristics of the total study sample and of the subset with hippocampal and amygdalar volumes

Characteristic	Total	Subset
Number	1031	505
Age (years)	72 (7)	73 (8)
Sex (% women)	52	50
Total homocysteine ( $\mu\text{mol/l}$ )	11.5 (4.1)	11.9 (4.3)
Presence of diabetes (%)	7	6
Presence of hypertension (%)	52	53
Pack-years of cigarette smoking	19 (24)	20 (25)
Serum creatinine level ( $\mu\text{mol/l}$ )	88.9 (18.6)	89.7 (19.9)

Values are unadjusted means (SD) or percentages unless otherwise specified.

on the widening of sulci and narrowing of gyri in comparison to reference scans. A score from 0 (no cortical atrophy) to 3 (severe cortical atrophy) at five different brain regions (frontal, parietal, temporal and occipital lobes, and insular region) was given. The sum score of all five regions (range 0–15) was used for the analyses. The intrarater weighted kappa was 0.82, and the interrater weighted kappa was 0.81.

### Plasma homocysteine measurements

Non-fasting blood samples were collected and processed at time of MRI as described previously (Vermeer *et al.*, 2002b). Blood samples were unavailable in 39 participants due to errors in the blood collection process. Plasma levels of total homocysteine were determined by fluorescence polarization immunoassay on an IMx analyser (Abbott). Seven individuals with extreme values were excluded from the analyses since their plasma homocysteine levels fell outside the range 5–45  $\mu\text{mol/l}$  in order to minimize the effects of regression dilution bias. Finally, 1031 participants were available for the analyses on global brain atrophy, and 505 participants for the analyses on hippocampal and amygdalar atrophy.

### Covariates

We obtained information on the following covariates by interview and physical examination in 1995–1996: diabetes mellitus, hypertension (systolic blood pressure level  $\geq 160$  mmHg, or diastolic blood pressure level  $\geq 95$  mmHg, or use of blood pressure lowering medication), pack-years of cigarette smoking, vitamin supplements (Vermeer *et al.*, 2002a) and serum creatinine levels (enzymatic assay). Presence of carotid artery plaques, and the intima-media thickness of the common carotid artery, were assessed as markers of atherosclerotic disease (Bots *et al.*, 1993). White matter lesions on MRI were scored in periventricular (grade 0–9) and subcortical regions (approximated volume) (de Groot *et al.*, 2000). Infarcts on MRI were defined as focal hyperintensities on T<sub>2</sub>-weighted

images, without prominent hypointensities on T<sub>1</sub>-weighted images (Vermeer *et al.*, 2002a).

### Data analysis

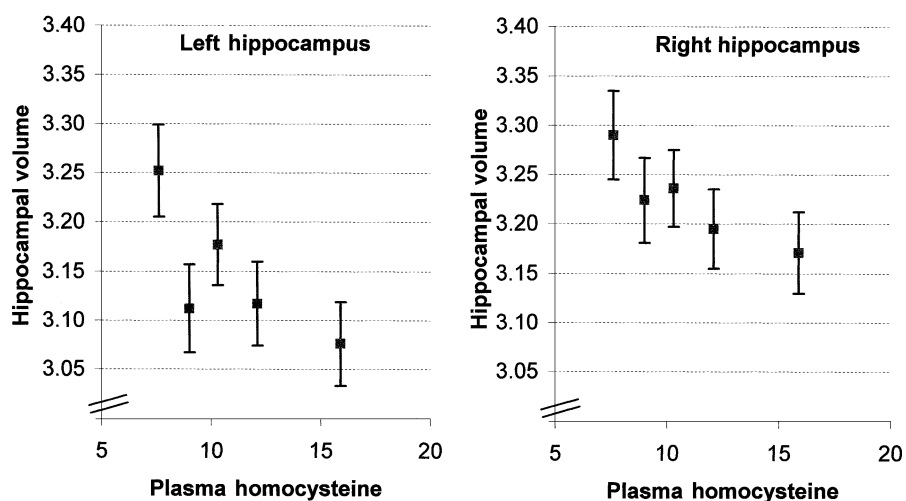
The relation between plasma homocysteine level and atrophy was evaluated using both homocysteine in quintiles and as a continuous variable. Since homocysteine levels increase markedly with age, quintiles were defined in an age-specific manner for each of the 5-year age categories. We compared adjusted means of hippocampal and amygdalar volumes and global brain atrophy across the age-specific quintiles of plasma homocysteine by ANCOVA (analysis of covariance). The analyses were adjusted for age, sex, diabetes, hypertension, pack-years of cigarette smoking, serum creatinine and, for the hippocampal and amygdalar analyses, midsagittal area. Because these analyses did not suggest a non-linear association between homocysteine and atrophy, we performed multivariate linear regression to calculate the change in atrophy per standard deviation increase in plasma homocysteine level. We investigated whether carotid atherosclerosis, white matter lesions or presence of infarcts on MRI mediated the association between homocysteine and atrophy by adding these covariates to the model. Assumptions of the models were confirmed by residual analyses.

### Results

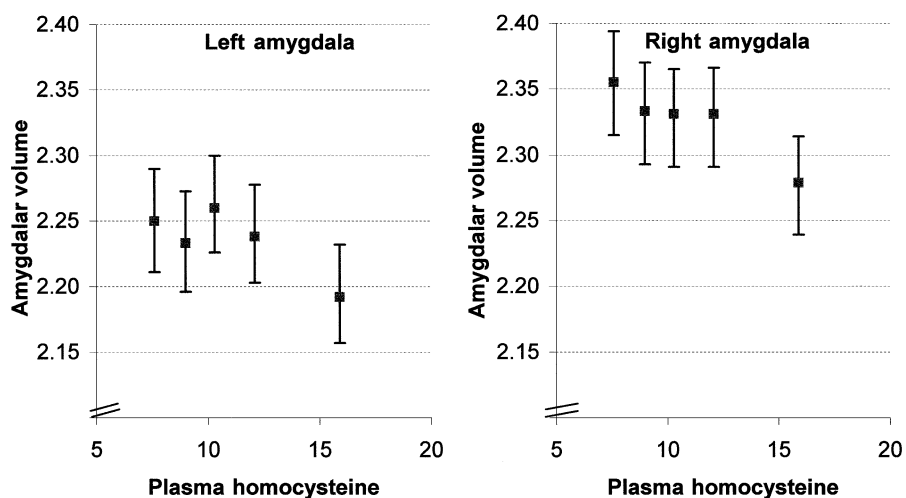
Selected characteristics of the total study sample and the subset with hippocampal and amygdalar volumes are shown in Table 1.

Plasma homocysteine levels increased with increasing age (1.5  $\mu\text{mol/l}$  increase per 10 years) and were higher in men (sex difference 1.2  $\mu\text{mol/l}$ ). Sixty-one participants (5.9%) reported use of multivitamin supplements, and these individuals had lower plasma homocysteine levels than non-users (age and sex adjusted difference  $-1.3$   $\mu\text{mol/l}$ ; 95% CI  $-2.3$  to  $-0.3$ ).

Figure 2 shows the association between plasma homocysteine levels and hippocampal volumes. People with higher plasma homocysteine levels had smaller hippocampal volumes [difference in left hippocampal volume  $-0.05$  (95% CI  $-0.09$  to  $-0.01$ ) and right hippocampal volume  $-0.03$  (95% CI  $-0.07$  to  $0.01$ ) per standard deviation increase in plasma homocysteine level adjusted for age, sex, diabetes, hypertension, pack-years of cigarette smoking, creatinine levels and midsagittal area]. Further adjustment for carotid atherosclerosis, white matter lesions and infarcts did not change this association (data not shown). In contrast, there was a non-significant decrease in amygdalar volume with increasing plasma homocysteine levels (Fig. 3). Per standard deviation increase in plasma homocysteine level, the left amygdalar volume decreased  $-0.01$  (95% CI  $-0.04$  to  $0.03$ ) and the right



**Fig. 2** Hippocampal volumes according to age-specific quintiles of plasma homocysteine levels. The mean volumes (standard error) are plotted at the median of each quintile and are adjusted for age, sex, diabetes, hypertension, pack-years of cigarette smoking, creatinine levels and midsagittal area. Note that the left hippocampus is on average smaller than the right hippocampus.



**Fig. 3** Amygdalar volumes according to age-specific quintiles of plasma homocysteine levels. The mean volumes (standard error) are plotted at the median of each quintile and are adjusted for age, sex, diabetes, hypertension, pack-years of cigarette smoking, creatinine levels and midsagittal area. Note that the left amygdala is on average smaller than the right amygdala.

amygdalar volume decreased by  $-0.02$  ml (95% CI  $-0.05$  to  $0.02$ ).

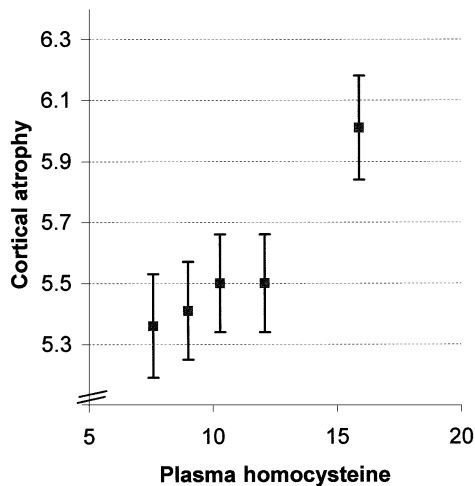
Figure 4 shows the association between plasma homocysteine levels and severity of cortical atrophy. The degree of cortical atrophy increased with increasing plasma homocysteine levels [per standard deviation  $0.23$  units more (95% CI  $0.07$ – $0.38$ )]. This association was unaltered after adjusting for carotid atherosclerosis [per standard deviation  $0.22$  ( $0.06$ – $0.37$ )] and slightly weakened after adjusting for white matter lesions and infarcts [per standard deviation  $0.19$  ( $0.03$ – $0.34$ )].

The results were not materially altered after exclusion of regular users of multivitamin supplements.

## Discussion

This study found that increasing plasma homocysteine levels are associated with more hippocampal and cortical atrophy in an older non-demented population.

The chief strength of the present study is the population-based study design and the large number of volumetric



**Fig. 4** Global brain atrophy according to age-specific quintiles of plasma homocysteine levels. The mean atrophy score (standard error) is plotted at the median of each quintile and is adjusted for age, sex, diabetes, hypertension, pack-years of cigarette smoking and creatinine levels.

assessments of the hippocampus and amygdala. However, a limitation was that the instruments used to assess global brain atrophy were somewhat imprecise.

Plasma homocysteine levels reflect vitamin status, renal function and genetic variations in the enzymes controlling homocysteine metabolism genes (Refsum *et al.*, 1998). Recently, it was shown that a low plasma folate level may predict more neocortical atrophy at death (Snowdon *et al.*, 2000), although homocysteine may have mediated this association. There are no available data on effects of genetic variations in homocysteine metabolism on brain atrophy. Two putative effects of homocysteine support a causal association between higher plasma homocysteine levels and brain atrophy. First, homocysteine damages the vascular walls (Nappo *et al.*, 1999) from arteries (Selhub *et al.*, 1995; Fassbender *et al.*, 1999). People with more global brain atrophy more frequently have atherosclerosis in the carotid arteries and white matter lesions on MRI, which are assumed to be small vessel disease (Meguro *et al.*, 1993; Manolio *et al.*, 1999). However, the association between plasma homocysteine levels and atrophy was unaltered by adjusting for carotid atherosclerosis, and only partly reduced by adjusting for white matter lesions, suggesting that other pathways may be involved. Secondly, neurotoxic effects of homocysteine in cultures of cortical and hippocampal neurons could partly explain the associations (Lipton *et al.*, 1997; Kruman *et al.*, 2000). These studies in rats showed that hippocampal neurons were even more sensitive to the effects of homocysteine (Kruman *et al.*, 2000) than cortical neurons (Lipton *et al.*, 1997). Some individuals with hippocampal, and possibly global, brain atrophy are more likely to develop clinical Alzheimer's disease (Jack *et al.*, 2000; Fox *et al.*, 2001). The findings of the present study suggest that higher homocysteine levels may be associated with early Alzheimer

pathology. However, due to the cross-sectional design of the current study, it remains uncertain whether high homocysteine levels actually precede changes in pathology and cause the brain to shrink. Prospective studies using several atrophy and homocysteine measurements are necessary to unravel cause and consequence. The finding that high baseline homocysteine levels in patients with Alzheimer's disease predicted more rapid atrophy of the medial temporal lobe over the following 3 years supports a causal association (Clarke *et al.*, 1998). Our results confirm cross-sectional studies which show a high plasma homocysteine level to be associated with Alzheimer's disease and cognitive impairment (Clarke *et al.*, 1998; McCaddon *et al.*, 1998; Lehmann *et al.*, 1999). Furthermore, they are in keeping with a prospective study which showed that a high plasma homocysteine level is an independent risk factor for Alzheimer's disease (Seshadri *et al.*, 2002).

Several large-scale randomized trials with folic acid-based vitamin supplements to lower homocysteine levels are currently being conducted and almost all of these trials include an assessment of cognitive function; some have sub-studies that also include MRI measurements. Further large-scale trials are required to assess whether lowering plasma homocysteine levels may prevent Alzheimer-related structural abnormalities or delay progression of clinical symptoms of Alzheimer's disease.

## Acknowledgements

We wish to thank Carole Johnston for carrying out the homocysteine measurements, David Smith for his contribution in the initiation of this project, and Freek Hoebeek and Dr Eric Achten for their help in measuring the hippocampus and the amygdala. We also acknowledge the EU BIOMED Demonstration Project (BMH 4-98-3549), which paid for homocysteine assays. The Netherlands Organisation for Scientific Research (NWO) and the Health Research and Development Council (ZON) supported this study. M.M.B.B. is a fellow of the Royal Netherlands Academy of Arts and Sciences.

## References

- Bots ML, van Swieten JC, Breteler MM, de Jong PT, van Gijn J, Hofman A, et al. Cerebral white matter lesions and atherosclerosis in the Rotterdam Study. *Lancet* 1993; 341: 1232-7.
- Breteler MM. Vascular involvement in cognitive decline and dementia. Epidemiologic evidence from the Rotterdam Study and the Rotterdam Scan Study. *Ann NY Acad Sci* 2000; 903: 457-65.
- Clarke R, Smith AD, Jobst KA, Refsum H, Sutton L, Ueland PM. Folate, vitamin B12, and serum total homocysteine levels in confirmed Alzheimer disease. *Arch Neurol* 1998; 55: 1449-55.
- Cuenod CA, Denys A, Michot JL, Jehenson P, Forette F, Kaplan D, et al. Amygdala atrophy in Alzheimer's disease. An in vivo magnetic resonance imaging study. *Arch Neurol* 1993; 50: 941-5.

- de Groot JC, de Leeuw FE, Oudkerk M, van Gijn J, Hofman A, Jolles J, et al. Cerebral white matter lesions and cognitive function: the Rotterdam Scan Study. *Ann Neurol* 2000; 47: 145–51.
- Duvernoy HM. The human hippocampus: functional anatomy, vascularization and serial sections with MRI. 2nd ed. Berlin: Springer-Verlag; 1998.
- Fassbender K, Mielke O, Bertsch T, Nafe B, Fröschen S, Hennerici M. Homocysteine in cerebral macroangiography and microangiopathy. *Lancet* 1999; 353: 1586–7.
- Fox NC, Crum WR, Scchill RI, Stevens JM, Janssen JC, Rossor MN. Imaging of onset and progression of Alzheimer's disease with voxel-compression mapping of serial magnetic resonance images. *Lancet* 2001; 358: 201–5.
- Hofman A, Laar van A, Klein F, Valkenburg HA. Coffee and cholesterol [letter]. *N Engl J Med* 1983; 309: 1248–50.
- Hofman A, Grobbee DE, de Jong PT, van den Ouweland FA. Determinants of disease and disability in the elderly: the Rotterdam Elderly Study. *Eur J Epidemiol* 1991; 7: 403–22.
- Jack CR Jr, Petersen RC, Xu Y, O'Brien PC, Smith GE, Ivnik RJ, et al. Rates of hippocampal atrophy correlate with change in clinical status in aging and AD. *Neurology* 2000; 55: 484–9.
- Kruman II, Culmsee C, Chan SL, Kruman Y, Guo Z, Penix L, et al. Homocysteine elicits a DNA damage response in neurons that promotes apoptosis and hypersensitivity to excitotoxicity. *J Neurosci* 2000; 20: 6920–6.
- Lehmann M, Gottfries CG, Regland B. Identification of cognitive impairment in the elderly: homocysteine is an early marker. *Dement Geriatr Cogn Disord* 1999; 10: 12–20.
- Lipton SA, Kim WK, Choi YB, Kumar S, D'Emilia DM, Rayudu PV, et al. Neurotoxicity associated with dual actions of homocysteine at the N-methyl-D-aspartate receptor. *Proc Natl Acad Sci USA* 1997; 94: 5923–8.
- Manolio TA, Burke GL, O'Leary DH, Evans G, Beauchamp N, Knepper L, et al. Relationships of cerebral MRI findings to ultrasonographic carotid atherosclerosis in older adults: the Cardiovascular Health Study. *Arterioscler Thromb Vasc Biol* 1999; 19: 356–65.
- McCaddon A, Davies G, Hudson P, Tandy S, Cattell H. Total serum homocysteine in senile dementia of Alzheimer type. *Int J Geriatr Psychiatry* 1998; 13: 235–9.
- Meguro K, Yamaguchi T, Hishinuma T, Miyazawa H, Ono S, Yamada K, et al. Periventricular hyperintensity on magnetic resonance imaging correlated with brain ageing and atrophy. *Neuroradiology* 1993; 35: 125–9.
- Nappo F, De Rosa N, Marfella R, De Lucia D, Ingrosso D, Perna AF, et al. Impairment of endothelial functions by acute hyperhomocysteinemia and reversal by antioxidant vitamins. *JAMA* 1999; 281: 2113–8.
- Ott A, Breteler MM, van Harskamp F, Stijnen T, Hofman A. Incidence and risk of dementia. The Rotterdam Study. *Am J Epidemiol* 1998; 147: 574–80.
- Refsum H, Ueland PM, Nygård O, Vollset SE. Homocysteine and cardiovascular disease. [Review]. *Annu Rev Med* 1998; 49: 31–62.
- Roth M, Huppert FA, Tym E. CAMDEX: the Cambridge examination for mental disorders of the elderly. Cambridge: Cambridge University Press; 1988.
- Selhub J, Jacques PF, Bostom AG, D'Agostino RB, Wilson PW, Belanger AJ, et al. Association between plasma homocysteine concentrations and extracranial carotid-artery stenosis. *N Engl J Med* 1995; 332: 286–91.
- Seshadri S, Beiser A, Selhub J, Jacques PF, Rosenberg IH, D'Agostino RB, et al. Plasma homocysteine as a risk factor for dementia and Alzheimer's disease. *N Engl J Med* 2002; 346: 476–83.
- Snowdon DA, Tully CL, Smith CD, Riley KP, Markesbery WR. Serum folate and the severity of atrophy of the neocortex in Alzheimer disease: findings from the Nun study. *Am J Clin Nutr* 2000; 71: 993–8.
- Vermeer SE, Koudstaal PJ, Oudkerk M, Hofman A, Breteler MM. Prevalence and risk factors of silent brain infarcts in the population-based Rotterdam Scan Study. *Stroke* 2002a; 33: 21–5.
- Vermeer SE, van Dijk EJ, Koudstaal PJ, Oudkerk M, Hofman A, Clarke R, et al. Homocysteine, silent brain infarcts, and white matter lesions: the Rotterdam Scan Study. *Ann Neurol* 2002b; 51: 285–9.

Received February 14, 2002. Revised July 12, 2002.

Accepted July 15, 2002