

# We are IntechOpen, the world's leading publisher of Open Access books Built by scientists, for scientists

5,900

Open access books available

145,000

International authors and editors

180M

Downloads

Our authors are among the

154

Countries delivered to

TOP 1%

most cited scientists

12.2%

Contributors from top 500 universities



WEB OF SCIENCE™

Selection of our books indexed in the Book Citation Index  
in Web of Science™ Core Collection (BKCI)

Interested in publishing with us?  
Contact [book.department@intechopen.com](mailto:book.department@intechopen.com)

Numbers displayed above are based on latest data collected.  
For more information visit [www.intechopen.com](http://www.intechopen.com)



---

# How to Sample the Unreachable: Transbronchial Biopsy

---

Mihai Olteanu, Floarea Mimi Nițu, Andreea Golli, Mădălina Olteanu, Adina Turcu, Florentina Dumitrescu, Bogdan Oprea, Ramona Cioboată, Alin Demetrian, Roxana Nemeș, Agripina Rașcu, Edith Simona Ianoși and Tudorel Ciurea

Additional information is available at the end of the chapter

<http://dx.doi.org/10.5772/intechopen.81909>

---

## Abstract

Transbronchial biopsy (TBBx) or bronchoscopic lung biopsy (BLBx) should be a diagnosis tool for focal peripheral lesions and for diffuse lung disease in every bronchoscopic suite around the world. The main advantage of this procedure is that it avoids open lung surgery for peripheral lung biopsy. The procedure is usually safe and can be done in an outpatient setting with moderate sedation, but life-threatening complications can occur, so a proper evaluation of the risk benefits ratio should be carefully analyzed before the intervention. There is no need for guidance in diffuse peripheral lesions, but for localized peripheral lesions, the diagnostic yield of TBBx is significantly higher with fluoroscopic guidance. In this chapter, we assess the utility, indications, and contraindication of this technique, as well as its clinical applications and complications.

**Keywords:** lung biopsy, transbronchial biopsy (TBBx), bronchoscopic lung biopsy

---

## 1. Introduction

Transbronchial biopsy (TBBx) or bronchoscopic lung biopsy (BLBx) should be a diagnosis tool for focal peripheral lesions and for diffuse lung disease in every bronchoscopic suite around the world. The main advantage of this procedure is that it avoids open lung surgery for peripheral lung biopsy. The procedure is usually safe and can be done in an outpatient setting with moderate sedation, but life-threatening complications can occur, so a proper evaluation of

---

the risk benefits ratio should be carefully analyzed before the intervention. There is no need for guidance in diffuse peripheral lesions, but for localized peripheral lesions, the diagnostic yield of TBBx is significantly higher with fluoroscopic guidance. In this chapter we assess the utility, indications, and contraindication of this technique, as well as its clinical applications and complications.

## 2. Indications

TBBx is a solution to consider in a large variety of peripheral lung disorders. TBBx can be combined for an increased yield of diagnosis with other bronchoscopic diagnostic procedures, like bronchial and bronchioloalveolar cytology washings, cytology brushes, and peripheral transbronchial needle aspirations.

The main indications for TBBx are malignancies, infections, and diffuse lung diseases.

### 2.1. Malignancies

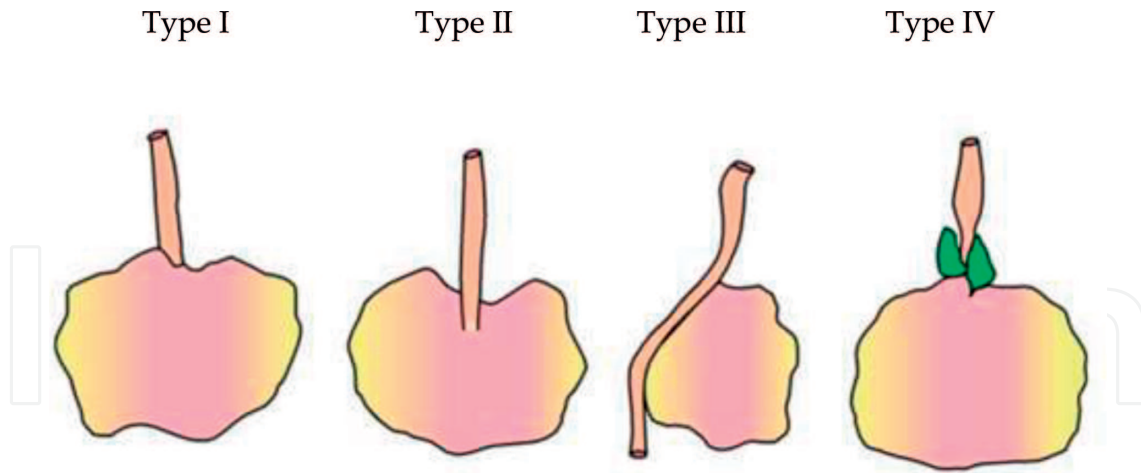
In peripheral malignancies, the average diagnostic yield of TBBx is 57% (17–77%). When this procedure is done in combination with peripheral bronchial washing and brushing, it comes with an exclusive diagnosis in up to 19% of the patients [1].

In lymphangitic carcinomatosis, TBBx appears to have a high diagnostic yield, but in metastatic pulmonary tumors, the diagnostic yield is limited (17%).

There is great debate around the number of biopsies necessary in order to have a satisfactory diagnostic yield. Descombes et al. showed a 21% diagnostic yield in the case of 1–3 TBBx biopsies and 78% yield when 6–10 biopsies were taken. Popovich et al. showed an increase of 25% between the first TBBx diagnostic yield (45%) and multiple biopsies (70%). There is a general consensus, based on these studies and many more, that 6–10 biopsies should be taken for an optimum diagnostic yield in lung cancer [2, 3].

The size of the lesion and its relationship with the bronchial tree are also very important to assess the utility of TBBx. Regarding the size of the lesion, studies showed a diagnostic yield of 34% in the case of a lesion smaller than 2 cm and 63% for lesions greater than 2 cm in diameter [4]. Regarding the position of the lesion in relation to the bronchial tree, there are four situations very well described by Tsuboi et al. (**Figure 1**): type I, in which the tumor is at the end of the opened bronchus; type II, when the tumor contains the bronchus; type III, when the bronchus trajectory is modified, and the diameter can also be modified, either compressed or narrowed by the tumor mass, but the bronchial mucosa is normal; and type IV, when the bronchus is narrowed in the proximal part by the submucosal and peribronchial infiltration of the tumor, fibrosis, or enlarged lymph nodes [5].

There is an issue regarding the bronchus sign often seen on thoracic CT, which means that the permeable bronchus is contained in the tumor mass or it ends with the tumor. The significance



**Figure 1.** Relationship between tumor mass and tributary bronchus [5].

would be that with the bronchus sign present on thoracic CT, the yield of TBBx is 60–82%, compared with 0–44% when the bronchus sign is absent [6–8].

It is recommended that in the case of a type III or IV lesion, peripheral transbronchial needle aspiration (TBNA) should be used for sampling the tumor instead of TBBx, due to the needle ability to pierce the tumor directly beyond the narrowed and displaced bronchial tree, which is very hard for the TBBx forceps to do.

## 2.2. Infections

TBBx is used in a variety of pulmonary infections as well. The main indications for TBBx in lung infections are non-resolving pneumonia, *Mycobacterium tuberculosis* or nontuberculous *Mycobacterium* infection, fungal infections, *Pneumocystis carinii* pneumonia, and some viral infections, such as CMV pneumonitis.

### 2.2.1. Non-resolving pneumonia

The term non-resolving pneumonia, which must be differentiated from non-responding pneumonia and slowly resolving pneumonia, is defined as the persistence of clinical symptoms and signs (cough, sputum production, with or without fever  $>37.7^{\circ}\text{C}$ ) and failure of resolution of the radiographic features by 50% in 2 weeks or completely in 4 weeks on serial chest X-rays, in spite of antibiotic treatment for at least 10 days. Arancibia et al. reached a diagnosis in non-resolving pneumonia patients who failed antibiotic treatment in 57% of the cases. Nevertheless, TBBx is seldom used for non-resolving pneumonia, because other methods are less invasive and at least as useful, like protected brushing and bronchoalveolar lavage. TBBx is invaluable because it can confirm other pathologies like *Mycobacterium* (tuberculosis or nontuberculosis) infections, fungal infections, neoplasms (bronchioloalveolar cancer), BOOP, and histiocytosis [9].

### 2.2.2. Tuberculosis

Tuberculosis has a high morbidity and mortality worldwide. Nowadays, despite the discovery and availability of specific preventive and curative chemotherapy, pulmonary tuberculosis is still a fatal airborne transmitted disease [10]. Fiberoptic bronchoscopy and TBBx are an important bronchoscopic procedure to evaluate patients with negative smears and radiologic and anamnestic suspicion of pulmonary tuberculosis. It can provide immediate histopathology and smear-positive diagnosis, and it can rule out malignancies and fungal infections presenting like pulmonary tuberculosis as differential diagnosis [11].

In the vast majority of patients, adding TBBx to bronchoalveolar lavage is the maximum of procedures that can be undergone to have a confirmation diagnosis. The usual candidates for these methods would be patients with a clinical suspicion of active tuberculosis, with suspected lesions on chest X-ray or thoracic CT and at least three negative acid-fast bacilli sputum exams, or with inability to provide good quality sputum. TBBx provides confirmation diagnosis in 17–60% of active pulmonary tuberculosis cases [12].

TBBx also provides rapid confirmation diagnosis in smear-negative miliary tuberculosis, with a diagnosis yield of 60–80% [13, 14].

### 2.2.3. Non-tubercular mycobacteria

TBBx should be performed whenever there is a suspicion of non-tubercular pulmonary infection. According to the American Thoracic Society, the diagnosis of non-tubercular pulmonary infection requires one of the following microbiological criteria, in a favorable clinical setting: at least two separate positive sputum cultures *or* at least one positive culture from bronchial lavage *or* transbronchial biopsies with granulomatous inflammation, Ziehl Nielsen acid-fast bacilli with positive non-tubercular bacilli cultures, and at least one sputum exam or bronchial wash culture positive for non-tubercular mycobacteria [15].

### 2.2.4. Fungal infections

In fungal infections usually there is no need for TBBx, because a confirmation diagnosis is reached with the help of bronchial washings and bronchioalveolar lavage procedures. There is little improvement in diagnostic yield with this procedure, and so it should not be done at first bronchoscopy except in the case of negative initial tests, with a maintained suspicion of fungal infection [16, 17].

## 2.3. Diffuse lung diseases

### 2.3.1. Sarcoidosis

In sarcoidosis, a confirmation diagnosis is established at bronchoscopy with a combination of bronchioalveolar lavage, endobronchial biopsy, transbronchial biopsy, and transbronchial needle aspiration. As we can see, there are a lot of diagnostic possibilities to choose from when we are looking for a confirmation. It depends, however, on the stage of sarcoidosis to choose

the best, minimum invasive procedure that will provide a confirmation. The stages of sarcoidosis are stage I, when we have lymph node involvement; stage II, when we have lymph node involvement and pulmonary infiltrates; stage III, when granulomas are only present in the lung tissue, expressed radiologically as pulmonary infiltrates; and stage IV, when diffuse scarring is found in the lung tissue, indicating irreversible damage. The diagnostic yield of TBBx varies between 50 and 65% in stage I, 63 and 82% in stage II, and 80 and 85% in stage III. Bronchial mucosa is frequently involved in all stages of sarcoidosis, so an endobronchial biopsy adds an average of 20% over the diagnostic yield of TBBx [18–20].

Of course, one should always look for reaching the most affected areas of the mediastinum and lung parenchyma. For example, in lymph node involvement (stage I and III), one should always puncture the nodes (conventional transbronchial needle aspiration or echo-guided needle aspiration) with or without endobronchial biopsy and TBBx, in the same procedure.

### 2.3.2. *Lymphangitic carcinomatosis*

The nonspecific diffuse interstitial pattern of lymphangitic carcinomatosis is a serious differential diagnostic problem, especially in patients without any obvious primary carcinoma, and it is often a cause of delayed diagnosis and postmortem tissue confirmation. In these patients, differential consists of acute or subacute infectious processes, radiation pneumonitis, chemo drug reaction, idiopathic pulmonary fibrosis, or diffuse tumor infiltration [21].

### 2.3.3. *Pulmonary alveolar proteinosis*

The worldwide accepted diagnosis for pulmonary alveolar proteinosis (PAP) is still reached by flexible bronchoscopy with bronchoalveolar lavage (BAL). Transbronchial biopsies can be combined with BAL findings when these are done in the affected lung segments, and these are both usually sufficient to establish the etiology. One must be aware of this diagnosis possibility and request PAS staining. Usually, this is the cause of underdiagnosis (low suspicion). PAP can still be diagnosed by requesting Papanicolaou staining from BAL that can show specific green and orange globules. BAL analyzed by electronic microscopy can also reveal specific multilamellar structures.

### 2.3.4. *Pulmonary Langerhans histiocytosis*

Clinical features and high-resolution computed tomography usually suggest this diagnostic, but tissue confirmation is still needed. Surgical lung biopsy for confirmation is the golden standard because of being able to sample the affected areas and to provide an appropriate amount of tissue. TBBx can also provide tissue for a confirmation diagnosis in some cases, but the yield varies from 10 to 40%. This low yield is probably due to biopsy site selection error secondary to patchy distribution of the lung infiltrates. In conclusion, a nondiagnostic TBBx procedure should be followed by a surgical biopsy confirmation. One should always look for Langerhans cells staining for CD1a (>5%) and S100 protein on immunocytochemistry, but false-positive results can be found in smokers [22, 23].

### 2.3.5. *Amyloidosis*

Without lung biopsies, amyloid lung disease often goes unrecognized. Amyloidosis represents a heterogeneous group of diseases characterized by the deposition of congophilic fibrils in the extracellular matrix of tissues and organs. In an amyloid lung, there can be multiple clinicopathologic forms of lesions. These are diffuse amyloidosis with an alveolar-septal pattern, nodular amyloidosis, and tracheobronchial amyloidosis (less frequent encountered). There is no specific localization or extent of these lesions, but there have been described three types of lesions: proximal, mid, and distal involvement. Flexible bronchoscopy with TBBx is the preferred tool for tracheobronchial amyloidosis diagnosis. Computed tomography usually appreciates the extent of the disease. Severe amyloid deposition in the proximal and mid bronchi can endanger air passage, a situation in which laser or/and forceps recanalization is required. External beam radiation therapy can also be used for endobronchial debridement. The mortality is an important matter in this situation, because recurrence is very common and approximately 30% of these patients eventually die [24].

### 2.3.6. *Lymphangioliomyomatosis (LAM)*

LAM is a rare cystic lung disease that affects women during their reproductive years. LAM is usually difficult to diagnose because of its similarity to other lung diseases and because symptoms are variable from patient to patient. There are a number of tests that a physician can address to in order to confirm or infirm the existence of LAM and to evaluate the extent of lung damage, as well as the spread. High-resolution CT scan (HRCT) is the most accurate and noninvasive test for diagnosing LAM. It can be used in combination with VEGF-D blood test to help distinguish LAM from other cystic lung diseases. Sometimes, an elevated VEGF-D level is enough to confirm diagnosis, though it can be looked at as a replacement for lung biopsy. Nevertheless, lung biopsy is the gold standard for LAM diagnosis, and transbronchial biopsy plays an important role because it is less invasive than surgical lung biopsy. However, the amount of tissue obtained through this procedure may sometimes not be enough for a definitive LAM diagnosis. Also, immunohistochemical studies from the lung biopsies show positive staining of LAM cells for HMB-45 monoclonal antibodies and for estrogen receptors, and they both strongly support LAM diagnosis [25–27]. Some authors found that TBBx has a yield of approximately 60% in patients with LAM. Therefore, they concluded that TBBx is safe and effective for the diagnosis of LAM, avoiding surgery with lung biopsy in more than half of LAM patients [28].

### 2.3.7. *Bronchiolitis obliterans with organizing pneumonia (cryptogenic organizing pneumonia)*

The pathologic hallmarks of COP include granulation tissue in the terminal and respiratory bronchioles and alveolar ducts which can be extended and organized into alveoli. Also, chronic inflammatory changes in the surrounding interstitial space can be found. As mentioned before, in some settings TBBx was found to be adequate for diagnosis, but thoracoscopic or surgical lung biopsy has the advantage of larger lung biopsy specimens, and this is needed in order to exclude other conditions that mimic COP. In specialized centers though, TBBx in COP has sensitivity of 64%, specificity of 86%, and positive predictive value of 94% and negative predictive value of

40%. Literature recommends TBBx before referring the patients for more invasive methods. Nevertheless, if diagnosis remains unclear after TBBx and if incomplete response to oral corticosteroids is seen, a surgical approach with lung biopsy must be performed [29–34].

#### 2.3.8. Hypersensitivity pneumonitis (HP)

HP is mostly a clinical diagnosis, and histopathological confirmation is only necessary when diagnosis is uncertain or the clinical outcome is inadequate in spite of treatment. Large biopsy specimens are needed, but in some cases of acute and subacute HP (less in chronic HP), TBBx showed adequate specimens. The histopathological findings in subacute HP consist of cellular bronchiolitis, diffuse interstitial infiltrates of chronic inflammatory cells, and scattered noncaseating granulomas [35–37].

### 3. Contraindications

There are absolute and relative contraindications for TBBx.

Absolute contraindications:

- Absence of informed consent
- Lack of patient cooperation
- Inadequate facilities for patient resuscitation
- Uncorrected bleeding disorders
- Severe pulmonary hypertension
- Massive hemoptysis
- Refractory hypoxia
- Uncontrolled arrhythmias
- Uncontrolled cough
- Uncontrolled bronchospasm

Relative contraindications:

- Uremia—Because uremic patients have a higher risk of bleeding when TBBx is performed, serum creatinine should be measured in the case renal insufficiency is presumed. Some studies showed increased bleeding when both BUN >30 mg/dl (urea >64.2 mg/dl) and serum creatinine >3.0 mg/dl [38]. However, elevated BUN can also be encountered in other situations, like congestive heart failure, dehydration, gastrointestinal bleeding, some antibiotics, and high-protein diet.
- Thrombocytopenia (when the platelet count is less than 50,000/ $\mu$ L).



- Pulmonary hypertension (although there is little evidence regarding excessive bleeding after TBBx even in severe pulmonary hypertension, it is considered to be a safe procedure when pulmonary hypertension is mild to moderate) [39, 40].
- Anticoagulants and antiaggregants, if not discontinued. Aspirin can be continued, but clopidogrel must be discontinued at least 5 days before TBBx. Warfarin must be discontinued 3 days before the procedure and heparin 6 hours before, whereas enoxaparin given in deep vein thrombosis can be discontinued 12 hours before the procedure (do not administer in the morning of the procedure). Targeted international normalized ratio (INR) must be below 1.5 (some studies showed a better safety profile when INR is below 1.3) [41, 42].
- Mechanical ventilation—In these patients there is an increased risk of tension pneumothorax when TBBx is performed, so benefits should be balanced against the risks and discussed with the patients, for proper management.

#### 4. Complications

There are different percentages of procedure-related complications in the literature, depending of many factors, like patient selection, the pulmonary disorder for which the TBBx was done, the use of sedation, the number of biopsies taken, forceps size, and nevertheless, the bronchoscopist's experience.

The major complications of TBBx are pneumothorax and bleeding.

Pneumothorax is encountered in 1–6% of patients with performed TBBx [2].

A prospective study of 350 cases revealed that chest X-rays are usually not necessary after TBBx, but it is still recommended for safety reasons [43].

The size of the pneumothorax was associated with the symptoms, so it is possible to have an immediate evaluation of the pneumothorax magnitude based on patient's clinical status. Pneumothorax is a rare instance but may be followed by a pigtail catheter insertion for lung re-expansion. Repeated chest radiographs are usually necessary to follow lung re-expansion and to choose the right moment to extract the chest tube.

Failure to control coughing during TBBx increases pneumothorax risk. Patients with positive-pressure ventilation devices are more likely to manifest pneumothorax after TBBx. In patients with bullous emphysema and in those with pneumocystis pneumonia, the pneumothorax risk is higher [44].

Fluoroscopic guidance during TBBx lowers the risk of pneumothorax. Fluoroscopic examination can reveal pneumothorax cases right after TBBx, but sometimes slowly developing pneumothorax is encountered several hours after the procedure [45].

Tension pneumothorax is a rare event. If no symptoms are present 4 hours after the procedure, a pneumothorax with clinical significance is usually not present. Chest X-ray should be

performed after ½–1 hours after TBBx when high-grade suspicion is present despite normal post-bronchoscopy fluoroscopy. The presence of symptoms and the extent of pneumothorax on chest X-ray establish the management of pneumothorax, but oxygen delivery and continuous inpatient observation usually are sufficient. Another method used in patients with moderate symptoms, but with determined significant pneumothorax, is Heimlich's valve placement in the bronchoscopy lab. In these instances, if repeated X-rays show no increased pneumothorax after 4–6 hours, they can be discharged with Heimlich's valve on. In case of lung re-expansion failure or incomplete lung re-expansion using Heimlich's valve, especially when severe symptoms are present, it is mandatory to place a chest tube drainage system. If pneumothorax is encountered in patients mechanically ventilated, it is also mandatory to place a chest tube system without delay [46].

Bleeding after transbronchial biopsy occurs in 0–26% of cases. Important bleeding is encountered in 1–2% of patients after TBBx [47].

Bleeding risk is higher in patients with renal insufficiency and in patients with depressed immune system, and though sporadic reports of deaths caused by bleeding after TBBx have been published, it is thought to be an underreported instance. Usually, bleeding events developed after TBBx can be managed in the bronchoscopy suite. Patients with minor bleeding after TBBx are usually observed with the bronchoscope, waiting for the bleeding to stop. One should not apply suction near the biopsy area because the clot must be allowed to form. This way, the bleeding is mostly self-limited. The main concern in case of bleeding after a TBBx procedure is not the risk of exsanguination but the risk of flooding other lung segments. That is why one must keep the bronchoscope wedged into the tributary bronchus in order to prevent the blood flooding other lung segments and with the purpose of letting the clot to be formed. This technique has been first described by Zavala [48]. In case of significant bleeding despite bronchus blockage, it is important to put the patient in the safety position, with the affected bleeding side inferiorly.

The wedged position of the bronchoscope can be lost during TBBx and when it happens, the bronchoscopist must reposition the bronchoscope in the same wedged position as soon as possible. Sometimes, this maneuver is difficult when there is significant bleeding from the biopsy site, so the bronchoscopist must be able to reposition the bronchoscope without visual help, only by picturing in his mind the bronchial tree and repeating the exact insertion movements of the bronchoscope in order to reach the previous wedged position. Fluoroscopic guidance can help when endoscopic view is lost. Usually, the bronchoscope is wedged for only 5 minutes, and then it can be gently retracted slowly, verifying the withdrawal step by step and assuring that the bleeding is contained. Another way of dealing with bleeding risk is to withdraw the bronchoscope and to apply suction preventing blood from entering other vicinity pulmonary segments. One can also administer 1:20000 epinephrine in total quantity of 20 ml and cold saline bursts on the channel of the bronchoscope, and as final safety solution, one can place an endobronchial blocker that practically blocks the segmental bronchus tributary to the bleeding biopsy site. Few post-TBBx bleeding cases need endotracheal tubes to secure the airways, balloon tamponade, or even contralateral lung selective

intubation. The existing literature recommends that the bronchoscopy suites should be able to sustain a possible rigid bronchoscopy intubation as ultimate safety solution for these special cases, if the bleeding cannot be controlled only with the help of flexible bronchoscope [46].

Rare complications that have been reported include mediastinal and subcutaneous emphysema.

## 5. Procedure preparation

Each patient should have detailed history taken and thorough physical examination and radiological assessment (chest X-ray and a thoracic computed tomography) before the procedure. A complete blood work is not mandatory but is based on patient's history and clinical evaluation. It should contain complete blood count, coagulation profile, blood chemistry, and arterial blood gas analysis. Spirometry and electrocardiogram are not mandatory before the procedure. These investigations should be reserved for individual clinical relevant findings or in the case of known comorbidities.

Adequate airway examination should precede the transbronchial biopsy. For this to happen in an undisturbed matter and with total patient cooperation, one must control cough with progressive lidocaine instillation, as well as administer sedation with systemic administration of opiates. This way, the patient is calm, with no anxiety or cough that can interfere with the procedure and lead to a higher risk of complications, like pneumothorax.

A proper bronchoscopic and TBBx technique must be mastered, regardless of the degree of sedation and anesthesia used, because it reduces the incidence of complications, also. Fluoroscopy is nevertheless important, when it can be used, because it can increase diagnosis yield and decrease pneumothorax as complication of TBBx. Other factors that can help decrease complication rates are the presence of an intensivist-anesthesiologist and a second interventional pulmonologist. The team must be prepared to intervene in emergency situations like pneumothorax and massive bleeding from the biopsy site. Necessary equipment for complication management, like balloon catheters, endobronchial blockers, chest tubes, or endotracheal intubation tubes must be immediately available [49].

## 6. Pre-procedure concerns

Chest computed tomography (CT) must be performed before bronchoscopy because it shows the anatomic appearance, vascularization, and nearby reports of the targeted lesions. CT can provide a probability diagnosis corroborated with a proper anamnesis especially in patients with sarcoidosis, usual interstitial pneumonia, Langerhans cell histiocytosis, subacute hypersensitivity pneumonitis, acute eosinophilic pneumonia, or lymphangioliomyomatosis. In the event of non-diagnosis abnormalities, chest CT still provide a picture of peribronchovascular

and central lesions that can easily be sampled by TBBx, like centrilobular nodules of ground-glass attenuation, for example [37].

## 7. Equipment

When a TBBx is necessary, one must have an interventional bronchoscopy room equipped with devices for monitoring oxygen saturation, heart rate, blood pressure, respiratory rate, and, if possible, end-tidal CO<sub>2</sub>. Of course, one must have available adult-size flexible video bronchoscope, suction device, biopsy forceps, specimen containers, as well as proper cardiopulmonary resuscitation equipment, and mandatory supplemental oxygen. If possible, in case of emergency, the interventional bronchoscopy multidisciplinary team must be able to convert the flexible bronchoscopy into rigid bronchoscopy, for safety reasons. In regard to the TBBx forceps, it can be cupped and toothed with a needle that can anchor the lesion. It is not mandatory but is recommended to have fluoroscopy equipment in the room for better localization of the lesions and to minimize the risk of pneumothorax [46].

## 8. Patient preparation

Usually, TBBx is performed with the patient in supine position. After positioning, topical anesthesia with lidocaine 2–4% is delivered by spraying or by instilling directly on the nasal and/or oropharyngeal mucosa, depending on the preferred way of inserting the bronchoscope. A good laryngeal anesthesia is then achieved by instilling or aerosolizing lidocaine using a nebulizer.

After a good anesthesia is carried out, the patient can undergo moderate (conscious) sedation using narcotics and benzodiazepines, in incremental doses. This method is safe and increases the yield of TBBx, since the procedure is performed without patient cough or anxiety. Both benzodiazepines and narcotics have different degrees of respiratory depression as side effects, so permanent monitoring is required. The best way of assuring good sampling of the targeted peripheral lung parenchyma remains rigid combined with flexible bronchoscopy, though. In this case, general anesthesia is mandatory [49].

Benzodiazepines are used for their effects of amnesia, anticonvulsant, anxiolytic, muscle relaxant, and behavioral disinhibition.

Usually, midazolam is the best benzodiazepine for short-term moderate sedation because it has the highest lipid solubility (that reassures better nervous system penetration), is one of the fastest onset of action (3–5 minutes), has an incremental dose of 0.5–1 mg (loading dose is around 0.02–0.1 mg/kg), with an average total dose of 1–5 mg that can be administered every 3–5 minutes depending on the degree of sedation needed, and has the shortest effect duration of all intravenous benzodiazepines, of only 0.5–2 hours.

Fentanyl is also used for moderate sedation at a large scale. Its high degree of lipid solubility provides a better penetration in central nervous system structures, as well. Next to morphine, fentanyl has 600 times more lipid solubility and has less hemodynamic effects with the same level of analgesia at a nearly 1/100 of the morphine dose, and the onset of action is faster (1–2 minutes). It has an effect of action 30–60 minutes with a loading dose of 50–100 µg.

Propofol and dexmedetomidine are also used [49].

## 9. Technique

Radiological and fluoroscopic findings, when available, guide the choice of the biopsy site. One should not attempt TBBx from the both lungs in the same procedure because of an increased risk of bilateral pneumothorax. When we have focal disease, the selection of biopsy site is relatively easy to choose. If diffuse disease is present, the choice of biopsy site requires some things to be taken into consideration. In these cases, literature recommends to take the biopsy from the lower lobes, left or right lung, because of the fact that the bleeding is usually contained in these areas before it spills into the other lobes. Biopsy from the upper lobes is to be avoided because the blood can easily pass into other segments from the inferior lobes, bilaterally, and thus limiting the time to react in order to stop the bleeding.

Once the selected site is chosen, the distal end of the bronchoscope is passed through the specific segmental bronchus until it wedges. Then, the biopsies are performed, with the help of fluoroscopy, if available. The forceps is introduced and advanced through the working channel of the bronchoscope until mild resistance is usually felt. This is due to the mild resistance encountered when passing through the distal end of the flexible bronchoscope, especially when the biopsy is performed from the upper lobes or the upper segments of the lower lobes, when distal end is more bended than usual. One must not push very hard in this situation, because the channel of the flexible bronchoscope can very easily be damaged by the forceps. The solution is to slightly let go of the control lever and gently advance the forceps until it passes the distal end of the flexible bronchoscope. In this manner, there is a possibility to lose the wedged position of the bronchoscope in the specific segmental bronchus. In this case, one can retract the bronchoscope from the wedged position and push the forceps a couple of centimeters beyond the distal end of the bronchoscope into the targeted segmental bronchus and then gently advance the bronchoscope using the forceps as guide. Using the fluoroscopic guidance of the TBBx, one should advance the forceps in the selected pulmonary segment until resistance is met. This is due to the fact that the tip of the forceps is very close to the visceral pleura. The forceps is then pulled out 2–3 cm in which time the patient is instructed to take a deep breath and hold for a little while. In this way, the peripheral airways are dilated, and so the forceps can be opened easily. The patient is asked to breathe out while the opened biopsy forceps is gently advanced under fluoroscopic guidance until resistance is met. This is due to the fact that the larger surface of the opened forceps is blocked in its advancement earlier than the narrower surface of the closed forceps by the bifurcation of the respiratory and terminal bronchioles, meaning that the site of the biopsy has been reached. Then, the assistant is asked

to close the forceps that can be gently retracted afterwards. The lung parenchyma is usually sampled by tearing off the respiratory and terminal bronchioles [46].

In case there is a focal lung cancer, presenting like a solitary mass or nodule, by the same method, the forceps is advanced until the tumor's margin is reached. If fluoroscopy is available, now is the time to rotate the arm of the fluoroscope to be aware of the movement of the biopsy forceps related to the lung lesion. A good positioning of the biopsy forceps can be trusted if both the lesion and the forceps move together with the movement of the fluoroscope. After confirming the correct position, the forceps is then retracted approximately 0.5–1 cm and then opened. The opened forceps is then inserted firmly into the mass, this position being also confirmed by fluoroscopy, then closed in a decisive manner, and pulled back gently or slightly rotated along with the retraction. Somehow different from the TBBx of diffuse interstitial lung disease, TBBx of a lung mass or nodule does not need respiratory maneuvers. Another sign of a good position and biopsy is the fact that when the biopsy is actually taken, the lesion moves along with the forceps. The ideal transbronchial biopsy specimen consists of four to six samples, with at least one sample containing full-thickness bronchial mucosa and some alveolar parenchyma, so this maneuver can be repeated several times from the same area of interest, in the same time keeping as much as possible the bronchoscope in a wedged position. This prevents the blood resulting from the biopsy site to spill into other parts of the lungs and favors the blood clot formation having a tamponade effect over the source of bleeding. The period of time required for an acceptable hemostasis is of at least 4 minutes after all biopsies have been taken. Of course, one should not apply suction at any time to allow the formation of the blood clot [46].

## 10. Conclusions

Transbronchial biopsy is a very important tool in the interventional bronchoscopy tools spectrum, mainly due to the fact that surgery can be avoided with a successful TBBx. Patients do not easily accept surgical lung biopsy as diagnosis method because it is more invasive and it requires general anesthesia. TBBx provides an acceptable diagnosis yield in peripheral lung masses, depending on the size of the mass and the presence of bronchus sign, which represent a guarantee that the mass is reachable with the forceps or needle, for that matter. TBBx is also indicated in pulmonary tuberculosis, fungal infections, and other lung infiltrates, when the etiology is unclear. It has an important role in immunocompromised patients and post-lung-transplant patients for the periodic evaluation of the rejection disease, as well as opportunistic infection diagnosis. TBBx has a lower yield, yet important, in the diagnosis of lymphangitis carcinomatosa, sarcoidosis, pulmonary Langerhans' cell histiocytosis, and lymphangioleiomyomatosis. Diagnosis yield is too low to consider in idiopathic pulmonary fibrosis and different types of idiopathic interstitial pneumonia, as well as in lung nodules less than 2–3 cm in diameter. The main complications of this technique are hemoptysis and pneumothorax, encountered in less than 2% of cases. In the event of performing this interventional bronchoscopic procedure, one must be able to efficiently perform the procedure and manage the complications that can follow.

## Author details

Mihai Olteanu<sup>1\*</sup>, Floarea Mimi Nițu<sup>1</sup>, Andreea Golli<sup>1</sup>, Mădălina Olteanu<sup>1</sup>, Adina Turcu<sup>1</sup>, Florentina Dumitrescu<sup>1</sup>, Bogdan Oprea<sup>1</sup>, Ramona Cioboată<sup>1</sup>, Alin Demetrian<sup>1</sup>, Roxana Nemeș<sup>2</sup>, Agripina Rașcu<sup>3</sup>, Edith Simona Ianoși<sup>4</sup> and Tudorel Ciurea<sup>1</sup>

\*Address all correspondence to: m78olteanu@yahoo.com

1 University of Medicine and Pharmacy, Craiova, Romania

2 Institute of Pneumophthisiology "Marius Nasta", Bucharest, Romania

3 University of Medicine and Pharmacy "Carol Davila", Bucharest, Romania

4 University of Medicine, Pharmacy, Sciences and Technologies, Târgu Mureș, Romania

## References

- [1] Mazzone P, Jain P, Arroliga AC, Matthay RA. Bronchoscopic and needle biopsy techniques for diagnosis and staging of lung cancer. *Clinics in Chest Medicine*. 2002;**23**:137-158
- [2] Descombes E et al. Transbronchial lung biopsy: An analysis of 530 cases with reference to the number of samples. *Monaldi Archives for Chest Disease*. 1997;**52**(4):324-329
- [3] Popovich J Jr et al. Diagnostic accuracy of multiple biopsies from flexible fiberoptic bronchoscopy. A comparison of central versus peripheral carcinoma. *The American Review of Respiratory Disease*. 1982;**125**(5):521-523
- [4] Rivera MP et al. Initial diagnosis of lung cancer: ACCP evidence-based clinical practice guidelines (2nd edition). *Chest*. 2007;**132**(3 Suppl):131S-148S
- [5] Tsuboi E et al. Transbronchial biopsy smear for diagnosis of peripheral pulmonary carcinomas. *Cancer*. 1967;**20**(5):687-698
- [6] Naidich DP et al. Solitary pulmonary nodules: CT-bronchoscopic correlation. *Chest*. 1988;**93**(3):595-598
- [7] Bilaceroglu S, Kumcuoglu Z, Alper H, et al. CT-bronchus sign guided bronchoscopic multiple diagnostic procedures in carcinomatous pulmonary nodules and masses. *Respiration*. 1998;**65**:49-55
- [8] Gaeta M, Russi EG, La Spada F, et al. Small bronchogenic carcinomas presenting as solitary pulmonary nodules. Bioptic approach guided by CT-positive bronchus sign. *Chest*. 1992;**102**:1167-1170
- [9] Arancibia F, Ewig S, Martinez JA, et al. Antimicrobial treatment failures in patients with community acquired pneumonia: Causes and prognostic implications. *American Journal of Respiratory and Critical Care Medicine*. 2000;**162**:154-160

- [10] Arghir OC, Dantes E, Otelea M, Rascu A, Borgazi E, Cambre SC. Eight year survey of tuberculosis in-hospital mortality in the South Eastern part of Romania. *Romanian Journal of Legal Medicine*. 2018;**26**(2):183-187
- [11] Wallace JM et al. Bronchoscopy and transbronchial biopsy in evaluation of patients with suspected active tuberculosis. *The American Journal of Medicine*. 1981;**70**(6):1189-1194
- [12] Wang KP, Wise RA, Terry PB, et al. Comparison of standard and large forceps for transbronchial lung biopsy in the diagnosis of lung infiltrates. *Endoscopy*. 1980;**12**:151-154
- [13] Milligan SA, Luce JM, Golden J, Stulbarg M, Hopewell PC. Transbronchial biopsy without fluoroscopy in patients with diffuse roentgenographic infiltrates and the acquired immunodeficiency syndrome. *The American Review of Respiratory Disease*. 1988;**137**:486-488
- [14] Cox ID, Bagg LR, Russell NJ, et al. Relationship of radiologic position to the diagnostic yield of fiberoptic bronchoscopy in bronchial carcinoma. *Chest*. 1984;**85**:519-522
- [15] Griffith DE, Aksamit T, Brown-Elliott BA, et al. An official ATS/IDSA statement: Diagnosis, treatment and prevention of nontuberculous mycobacterial diseases. *American Journal of Respiratory and Critical Care Medicine*. 2007;**175**:367-416
- [16] Patel RG, Patel B, Petrini MF, Carter RR, Griffith J. Clinical presentation, radiographic findings, and diagnostic methods of pulmonary blastomycosis: A review of 100 consecutive cases. *Southern Medical Journal*. 1999;**92**:289-295
- [17] Sabonya RE, Barber RA, Wiens J, et al. Detection of fungi and other pathogens in immunocompromised patients by bronchoalveolar lavage in an area endemic for coccidioidomycosis. *Chest*. 1990;**97**:1349-1355
- [18] Bilaceroglu S, Perim K, Gunel O, Cagirici U, Buyuksirin M. Combining transbronchial aspiration with endobronchial and transbronchial biopsy in sarcoidosis. *Monaldi Archives for Chest Disease*. 1999;**54**:217-223
- [19] Shorr AF, Torrington KG, Hnatiuk OW. Endobronchial biopsy for sarcoidosis. A prospective study. *Chest*. 2001;**120**:109-114
- [20] Trisolini R, Lazzari AL, Cancellieri A, et al. Transbronchial needle aspiration improves the diagnostic yield of bronchoscopy in sarcoidosis. *Sarcoidosis, Vasculitis, and Diffuse Lung Diseases*. 2004;**21**:147-151
- [21] Aranda C, Sidhu G, Sasso LA, Adams FV. Transbronchial lung biopsy in the diagnosis of lymphangitic carcinomatosis. *Cancer*. 1978;**42**:1995-1998
- [22] Travis WD, Borok Z, Roum JH, et al. Pulmonary Langerhans cell granulomatosis (histiocytosis-X). A clinicopathological study of 48 cases. *The American Journal of Surgical Pathology*. 1993;**17**:971-986
- [23] Auerswald U, Barth J, Magnussen H. Value of CD-1 positive cells in bronchoalveolar lavage fluid for the diagnosis of pulmonary histiocytosis-X. *Lung*. 1991;**169**:305-309



- [24] O'Regan A, Fenlon HM, Beamis JF Jr, Steele MP, Skinner M, Berk JL. Tracheobronchial amyloidosis: The Boston University experience from 1984 to 1999. *Medicine (Baltimore)*. 2000;**79**(2):69-79
- [25] Urban T, Lazor R, Lacronique J, et al. Pulmonary lymphangiomyomatosis. A study of 69 patients. *Medicine*. 1999;**78**:321-337
- [26] Bonetti F, Chiodera PL, Pea M, et al. Transbronchial biopsy in lymphangiomyomatosis of the lung. HMB 45 for diagnosis. *The American Journal of Surgical Pathology*. 1993;**17**:1092-1102
- [27] Torre O, Harari S. The diagnosis of cystic lung disease: A role for bronchoalveolar lavage and transbronchial biopsy? *Respiratory Medicine*. 2010;**104**:S81-S85
- [28] Meraj R, Wikenheiser-Brokamp KA, Young LR, et al. Utility of transbronchial biopsy in the diagnosis of lymphangiomyomatosis. *Frontiers in Medicine*. 2012;**6**:395. DOI: 10.1007/s11684-012-0231-5
- [29] Epler GR, Colby TV, McLoud TC, Carrington CB, Gaensler EA. Bronchiolitis obliterans organizing pneumonia. *The New England Journal of Medicine*. 1985;**312**:152-158
- [30] Cordier J-F. Cryptogenic organizing pneumonia. *Clinics in Chest Medicine*. 1993;**14**:677-692
- [31] Bartter T, Irwin RS, Nash G, Balikian JP, Hollingsworth HH. Idiopathic bronchiolitis obliterans organizing pneumonia with peripheral infiltrates on chest roentgenogram. *Archives of Internal Medicine*. 1989;**149**:273-279
- [32] Azzam ZS, Bentur L, Rubin AH, Ben-Izhak O, Alroy G. Bronchiolitis obliterans organizing pneumonia. Diagnosis by transbronchial biopsy. *Chest*. 1993;**104**:1899-1901
- [33] Polpetti V, Cazzato S, Minicuci N, Zompatori M, Burzi M, Schiattone ML. The diagnostic value of bronchoalveolar lavage and transbronchial biopsy in cryptogenic organizing pneumonia. *The European Respiratory Journal*. 1996;**9**:2513-2516
- [34] Cordier JF. Cryptogenic organizing pneumonia. *The European Respiratory Journal*. 2006;**28**:422-446
- [35] Leslie KO, Gruden JF, Parish JM, Scholand MB. Transbronchial biopsy interpretation in the patient with diffuse parenchymal lung disease. *Archives of Pathology and Laboratory Medicine*. 2007;**131**:407-423
- [36] Lacasse Y, Fraser RS, Fournier M, Cormier Y. Diagnostic accuracy of transbronchial biopsy in acute farmer's lung disease. *Chest*. 1997;**112**:1459-1465
- [37] Gruden JF, Webb WR, Naidich DP, McGuinness G. Multinodular disease: Anatomic localization at thin section CT-multireader evaluation of a simple algorithm. *Radiology*. 1999;**210**:711-720

- [38] Wahidi MM, Rocha AT, Hollingsworth JW, Govert JA, Feller-Kopman D, Ernst A. Contraindications and safety of transbronchial biopsy via flexible bronchoscopy. *Respiration*. 2005;**72**:285-295
- [39] Morris MJ, Peacock MD, Mego DM, Johnson JE, Anders GT. The risk of hemorrhage from bronchoscopic lung biopsy due to pulmonary hypertension in interstitial lung disease. *Journal of Bronchology*. 1998;**5**:117-121
- [40] Diaz-Guzman E, Vadi S, Minai OA, Gildea TR, Mehta AC. Safety of diagnostic bronchoscopy in patients with pulmonary hypertension. *Respiration*. 2009;**77**:292-297
- [41] Herth FJF, Becker HD, Ernst A. Aspirin does not increase bleeding complications after transbronchial biopsy. *Chest*. 2002;**122**:1461-1464
- [42] Ernst A, Eberhardt R, Wahidi M, Becker HD, Herth FJF. Effect of routine clopidogrel use on bleeding complications after transbronchial biopsy in humans. *Chest*. 2006;**129**:734-737
- [43] Izbicki G, Romem A, Arish N, Cahan C, Azulai H, Chen-Shuali C, et al. Avoiding routine chest radiography after transbronchial biopsy is safe. *Respiration*. 2016;**92**(3):176-181
- [44] Broddus C, Dake MD, Stulbarg MS, et al. Bronchoalveolar lavage and transbronchial biopsy for diagnosis of pulmonary infections in the acquired immunodeficiency syndrome. *Annals of Internal Medicine*. 1985;**102**:747-752
- [45] Ahmad M, Livingston DR, Golish JA, Mehta AC, Wiedemann HP. The safety of outpatient bronchoscopy. *Chest*. 1986;**90**:403-405
- [46] Mehta AC, Jain P, editors. *Interventional Bronchoscopy: A Clinical Guide*, Respiratory Medicine 10. New York: © Springer Science+Business Media; 2013. DOI: 10.1007/978-1-62703-395-4\_2
- [47] Milman N, Fourschou P, Munch EP, Grode G. Transbronchial lung biopsy through fiberoptic bronchoscope. Results and complications in 452 examinations. *Respiratory Medicine*. 1994;**88**:749-753
- [48] Zavala DC. Pulmonary hemorrhage in fiberoptic transbronchial biopsy. *Chest*. 1976;**70**(5):584-588
- [49] Lessnau KD et al. Transbronchial Biopsy. Updated 23-03-2017, Medscape. Available from: <https://emedicine.medscape.com/article/1894323-overview>

