

CASE REPORT

Huge abdominal swelling due to haemorrhagic splenic cyst

MR Islam¹, MG Rahman², MD Parvin³

Abstract

Splenic cyst is an uncommon problem in surgical practice. It is usually diagnosed in scanning procedure. In some cases it produces symptoms like abdominal mass, abdominal pain, distention, constipation either due to haemorrhage, rupture or big size. In our case, patient presents with abdominal pain, distention, vomiting, constipation and respiratory embarrassment. Routine investigation was done and diagnosis was confirmed after laparotomy, Splenectomy was done. Post operative recovery was good.

Introduction

Splenic cysts are unusual in everyday surgical practice. They can be Parasitic (Hydatid cyst) caused by *ecchinococcus granulosus* or Nonparasitic.^{1,2} Nonparasitic cysts are again divided into True or Primary lined by an epithelial cover (epidermoid, dermoid and mesothelial) or endothelial cover (haemangioma, lymphangioma). False or secondary or pseudo cyst (non-epithelial or connective tissue covering), usually traumatic in origin.^{3,4} Primary Splenic cysts comprise 30-40% and commonly occur in children and young adults.^{5,6} Small cysts are usually asymptomatic and diagnosed incidentally during abdominal scanning (Ultrasonography, CT scan or MRI).⁷ Splenectomy is the method of choice for the treatment of large primary splenic cyst.^{5,8} Conservative surgical approach has been advised for small cyst especially in children or young adult to avoid post splenectomy infections.^{4,8} Here we present a case of huge Splenic cyst with diagnosis and management.

Case report

Mr. Fahim, a boy of 16 years old coming from Sheikh Para, Khulna was admitted in a private clinic in Khulna city on 29/12/2014 with complaints of huge abdominal distention, pain, vomiting with embarrassment of respiration for 7 days. The patient was unnoticed about his symptoms even one week back then he gradually developed huge abdominal distention which is associated with severe pain and vomiting. Later on

he developed constipation and respiratory embarrassment as well. Patient was unable to take food. On examination, the patient was ill looking, anaemic, no jaundice or oedema, the abdomen was tense and tender.

The abdomen was dull on percussion, fluid thrill was positive but no shifting dullness, bowel sound was found normal. On investigation his blood counts were normal, USG reports shows a cystic mass occupying whole of the abdomen from xiphoid process to pubic symphysis, and both flanks are full. Left kidney was not found in its own position. Plain X Ray abdomen shows ground glass appearance, no gas fluid level was found. Clinically it was diagnosed as a case of huge Hydronephrosis. Differential diagnosis were volvulus of sigmoid colon, perforation of gas containing hollow viscous or other causes of intestinal obstruction including intra abdominal malignancy. Patient was decided for urgent laparotomy as an emergency case.

Abdomen was opened with a midline incision. The huge mass was found to be a splenic cyst and was diagnosed by the presence of notched appearance at the anterior border. The cyst was decompressed, it contains haemorrhagic fluid, and the amount was about two liters. Splenectomy was done (Fig-1). Two units of whole blood were transfused peroperatively. Abdomen was closed with a drain at left sub diaphragmatic space after proper haemostasis. Patient was discharged on eighth postoperative

1. Md. Rafiqul Islam FCPS, Senior Consultant (Surgery), General Hospital, Khulna.

2. Md. Gulzar Rahman MBBS, Resident Surgeon, Gazi Medical College Hospital, Khulna.

3. Mst. Dilruba Parvin MBBS, Medical Officer, RHSTEP Khulna Medical College Hospital, Khulna.

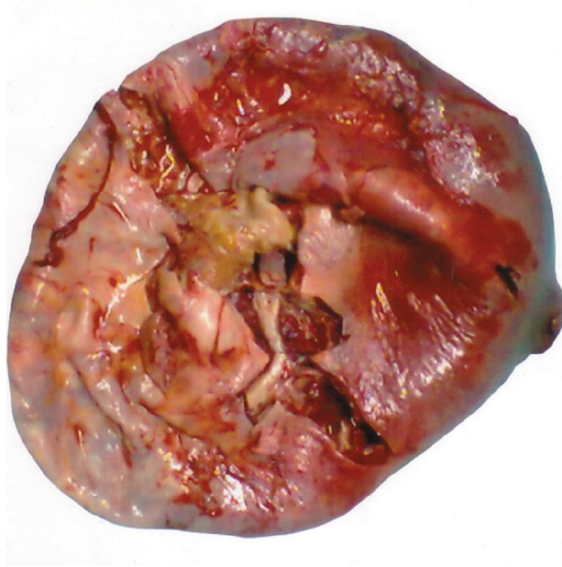

Fig. 1: Splenic cyst after operation

day without any complication. On subsequent follow up for one year patient was completely well both physically and mentally (Fig-2). Histopathologically it was a false cyst of degenerative origin.

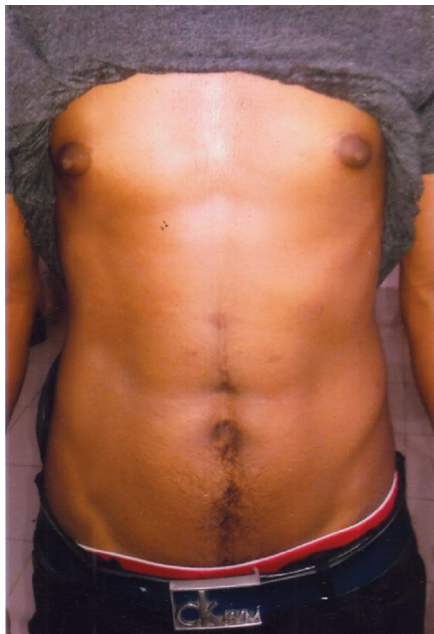


Fig. 2: The patient, one year after splenectomy operation

Discussion

Small Splenic cysts are usually asymptomatic and diagnosed incidentally during scanning procedure.

Large cyst may cause pain and heaviness at left hypochondrium due to distention of capsule or space occupying mechanism within abdominal cavity or may present as palpable mass.^{3,5,9} In our case patient presents symptoms due to huge space occupying lesion causing abdominal pain, distention, respiratory embarrassment etc.

When patient presents lump at left hypochondrium it is necessary to exclude other cause of splenomegaly (mononucleosis, chronic leukemias, collagen vascular disease, liver disease).¹² Serological study is useful in excluding most of the above causes. In our case only routine examinations were done due to emergency situation. USG is able to diagnose the cause either cystic or solid in nature. Computed tomography and Magnetic resonance imaging may give most of the information, composition, location, position, relation with surrounding tissues.^{5,7,10} There are different types of surgical treatments according to the age; size, location and position of the cyst. The classical approach to Splenic cyst is open complete splenectomy.^{5,8} Other options are partial splenectomy, total cystectomy, marsupialization or cyst decapitation (unroofing) associated either by open laparotomy or laparoscopy.⁵ Partial splenectomy should preserve 25% of splenic tissue, which is the minimum splenic tissue to preserve immunological protection.^{5,10} Partial cystectomy can safely be done by laparoscopic, approach.

Splenic cyst larger than 5cm or symptomatic one should be treated surgically. If the cyst is very large and almost covered by splenic tissue or if it is located in the splenic hilum, complete splenectomy is recommended. Partial cystectomy (unroofing) could be the acceptable procedure in the majority of other cases. Laparoscopic procedure seems to be safe procedure in expert hand. In our cases the cyst is huge in size, almost occupying whole of the abdomen, so laparotomy, decompression and total splenectomy was the procedure of choice.

References

1. Macheras A et al, Non parasitic splenic cysts . A report of three cases. World J. of gastroenterol 2005; 11:6834-87
2. Avital S, Kashtan H. A large epithelial splenic cyst. N Engl J Med 2003; 349: 2173-2174

3. Safioleas M, Misiakos E, Manti C. Surgical treatment for splenic hydatidosis. *World J Surg* 1997; 21: 374-378
4. Reddi VR, Reddy MK, Srinivas B, Sekhar CC, Ramesh O. Mesothelial splenic cyst a case report. *Ann Acad Med Singapore* 1998; 27: 880-882
5. Heidenreich A, Canero A, di Pasquo A. Laparoscopic approach for treatment of a primary splenic cyst. *Surg Laparosc Endosc* 1996; 6: 243-246
6. Hansen MB, Moller AC. Splenic cysts. *Surg Laparosc Endosc Percutan Tech* 2004; 14: 316-322
7. Robertson F, Leander P, Ekberg O. Radiology of the splen. *Eur Radiol* 2001; 11: 80-95
8. Smith ST, Scott DJ, Burdick JS, Rege RV, Jones DB. Laparoscopic marsupialization and hemisplenectomy for splenic cysts. *J Laparoendosc Adv Surg Tech A* 2001; 11: 243-249
9. Trompetas V, Panagopoulos E, Priovolou Papaevangelou M, Ramantanis G. Giant benign true cyst of the splen with high serum level of CA 19 9. *Eur J Gastroenterol Hepatol* 2002; 14: 85-88
10. Labruzzo C, Haritopoulos KN, Tayar AR, Hakim NS. Post traumatic cyst of the spleen: a case report and review of the literature. *Int Surg* 2002; 87: 152-156