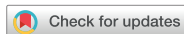

Original Article
Infectious Diseases,
Microbiology & Parasitology



Human Sparganosis in Korea

Jeong-Geun Kim ,¹ Chun-Seob Ahn ,¹ Woon-Mok Sohn ,² Yukifumi Nawa ,³
and Yoon Kong ¹

¹Department of Molecular Parasitology, Samsung Medical Center, Sungkyunkwan University School of Medicine, Suwon, Korea

²Department of Parasitology and Tropical Medicine, Institute of Health Science, Gyeongsang National University College of Medicine, Jinju, Korea

³Tropical Diseases Research Center, Faculty of Medicine, Khon Kaen University, Khon Kaen, Thailand



Received: May 8, 2018

Accepted: Jul 5, 2018

Address for Correspondence:

Yoon Kong, MD, PhD

Department of Molecular Parasitology,
Samsung Medical Center, Sungkyunkwan
University School of Medicine, 2066 Seobu-ro,
Jangan-gu, Suwon 16419, Republic of Korea.
E-mail: kongy@skku.edu

© 2018 The Korean Academy of Medical
Sciences.

This is an Open Access article distributed
under the terms of the Creative Commons
Attribution Non-Commercial License ([https://
creativecommons.org/licenses/by-nc/4.0/](https://creativecommons.org/licenses/by-nc/4.0/))
which permits unrestricted non-commercial
use, distribution, and reproduction in any
medium, provided the original work is properly
cited.

ORCID iDs

Jeong-Geun Kim

<https://orcid.org/0000-0002-4162-5109>

Chun-Seob Ahn

<https://orcid.org/0000-0001-7719-4817>

Woon-Mok Sohn

<https://orcid.org/0000-0002-9795-9386>

Yukifumi Nawa

<https://orcid.org/0000-0002-0206-5196>

Yoon Kong

<https://orcid.org/0000-0003-0905-4606>

Disclosure

The authors have no potential conflicts of
interest to disclose.

ABSTRACT

Background: Sparganosis is a larval cestodiasis caused by the plerocercoid of *Spirometra* spp. Since the first description of human sparganosis in 1924, several hundred cases have been reported in Korea. However, systematic approaches for literature surveys of Korean sparganosis have seldom appeared.

Methods: We searched publicly available databases such as PubMed, Research Information Sharing Service, and Korea Medical Citation Index with relevant Medical Subject Headings.

Results: At least 438 Korean sparganosis cases have been described from 1924 to 2015. Preoperative diagnosis has been significantly increased since the 1980s due to popularization of serological and imaging diagnostics. Cases were largely detected from fifth decades in general, but cerebral sparganosis was detected in relatively young age groups (third and fourth decades). Sparganosis was prevalent in men (75.9%). Consumption of frog/snake and drinking unfiltered water were found in 63.4% and 16.9% of patients, respectively. Most frequently affected sites were subcutaneous tissues (49.9%), followed by the central nervous system (36.2%). Involvements of visceral organs (7.6%), ocular regions (3.6%), and muscles (2.7%) were noticed. In women, breast sparganosis constituted a large proportion (34.2%). Sparganosis associated with immunocompromised patients has recently been reported.

Conclusion: Sparganosis has been continuously reported in Korea during the past 90 years, although its incidence has decreased during the last 20 years. The disease is mostly characterized by subcutaneous nodule, but infection of the worm in vital organs often results in serious illness. Continuous awareness is warranted to monitor sparganosis occurrence and associated clinical consequences.

Keywords: Sparganum; Sparganosis; Korea; Subcutaneous Tissue; Central Nervous System; Immunocompromised Patient

INTRODUCTION

Sparganosis is a larval cestodiasis (metacestodiasis) triggered by infection with the plerocercoid of *Spirometra* spp. of which adults thrive in the small intestine of canine or feline host (<https://www.cdc.gov/dpdx/sparganosis/index.html>). Humans mostly serve as an intermediate host and are infected with larval worms (plerocercoid: sparganum, pl. spargana). The sparganum might grow into an adult in human intestine in extremely rare cases.¹

Author Contributions

Conceptualization: Nawa Y, Kong Y. Data curation: Kim JG, Sohn WM, Nawa Y, Kong Y. Formal analysis: Kim JG, Ahn CS, Kong Y. Writing - original draft: Kim JG, Kong Y. Writing - review & editing: Ahn CS, Sohn WM, Nawa Y, Kong Y.

Drinking unfiltered water that contains cyclops infected with procercoid and/or ingesting raw or inadequately cooked flesh of frogs/snakes or other paratenic hosts are important sources of human infections. Application of raw flesh/skin of poikilothermic intermediate hosts to subside sore edema and ophthalmitis is also a risk factor.²⁻⁴

Sparganosis has been sporadically detected globally, but the majority of cases occurred in East and Southeast Asian countries in relation to their eating habits and traditional medical practice.⁴ The disease is principally characterized by a slowly migrating subcutaneous nodule(s), but infection may occur in any part of the body. Infection of the worm(s) in vital organs often results in serious illness. The parasite might invoke symptoms as early as two months postinfection.² Sometimes patients could remain asymptomatic for approximately 17 years.³ Different *Spirometra* spp. can cause human infections. *Spirometra mansoni* in Europe, *Spirometra mansonoides* in America, and *Spirometra erinaceieuropaei* in Asia including Korea.⁵ A recent morphological and molecular study has demonstrated that *Spirometra decipiens* plerocercoid is involved in Korean sparganosis.⁶

Sparganosis has not been uncommon in Korea. The following factors might be associated with the development of disease. Farmers working in rice paddies or in the forest might drink unfiltered water when they are thirsty during work as a long traditional lifestyle of aquaculture or forestry activity. Some people used to consume flesh of frog and/or snake to treat tuberculosis, arthralgia, and neuralgia.³ Previous seroepidemiological surveys of apparently healthy persons in Korea have demonstrated seropositive rates of 1.7%–3.3% for sparganosis. Large proportions (40.4%–62.5%) of seropositive people were old men aged over sixth decades,^{7,8} suggesting that such traditional habits might be linked to hidden infections, although non-specific serological cross-reactions by some other underlying factors could not be ruled out.⁹

In Korea, an authentic case of sparganosis in the lower leg was firstly found in 1917 which was described in 1924.¹⁰ Several hundreds of cases were thenceforward reported. However, systematic approaches of literature survey of human sparganosis in Korea have rarely appeared.^{2,3,11} In the present study, we provide an overview and perspectives of human sparganosis in Korea by mining the publicly available databases during the period of 1924 to 2015.

METHODS**Literature survey**

Published reports were searched from publicly available databases which included PubMed (www.ncbi.nlm.nih.gov/pubmed), Research Information Sharing Service (RISS; <https://www.riss.kr>), and Korea Medical Citation Index (KoMCI; <https://komci.org/>). We used terms “sparganosis,” “*Spirometra*,” and “Korea” in conjunction with associated Medical Subject Headings (MeSH) in the National Library of Medicine (<https://www.nlm.nih.gov/mesh/>).

Collection of sparganum from Korean terrestrial snakes

We examined 81 terrestrial snakes that had been caught in the southern part of Korea (Gyeongsangnam-do). Those snakes were donated by the Association of Wild Animals Protection for research purpose, including 38 *Agkistrodon brevicaudus*, 25 *Rhabdophis tigrinus*, and 15 *Elaphe rufodorsata*. The snakes were individually anesthetized with ethyl ether and sacrificed. Each snake was examined for the presence of sparganum.

Ethics statement

Euthanasia of moribund snakes was approved by the Institutional Review Board of Gyeongsang National University School of Medicine (approval No. GNU-03-008). Informed consent was not needed.

RESULTS

Survey of Korean sparganosis cases in publicly available domains

We were able to collect information on 438 human sparganosis cases from 159 articles published in 51 journals. We found 55 papers in PubMed and 104 papers in two Korean paper search sites (RISS and KoMCI). Twenty-six and 75 articles were independently listed in PubMed and Korean search sites, respectively, among which 29 articles could be found in all search conditions. Out of the 51 Journals, the largest number of articles dealt with human sparganosis had been found in the *Korean Journal of Parasitology*, which contained 156 case reports. A total of 48 cases of human sparganosis were reported in the *Journal of the Korean Society of Radiology*. In addition, 35 and 12 cases were retrieved from the *Journal of Korean Neurosurgical Society* and the *Korean Journal of Urology*, respectively. The other 187 cases were reported in *Radiology*, *Neuroradiology*, *Urology*, and other international journals (We only listed three major journals that published the most Korean sparganosis).

Epidemiological characteristics

We analyzed the number of sparganosis cases reported in Korea during the period of 1924 to 2015 (Fig. 1). A previous study reported a total of 63 cases during the period of 1924–1974: 58 cases from 1924 to 1973 and additional five cases in 1975.³ At that time, preoperative diagnosis of sparganosis was almost impossible. Moreover, academic capacity to preserve medical literature between 1944 and 1953 had been chaos due to social crisis. Social and medical infrastructures were very poor in Korea, which might have hampered appropriate evaluation of medical situations including those of sparganosis.^{2,3}

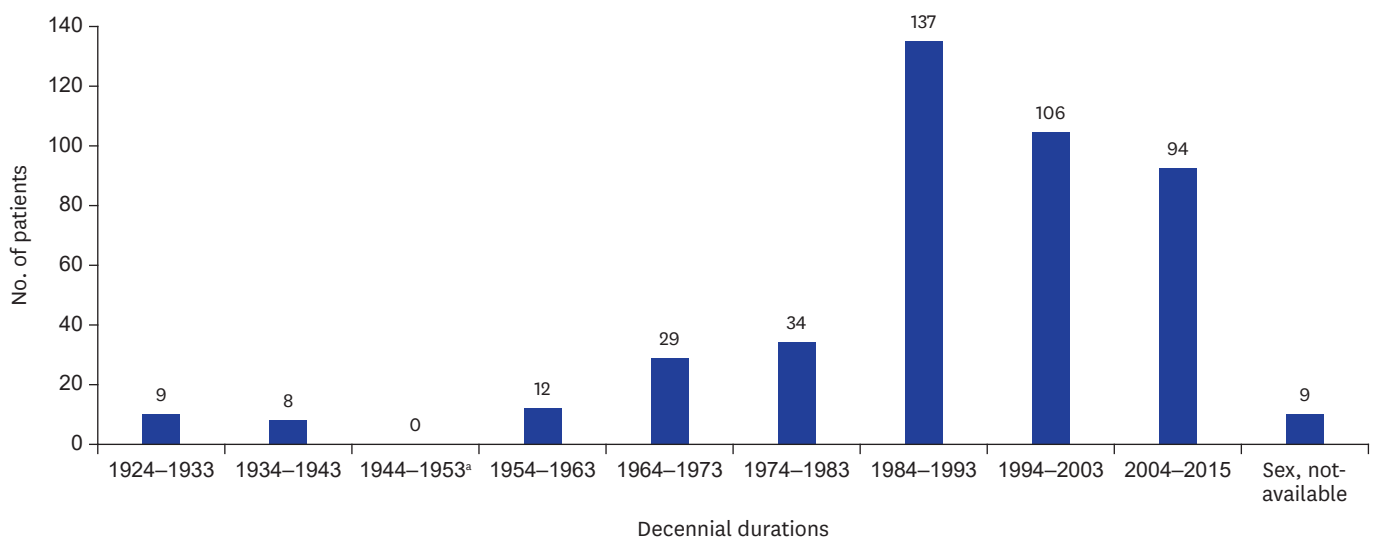


Fig. 1. Decennial distribution patterns of human sparganosis reported in Korea during 1924–2015. At least 438 sparganosis cases were reported in Korea. Cases reported between 1924 and 1953 referred to cases recorded in Korean peninsula and those after 1954 represented sparganosis reported in the Republic of Korea. Duplicated publications were excluded by reviewing individual papers.

^aMost medical records in Korea were not preserved during 1944–1953 due to the Pacific War (1941–1945), post-war chaos (1945–1948) and the Korean War (1950–1953).³

Since the late 1970s, human sparganosis continue to occur in Korea. Min¹¹ found additional 56 cases through literature survey between 1975 and 1989. Our literature search revealed that a total of 243 cases were described between 1984 and 2003 (Fig. 1) including those listed by Cho et al.³ and Min.¹¹ Thereafter, cases seemed to be decreased to some extent. Nevertheless, sparganosis cases have been continually reported during the last 15 years (94 cases between 2004 and 2015).

A drastic increase of sparganosis cases from the early 1980s might be due to the development and popularization of diagnostic modalities which allow easier and earlier detection of preoperative patients. Imaging diagnostics including computed tomography (CT)/magnetic resonance imaging (MRI)/ultrasonography (US) have become widely applied for the diagnosis of sparganosis, through which pathognomonic signs for sparganosis are established (see also later sections).^{12,13} Serological tests using crude extracts of the sparganum as antigen has yielded sensitivity of 85.7%–90% and specificity of 87%–97.5% and purified protein fractions of 31 and 36 kDa have exhibited sensitivity and specificity over 95%.^{9,14,15} By these means, preoperative diagnosis of sparganosis cases, especially those of the central nervous system (CNS) and subcutaneous tissues including breast, has been substantially improved.

Fig. 2 shows age and gender distribution of patients. Patients were largely diagnosed between their third and sixth decades. However, 10 cases (2.5%) were detected in their early ages (under 10 years), suggesting that people might have been exposed to infection sources from childhood. Among cases with available demographic data (398 cases), the incidence of sparganosis was 2.5 times higher in men (284 cases) than that in women (114 patients).

Drinking unfiltered water contaminated with cyclops harboring proceroid and/or contraction with snakes/frogs infected with plerocercoid might be intimately involved in human sparganosis.^{2,3} We analyzed such behavioral habits of patients. Ingestion of snake and/or frog was recognized in 63.4% (203 patients) of patients whose eating history was available (320 cases). Drinking unfiltered water was also observed in 16.9% (54 cases) of these patients. However, 19.7% (63 cases) of patients denied exposure to any possible infection source (Table 1).

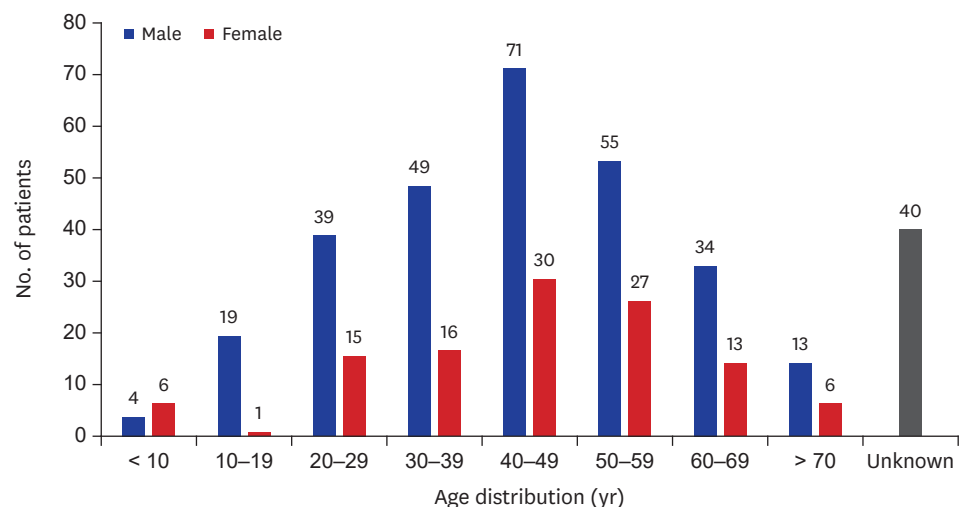


Fig. 2. Age and sex distribution of sparganosis cases in Korea. Among 438 cases, 284 patients were men and 114 patients were women. We could not trace personal information for 40 cases.

Table 1. Behavioral habits of Korean sparganosis cases^a

Sources	No. of cases (%)
Snakes and frogs	63 (19.7)
Snakes	101 (31.6)
Frogs	39 (12.2)
Unfiltered water	54 (16.9)
Negative	63 (19.7)
Subtotal	320 (100.0)
Not-available	118
Total	438

^aConsumption and drinking experiences of intermediate/transport hosts related to transmission of sparganosis.

Many studies have observed infection status of the sparganum in frogs and snakes in Korea from the mid-1920s to the mid-1980s.^{11,16-18} Examination of snakes and frogs revealed variable infection rates of 3.1%–100%. Infection status of snakes was higher than that of frogs.¹¹ In 2003, we examined 81 Korean terrestrial snakes including 38 *Agkistrodon brevicaudus*, 25 *Rhabdophis tigrinus* and 15 *Elaphe rufodorsata* with an aid from the Association of Wild Animals Protection because those snakes were illegally caught. We observed that the infection rate reached 60.5%–92.5%, with mean worm density of 37.7 worms per snake (Table 2). This result confirmed that snakes might be an important intermediate/paratenic host related to transmission of sparganosis to humans.

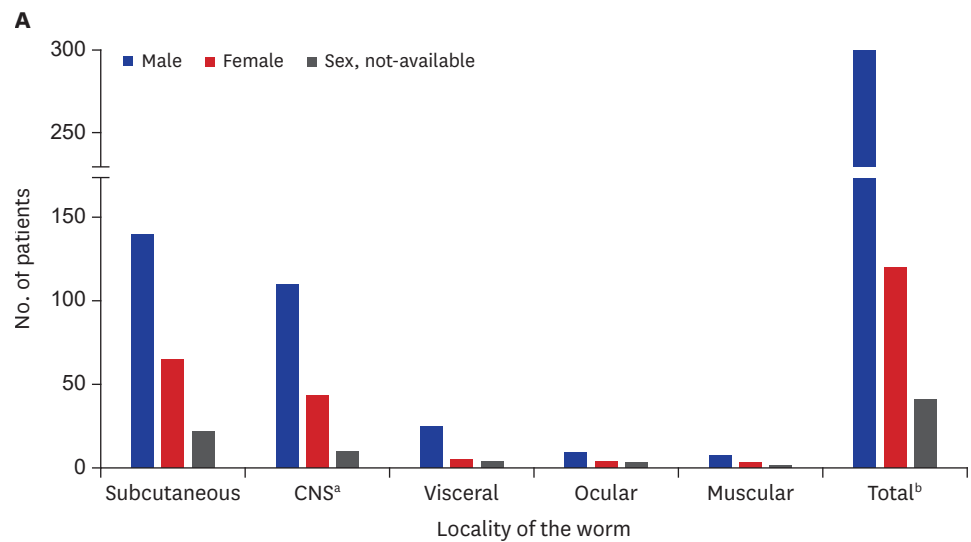
When we analyzed infection sites of sparganosis cases in the human body (438 cases), subcutaneous tissues were the most commonly affected sites (49.9%; 223 cases), followed by the CNS (36.2%; 162 patients) including the spinal cord. Infection of visceral organs was recognized in 7.6% of patients (34 cases). Ocular cases were observed in 16 patients (3.6%). Muscular sparganosis was recorded in 12 patients (2.7%) (Fig. 3). A total number of affected sites exceeded 438 due to infections at multiple sites in seven patients (four cases of subcutaneous and muscular infections, two each case with subcutaneous and visceral infections, and one case of systemic infection).

Subcutaneous sparganosis

Sparganosis of subcutaneous tissues was most commonly described in Korea, similar to that observed in other countries.^{4,19-21} Table 3 depicts localities of lesions in the body, number of cases and gender/age distributions among 218 subcutaneous sparganosis reported in Korea (total number was 223 due to multiple infections). We were able to trace medical records of 202 patients, in which men constituted 68.3% (138/202 cases). The most frequently affected site was the lower extremity (35%), followed by trunk (26%). Involvement of the scrotum was observed in 11.7% of men. In women, breast was the most predilection site (34.2%). Clinical and imaging findings of breast sparganosis have previously been summarized.²² Major symptoms of subcutaneous sparganosis included painless mass (91 cases) and painful mass (39 patients). Other symptoms included itching sensation of the infected sites (23 cases) and hemorrhagic mass (5 patients). Some cases with scrotal sparganosis were associated with Fournier's gangrene (19.2%; 5/26 patients). Eleven patients did not complain of any

Table 2. Infection status of sparganum in terrestrial snakes collected from Gyeongsangnam-do, Korea (2003)

Species of snake	No. of examined	No. of infected (%)	No. of spargana detected		
			Total	Range	Average
<i>Agkistrodon brevicaudus</i>	38	23 (60.5)	355	1–215	15.4
<i>Rhabdophis tigrinus</i>	28	26 (92.9)	1,686	2–237	64.8
<i>Elaphe rufodorsata</i>	15	12 (80.0)	396	1–125	33.0
Total	81	61 (75.3)	2,437	1–237	37.7



B

Location	No. of cases (%)	Male (%)	Female (%)	Sex, not-available
Subcutaneous	223 (49.9)	138 (47.9)	64 (53.8)	21
CNS ^a	162 (36.2)	109 (37.9)	43 (36.1)	10
Visceral	34 (7.6)	25 (8.7)	5 (4.2)	4
Ocular	16 (3.6)	9 (3.1)	4 (3.4)	3
Muscular	12 (2.7)	7 (2.4)	3 (2.5)	2
Total ^b	447 (100)	288 (100)	119 (100)	40

Fig. 3. Number and sex distribution of cases according to infection sites.

CNS = central nervous system.

^aCNS sparganosis included spinal cord infection; ^bTotal number of cases exceeded 438 due to infections at multiple sites in 7 cases (4 cases of subcutaneous and muscular infections, 2 cases with subcutaneous and visceral infections, and 1 case of systemic sparganosis).

symptom. We could not trace clinical information for 44 patients. Cases with subcutaneous sparganosis were largely detected in the sixth decade (age distribution, 4–85 years). However, a 4-year-old boy and a 6-year-old boy who visited a clinic with chief complaint of a painful neck mass and a painless cystic mass on the scrotum, respectively, were found to be infected with sparganum. The boy who had a neck mass had no history of exposing to any possible infection source while the other boy with scrotal mass had a history of drinking water from mineral springs.^{23,24}

Table 3. Number of subcutaneous sparganosis patients in each body compartment along with sex and age distribution

Localities	No. of cases (%)	Male	Female	Sex, not-available	Age distribution (mean)
Lower extremities	78 (35.0)	55	12	11	27–85 (53.2)
Trunk	58 (26.0)	44	7	7	44–75 (58.8)
Breast	39 (17.5)	0	39	0	29–81 (54.7)
Scrotum	26 (11.7)	26	0	0	32–75 (53.0)
Inguinal area	6 (2.7)	2	2	2	45–63 (53.0)
Upper extremities	5 (2.2)	3	1	1	40–49 (44.5)
Axilla	4 (1.8)	3	1	0	52–61 (56.5)
Penile shaft	2 (0.9)	2	0	0	36–72 (54)
Neck	2 (0.9)	2	0	0	4–80 (42)
Vulva	2 (0.9)	0	2	0	32–52 (42)
Spermatic cord	1 (0.5)	1	0	0	6 (6.0)
Total	223 (100)	138	64	21	4–81 (47.1)

Plain radiographs of subcutaneous sparganosis often show linear or elongated calcifications. Nodular elongated soft tissue mass shadows might also be observed, but not always.²⁵ US findings include poorly-/well-defined, heterogeneous hypoechoic mass in affected sites and multiple elongated, folded, band-like hypoechoic tracts with serpiginous tubular echogenicity.^{25,26} On CT/MRI, multiple serpiginous tubular tracts having peripheral rim enhancement with perilesional soft tissue edema have been recognized.^{27,28}

Sparganosis of the CNS and spinal cord

In Korea, at least 162 cases of CNS involvement including the spinal cord were reported. One case was infected at both CNS and the spinal cord²⁹ while 13 cases were spinal cord infections (Table 4). The proportion of CNS cases was remarkably high in Korea compared to that in other countries.^{4,19-21} Since the early 1980s', most cerebral cases were diagnosed preoperatively by specific serological tests together with neuroimaging modalities.^{9,12,30-32} CNS involvement was significantly higher in men (75.9%) than that in women (24.1%) among 116 patients whose demographical information was available. Age of these patients ranged from 6 to 72 years. The third (20.7%), fourth (23.2%), fifth (19.8%), and sixth (19.8%) decades constituted major populations (Fig. 4).

Neuroimaging findings have demonstrated pathognomonic features of cerebral sparganosis, including white matter hypodensity with adjacent ventricular dilatation, irregular or nodular enhancing lesion, and small punctate calcifications. Cortical atrophy has also been recognized in many patients.³⁰ Contrast images of MRI have better resolution than CT in detecting degenerated tissues.³¹ On neuroimaging scans taken at follow-up monitoring, location or shape of the enhancing lesion is typically altered, suggesting possible

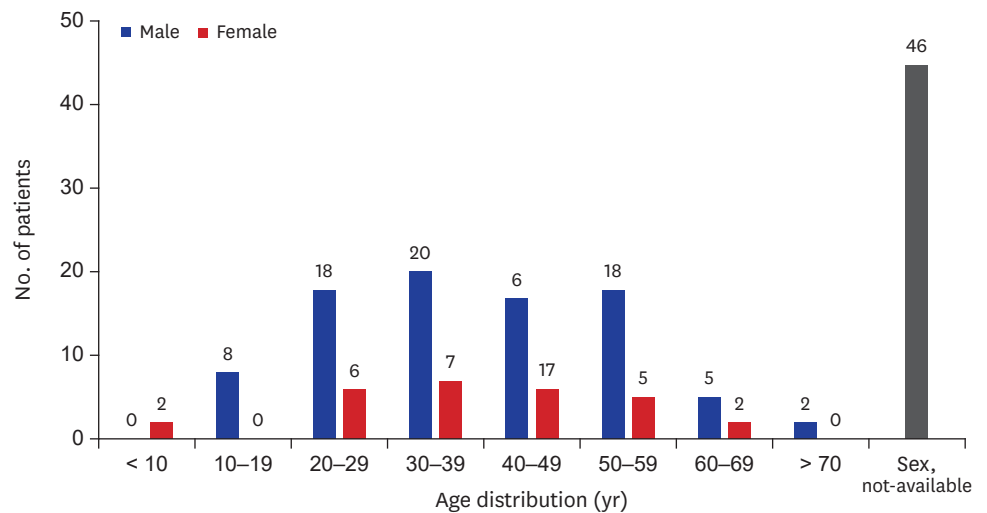


Fig. 4. Age and sex distribution of patients with cerebral sparganosis whose demographic information is available (n = 116).

Table 4. Number of cerebral sparganosis cases in Korea

Localities	No. of cases (mean ages)		Sex, not-available	Total
	Male	Female		
CNS	100 (35.1)	39 (37.2)	9	148
Spinal cord	9 (49.3)	3 (42.5)	1	13
CNS + spinal cord	0	1 (42.0)	0	1
Total	109 (42.2)	43 (40.6)	10	162

CNS = central nervous system.

wondering of the worm in the hemisphere. This finding is also highly specific for cerebral sparganosis.³¹

Major symptoms of 148 CNS patients included seizure (20.9%), headache (12.8%), and hemiparesis (6.8%). Altered mental functions such as cognition difficulty, decreased memory and calculation, and intellectual deterioration were observed in 17 cases (11.5%). In addition, some patients manifested with motor weakness (4.7%). These symptoms were shown to be progressed with wax and wane patterns along with the course of the disease. Two patients (1.4%) underwent status epilepticus. Principal symptoms of spinal sparganosis included voiding difficulty (38.5%), back pain (38.5%), and paresis (23.1%). The patient who had concomitant infections in the CNS and spinal cord presented seizure, signs and symptoms of increased intracranial pressure, facial palsy, hearing loss, voiding difficulty, and paresis of the lower extremities. The patient's symptoms were significantly improved after surgical removal of worms in the cerebellar-pontine angle and in the 3rd–5th lumbar spinal cord together with decompression of communicating hydrocephalus by ventriculoperitoneal shunt operation.²⁹

Visceral sparganosis

Sparganosis of visceral organs were relatively infrequent in Korea (7.8%; 34/438 patients). Patients' ages were between 23 and 70 years (mean: 50.6 years). Ratio of man and woman patients was 4.8:1. As shown in **Table 5**, worms were found in several different organs/tissues, among which the urogenital system (29.4%), the lung (29.4%), and the intestine (23.5%) were mainly affected organs. In the urogenital system, bladder wall, epididymis, and penile shaft infections were described. A ureteral stone associated with sparganum has been reported.³² Pleural sparganosis could provoke chest pain, pleural effusion, dyspnea, and/or empyema.³³ Sparganum infected in the intestinal wall caused obstruction, perforation, or abscess formation. An intraperitoneal mass causing abdominal pain has been reported.³⁴ Imaging scans of patients have revealed poorly defined, heterogeneous mass with increased echogenicity, and/or cavitating mass. In addition, double hypoechoic rings surrounding the mass, i.e., “tubule-in-a-tubule” appearance could be observed.³⁵ One case of pericardial mass presenting recurrent pericardiopleural effusion, chest pain, and dyspnea was reported. The patient consumed raw frog flesh more than 30 times for treatment of thyroid disease. She was treated with three consecutive doses of praziquantel (75 mg/kg/day), after which symptoms and pericardial effusion gradually disappeared. However, follow-up surveillance of the patient's anti-sparganum specific antibody level remained to be strongly positive.³⁶ A sparganosis causing retropharyngeal abscess has been recorded in the literature, while detailed history was unavailable.³

Ocular sparganosis

In Southeast Asian countries including southern China, large numbers of ocular sparganosis have occurred due mainly to application of traditional poultice to subside sores or edema

Table 5. Number of patients and lesions of visceral sparganosis reported in Korea

Localities	No. of cases (%)	Male	Female	Sex, not-available
Urogenital system	10 (29.4)	9	1	0
Lung	10 (29.4)	7	2	1
Intestine	8 (23.5)	5	1	2
Omentum	2 (5.9)	2	0	0
Liver	1 (2.9)	1	0	0
Heart	1 (2.9)	0	1	0
Peritoneal cavity	1 (2.9)	1	0	0
Retropharynx	1 (2.9)	0	0	1
Total	34 (100)	25	5	4

Table 6. Number of patients and localities of ocular sparganosis

Locations	No. of cases (%)	Male	Female	Sex, not-available
Subconjunctiva	11 (68.8)	7	2	2
Eyelid	4 (25.0)	2	1	1
Intraorbit	1 (6.3)	0	1	0
Total	16 (100)	9	4	3

of inflamed eyes and/or skins.^{4,20} However, such types of traditional therapy have not been practiced in Korea,³ which might be responsible for the low incidence of ocular sparganosis in this country. A total of 16 ocular cases (3.6%; 16/438 cases) has been reported (**Table 6**). Patients' age ranged from 11 to 67 years (man:woman = 3:1). Subconjunctival area was the most predilection site (68.8%), followed by eyelid (25%). Their main clinical symptoms were painless mass with/without itching. One case of intraorbital sparganosis was described in an 11-year-old girl who complained of exophthalmos and itching sensation for a year. Other symptoms such as foreign body sensation, decreased visual acuity, or visual field defect were not observed. The patient was initially diagnosed as intraocular malignancy. During operation, a hard mass tightly adhered to the upper posterior intraorbital wall was resected. A live sparganum was extracted from the lesion. Her mother admitted that she had eaten cooked frog for 2–3 times.³⁷ The worm might have directly invaded into the orbit from the periorbital soft tissue. However, how the sparganum penetrated through the orbital wall surrounded by bony structure remains unknown.

Muscular sparganosis

Skeletal muscular tissues are relatively reluctant to allow penetration and migration of the sparganum due to their compact architectural structure. Sparganum was often found between muscles and fascial layers surrounded by fibrous capsule. Sparganosis of the muscular system was barely reported in Korea. A total of 12 cases were recorded, including seven men and three women (mean age, 61 years). Personal information for the remaining two patients was unavailable. Four cases had multiple infections in both subcutaneous tissues and muscles. Those muscular sparganosis cases revealed US findings of poorly defined intramuscular mass with heterogeneous echotextures in affected sites,²⁷ resembling those seen in subcutaneous sparganosis.²⁶ Most patients had a painless lump on the affected site (8 cases). The worm was discovered in the chest wall muscles in two cases and in the neck and trunk muscle in one case each.

Systemic sparganosis

An extremely uncommon case of systemic infections with multiple worms was described in Korea. A woman who complained of palpable mass on the breast visited a hospital. During evaluation of the breast mass, subcutaneous masses on the elbow and thigh were also noticed. Whole body MRI revealed multiple nodules on the subcutaneous fat layer of several organs, including the breast, elbow, thighs, calf, chest walls, abdominal wall, inguinal area, and suprapubic area. Masses in the psoas and gluteus muscles were additionally detected. A total of 16 worms were removed from respective tissues and muscles. She had a history of eating snakes to relieve leg pain 40 years ago.³⁸

Sparganosis of immunocompromised patients

Sparganosis or proliferative sparganosis associated with immunocompromised patients, such as those with acquired immune deficiency syndrome (AIDS), cancer, or allograft recipients have been sporadically detected worldwide. Proliferative sparganosis in immunocompromised patients often result in serious outcomes.³⁹⁻⁴¹ We found that at least

five sparganosis cases in Korea were associated with immunosuppressed conditions. All these cases were reported in recent 10 years.

The first case was identified in a woman patient. The patient who suffered from invasive ductal carcinoma of the right breast suddenly developed a mass on the ipsilateral breast. US findings compatible to sparganosis were observed. A live sparganum was removed via excisional biopsy.⁴² The next case was noticed in a man who underwent allogeneic hematopoietic stem cell transplantation for treatment of myelodysplastic syndrome. The patient was treated with a nucleic acid synthase inhibitor (decitabine), after which a hard and movable mass was developed on the left scrotum. Multiple enlargements of regional lymph nodes were also observed. Pelvic MRI suggested a myeloid sarcoma in the subcutaneous fat layer. However, histopathological specimen obtained from biopsy revealed a characteristic feature of sparganosis.⁴³ Two patients who received chemotherapy for treatment of metastatic rectal cancer or B cell lymphoma abruptly developed hemorrhagic plaques on abdomen or growing subcutaneous masses of the chest and abdomen. Biopsied specimen exhibited histological features of sparganosis. Both patients agreed that they ingested cooked snakes several times.^{44,45}

Two sparganosis cases were misdiagnosed as tumor metastasis. A patient was treated for metastatic gastric cancer. After third rounds of anticancer medication, a painless mass was detected on the left lower extremity which was suspected to be a skin metastasis. Tissue biopsy demonstrated a sparganum.⁴⁶ Another case was seen in a breast cancer patient. She received neoadjuvant treatment, after which an axillary nodule was additionally recognized. During curative surgery for breast cancer, axillary lesion was also resected and a viable sparganum was recovered.⁴⁷

DISCUSSION

Sparganosis has been continuously detected in Korea during the past 90 years, although annual incidence seemed to be decreased in the last 20 years. However, whether the prevalence of the sparganosis has actually decreased remains unclear because most clinicians in Korea now regard sparganosis as no longer reportable disease unless unusual complications/sequelae have been combined. In this respect, the authors identified more than 15 sparganosis cases affecting various organs/tissues, including thyroid gland from samples referred from several hospitals during recent 10 years in Korea (Kong Y., unpublished observation). Some minor fractions of the elderly people still believe that snakes/frogs have special benefits for muscular tonicity and treatment of arthralgia, tuberculosis, and other chronic wasting diseases. They continue to consume snakes/frogs, although they are aware that these types of convention are illegal with a risk of parasitic infections including sparganosis. Many people who like hiking, trekking and climbing sometimes drink unfiltered water. Those cultural habits and social behaviors might be the major limiting factors for terminating sparganosis transmission in this country.

In this study, we analyzed sparganosis cases reported in Korea by mining publicly available databases. During the period between 1924 and 2015, at least 438 cases were described in the literature (**Fig. 1**). We surmise that many more neglected cases are not reported in the literature. Most patients (80.3%) have a history of ingesting frogs/snakes and/or unfiltered water. Patients were largely detected in their middle ages between the fifth and sixth decades.

The disease was more common in men than in women (man:woman = 2.5:1). Subcutaneous tissues of the lower extremities were the most frequently affected sites (Fig. 3). These epidemiological situations were similar to those observed in other countries.^{4,19-21} However, Korean sparganosis shows some differences in terms of clinical and epidemiological aspects.

Since the 1980s, most patients were preoperatively diagnosed by imaging modalities combined with serological tests. Many cases of cerebral sparganosis have been detected in a relatively young age group (Fig. 4). Detection of a large number of cerebral sparganosis patients in relatively young age groups between third and fourth decades (43.1%) suggested that they might have severe diseases that led to early visit to clinics. Histological characteristics of the brain parenchyma might be related to early and deleterious symptoms/signs of cerebral sparganosis. Sparganum might migrate more vigorously within the brain parenchyma compared to other body compartments because brain parenchyma is mainly composed of soft tissue that is vulnerable to mechanical damage triggered by the invasive wandering worm. Bioactive molecules secreted by the sparganum including tissue hydrolyzing enzymes might also contribute to further damage to friable brain parenchyma.⁴⁸ A previous study has indicated that the frontoparietal lobes are frequently affected sites.³⁰ Infection of the occipital lobe alone was indeed rarely observed in this retrospective survey. However, involvement of parietal/parietooccipital/parietotemporal lobes was noticed to some extent.^{12,30,31} The sparganum might randomly invade the whole hemisphere. It might not have a specifically favored site, but it depends on the size of the lobe.

Ocular sparganosis is relatively infrequent in Korea. Large proportions of woman patients are infected with the sparganum on the breast. Interestingly, we recognized one extremely rare case of systemic sparganosis who had index lesion on the breast. Most cases of sparganosis were caused by a single worm. Sometimes two or more worms were found simultaneously in different localities of the body. However, systemic infections with multiple worms are very rare. Whether multiple worms might have infected the patient at once or accumulation of worms by repeated infection with a single worm during long periods could not be properly evaluated in this patient.³⁸

Sparganosis associated with immunocompromised patients has recently been reported in Korea. It is not certain whether immune status of patients truly affects exacerbation of sparganosis lesions and symptoms/signs. However, under immunocompromised conditions, mechanical activity of the sparganum and bioactive molecules secreted by the worm might accelerate and aggravate local damages. Several species of proteolytic enzymes might actively operate in the course of infection. These molecules might additionally contribute to the deterioration of lesions.^{48,49} Although authentic case of fatal sparganosis related to immune suppression has not been reported in this country, those unfavorable conditions should be kept in mind.

We could not identify genuine proliferative sparganosis cases in Korea, although one case of multiple subcutaneous sparganosis was highly suspected to be infected with proliferative sparganum.⁵⁰ However, proliferative sparganosis has been described in several other countries.⁵¹⁻⁵⁴ Proliferative sparganum (*Sparganum proliferum*) is a peculiar type of budding sparganum. It is genetically distinct from *Spirometra* species.⁵⁵ The parasite may proliferate asexually, branching, and breaking down into numerous segments, each of which has capacity to further develop. Some cases of proliferative sparganosis are associated with immunosuppressed conditions.³⁹⁻⁴¹ Occurrence of proliferative sparganosis should be carefully monitored in Korea.

Recent molecular phylogenetic analysis employing mitochondrial cytochrome c1 (*cox1*) gene has demonstrated that plerocercoid of *S. decipiens* can trigger human infections in Korea, in addition to plerocercoid of *S. erinacei*.⁶ The plerocercoid of *S. decipiens* has also been recovered from Korean terrestrial snakes. Interestingly, all sparganum (n = 904) recovered from snakes were identified as plerocercoid of *S. decipiens*, but not that of *S. erinacei*.⁵⁶ When we consider the fact that *S. erinacei* has not been discovered in naturally infected carnivorous hosts,⁵⁷ *S. decipiens* might be the responsible species found in the natural sylvatic cycle. These results suggest strongly that sparganum found in human cases should be carefully revisited for their species identification in the near future.

Currently, drugs effective for treating sparganosis are unavailable.⁵⁸ In this series, we observed that some patients were treated with praziquantel. A few patients seemed to respond to the drug because their symptoms subsided after medication. However, follow-up monitoring of anti-sparganum specific antibody levels demonstrated strong positive reactions,³⁶ suggesting that the sparganum might become dormant in the body, but not eradicated. This situation should be carefully considered when managing patients. Sparganosis of vital organs and/or related to immune suppressions may result in serious consequences. Public health education with regular interview by local health authorities, periodic check-up of suspected cases, continuous monitoring of the prevalence and medical surveillance system through patient-doctor rapport network might be needed in Korea.

ACKNOWLEDGMENTS

The authors are grateful to Ms. Jung-A Kim (Department of Parasitology and Tropical Medicine, Gyeongsang National University College of Medicine) for her excellent assistance during collection of sparganum from snakes.

REFERENCES

1. Lee SH, Chai JY, Seo BS, Cho SY. Two cases of human infection by adult of *Spirometra erinacei*. *Korean J Parasitol* 1984;22(1):66-71.
[PUBMED](#) | [CROSSREF](#)
2. Weinstein PP, Krawczyk HJ, Peers JH. Sparganosis in Korea. *Am J Trop Med Hyg* 1954;3(1):112-29.
[PUBMED](#) | [CROSSREF](#)
3. Cho SY, Bae JH, Seo BS. Some aspects of human sparganosis in Korea. *Korean J Parasitol* 1975;13(1):60-77.
[PUBMED](#) | [CROSSREF](#)
4. Liu Q, Li MW, Wang ZD, Zhao GH, Zhu XQ. Human sparganosis, a neglected food borne zoonosis. *Lancet Infect Dis* 2015;15(10):1226-35.
[PUBMED](#) | [CROSSREF](#)
5. Bowman DD, Hendrix CM, Lindsay DS, Barr SC. *Feline Clinical Parasitology*. 1st ed. Ames, IA: Iowa State University Press; 2002.
6. Jeon HK, Park H, Lee D, Choe S, Kim KH, Huh S, et al. Human infections with *Spirometra decipiens* plerocercoids identified by morphologic and genetic analyses in Korea. *Korean J Parasitol* 2015;53(3):299-305.
[PUBMED](#) | [CROSSREF](#)
7. Kong Y, Cho SY, Kang WS. Sparganum infections in normal adult population and epileptic patients in Korea: a seroepidemiologic observation. *Korean J Parasitol* 1994;32(2):85-92.
[PUBMED](#) | [CROSSREF](#)
8. Lee KJ, Bae YT, Kim DH, Deung YK, Ryang YS. A seroepidemiologic survey for human sparganosis in Gangweon-do. *Korean J Parasitol* 2002;40(4):177-80.
[PUBMED](#) | [CROSSREF](#)

9. Kim H, Kim SI, Cho SY. Serological diagnosis of human sparganosis by means of micro-ELISA. *Korean J Parasitol* 1984;22(2):222-8.
[PUBMED](#) | [CROSSREF](#)
10. Doi T, Boku S. The first case of *Sparganum mansoni* from a Korean and three cases from Japanese. *J Chosen Med Ass* 1924;50:47-51.
11. Min DY. Cestode infections in Korea. *Korean J Parasitol* 1990;28 Suppl:123-44.
[PUBMED](#) | [CROSSREF](#)
12. Chang KH, Cho SY, Chi JG, Kim WS, Han MC, Kim CW, et al. Cerebral sparganosis: CT characteristics. *Radiology* 1987;165(2):505-10.
[PUBMED](#) | [CROSSREF](#)
13. Chung SY, Park KS, Lee Y, Park CK. Breast sparganosis: mammographic and ultrasound features. *J Clin Ultrasound* 1995;23(7):447-51.
[PUBMED](#) | [CROSSREF](#)
14. Cho SY, Kang SY, Kong Y. Purification of antigenic protein of sparganum by immunoaffinity chromatography using a monoclonal antibody. *Korean J Parasitol* 1990;28(3):135-42.
[PUBMED](#) | [CROSSREF](#)
15. Morakote N, Kong Y. Antigen specificity of 36 and 31 kDa proteins of *Spirometra erinacei* plerocercoid in tissue invading nematodiasis. *Korean J Parasitol* 1993;31(2):169-71.
[PUBMED](#) | [CROSSREF](#)
16. Kobayashi H. On the animal parasites in Korea. *Jpn Med World* 1925;5(1):9-16.
17. Cho SY, Hwang KI, Seo BS. On the *Sparganum mansoni* infection in some Korean terrestrial snakes. *Korean J Parasitol* 1973;11(2):87-94.
[PUBMED](#) | [CROSSREF](#)
18. Kim CH. The infection status of *sparganum* and *Gnathostoma* in frogs of southern part of Korea. *Korean J Parasitol* 1983;21(1):83-6.
[PUBMED](#) | [CROSSREF](#)
19. Mitchell A, Scheithauer BW, Kelly PJ, Forbes GS, Rosenblatt JE. Cerebral sparganosis. Case report. *J Neurosurg* 1990;73(1):147-50.
[PUBMED](#) | [CROSSREF](#)
20. Anantaphruti MT, Nawa Y, Vanvanitchai Y. Human sparganosis in Thailand: an overview. *Acta Trop* 2011;118(3):171-6.
[PUBMED](#) | [CROSSREF](#)
21. Lo Presti A, Aguirre DT, De Andrés P, Daoud L, Fortes J, Muñiz J. Cerebral sparganosis: case report and review of the European cases. *Acta Neurochir (Wien)* 2015;157(8):1339-43.
[PUBMED](#) | [CROSSREF](#)
22. Koo M, Kim JH, Kim JS, Lee JE, Nam SJ, Yang JH. Cases and literature review of breast sparganosis. *World J Surg* 2011;35(3):573-9.
[PUBMED](#) | [CROSSREF](#)
23. Lee EG, Kim WJ, Lee HJ, Lee SE, Yoon MS. Sparganosis in a child. *Korean J Dermatol* 2012;50(12):1087-8.
24. Lim D, Kim CS, Kim SI. Sparganosis presenting as spermatic cord hydrocele in six-year-old boy. *Urology* 2007;70(6):1223.e1-2.
[PUBMED](#) | [CROSSREF](#)
25. Kim HY, Kang CH, Kim JH, Lee SH, Park SY, Cho SW. Intramuscular and subcutaneous sparganosis: sonographic findings. *J Clin Ultrasound* 2008;36(9):570-2.
[PUBMED](#) | [CROSSREF](#)
26. Choi SJ, Park SH, Kim MJ, Jung M, Ko BH. Sparganosis of the breast and lower extremities: sonographic appearance. *J Clin Ultrasound* 2014;42(7):436-8.
[PUBMED](#) | [CROSSREF](#)
27. Cho JH, Lee KB, Yong TS, Kim BS, Park HB, Ryu KN, et al. Subcutaneous and musculoskeletal sparganosis: imaging characteristics and pathologic correlation. *Skeletal Radiol* 2000;29(7):402-8.
[PUBMED](#) | [CROSSREF](#)
28. Ha S, Oh SW, Kim YK, Yi A, Ahn YJ. Breast sparganosis incidentally detected by FDG PET/CT. *Nucl Med Mol Imaging* 2013;47(2):130-3.
[PUBMED](#) | [CROSSREF](#)
29. Yoo H, Kim DG. Sparganosis of brain and lumbar spinal canal. *J Korean Neurosurg Soc* 1999;28(7):1027-31.
30. Chang KH, Chi JG, Cho SY, Han MH, Han DH, Han MC. Cerebral sparganosis: analysis of 34 cases with emphasis on CT features. *Neuroradiology* 1992;34(1):1-8.
[PUBMED](#) | [CROSSREF](#)

31. Moon WK, Chang KH, Cho SY, Han MH, Cha SH, Chi JG, et al. Cerebral sparganosis: MR imaging versus CT features. *Radiology* 1993;188(3):751-7.
[PUBMED](#) | [CROSSREF](#)
32. Kim HW, Kim JH. A case of sparganosis infesting with stone in human ureter. *Korean J Urol* 1970;11(1):23-6.
33. Kim DH, Yi IH, Youn HC, Kim SC, Kim BS, Cho KS, et al. Pleural sparganosis: a case report. *Korean J Thorac Cardiovasc Surg* 2006;39(6):502-3.
34. Lee JH, Yu JS, Park MS, Lee SI, Yang SW. Abdominal sparganosis presenting as an abscess with fistulous communication to the bowel. *AJR Am J Roentgenol* 2005;185(4):1084-5.
[PUBMED](#) | [CROSSREF](#)
35. Park WH, Shin TY, Yoon SM, Park SH, Kang YJ, Kim DK, et al. A case report of testicular sparganosis misdiagnosed as testicular tumor. *J Korean Med Sci* 2014;29(7):1018-20.
[PUBMED](#) | [CROSSREF](#)
36. Lee JH, Kim GH, Kim SM, Lee SY, Lee WY, Bae JW, et al. A case of sparganosis that presented as a recurrent pericardial effusion. *Korean Circ J* 2011;41(1):38-42.
[PUBMED](#) | [CROSSREF](#)
37. Shin JH, Chung JK, Kim WB, Kim DJ, Ok YC, Lee KW. A case report of sparganosis of the orbit. *J Korean Neurosurg Soc* 1975;4(2):409-12.
38. Song EJ, Sohn YM, Ryu KN, Min SY, Shin SH, Park YK. Breast sparganosis and incidentally detected subcutaneous and intramuscular sparganosis at several sites: case report and literature review. *Jpn J Radiol* 2015;33(4):225-8.
[PUBMED](#) | [CROSSREF](#)
39. Connor DH, Sparks AK, Strano AJ, Neafie RC, Juvelier B. Disseminated parasitosis in an immunosuppressed patient. Possibly a mutated sparganum. *Arch Pathol Lab Med* 1976;100(2):65-8.
[PUBMED](#)
40. Olson PD, Yoder K, Fajardo L-G LF, Marty AM, van de Pas S, Olivier C, et al. Lethal invasive cestodiasis in immunosuppressed patients. *J Infect Dis* 2003;187(12):1962-6.
[PUBMED](#) | [CROSSREF](#)
41. Meric R, Ilie MI, Hofman V, Rioux-Leclercq N, Michot L, Haffaf Y, et al. Disseminated infection caused by *Sparganum proliferum* in an AIDS patient. *Histopathology* 2010;56(6):824-8.
[PUBMED](#) | [CROSSREF](#)
42. Lee YJ, Choo KS, Bae YT, Kim JY. A case report of breast sparganosis in a patient with ipsilateral breast cancer: MRI and ultrasonographic findings. *J Korean Soc Radiol* 2010;63(6):569-75.
[CROSSREF](#)
43. Yeo JY, Han JY, Lee JH, Park YH, Lim JH, Lee MH, et al. A case of inguinal sparganosis mimicking myeloid sarcoma. *Korean J Parasitol* 2012;50(4):353-5.
[PUBMED](#) | [CROSSREF](#)
44. Chun SM, Yun SJ, Lee JB, Lee SC, Won YH, Kim SJ. A case of sparganosis in a patient with rectal cancer. *Korean J Dermatol* 2012;50(4):332-6.
45. Roh SY, Lee JY, Park KW, Jung SN. Sparganosis in a patient with diffuse large B cell lymphoma. *J Cancer Res Ther* 2013;9(4):712-4.
[PUBMED](#) | [CROSSREF](#)
46. Lee JS, Park SJ, Park MI, Kim KJ, Moon W, Shin EK, et al. A case of sparganosis mimicking a skin metastasis in a patient with stomach cancer. *Korean J Med* 2009;77(6):755-8.
47. Lee EK, Yoo YB. Axillary sparganosis which was misunderstood lymph node metastasis during neoadjuvant chemotherapy in a breast cancer patient. *Ann Surg Treat Res* 2014;87(6):336-9.
[PUBMED](#) | [CROSSREF](#)
48. Kong Y, Chung YB, Cho SY, Choi SH, Kang SY. Characterization of three neutral proteases of *Spirometra mansoni* plerocercoid. *Parasitology* 1994;108(Pt 3):359-68.
[PUBMED](#) | [CROSSREF](#)
49. Kong Y, Chung YB, Cho SY, Kang SY. Cleavage of immunoglobulin G by excretory-secretory cathepsin S-like protease of *Spirometra mansoni* plerocercoid. *Parasitology* 1994;109(Pt 5):611-21.
[PUBMED](#) | [CROSSREF](#)
50. Cho BK, Chun CS, Choi WY, Cho SY. A case of unusual sparganosis. *Korean J Dermatol* 1985;23(5):672-7.
[PUBMED](#) | [CROSSREF](#)
51. Torres JR, Noya OO, Noya BA, Mouliniere R, Martinez E. Treatment of proliferative sparganosis with mebendazole and praziquantel. *Trans R Soc Trop Med Hyg* 1981;75(6):846-7.
[PUBMED](#) | [CROSSREF](#)

52. Moulinier R, Martinez E, Torres J, Noya O, de NOya BA, Reyes O. Human proliferative sparganosis in Venezuela: report of a case. *Am J Trop Med Hyg* 1982;31(2):358-63.
[PUBMED](#) | [CROSSREF](#)
53. Lo YK, Chao D, Yan SH, Liu HC, Chu FL, Huang CI, et al. Spinal cord proliferative sparganosis in Taiwan: a case report. *Neurosurgery* 1987;21(2):235-8.
[PUBMED](#) | [CROSSREF](#)
54. Nakamura T, Hara M, Matsuoka M, Kawabata M, Tsuji M. Human proliferative sparganosis. A new Japanese case. *Am J Clin Pathol* 1990;94(2):224-8.
[PUBMED](#) | [CROSSREF](#)
55. Jeon HK, Park H, Lee D, Choe S, Sohn WM, Eom KS. Molecular detection of *Spirometra decipiens* in the United States. *Korean J Parasitol* 2016;54(4):503-7.
[PUBMED](#) | [CROSSREF](#)
56. Jeon HK, Park H, Lee D, Choe S, Kim KH, Sohn WM, et al. Genetic identification of *Spirometra decipiens* plerocercoids in terrestrial snakes from Korea and China. *Korean J Parasitol* 2016;54(2):181-5.
[PUBMED](#) | [CROSSREF](#)
57. Faust EC, Campbell HE, Kellogg CR. Morphological and biological studies on the species of *Diphyllobothrium* in China. *Am J Hyg* 1929;9(3):560-83.
58. Wittner M, Tanowitz HB. Other cestode infection. In: Guerrant RL, Walker DH, Weller PF, editors. *Essentials of Tropical Infectious Disease*. New York, NY: Churchill Livingstone; 2001, 490-1.