

Hydatid cysts in muscles: clinical manifestations, diagnosis, and management of this atypical presentation

Recep Tekin^[1], Alper Avci^[2], Rojbin Ceylan Tekin^[3], Mehmet Gem^[4] and Remzi Cevik^[5]

[1] Department of Clinical Microbiology and Infectious Diseases, Faculty of Medicine, Dicle University, Diyarbakir, Turkey. [2]. Department of Thoracic Surgery, Faculty of Medicine, Cukurova University, Adana, Turkey. [3]. Department of Radiology, Diyarbakir Genesis Hospital, Diyarbakir, Turkey. [4]. Department of Orthopaedic Surgery, Faculty of Medicine, Dicle University, Diyarbakir, Turkey. [5]. Department of Physical Medicine and Rehabilitation, Faculty of Medicine, Dicle University, Diyarbakir, Turkey.

ABSTRACT

Introduction: Hydatid cysts are rarely detected in muscle tissue (0.7-0.9%), even in endemic countries. The aim of this study was to present information regarding the clinical manifestations, diagnosis, and management of muscle echinococcosis. **Methods:** Twenty-two patients with hydatid cysts in the muscle were followed from January 2006 through December 2014. **Results:** Twenty-four sites of muscle involvement were observed in the 22 patients. Fifteen (68%) of our patients were women, while seven (32%) were men. The mean age was 28.1 ± 15.4 (6-61) years. The most frequent locations were the thigh (27.2%) and the paravertebral region (13.6%). Most patients reported a painless slow-growing mass with normal overlying skin. Most (90.2%) cases were treated by surgical excision and fine-needle aspiration. **Conclusions:** Primary muscle hydatid cyst should be considered in the differential diagnosis in cystic masses of the muscular system without pain and localized enlargement of soft tissue, especially in endemic areas. Hydatid cyst should be investigated using serological tests and imaging modalities. If possible, total surgical excision of hydatid cyst in the muscle should be performed.

Keywords: Echinococcosis. Hydatid cyst. Muscle.

INTRODUCTION

Hydatid cyst disease is an endemic parasitic infection caused by *Echinococcus granulosus*, and is an important public health issue in Mediterranean countries, the Middle East, Africa, Asia, South America, and Australia⁽¹⁾. The liver and lungs are the two most frequently affected organs in humans, because the swallowed eggs hatch in the intestines and are transported by the portal system to the liver⁽²⁾. The localization of hydatid cyst in muscle is rare (0.7-0.9%), even in endemic countries. This primitive and isolated form of echinococcosis can present difficulties in diagnosis and management, particularly for inexperienced clinicians, and it must be correctly differentiated from soft-tissue tumors⁽³⁾. The aim of this study was to present information regarding the clinical manifestations, diagnosis, and management of atypical muscle echinococcosis. To the best of our knowledge, this study is the most comprehensive case series published in the literature.

METHODS

Twenty-two patients who were monitored by different clinics for soft-tissue cystic echinococcosis from January 2006 through December 2014 were included in the study. All patients lived in Turkey, which is an endemic area for hydatid disease. The following medical information was retrospectively collected from patient medical records: epidemiological data, gender, age, occupation, cyst location, clinical examination, clinical presentation, history and physical elements associated with the enlarging mass, laboratory findings, imaging techniques, fine-needle aspiration (FNA), neoadjuvant chemotherapy, therapeutic options with surgery, postoperative adjuvant medical therapy, follow-up period, and recurrences. Results of an immunofluorescence assay (IFA) test to detect echinococcosis antibodies were recorded. For follow-up care, ultrasonography (US) or magnetic resonance imaging (MRI) examination was performed and compared with previous studies to detect new onset or recurrence of hydatid cyst^{(1) (2)}. In patients diagnosed with more than one hydatid cyst, only one lesion underwent histopathological examination, and remaining lesions with similar or characteristic radiological features were accepted as hydatid cysts.

Corresponding author: Dr. Recep Tekin. Department of Infections Disease, Faculty of Medicine of Dicle University, Yenişehir 21280 Diyarbakir, Turkey.

Phone: +90 412 248 80 01- 4858

e-mail: receptekin@yahoo.com

Received 17 June 2015

Accepted 18 August 2015

RESULTS

Twenty-two patients were included in the study. Fifteen (68%) of the patients were women, while seven (32%) were men, with a mean age of 28.1 ± 15.4 (6-61) years. The lower extremities were involved in eight (36.3%) patients, with the thigh muscle being the most common location [six (27.2%) patients], followed by a paravertebral site [three (13.6%) patients]. The upper extremities were the rarest location, being involved in only one (4.5%) patient. An overview of socio-demographic data, symptoms, clinical signs, and treatment in the 22 patients is given in **Table 1**. The main symptom was a painless slow-growing mass with normal overlying skin. Clinically, the gradual emergence of a soft-tissue swelling, lasting for a year on average, was the main reason for consultation. MRI was the most common imaging modality used in the patients in our study (**Figure 1**). In all patients, the cysts were confined to the muscle and did not affect neurovascular structures or bones, and the diagnosis of muscle echinococcosis was confirmed by histopathological examination. We were able to obtain only seven IFA tests in our patients, and all IFA test results exceeded the 1/160 value. Most of the patients [18 (81.8%) patients] underwent complete surgical resection (**Figure 2**).

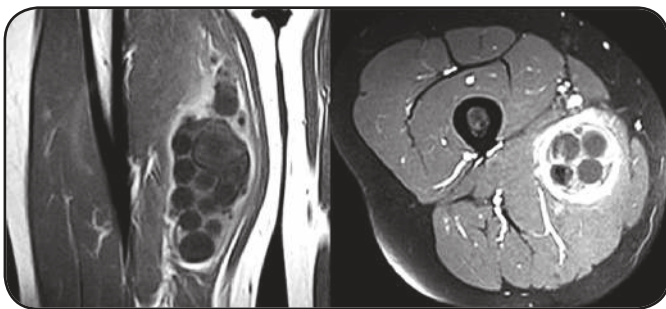


FIGURE 1 - Contrast-enhanced magnetic resonance images of a cystic mass arising from the origin of the right adductor muscle. A hyperintense multicystic lesion with multiple daughter cysts is seen.

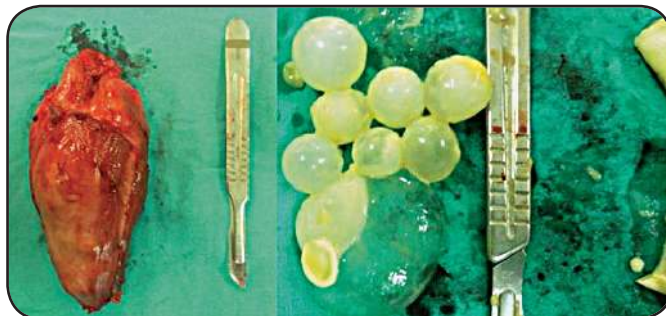


FIGURE 2 - Postoperative view of the mass and macroscopic aspect. The surgical specimen contained multiple small daughter cysts.

DISCUSSION

Cystic echinococcosis remains a health issue in developing countries because of the lack of strict control programs to prevent the transmission of this infection and problems such as high populations of stray dogs, illegal butchering of animals, and poor public education about disease⁽⁴⁾. The liver (50-70%) and lungs (20-30%) are the most frequent organs affected by hydatid cysts. Muscle hydatidosis is rare, possibly because of muscle lactic acid content and muscle contraction, two factors that likely prevent cyst growth in striated muscle. However, parasitic cysts are inclined to grow in the trunk, neck, and legs because of relatively less muscle contraction and more vascularization of these areas. Intramuscular hydatid cysts have been reported in the muscles of the chest wall and in the pectoralis major, sartorius, quadriceps, and gluteus muscles^{(5) (6)}. Primary hydatid cyst in muscular tissue has a very low incidence, with only select reports in the literature. Khanna et al.⁽⁷⁾ reported 24 unusual hydatid cyst locations among 110 patients with cystic echinococcosis in a period of 23 years. These locations included the spleen, skin, and soft tissue in decreasing order of frequency. Mseddi et al.⁽⁸⁾ reported 11 intramuscular hydatid cysts in a period of 17 years.

Clinically, the early stage of muscular hydatid disease is asymptomatic. The symptoms and signs of hydatid cyst disease depend on the involved organ, site of localization, effect on the adjacent tissue, complications after rupture, immunological reactions, and secondary infection. A palpable mass is the most constant clinical finding of hydatid disease affecting soft tissues, and the clinical manifestations are caused by compression of the organ involved^{(9) (10) (11)}. Muscle hydatid disease most often manifests as a slow-growing soft-tissue tumor, and can imitate myositis or a calcified hematoma. However, some cysts are revealed by complications such as nerve compression or infection, thereby simulating an acute abscess or a malignant tumor⁽³⁾. Our patients mostly presented with a painless growing mass in an affected part of the body. However, cysts are sometimes clinically asymptomatic and diagnosed incidentally.

If there is accompanying organ involvement and hydatid serologic testing is positive, local muscle involvement may be diagnosed easily. Otherwise, diagnosis of a primary skeletal muscle hydatid cyst is challenging⁽¹²⁾. Eosinophilia is usually not detected in healthy cystic echinococcosis. In our patients, only a single (4.7%) patient showed a positive finding of eosinophilia with 10% eosinophils. Although imaging methods have a primary role in diagnosis, there is need for serological verification in complicated cases and postoperative evaluation of the patient and in monitoring for recurrence. There are several serologic methods used in serologic diagnosis of cystic echinococcosis⁽¹³⁾, including enzyme-linked immunosorbent assay, western blot testing, and indirect hemagglutination antibody testing; however, these tests remain supportive and inadequate alone for the diagnosis of hydatid cyst⁽¹⁴⁾. Nevertheless, serologic tests can be useful for the differential diagnosis of cystic echinococcosis from neoplasm, abscess, simple cyst, or other masses, and for revealing asymptomatic hydatid cyst carriers and the efficacy of public control programs⁽¹⁵⁾.

TABLE 1 - Epidemiologic data of patients with muscle hydatid cysts.

Case	Sex	Age	Job	Location	IFAT	Imaging	Neoadjuvant therapy	Treatment	Adjuvant therapy	Other organ involvement	Follow-up	Recurrence
1	M	25	Farmer	Psoas + lumbar	NA	MRI	Albendazole	CSR	Albendazole	None	1 y	NA
2	M	9	Student	Intradiaphragmatic	NA	CT	None	CSR	Albendazole	Liver	NA	NA
3	F	37	Housewife	Para-umbilical	NA	US, MRI	NA	CSR	NA	None	NA	NA
4	F	23	Housewife	Thigh	NA	US, MRI	None	CSR	Albendazole	None	6 m	None
5	F	10	Student	Thigh	NA	US, MRI	NA	CSR	NA	None	NA	None
6	F	41	Housewife	Paravertebral	1/640	MRI	Albendazole	CSR	Albendazole	Lungs	1 y	NA
7	M	23	Employee	Parailiac	NA	CT	NA	CSR	NA	Liver	NA	NA
8	M	48	Farmer	Pelvic	NA	CT	None	Follow-up	Albendazole	Liver	NA	NA
9	F	15	Farmer	Gluteal + iliac	1/1280	US, MRI	Albendazole	CSR	Albendazole	Multiorgan	2 y	Yes
10	M	15	Student	Abdominal wall	NA	US, CT	None	PAIR	Albendazole	Liver, pancreas	NA	NA
11	F	21	NA	Intercostal	1/320	CT	Albendazole	CSR	Albendazole	Plueta	5 y	None
12	F	18	Farmer	Gluteal	1/640	US, MRI	Albendazole	CSR	Albendazole	None	6 m	None
13	F	38	Housewife	Intercostal	NA	CT	NA	CSR	Albendazole	None	2 m	None
14	F	24	Farmer	Thigh	1/320	US, MRI	NA	CSR	Albendazole	None	2 y	None
15	M	27	Employee	Psoas	1/320	CT	None	PAIR	Albendazole	None	1 y	None
16	F	21	Student	Intradiaphragmatic	1/640	CT	None	CSR	Albendazole	Lungs	1 y	None
17	F	28	Housewife	Throic	NA	MRI	NA	CSR	Albendazole	None	NA	NA
18	M	59	Farmer	Forearms	NA	US, MRI	None	CSR	Albendazole	None	1 y	None
19	F	6	Farmer	Thigh	NA	US, MRI	None	CSR	Albendazole	None	1 y	None
20	F	61	Farmer	Intradiaphragmatic	NA	CT	NA	CSR	NA	Lungs	1 y	Yes
21	F	42	Farmer	Thigh	NA	US, CT, MRI	None	Follow-up	Mebendazole	Liver	1 y	None
22	F	46	Housewife	Gastrocnemius	1/640	US, MRI	None	CSR	Albendazole	Liver	3 m	None

IFAT: indirect immunofluorescence antibody test; **M:** male; **F:** female; **NA:** not available; **MRI:** magnetic resonance imaging; **CSR:** complete surgical resection; **CT:** computed tomography; **US:** ultrasonography; **PAIR:** percutaneous aspiration-injection-reaspiration; **y:** years; **m:** months.

The use of imaging modalities such as US, computed tomography (CT), and MRI in the diagnosis of slow-growing cystic masses in the musculoskeletal system enables accurate visualization of structures and their relation to adjacent tissues. In addition, confirmation of diagnosis of hydatid cyst with these imaging modalities helps to prevent unnecessary cystic puncture and its complications such as local dissemination and anaphylactic shock⁽⁹⁾⁽¹⁶⁾. Danice et al.⁽¹⁷⁾ and Maurmen et al.⁽¹⁸⁾ reported US and CT to be the best methods for diagnosis.

Ultrasonography is a noninvasive, inexpensive, and repeatable imaging modality, which is widely used and accepted in the diagnosis of this disease, and cysts can be classified according to the US criteria of Gharbi⁽¹⁹⁾. In addition, US can be used as a practical guide during interventional procedures. Daughter cysts, detached membranes, and double-line sign are the most characteristic features of hydatid cyst on US⁽¹⁶⁾. Although CT is superior in detecting wall calcifications and bony associations, the appearance of the cyst is rarely typical. The CT findings are variable, and hydatid cyst can appear as a unilocular cyst, a multivesicular lesion, an atypical complex, or a solid lesion. The multivesicular lesion is characteristic of hydatid cyst and reflects multiple daughter cysts within the parent cyst, whereas a solid or complex lesion is the result of inflammatory changes and may mimic a tumor. As it is with the appearance of hydatid cyst on US, the presence of daughter cysts and detached membranes on CT may aid in the diagnosis⁽⁹⁾⁽²⁰⁾. In addition, bony invasion is critical in soft tissue cysts, and the use of CT is advised as a part of screening and treatment protocols. In the present cases, MRI and US might not have been useful in the diagnosis. MRI findings of hydatid cysts in the liver are well described, but the diagnosis is more difficult to make in the soft tissue of the musculoskeletal system because the MRI findings are not well described⁽⁹⁾. However, MRI is an important imaging modality in the detection and characterization of soft-tissue masses; therefore, further clarification of characteristic findings with hydatid cyst is needed.

For simple cases of muscle hydatid cyst, the most common form of treatment is surgical removal of the cyst combined with chemotherapy before and after surgery. For inoperable cases, medical treatment and/or percutaneous aspiration-injection-reaspiration (PAIR) are alternative treatment options⁽²¹⁾⁽²²⁾. In our series, 18 patients underwent surgical treatment, two patients underwent PAIR, and two patients received medical treatment only.

Anthelmintic therapy with albendazole or mebendazole is effective against tapeworm disease, and medical treatment alone may be effective in 30-40% of cases of hydatid disease and may be used for the treatment of patients with inoperable disease⁽²³⁾. Many authors recommend preoperative use of anthelmintics to sterilize the cyst, and reduce the consequences of spillage, and the chances of anaphylaxis and dissemination, at surgery. In addition, postoperative medical treatment reduces the chances of recurrence⁽²³⁾⁽²⁴⁾⁽²⁵⁾. However, if preoperative prediction of complete removal of an unruptured cyst is not possible, albendazole therapy can be initiated prior to surgery, and postoperative drug therapy is administered in most cases at various dosage regimens⁽¹¹⁾.

In conclusion, a primary muscle hydatid cyst should be considered in the differential diagnosis in cystic masses of the muscular system without pain and localized enlargement of soft tissue, especially in endemic regions such as our country. Hydatid cysts should be investigated using blood tests and imaging modalities; confirmed cases should be treated with total surgical excision if possible.

CONFLICT OF INTEREST

The authors declare that there is no conflict of interest.

REFERENCES

1. Kayaalp C, Dirican A, Aydin C. Primary subcutaneous hydatid cysts: a review of 22 cases. *Int J Surg* 2011; 9:117-121.
2. Alimehmeti R, Seferi A, Rroji A, Alimehmeti M. Saphenous neuropathy due to large hydatid cyst within long adductor muscle: case report and literature review. *J Infect Dev Ctries* 2012; 6:531-535.
3. Madhar M, Aitsoultana A, Chafik R, Elhaouy H, Saidi H, Fikry T. Primary hydatid cyst of the thigh: on seven cases. *Musculoskelet Surg* 2013; 97:77-79.
4. Nath K, Prabhakar G, Nagar RC. Primary hydatid cyst of neck muscles. *Indian J Pediatr* 2002; 69:997-998.
5. Kocakusak A, Koyuncu A, Arikan S, Senturk O. Primary hydatid cyst of vastus lateralis muscle. *Acta Chir Belg* 2004; 104:471-472.
6. Versaci A, Scuderi G, Rosato A, Angiò LG, Oliva G, Sfuncia G, et al. Rare localizations of echinococcosis: Personal experience. *ANZ J Surg* 2005; 75:986-991.
7. Khanna AK, Prasanna GV, Khanna R, Khanna A. Unusual sites of hydatid cysts in India. *Trop Doct* 2005; 5:233-235.
8. Mseddi M, Mtaoumi M, Dahmene J, Ben Hamida R, Siala A, Moulda T, et al. Hydatid cysts in muscles: eleven cases. *Rev Chir Orthop Reparatrice Appar Mot* 2005; 91:267-271.
9. Vasilevska V, Zafirovski G, Kirjas N, Janevska V, Samardziski M, Kostadinova-Kunovska S, et al. Imaging diagnosis of musculoskeletal hydatid disease. *Prilozi* 2007; 28:199-209.
10. Ozgonul A, Sogut O, Cece H, Aydın S, Kürkcüoğlu IC. Co-occurrence of diaphragmatic and serratus anterior muscle hydatidosis: an unusual localization. *J Emerg Med* 2012; 43:219-22.
11. Karimi A, Asadi K, Mohseni F, Hosseini Akbar M. Hydatid Cyst of the Biceps Femoris Muscle (a Rare Case in Orthopedic Surgery). *Shiraz E Medical J* 2011; 12:150-154.
12. Dudkiewicz I, Salai M, Apter S. Hydatid cyst presenting as a soft-tissue thigh mass in a child. *Arch Orthop Trauma Surg* 1999; 119:474-475.
13. Biava MF, Dao A, Fortier B. Laboratory diagnosis of cystic hydatid disease. *World J Surg* 2001; 25:10-14.
14. Yazar S, Altıntaş N. Serodiagnosis of cystic echinococcosis in Turkey. *Helminthol* 2003; 40:9-13.
15. Aydın M, Adiyaman G, Doğruman-Al F, Kuştimur S, Ozkan S. Determination of anti-echinococcus IgG antibodies by ELISA in patients with suspected hydatid cyst. *Türkiye Parazitoloj Derg* 2012; 36:61-64.
16. Yucesoy C, Ozturk E, Hekimoglu B. Radiologic findings and percutaneous treatment of a rare giant soft tissue hydatid cyst. *JBR-BTR* 2013; 96:286-289.
17. Danice B, Mirkovic M, Ilie M. 20 years experience in the treatment of abdominal echinococcosis (1966-1987). *Acta Chir Jugosl* 1989; 36:579-582.
18. Maurmen EI, Ala Qou ME, Mansouri A, Mokhtari M. Peritoneal echinococcosis, Diagnostic and therapeutic problems apropos 34 cases. *Chirurgie* 1991; 117:854-859.

19. Gharbi HA, Hassine W, Brauner MW, Dupuch K. Ultrasound examination of hydatid liver. *Radiology* 1981; 139:459-463.
20. Merkle EM, Schulte M, Vogel J, Tomczak R, Rieber A, Kern P, et al. Musculoskeletal involvement in cystic echinococcosis: Report of eight cases and review of the literature. *Am J Roentgenol* 1997; 168:1531-1534.
21. Hui M, Tandon A, Prayaga AK, Patnaik S. Isolated musculoskeletal hydatid disease: diagnosis on fine needle aspiration and cell block. *J Parasit Dis* 2015; 39:332-335.
22. Pathak TK, Roy S, Das S, Achar A, Biswas AK. Solitary hydatid cyst in thigh without any detectable primary site. *J Pak Med Assoc* 2011; 61:1244-1245.
23. Andalib Aliabady Z, Berenji F, Jamshidi MR. A case report of muscle hydatidosis from iran. *Iran J Parasitol* 2015; 10:132-135.
24. Tekin R, Kara AF, Tekin RC, Cimen D. Cardiac hydatid cyst case recovered with medical treatment. *Anadolu Kardiyol Derg* 2011; 11:650-651.
25. Mushtaque M, Mir MF, Malik AA, Arif SH, Khanday SA, Dar RA. Atypical localizations of hydatid disease: experience from a single institute. *Niger J Surg* 2012; 18:2-7.