

# Hydronephrosis in the course of ureteropelvic junction obstruction: An underestimated problem? Current opinions on the pathogenesis, diagnosis and treatment

Wojciech Krajewski<sup>1, B, D</sup>, Joanna Wojciechowska<sup>2, B, D</sup>, Janusz Dembowski<sup>1, E</sup>, Romuald Zdrojowy<sup>1, E</sup>, Tomasz Szydełko<sup>3, 4, A, E, F</sup>

<sup>1</sup> Department of Urology and Oncologic Urology, Wrocław Medical University, Poland

<sup>2</sup> Department of Otolaryngology and Surgery of the Head and Neck, Wrocław Medical University, Poland

<sup>3</sup> Clinical Department of Urology, 4<sup>th</sup> Clinical Military Hospital, Wrocław, Poland

<sup>4</sup> Department of Palliative Care Nursing, Wrocław Medical University, Poland

A – research concept and design; B – collection and/or assembly of data; C – data analysis and interpretation;

D – writing the article; E – critical revision of the article; F – final approval of article

Advances in Clinical and Experimental Medicine, ISSN 1899-5276 (print), ISSN 2451-2680 (online)

*Adv Clin Exp Med.* 2017;26(5):857–864

## Address for correspondence

Wojciech Krajewski  
E-mail: wk@softstar.pl

## Funding sources

None declared

## Conflict of interest

None declared

Received on May 26, 2015

Revised on August 24, 2015

Accepted on September 23, 2015

## Abstract

Ureteropelvic junction obstruction (UPJO) causes a reduction in the urine flow from the renal pelvis into the ureter. Untreated UPJO may cause hydronephrosis, chronic infection or urolithiasis and will often result in progressive deterioration of renal function. Most cases of UPJO are congenital; however, the disease can be clinically silent until adulthood. Other causes, both intrinsic and extrinsic, are acquired and include urolithiasis, post-operative/inflammatory/ischemic stricture, fibroepithelial polyps, adhesions and malignancy. In the past, the most frequent symptom of UPJO in neonates and infants was a palpable flank mass. Nowadays, thanks to the widespread use of maternal and prenatal ultrasound examinations, asymptomatic hydronephrosis is diagnosed very early. In adults and older children symptoms may include intermittent abdominal or flank pain, nausea, vomiting and hematuria. In addition to high specificity and sensitivity in detecting UPJO, modern technologically advanced equipment such as ultrasound, magnetic resonance imaging and computed tomography provides a lot of information about the function of the affected kidney and the anatomy of the surrounding tissues. Treatment options for UPJO include a wide spectrum of approaches, from active surveillance or minimally invasive endourologic techniques to open, laparoscopic or robotic pyeloplasty. The main goal of therapy is to relieve symptoms and maintain or improve renal function, but it is difficult to define treatment success after UPJO therapy.

**Key words:** hydronephrosis, ureteropelvic junction obstruction, pyeloplasty

## DOI

10.17219/acem/59509

## Copyright

Copyright by Author(s)

This is an article distributed under the terms of the  
Creative Commons Attribution Non-Commercial License  
(<http://creativecommons.org/licenses/by-nc-nd/4.0/>)

Ureteropelvic junction obstruction (UPJO) causes a reduction in the urine flow from the renal pelvis into the ureter. The narrowing of the ureter can be partial or complete. Untreated UPJO may cause hydronephrosis, chronic infection or urolithiasis and will often result in progressive deterioration of renal function. The main mechanism triggering renal parenchymal damage is increased pressure in the pelvicalyceal system. Most cases of UPJO are congenital, but the disease can remain clinically silent until adulthood. Other causes, both intrinsic and extrinsic, are acquired, and include urolithiasis, post-operative/inflammatory/ischemic stricture, fibroepithelial polyps, adhesions and malignancy.<sup>1</sup> Congenital UPJO is typically caused by the presence of an aperistaltic segment of the ureter, which does not allow the development of an effective peristaltic wave. In this pathological section, spiral musculature is replaced by longitudinal muscle and/or fibrous tissue. Other pathologies, such as abnormal secretion of compounds like transforming growth factor- $\beta$ , epidermal growth factor and other cytokines, nitric oxide and neuropeptide Y have a proven role in the pathogenesis of UPJO.<sup>2</sup>

The importance of interstitial Cajal cells in UPJO is controversial. The results of trials investigating distributional difference in Cajal cells in obstructed and unobstructed UPJ are contradictory in different publications.<sup>3</sup> A case of UPJO caused by Kawasaki disease and vasculitis of the ureter vessels has been reported.<sup>4</sup>

The role of crossing vessels in the pathogenesis of UPJO is also controversial. They have been observed in 30% of the general population and in up to 63% of UPJO cases; however, despite this association, the relationship between crossing vessels and UPJO is unclear. In some cases, because of a lack of demonstrable histopathological changes, it appears that crossing vessels cause only a mechanical obstacle. In other patients, crossing vessels lead to UPJ inflammation, fibrosis and smooth muscle hypertrophy, which subsequently result in obstruction. Finally, UPJO occurs due to other tissue pathologies, and is not associated with coexisting, clinically silent crossing vessels. To demonstrate the presence of crossing vessels, Doppler ultrasound (USG) scanning, endoluminal sonography, magnetic resonance imaging (MRI), and computed tomography (CT) can be used with nearly 100% accuracy.<sup>5</sup>

## Symptoms

In the past, the most frequent symptom of UPJO in neonates and infants was a palpable flank mass. Nowadays, thanks to the widespread use of maternal and prenatal ultrasound examinations, asymptomatic hydronephrosis is diagnosed very early. Occasionally, UPJO can be diagnosed during extended diagnostics of other congenital abnormalities.

In adults and older children, symptoms may include intermittent abdominal or flank pain, nausea, vomiting, hematuria or features of urinary tract infection. Laboratory findings can reveal microhematuria or pyuria. In some rare cases, hypertension is possible.

## Diagnosis

Classically, excretory urography was the most commonly used diagnostic option for UPJO. However, in addition to high specificity and sensitivity in detecting UPJO, modern technologically advanced equipment such as MRI, USG or CT provides a lot of information about the function of the affected kidney and the anatomy of the surrounding tissues. There are attempts to use CT imaging to estimate renal function based on renal parenchymal thickness. This non-invasive method does not require the injection of contrast, but further studies on larger groups of patients are needed to determine its role in UPJO diagnostics.<sup>6</sup> Another imaging method widely used in UPJO diagnosis and in estimating pre- and post-operative kidney function is nuclear renography (RN). RN involves intravenous administration of a radioisotope and observation by gamma camera as the radioisotope is excreted by the kidneys and passes through the urinary tract. Renal function is assessed between 1 and 2 min after the radioisotope injection and is expressed in terms of extraction value. A normal level of extraction is between 45 and 55%. Resistance to urine flow from the renal pelvis into the ureter is evaluated by T1/2 (the time taken for the renal unit to excrete half of the radioisotope). In cases of ureter obstruction the radioisotope will not pass beyond the level of the obstruction, or its transit time will be delayed. When T1/2 is shorter than 10–15 min, there is no obstruction; T1/2 longer than 20 min indicates significant obstruction; and when T1/2 is between 15 and 20 min, the result is equivocal.<sup>7</sup> RN can be also used to differentiate between UPJO and multicystic dysplastic kidneys. Multicystic dysplastic kidneys rarely reveal a concentration of isotope, while kidneys with UPJO usually demonstrate good concentrations of isotope. Despite the strong position of RN in UPJO diagnosis, there are publications indicating that it may not be necessary to perform routine RN to assess drainage and assess renal function in patients who become pain-free after UPJO operative treatment.<sup>8</sup>

Ultrasonography ranks first among the diagnostic procedures used to detect UPJO. However, ultrasonography does not provide information on the renal function of the hydronephrotic kidney. As dilatation of the pelvicalyceal system does not always result from UPJO, an ultrasound scan may turn out to be a false positive. Therefore, modifications of this imaging test have been introduced to improve the detection and diagnosis of UPJO. Diuretic ultrasonography comprises an ultrasound scan performed

before and after an injection of a diuretic. Duplex Doppler ultrasonography has been used for more than 20 years to evaluate UPJO. Renal obstruction causes a change in the Doppler waveform detected by means of the resistive index (RI). An RI value greater than 70 indicates obstruction. In adults, this diagnostic test is reported as showing a sensitivity of 92% and specificity of 88%.<sup>5</sup>

The multivariate scoring system introduced by Garcia-Pena et al. is yet another attempt to improve ultrasound sensitivity in diagnosing UPJO.<sup>9</sup> Those authors wrote: “The seven variables associated with a significantly higher risk of urinary tract obstruction were increased echogenicity, parenchymal rims 5 mm or less, contralateral hypertrophy, resistive index ratio 1.10 or greater, resistive index difference with diuresis of 70% or greater, ureter diameter 10 mm or greater and aperistaltic ureter”.<sup>9</sup> The sensitivity of the multivariate scoring system in high risk children was reported as 91%.

In some patients other diagnostic methods like retrograde pyelography are needed to confirm the diagnosis and to pinpoint the exact position of the obstruction. In cases with associated infection or reduced renal function, placement of a percutaneous nephrostomy tube is necessary to allow decompression of the collecting system and to allow antegrade pyelogram and dynamic pressure perfusion studies. The Whitaker test, an invasive diagnostic examination, is rarely recommended. It is indicated for patients with nephrostomy or when other diagnostic tests yield equivocal results. The test entails measuring renal pelvic pressure during an infusion of saline into the collecting system at a fixed rate of 10 mL/min. Intrapelvic pressure of less than 15 cm H<sub>2</sub>O is considered normal; greater than 22 cm H<sub>2</sub>O is indicative of obstruction; and between 15 and 22 cm H<sub>2</sub>O is indeterminate.<sup>10</sup>

It should be kept in mind that transitional cell carcinoma symptoms can sometimes mimic UPJO symptoms. Any case of UPJO, especially in an elderly patient and/or one with coexisting hematuria, warrants increased oncological vigilance.

To grade UPJO in both children and adults, the Society of Fetal Urology’s grading system based on ultrasound examination may be used. It has 5 stages: Grade 0: normal findings; Grade I: separation of the renal hilum; Grade II: Grade I + pelviectasis; Grade III: Grade II + caliectasis; Grade IV: Grade III + 50% or more thinning of the renal cortex relative to normal.<sup>11</sup> The degree of hydronephrosis can be also estimated on the basis of diuretic intravenous urography (IVU), and presented using a 4-grade scale; it has been shown that Grades I and II have no clinical significance in a large groups of patients.<sup>11</sup>

Infants with hydronephrosis on postnatal ultrasound with an anterior posterior diameter > 7 mm should undergo evaluation with a voiding cystourethrogram (VCUG). This fluoroscopic method provides a visualization of the anatomy of the bladder and urinary system,

allowing the diagnosis of vesicoureteral reflux, posterior urethral valves, ureteroceles and other anatomic abnormalities.<sup>12</sup>

Additionally, some findings in blood examinations can indicate UPJO. It has been shown that transforming growth factor-beta (TGFβ), epidermal growth factor (EGF), endothelin-1 (ET-1) and urinary tubular enzymes such as N-acetyl-beta-D-glucosaminidase (NAG), gamma-glutamyl transferase (GGT) and alkaline phosphatase (AKP) can be useful as non-invasive auxiliary examination tools in diagnosing UPJO in children. However, these biochemical markers are not yet used in routine clinical practice, but mainly in research settings.<sup>13</sup>

## Treatment

The first open pyeloplasty was reported by Trendelenburg in 1886, but the patient died during the procedure. The first successful open pyeloplasty was performed by Kuster in 1891. Nowadays treatment options for UPJO include a wide spectrum of approaches, from active surveillance or minimally invasive endourologic techniques to open, laparoscopic or robotic pyeloplasty. The main goal of therapy is to relieve symptoms and maintain or improve renal function; however, it is difficult to define treatment success after UPJO therapy. Various criteria such as relief of symptoms, stable or improved renal function or improvement in the RN/intravenous urogram are used either alone or (more often) in combination. Indications for UPJO treatment include cases in which extraction is reduced to less than 40% renal function in unilateral hydronephrosis with a normal other kidney, symptomatic patients with fast deterioration of renal function because of hydronephrosis, or Grade IV bilateral hydronephrosis. An extraction fraction of 10% or less usually indicates a non-salvageable hydronephrotic kidney.<sup>14</sup>

## Non-invasive approaches

In some children with congenital UPJO, the problem resolves spontaneously. Predicting which patients with UPJO will not require surgery is difficult. It has been shown that levels of urinary enzymes NAG, AKP and GGT were significantly higher in patients with hydronephrosis in whom operations were necessary when compared to those not requiring surgery. It has therefore been suggested that the levels of these enzymes can be used to identify patients requiring pyeloplasty. Additionally, it is known that the level of AKP falls significantly after UPJO treatment, so the concentration of this enzyme can be used as an adjunctive marker of improvement in drainage after pyeloplasty.<sup>15</sup>

In children, close follow-ups are required in the first 2 years of life to identify the subgroup of children with

obstruction that requires prompt surgery. That form of management appears to be a safe and recommended approach for neonates with primary bilateral ureteropelvic junction type hydronephrosis.<sup>16</sup> According to some authors each patient should be maintained on prophylactic antibiotics for the first year of life or until there was significant improvement in hydronephrosis.<sup>17</sup>

In adults with mild asymptomatic UPJO, careful observation with cyclic RN studies may be an appropriate approach. However, it is unclear how long the follow-up period should last. Only a few studies concerning this problem have been conducted and most of them were based on small group of patients. It seems reasonable to discharge patients with minimally symptomatic and/or asymptomatic UPJO from further evaluation 2 years after the diagnosis if they do not have symptomatic or renographic deterioration.

Patients with persistent pain secondary to UPJO can pose a management challenge. Analgesic drugs and physical interventions such as autonomic sympathetic blocks can be used to relieve the pain. There are reports of spinal cord stimulation as auxiliary treatment for chronic renal pain secondary to UPJO.<sup>18</sup>

## The endoscopic approach

Endoscopic endopyelotomy was firstly introduced by Ramsay et al. in 1984. The advantages of this procedure include shortened hospital stays and faster post-operative recovery. On the other hand, the success rates of endopyelotomy are worse than that of open, laparoscopic or robotic pyeloplasty. The available studies of antegrade endopyelotomy show success rates from 65 to 93%.<sup>19</sup> Outcomes could be improved with careful patient selection. It has been shown that patients with less advanced hydronephrosis (Grade II) have better antegrade endopyelotomy outcomes than more advanced cases do (Grade IV). Likewise, it has been shown that patients with better renal function have better outcomes than those with poor renal function. Stricture length is also an important factor. For strictures longer than 2 cm endopyelotomy results are unfavorable.<sup>20</sup>

Endopyelotomy is a lateral full-thickness incision made from the side of ureteral lumen. The incision is made laterally to avoid damage to possible crossing vessels. A double-J stent left after procedure to promote healing. The incision can be performed using a cold knife, a hot knife or a holmium laser in either antegrade and retrograde fashion, under vision or fluoroscopic control. Alternative endoscopic methods include balloon dilatation and Acucise endopyelotomy. This second procedure uses 2.8 cm long, 150 µm wide electrosurgical cutting wire mounted on an 8-mm inflatable balloon catheter to incise the pelviureteric junction under fluoroscopic control. There are several reports, mainly in animal models,

on Heineke-Mikulicz and Anderson-Hynes endopyeloplasties performed through percutaneous tracts.<sup>21</sup>

The most common complication after every type of endopyelotomy is hemorrhage, with an incidence of 2–4%. Other complications include ureteric injury, infection, ureteral spasms and scarring.<sup>22</sup>

## Open pyeloplasty

For years open pyeloplasty was considered the gold standard in UPJO treatment. Open pyeloplasty can be performed through an anterior extraperitoneal approach or posterior lumbotomy. The length of the incision and the morbidity associated with the procedure are the main disadvantages of open pyeloplasty.

## Laparoscopic pyeloplasty (LP)

Laparoscopic treatment of UPJO was first described in 1993, by Schuessler et al. as well as by Kavoussi and Peters. Because of the fact that laparoscopy entails less pain and blood loss, has comparable efficacy and better cosmetic results than open surgery and significantly better results than endourologic approaches, it became the new gold standard in UPJO treatment in both children and adults. It has been shown that LP is a good treatment option for both very young children (< 1 year) and for elderly people (70 years or older).<sup>23,24</sup> LP has also been shown to be adequate treatment for patients with UPJO in horseshoe kidneys.<sup>25</sup> In large studies the outcomes of LP are very good, ranging from 85 to 100%.<sup>26</sup> However, compared to open pyeloplasty or endopyelotomy, laparoscopic pyeloplasty requires advanced laparoscopic skills, mainly because of the complexity of the intracorporeal suturing. This means that LP is performed only at centers specialized in laparoscopy. LP is also a longer procedure than open pyeloplasty in the majority of published studies; however, some authors report that retroperitoneal LP can be shorter than an open operation.<sup>27</sup> Unfortunately, most of the available data comparing various methods come from non-randomized studies. Since the methods are significantly different in terms of invasiveness, it is difficult to persuade patients to accept a random procedure selection. In adult populations, only one randomized controlled trial has been conducted so far, including 62 patients, and the results were similar to those from retrospective studies.<sup>28</sup>

LP can be performed through a transperitoneal, anterior extraperitoneal or retroperitoneal approach. Because of the larger working space and more familiar anatomy, the retrocolic and transmesenteric transperitoneal routes are more frequently chosen. In a prospective randomized trial comparing trans- and retroperitoneal approaches, there was no difference in terms of functional outcomes,



but there was a longer operative time for the retroperitoneal approach.<sup>29</sup> Retrospective studies conducted on large cohorts confirm those results.<sup>30</sup> Comparing retrocolic and transmesenteric approaches, it seems that the latter should be considered whenever possible because it offers a significantly shorter operative time at no increased risk. The decision should be made during the operation, depending on intraoperative findings.

There is a controversy among surgeons what type of suture (running or interrupted) should be used while anastomosing the UPJ. Experimental studies performed on laboratory animals have shown that using running sutures could cause vascular compromise, deficiencies in collagen regeneration and more tissue ischemia and necrosis.<sup>26</sup> Additionally, continuous sutures in laparoscopy are associated with difficulty in maintaining appropriate tension during the procedure. However, in clinical studies, it has been shown that using the running suture method is associated with higher surgical efficiency and lower complication rates.<sup>31</sup> Based on the existing research, it can be concluded that continuous suturing reduces the overall cost of the procedure by shortening the time of procedure, the duration of drainage and thus the duration of hospitalization. Recently a novel mini-laparoscopic approach for management of UPJO in adults was reported, with good outcomes and better cosmetic results compared to classic LP.<sup>32</sup>

Alternative methods include one-trocar-assisted pyeloplasty (OTAP), first presented by Lima et al. in 2007. OTAP has been shown to be safe, feasible, and efficacious, with operative times similar to or even shorter than those of other minimally invasive techniques; the complication rates are similar to those of other laparoscopic UPJO treatments.<sup>33</sup>

Complication rates for LP range from 4 to 12.7%. One of the most common complications is anastomotic leakage, often related to double-J stent obstruction. It seems that most failures after LP occur in the first 2 years after the procedure; however, it is difficult to estimate the exact long-term results of LP because there are few reports with long-term follow-up of patients who have undergone pyeloplasty.<sup>34</sup>

## Robot-assisted pyeloplasty

Robotic systems reduce the limitations of laparoscopy through a 3-dimensional magnified view, full mobility of the instruments and the elimination of any tremor. However, there is no tactile feedback and total time of a robotic procedure and its total costs are higher. Additionally, in the hands of an experienced laparoscopic surgeon, a robot does not provide a significant clinical advantage compared with conventional laparoscopy. Nevertheless, it seems that whenever the technology is available, robotic pyeloplasty is likely to become the favored approach. Clinical

trials have shown that robotic pyeloplasty is a safe, feasible and effective procedure for treating UPJO.<sup>35</sup> A review and meta-analysis of the literature demonstrated that robotic pyeloplasty was associated with a 10-min reduction in operative time and significantly shorter hospital stays compared with the LP approach. However, there were no differences between the techniques concerning the rates of success and complications.<sup>36</sup> It has also been shown that the total cost was lower among patients undergoing open pyeloplasty as opposed to robotic pyeloplasty; however, the direct costs of robot-assisted surgery were lower than open surgery. This cost difference was largely attributable to the costs of robotic equipment.<sup>37</sup> Recent meta-analyses comparing robotic, laparoscopic and open pyeloplasty in children showed that robotic pyeloplasty might offer shorter hospital stays, lower analgesia requirements and lower estimated blood loss. The post-operative success rate was comparable in the 2 groups, but there was a significantly higher complication rate and higher costs in the robotic group.<sup>38</sup> Additionally, it has been shown that with 2 years of follow-up, only 5% of patients who underwent robotic pyeloplasty require a secondary procedure, compared with 13% of those who underwent a standard laparoscopic pyeloplasty.<sup>39</sup> Moreover, robot-assisted laparoscopic reoperative repair after failed primary treatment is safe and effective, and is less technically demanding than open repair for UPJO.<sup>40</sup> Robotic procedures are typically performed via a transperitoneal approach, although there are reports of a retroperitoneal approach being used in a small group of patients.<sup>41</sup>

## UPJ reconstruction techniques

### Dismembered pyeloplasty

Dismembered pyeloplasty is also called the Anderson-Hynes operation. Because dismembered pyeloplasty involves complete disconnection of the ureter and excision of the pathological segment, it is the most versatile form of operation. It allows reduction of a redundant pelvis and transposition of the UPJ when crossing vessels are the cause of obstruction. This method though, is not appropriate for long or multiple strictures, or for small intrarenal pelvis (Fig. 1–2).

### Flap procedures

Flap procedures include multiple techniques such as the Foley Y-V plasty, the Culp-DeWeerd spiral flap or the Scardino-Prince vertical flap. The most frequently used is the Foley Y-V plasty. The advantages of this procedure include significantly reduced operative time and decreased risk of devascularization of the UPJ. Flap procedures are suitable for long ureteral strictures with high insertion of the ureter into the renal pelvis. In cases with crossing

Fig. 1. Dismembered pyeloplasty

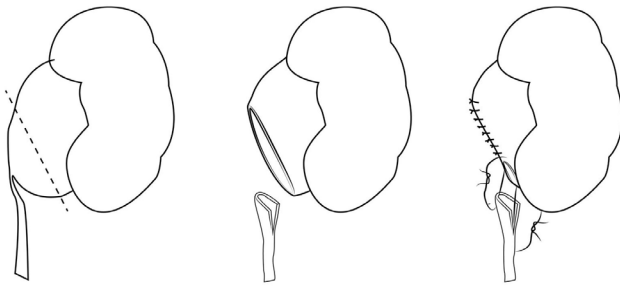


Fig. 2. Dismembered pyeloplasty when crossing vessels are present: dorsal transposition of the vessel

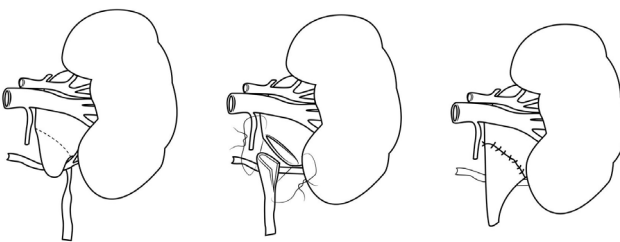


Fig. 3. Foley Y-V plasty

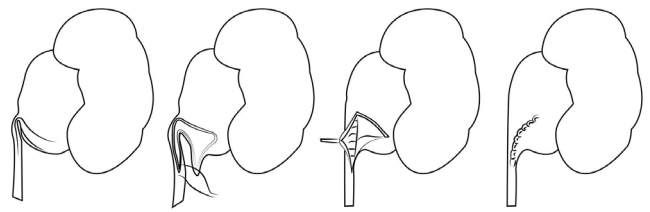
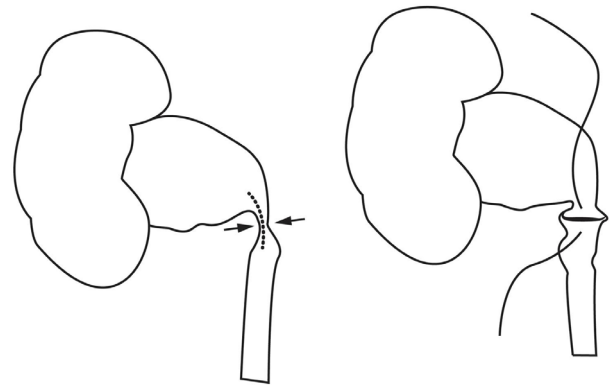


Fig. 4. Fenger plasty



vessels, cephalad translocation of the vessels should be performed instead of posterior transposition.<sup>42</sup> In a study comparing laparoscopic Anderson-Hynes pyeloplasty with laparoscopic Y-V pyeloplasty, it was shown that in the Y-V plasty group operative time was significantly shorter and intracorporeal suturing was easier with similar outcomes.<sup>43</sup> In another study that prospectively compared success rates in Anderson-Hynes and Y-V plasty, the former resulted in a higher success rate than Y-V pyeloplasty, but the difference was not statistically significant (Fig. 3).<sup>44</sup>

## Fenger plasty

Fenger plasty is the first nondismembered pyeloplasty introduced, and also the simplest approach that involves a Heineke-Mikulicz longitudinal incision through a narrowed segment and transverse closure. Laparoscopic suturing and knot tying are reduced to the placement of a few interrupted sutures. This procedure can be applied only to short strictures in the absence of high insertion of the ureter. This technique often causes shortening of the suture line on one side, resulting in buckling or kinking of the UPJ (Fig. 4).<sup>45</sup>

## Ureterocalicostomy

Ureterocalicostomy is a rarely used procedure for primary UPJO. Indications include proximal ureteral stricture associated with a small intrarenal pelvis. It is also used as a salvage technique for failed pyeloplasties.

## Nephrectomy

In some rare cases a nephrectomy can be performed. It may be indicated in symptomatic patients with diminished function or a non-functioning kidney, or after repeated repair failures. Nephrectomy should be considered only in cases with a normally functioning contralateral kidney.

## Crossing vessels

Cases with coexisting crossing vessels represent a therapeutic dilemma. There is no consensus on whether the transposition of the crossing vessels is necessary. The outcomes of operations with and without relocation seem not to differ. Therefore, transposition is indicated in cases with difficult anatomical relations. The decision should be made during surgery. The translocation technique, also called a vascular hitch, entails mobilizing, moving and fixing the vessel to a higher position on the renal pelvis. Laparoscopic pyelopyelostomy, another transpositioning option, has also been shown to be effective in a small cohort of patients.<sup>46</sup>

## The use of ureteral stents

Another dilemma concerns anastomosis stenting. There is no agreement on what type of stenting (retrograde or antegrade) should be used, and whether there is a need for stenting at all. Since the retrograde stenting procedure involves a number of technical inconveniences

(the need for patient repositioning, renal pelvis collapsing), attempts have been made to introduce stents in an antegrade fashion. Studies comparing the effectiveness of the 2 methods have reported conflicting results.<sup>47</sup>

Ureteral stenting, despite reducing the frequency of urinoma formation, can cause complications, especially in children. Trials comparing both stentless and stented techniques have shown that stentless pyeloplasty is a feasible and safe procedure. Still, some authors recommend stent use in patients with a solitary kidney, difficult anastomosis, significant bleeding during the procedure, and in patients with a thick noncompliant ureter due to chronic inflammation.<sup>48</sup>

## Conclusions

UPJO is a pathology of the upper urinary tract which may be diagnosed at any age. Untreated UPJO leads to deterioration and eventual loss of renal function. Current diagnostic methods make it possible to detect the disease early and to implement minimally invasive surgical procedures that are capable of enhancing renal function at best or, at least preventing its deterioration.

## References

- Szydelko T, Tuchendler T, Litarski A, Urbanczyk G, Apoznanski W, Janczak D. Laparoscopic Anderson-Hynes procedure as a treatment of ureteropelvic junction obstruction caused by fibroepithelial polyp. *Wideochir Inne Tech Malo Inwazyjne*. 2013;8:361–363.
- Knerr I, Dittrich K, Miller J, et al. Alteration of neuronal and endothelial nitric oxide synthase and neuropeptide Y in congenital ureteropelvic junction obstruction. *Urol Res*. 2001;29:134–140.
- Apoznanski W, Koleda P, Wozniak Z, et al. The distribution of interstitial cells of Cajal in congenital ureteropelvic junction obstruction. *Int Urol Nephrol*. 2013;45:607–612.
- Subramaniam R, Lama T, Chong CY. Pelviureteric junction obstruction as sequelae of Kawasaki disease. *Pediatr Surg Int*. 2004;20:553–555.
- Mitterberger M, Pinggera GM, Neururer R, et al. Comparison of contrast-enhanced color Doppler imaging (CDI), computed tomography (CT), and magnetic resonance imaging (MRI) for the detection of crossing vessels in patients with ureteropelvic junction obstruction (UPJO). *Eur Urol*. 2008;53:1254–1260.
- Ramaswamy K, Marien T, Mass A, Stifelman M, Shah O. Simplified approach to estimating renal function based on computerized tomography. *Can J Urol*. 2013;20:6833–6839.
- Roarke MC, Sandler CM. Provocative imaging. Diuretic renography. *Urol Clin North Am*. 1998;25:227–249.
- Lam W, Fernando A, Issa R, et al. Is routine postoperative diuresis renography indicated in all adult patients after pyeloplasty for ureteropelvic junction obstruction? *Urology*. 2015;85(1):246–251.
- Garcia-Pena BM, Keller MS, Schwartz DS, Korsvik HE, Weiss RM. The ultrasonographic differentiation of obstructive versus nonobstructive hydronephrosis in children: A multivariate scoring system. *J Urol*. 1997;158:560–565.
- Johnston RB, Porter C. The Whitaker test. *Urology journal*. 2014; 11(3):1727–1730.
- Fernbach SK, Maizels M, Conway JJ. Ultrasound grading of hydronephrosis: Introduction to the system used by the Society for Fetal Urology. *Pediatr Radiol*. 1993;23:478–480.
- Ek S, Lidfeldt KJ, Varricio L. Fetal hydronephrosis; prevalence, natural history and postnatal consequences in an unselected population. *Acta Obstet Gynecol Scand*. 2007;86:1463–1466.
- Shokeir AA. Role of urinary biomarkers in the diagnosis of congenital upper urinary tract obstruction. *Indian J Urol*. 2008;24:313–319.
- Bhat GS, Maregowda S, Jayaram S, Siddappa S. Is renal biopsy a better predictor of the outcome of pyeloplasty in adult ureteropelvic junction obstruction? *Urology*. 2012;79(2):321–325.
- Rathod KJ, Samujh R, Agarwal S, Kanojia RP, Sharma U, Prasad R. Hydronephrosis due to pelviureteric junction narrowing: Utility of urinary enzymes to predict the need for surgical management and follow-up. *J Indian Assoc Pediatr Surg*. 2012;17:1–5.
- Lam JS, Breda A, Schulam PG. Ureteropelvic junction obstruction. *J Urol*. 2007;177:1652–1658.
- Onen A, Jayanthi VR, Koff SA. Long-term followup of prenatally detected severe bilateral newborn hydronephrosis initially managed nonoperatively. *J Urol*. 2002;168(3):1118–1120.
- Kim CH, Issa M. Spinal cord stimulation for the treatment of chronic renal pain secondary to uretero-pelvic junction obstruction. *Pain Physician*. 2011;14:55–59.
- Manikandan R, Saad A, Bhatt RI, Neilson D. Minimally invasive surgery for pelviureteral junction obstruction in adults: A critical review of the options. *Urology*. 2005;65:422–432.
- Lam JS, Cooper KL, Greene TD, Gupta M. Impact of hydronephrosis and renal function on treatment outcome: Antegrade versus retrograde endopyelotomy. *Urology*. 2003;61:1107–1111.
- Sharp DS, Desai MM, Molina WR, et al. Dismembered percutaneous endopyeloplasty: A new procedure. *J Endourol*. 2005;19:210–217.
- Biyani CS, Minhas S, el Cast J, Almond DJ, Cooksey G, Hetherington JW. The role of Acucise endopyelotomy in the treatment of ureteropelvic junction obstruction. *Eur Urol*. 2002; 41:305–310; discussion 310–301.
- Giri SK, Murphy D, Costello AJ, Moon DA. Laparoscopic pyeloplasty outcomes of elderly patients. *J Endourol*. 2011;25:251–256.
- Metzelder ML, Schier F, Petersen C, Truss M, Ure BM. Laparoscopic transabdominal pyeloplasty in children is feasible irrespective of age. *J Urol*. 2006;175:688–691.
- Lallas CD, Pak RW, Pagnani C, et al. The minimally invasive management of ureteropelvic junction obstruction in horseshoe kidneys. *World J Urol*. 2011;29:91–95.
- Autorino R, Eden C, El-Ghoneimi A, et al. Robot-assisted and laparoscopic repair of ureteropelvic junction obstruction: A systematic review and meta-analysis. *Eur Urol*. 2014;65:430–452.
- Zhang X, Li HZ, Ma X, et al. Retrospective comparison of retroperitoneal laparoscopic versus open dismembered pyeloplasty for ureteropelvic junction obstruction. *J Urol*. 2006;176(3):1077–1080.
- Mei H, Pu J, Yang C, Zhang H, Zheng L, Tong Q. Laparoscopic versus open pyeloplasty for ureteropelvic junction obstruction in children: A systematic review and meta-analysis. *J Endourol*. 2011;25:727–736.
- Shoma AM, El Nahas AR, Bazeed MA. Laparoscopic pyeloplasty: A prospective randomized comparison between the transperitoneal approach and retroperitoneoscopy. *J Urol*. 2007;178:2020–2024; discussion 2024.
- Wu Y, Dong Q, Han P, Liu L, Wang L, Wei Q. Meta-analysis of transperitoneal versus retroperitoneal approaches of laparoscopic pyeloplasty for ureteropelvic junction obstruction. *J Laparoendosc Adv Surg Tech A*. 2012;22(7):658–662.
- Shao P, Qin C, Ju X, et al. Comparison of two different suture methods in laparoscopic dismembered pyeloplasty. *Urol Int*. 2011;87:304–308.
- Pini G, Goezen AS, Schulze M, Hruza M, Klein J, Rassweiler JJ. Small-incision access retroperitoneoscopic technique (SMART) pyeloplasty in adult patients: Comparison of cosmetic and post-operative pain outcomes in a matched-pair analysis with standard retroperitoneoscopy: Preliminary report. *World J Urol*. 2012;30:605–611.
- Mogiatti M, Destro F, Ruggeri G, Messina P, Tursini S, Lima M. One-trocar-assisted pyeloplasty in children: An 8-year single institution experience. *Eur J Pediatr Surg*. 2014. doi: 10.1055/S-0034-1372459.
- Seo IY, Oh TH, Lee JW. Long-term follow-up results of laparoscopic pyeloplasty. *Korean J Urol*. 2014;55:656–659.
- Uberoi J, Disick GI, Munver R. Minimally invasive surgical management of pelvic-ureteric junction obstruction: Update on the current status of robotic-assisted pyeloplasty. *BJU Int*. 2009;104: 1722–1729.

36. Braga LH, Pace K, DeMaria J, Lorenzo AJ. Systematic review and meta-analysis of robotic-assisted versus conventional laparoscopic pyeloplasty for patients with ureteropelvic junction obstruction: Effect on operative time, length of hospital stay, post-operative complications, and success rate. *Eur Urol.* 2009;56:848–857.
37. Varda BK, Johnson EK, Clark C, Chung BI, Nelson CP, Chang SL. National trends of perioperative outcomes and costs for open, laparoscopic and robotic pediatric pyeloplasty. *J Urol.* 2014;191:1090–1095.
38. Chang SJ, Hsu CK, Hsieh CH, Yang SS. Comparing the efficacy and safety between robotic-assisted versus open pyeloplasty in children: A systemic review and meta-analysis. *World J Urol.* 2015;33(11):1855–1865.
39. Lucas SM, Sundaram CP, Wolf JS, et al. Factors that impact the outcome of minimally invasive pyeloplasty: Results of the Multi-institutional Laparoscopic and Robotic Pyeloplasty Collaborative Group. *J Urol.* 2012;187:522–527.
40. Asensio M, Gander R, Royo GF, Lloret J. Failed pyeloplasty in children: Is robot-assisted laparoscopic reoperative repair feasible? *J Pediatr Urol.* 2015;11(2):69.e1–6.
41. Patel M, Porter J. Robotic retroperitoneal surgery: A contemporary review. *Current Opinion in Urology.* 2013;23(1):51–56.
42. Szydelko T, Apoznanski W, Koleda P, Rusiecki L, Janczak D. Laparoscopic pyeloplasty with cephalad translocation of the crossing vessel – A new approach to the Hellström technique. *Videosurgery Miniin.* 2015;e-pub, ahead of print.
43. Szydelko T, Kasprzak J, Apoznanski W, et al. Comparison of dismembered and nondismembered Y-V laparoscopic pyeloplasty in patients with primary hydronephrosis. *J Laparoendosc Adv Surg Tech A.* 2010;20(1):7–12.
44. Szydelko T, Kasprzak J, Lewandowski J, Apoznanski W, Dembowski J. Dismembered laparoscopic Anderson-Hynes pyeloplasty versus nondismembered laparoscopic Y-V pyeloplasty in the treatment of patients with primary ureteropelvic junction obstruction: A prospective study. *Journal of Endourology/Endourological Society.* 2012;26(9):1165–1170.
45. Polok M, Chrzan R, Veenboer P, et al. Nondismembered pyeloplasty in a pediatric population: Results of 34 open and laparoscopic procedures. *Urology.* 2011;78:891–894.
46. Sameh W, Elgebaly OF. Laparoscopic transposition pyelo-pyelostomy for repair of adult uretero-pelvic junction obstruction secondary to lower pole crossing vessels: A novel technique. *J Endourol.* 2012;26:377–380.
47. Arumainayagam N, Minervini A, Davenport K, et al. Antegrade versus retrograde stenting in laparoscopic pyeloplasty. *J Endourol.* 2008;22:671–674.
48. Shalhav AL, Mikhail AA, Orvieto MA, Gofrit ON, Gerber GS, Zorn KC. Adult stentless laparoscopic pyeloplasty. *JSLs.* 2007;11:8–13.