

Research article

Open Access

## Hyper-IgG4 disease: report and characterisation of a new disease

Guy H Neild\*<sup>1,2</sup>, Manuel Rodriguez-Justo<sup>3</sup>, Catherine Wall<sup>1</sup> and John O Connolly<sup>1,2</sup>

Address: <sup>1</sup>UCL Centre for Nephrology, Royal Free Hospital, London NW3 2QG, UK, <sup>2</sup>Institute of Urology and Nephrology, Middlesex Hospital, London W1T 3AA, UK and <sup>3</sup>Department of Histopathology, Royal Free and University College Medical School, University College Hospital, Rockefeller Building, London WC1E 6JJ, UK

Email: Guy H Neild\* - g.neild@ucl.ac.uk; Manuel Rodriguez-Justo - m.rodriguez-justo@ucl.ac.uk; Catherine Wall - Catherine.Wall@amch.ie; John O Connolly - j.connolly@ucl.ac.uk

\* Corresponding author

Published: 06 October 2006

Received: 17 May 2006

BMC Medicine 2006, 4:23 doi:10.1186/1741-7015-4-23

Accepted: 06 October 2006

This article is available from: <http://www.biomedcentral.com/1741-7015/4/23>

© 2006 Neild et al; licensee BioMed Central Ltd.

This is an Open Access article distributed under the terms of the Creative Commons Attribution License (<http://creativecommons.org/licenses/by/2.0>), which permits unrestricted use, distribution, and reproduction in any medium, provided the original work is properly cited.

### Abstract

**Background:** We highlight a chronic inflammatory disease we call 'hyper-IgG4 disease', which has many synonyms depending on the organ involved, the country of origin and the year of the report. It is characterized histologically by a lymphoplasmacytic inflammation with IgG4-positive cells and exuberant fibrosis, which leaves dense fibrosis on resolution. A typical example is idiopathic retroperitoneal fibrosis, but the initial report in 2001 was of sclerosing pancreatitis.

**Methods:** We report an index case with fever and severe systemic disease. We have also reviewed the histology of 11 further patients with idiopathic retroperitoneal fibrosis for evidence of IgG4-expressing plasma cells, and examined a wide range of other inflammatory conditions and fibrotic diseases as organ-specific controls. We have reviewed the published literature for disease associations with idiopathic, systemic fibrosing conditions and the synonyms: pseudotumour, myofibroblastic tumour, plasma cell granuloma, systemic fibrosis, xanthofibrogranulomatosis, and multifocal fibrosclerosis.

**Results:** Histology from all 12 patients showed, to varying degrees, fibrosis, intense inflammatory cell infiltration with lymphocytes, plasma cells, scattered neutrophils, and sometimes eosinophilic aggregates, with venulitis and obliterative arteritis. The majority of lymphocytes were T cells that expressed CD8 and CD4, with scattered B-cell-rich small lymphoid follicles. In all cases, there was a significant increase in IgG4-positive plasma cells compared with controls. In two cases, biopsies before and after steroid treatment were available, and only scattered plasma cells were seen after treatment, none of them expressing IgG4. Review of the literature shows that although pathology commonly appears confined to one organ, patients can have systemic symptoms and fever. In the active period, there is an acute phase response with a high serum concentration of IgG, and during this phase, there is a rapid clinical response to glucocorticoid steroid treatment.

**Conclusion:** We believe that hyper-IgG4 disease is an important condition to recognise, as the diagnosis can be readily verified and the outcome with treatment is very good.

**Background**

While investigating a patient who had an uncharacterised multisystem disease with evidence of a severe acute-phase response, we found that similar rare cases had been described, usually as single reports [1], under an alarming list of synonyms [2] (Table 1). These conditions are all characterised by chronic inflammation leading to dense fibrosis, and retroperitoneal fibrosis (RPF) is a typical example. The principal synonyms that we found for these fibrosing conditions are: pseudotumour, myofibroblastic tumour, plasma cell granuloma, systemic fibrosis, xanthofibrogranulomatosis, and multifocal fibrosclerosis (Table 1). As can be seen in Tables 1 and 2, these conditions, such as RPF, Reidel's thyroiditis and sclerosing pancreatitis, are usually localised to one or two organs but can present with systemic multisystem disease.

In another patient, we observed the rare behaviour of idiopathic RPF behaving like a tumour, in which the inflammatory mass was invading both the kidney and liver and presented as a progressive cholangitis. This case was one of a series of patients seen in our gastroenterological department, who had sclerosing pancreatitis and chronic inflammation associated with immunoglobulin (Ig)G4-expressing plasma cells [3,4]. In biopsies from both these cases, we found typical fibrosis with lymphoplasmacytic inflammation and IgG4-bearing plasma cells [5].

Sclerosing (autoimmune) pancreatitis is a unique form of pancreatitis, characterized by hypergammaglobulinaemia and a lymphoplasmacytic inflammation of the pancreas that responds to glucocorticoid treatment. It has several synonyms (Table 2). A Japanese group investigating this condition [6] found that the sera of their patients had a polyclonal band in the rapidly migrating fraction of gammaglobulins, which was caused by a high concentration

of the IgG4 gammaglobulin fraction. They also reported that serum concentrations of IgG4 were significantly and specifically raised in patients with sclerosing pancreatitis, and were closely associated with disease activity [6].

The same Japanese group found that of the 22 patients with sclerosing pancreatitis they studied, three also had concomitant hydronephrosis caused by a periureteric mass, diagnosed as RPF (Ormond's disease). Histological examination of the periureteric tissue showed abundant infiltration of IgG4-bearing plasma cells. Treatment with corticosteroids lowered serum concentrations of IgG4, and the authors proposed that IgG4 might have a pathological role in a systemic fibrosing process that includes pancreatic and retroperitoneal lesions [5].

Kamisawa et al have also published several reports emphasising the systemic nature of this process. Patients with autoimmune pancreatitis may also have involvement of lymph nodes and salivary glands as well as local tissues [7,8], in a pattern suggestive of multifocal fibrosclerosis [9,10].

We describe our index case, and report on the histological features of 11 other patients seen at our hospital with idiopathic RPF, for whom we have now been able to review the histology and examine sections for evidence of IgG4-expressing plasma cells. We also list the synonyms and disease associations that we believe are all part of the same disease process.

**Methods**

**Histological examination**

We report on the histological features of 16 biopsy specimens from 12 patients seen at the Middlesex hospital with a primary diagnosis of RPF, for whom we have now been

**Table 1: Systemic fibrosis synonyms**

Pseudotumour, inflammatory pseudotumour, fibrous pseudotumour	Systemic[83-85]	Lung[86-89], liver[87,90-93], breast[94], pancreas[83,95-99], orbit[100], RPF[98-101], mesentery[102]
Inflammatory myofibroblastic tumour, myofibroblastoma	Systemic	Pancreas[96], lung[46,103,104], brain[105], breast[106]
Plasma cell granuloma	Systemic	lung[107,108], brain[107]
Systemic fibrosis, generalized form of Ormond's disease, systemic idiopathic fibrosis, idiopathic systemic sclerosing disease	Systemic[1,109-111]	PRF[109,111-113], orbit[112], lung[114,115]
Xanthofibrogranulomatosis, xanthogranuloma	Systemic[1,2,116,117]	RPF[101,118-121], brain[118,122], orbit[123]
Multifocal fibrosclerosis, multifocal idiopathic fibrosclerosis	Systemic[84,85,124-128]	RPF[124,125,128-133], orbit[124,129-131,134] thyroid[127,128,132,133], pancreas[9]

RPF, retroperitoneal fibrosis.

**Table 2: Conditions associated with systemic fibrosis**

Name	Synonyms	
RPF	Ormond's disease	Systemic[109,111,113,135], lung[32,32,53,115,136,136,137], liver[138], breast, pancreas[5,139-141],
Retro-orbital tumour	Fibrous pseudotumour of the orbit, Graves' orbitopathy	RPF[124,129-131,142-145]
Riedel's thyroiditis		RPF[132,133,146-148] MFF[127,128,147,149,150]
Chronic sclerosing sialadenitis[151]	Kuttner's tumour	
Panniculitis	Weber-Christian syndrome steatonecrosis, necrosing panniculitis	Systemic[110], RPF[135,152-155] Biliary cirrhosis[156], pancreas[157]
Sclerosing pancreatitis[158]	Primary inflammatory pancreatitis (P)[159], lymphoplasmacytic sclerosing P[7,160,161], autoimmune P[162], sclerosing pancreaticocholangitis[163], pancreatic pseudo-tumour[95]	RPF[5,97,139,161,164,165], cholangitis[95,160,164,166,167], systemic[83,168-171] gastric ulcer[172], lung[173,174] panniculitis[157], mesentery[175]
Sclerosing cholangitis		MFF[128], pancreas[92,166]
Bronchiolitis obliterans with organizing pneumonia	Cryptogenic organizing pneumonia, pulmonary hyalinizing granuloma.	Systemic[50,176], pancreas[173,174], liver[177], RPF[115,136,137], renal[46,136], mediastinum[178,179]
Benign pleural mesothelioma[180,181], calcifying pseudotumour[182,183]	Asbestos-related?	RPF[11,26-28,32,32] peritoneum[56,184,185] pleura[54,55,186]

RPF, retroperitoneal fibrosis; MFF, multifocal fibrosclerosis

able to review the histology and examine sections for evidence of IgG4-expressing plasma cells. Only archival paraffin wax-embedded material was used for this study. All the biopsies were taken for diagnostic reasons with the informed consent of patients.

All the samples were routinely fixed in formalin and embedded in paraffin wax. Dewaxed sections (µm) were stained with haematoxylin and eosin. Immunohistochemical analysis was performed using antibodies (all Dako UK Ltd, Cambridgeshire, UK) against CD3, CD4, CD8, CD20, and CD138, and the kappa and lambda light chains of immunoglobulins, by the standard streptavidin-biotin-peroxidase method. For IgG4, a mouse human IgG4 monoclonal antibody was used (1:100 dilution, MC011; The Binding Site, Birmingham, UK). Negative controls were created by substituting the primary antibody with similarly diluted non-immunized mouse serum.

We examined a wide variety of other inflammatory conditions and fibrotic diseases as organ-specific controls, which included liver (autoimmune hepatitis, chronic hep-

atitis C), pancreas (chronic and alcoholic pancreatitis), salivary gland (chronic sialadenitis), gallbladder (chronic cholecystitis), kidney (tubulointerstitial nephritis), duodenum (chronic duodenitis), colon (non-specific colitis), and other fibrotic processes (Dupuytren's, keloid scars). Because an association between RPF and asbestos exposure has been reported [11], we also included cases of malignant mesotheliomas. In addition, specimens from cases of "benign pleural plaques" were stained as controls.

Positive controls comprised tissue obtained from pancreas, salivary gland and liver from patients seen in our gastroenterological department who had sclerosing pancreatitis and chronic inflammation associated with IgG4-expressing plasma cells, details of which have been reported previously [3,4].

The degree of inflammation was assessed as severe (>100 inflammatory cells per high power field ()), moderate (30–100 cells/HPF) and mild (30–10 cells/HPF). The presence of lymphoid-follicle formation, eosinophilic infiltration, venulitis and obliterative arteritis (on elastic van Gieson-stained sections) was also recorded. The number of IgG4-

positive cells was estimated by counting 10 HPF, and scoring as follows: 0 (no IgG4 plasma cells/HPF), 1 ( $\leq$  20 cells/HPF), 2 (20–50 cells/HPF) or 3 ( $\geq$  50 cells/HPF) [12]. Fibrosis was assessed as - (no fibrosis), + (mild), ++ (moderate) or +++ (severe).

#### Literature review

We reviewed the published literature for disease associations with idiopathic, systemic fibrosing conditions using the following synonyms: pseudotumour, myofibroblastic tumour, plasma cell granuloma, systemic fibrosis, xanthofibrogranulomatosis and multifocal fibrosclerosis. We also looked for reports associating these conditions with organ-specific conditions, particularly sclerosing pancreatitis (see Table 2 for other synonyms), RPF, Reidel's thyroiditis, panniculitis, Weber-Christian syndrome and retro-orbital tumour, and with a range of autoimmune diseases (Table 3).

Many of these reports are case reports. We have not attempted to list every report but rather to draw up a comprehensive list of all possible associations with at least one citation.

## Results

### Index case

A 39-year-old Moroccan steel fitter had lived in the UK for 31 years. He presented in May 2003 with abdominal pain, weight loss, sweating, generalized lymphadenopathy, and severe anaemia and thrombocytosis. Investigations showed haemoglobin of 6.7 g/dL (normal range 13.0–17.0 g/dL), platelets  $1031 \times 10^9/L$  ( $150\text{--}400 \times 10^9/L$ ), erythrocyte sedimentation rate (ESR) 120 mm/h (0–15 mm/h), IgG 21.4 g/L (8.0–18.0 g/L), IgA 2.9 g/L (0.9–4.5 g/L), IgM 0.6 g/L (0.6–2.8 g/L) and C-reactive protein (CRP) 289 mg/L (normal 0–5 mg/L). Biochemistry was normal. Chest X-ray showed apical pleural thickening. An intravenous urogram (IVU) showed left hydronephrosis; an ultrasound scan (USS) confirmed this, and showed dilatation of the bile and pancreatic ducts and the gallbladder. Computed tomography (CT) showed multifocal upper zone and patchy nodular airspace shadowing, with right posterior pleural thickening and subcarinal lymphadenopathy. Biopsies of pleural, ileal and colonic tissue, bone marrow, and left inguinal lymph node were all either normal or showed reactive change. Cultures of blood, urine and sputum were all negative. The patient was also negative for human immunodeficiency virus types 1 and 2, hepatitis B and C, human T-lymphotropic virus, toxoplasmosis and treponemal disease. Mantoux test was weakly positive, and although bronchoalveolar lavage was smear-negative, there was one positive culture for a mycobacterium after 3 weeks.

The patient was commenced on quadruple therapy for tuberculosis (TB) in July 2003, for an organism that was strongly isoniazid-resistant. The patient presented again in November with fatigue, weight loss and fever, which was thought to be medication-related. He was given prednisolone 20 mg for 6 weeks of, taken off all TB therapy, and after 2 months was feeling so well that he was told his TB had been cured.

He re-presented 3 months later (March 2004) with a 6-week history of night sweats, low-grade fever, lethargy, weight loss, left pleuritic chest pain and axillary lymphadenopathy. Blood tests again showed microcytic anaemia, and the same acute phase response. Antinuclear antibody (ANA), antineutrophil cytoplasmic antibodies, mitochondrial antibodies and smooth-muscle antibodies were all negative. CT showed many of the previous changes but with a right hydronephrosis that was confirmed on IVU (left hydronephrosis was no longer present). A repeat bone-marrow biopsy, inguinal lymph node and transjugular liver biopsies, endoscopy, colonoscopy, peritoneal fluid aspiration and bone scan were all either normal or non-specific. The patient was treated with quintuple anti-TB therapy in order to cover his original mycobacterium infection as well as an infection with *Mycobacterium fortuitum* that had been cultured from sputum on this occasion. He was also treated with steroids, initially 60 mg of prednisolone, tapered down to 20 mg over 3 months.

The patient was readmitted 6 months later with generalized abdominal pain and vomiting. He had stopped his steroids 11 days earlier because of side effects. Investigations showed only a marked inflammatory response. CT scan revealed no hydronephrosis, but now showed dilated, thick-walled small bowel in the left iliac fossa. During an exploratory laparotomy (October 2004), an inflamed omental mass adherent to the small-bowel mesentery was removed. Histology was reported as showing only some fibrosis with a mild chronic inflammatory cell infiltrate of lymphocytes and plasma cells. The patient was recommenced on steroids and quadruple anti-TB therapy.

He remained well for some months, but then presented (March 2005) with a 6-week history of pain in the right upper quadrant of the abdomen. His blood tests showed the same inflammatory response and a USS showed prominent intrahepatic ducts only. The histology of the omental mass was reviewed and showed a large number of IgG4-positive plasma cells throughout the fibroinflammatory reaction (Table 4). The patient's serum IgG concentration was 21.4 g/l and IgG4 2.4 (normal range 0–1.3 g/l). A diagnosis of hyper-IgG4 disease was made, all microbial therapy was stopped, and the patient was treated with prednisolone 20 mg/day with immediate

**Table 3: Rare associations with IgG4-related conditions (Case reports)**

<b>Head and neck</b>	
Submandibular gland fibrosis	Pancreas[95], cholangitis[187,188], pseudotumour[189]
Parotid involvement	pancreas[171]
Sjögren's syndrome	Pancreas[171,190], RPF[164], BOOP[191]
Maculopathy	MFF[126]
Uveitis	RPF[192]
Conjunctiva	Pseudotumour[86]
Hashimoto's disease, Graves' disease	RPF[193]
<b>Cardiovascular</b>	
Constrictive pericarditis	RPF[194]
Heart valves	RPF[20,22]
Mediastinal fibrosis	RPF[194-196]
Chronic periaortitis/aneurysm	RPF[197-205]
Vasculitis	RPF[125,206,207]
Occlusive phlebitis	MFF[149]
Intermittent claudication	RPF[208]
<b>Rheumatology</b>	
Rheumatoid arthritis	BOOP[176], RPF[209]
Polymyalgia rheumatica	BOOP[210]
Ankylosing spondylitis	RPF[211]
Periarticular fibrosis	RPF[212]
Skeletal hyperostosis	RPF[213]
Dermatomyositis	Pseudotumour[88], BOOP[214]
Polymyositis	BOOP[191,215]
Scleroderma	RPF[216]
<b>Other autoimmune conditions</b>	
Systemic lupus erythematosus	RPF[217]
Idiopathic thrombocytopenic purpura	RPF[218,219]
Haemolytic anaemia	Lung[220], cholangitis[221]
<b>Central nervous system</b>	
Brain	PCG[107], xanthogranuloma[118,222]
Sella	MFF[124,126]
Spinal cord compression	RPF[223]
<b>Gastrointestinal</b>	
Primary biliary cirrhosis	RPF[224], BOOP[176]
Mesentery	RPF[112,152,175,225], pseudotumour[102,153,155]
Bladder/pelvic mass	RPF[49,208,226,227]
Duodenal obstruction	RPF[228,229]
Portal hypertension	RPF[230]
<b>Others</b>	
Familial multifocal fibrosclerosis	Familial RPF
Proliferative crescentic glomerulonephritis, membranous glomerulonephritis	MFF[43] RPF[42] RPF[231] RPF[232]
Interstitial nephritis	Pancreas[233]
Testicular involvement	RPF[126,234]

MFF, multifocal fibrosclerosis; RPF, retroperitoneal fibrosis; BOOP, bronchiolitis obliterans with organizing pneumonia; PCG, plasma-cell granuloma.

**Table 4: Histopathology**

Patient no., sex, age	Organ	Fibrosis*	Lymphoplasmacytic infiltrate†	Lymphoid follicles	Venulitis	Eosinophilic component	IgG4-positive plasma cells‡
(1) Male, 52	Kidney	+++	+++	Yes	No	No	3
	Liver	++	+	No	No	Yes	0
(2) Male, 73	Retroperitoneum	+++	+++	Yes	Yes	Yes	3
(3) Male, 39	Omentum	+	++	Yes	No	No	3
(4) Male, 53	Retroperitoneum	+++	+++	Yes	Yes	Yes	3
(5) Male, 45	Periureter	+++	+++	Yes	Yes	No	2
(6) Female, 58	Retroperitoneum	+++	+++	No	Yes	No	3
(7) Female, 55	Para-aortic tissue	+++	+++	Yes	Yes	No	3
(8) Male, 47	Periureter tissue	+++	+	Yes	Yes	No	2
(9) Male, 48	Retroperitoneum	+++	++	No	No	No	2
(10) Male, 73	Retroperitoneum	+++	+++	Yes	Yes	Yes	1
(11) Female, 56	Retroperitoneum	+++	++	Yes	No	No	1
(12) Male, 53	Liver	++	+	No	No	No	1
	Colon	++	+	No	No	No	0

\*Degree of interstitial fibrosis: +, mild; ++, moderate; +++, severe fibrosis.

†Degree of inflammation: +++ (severe), >100 inflammatory cells/HPF; ++ (moderate), 30–100 cells/HPF; + (mild), 10–30 cells/HPF

‡IgG4-positive plasma cells: 0, no IgG4 plasma cells/high power field (HPF); 1, ≤ 20 cells/HPF; 2, 20–50 cells/HPF; 3, ≥ 50 cells/HPF (criteria of Aoki et al [12]).

improvement in his illness. He remains on azathioprine and 5 mg prednisolone.

#### Pathology of IgG4 disease

We reviewed the histology and examined sections for evidence of IgG4-expressing plasma cells of 16 biopsies from 12 patients with a clinical diagnosis of idiopathic RPF seen at our hospital in the past 10 years. Biopsies comprised nine samples of retroperitoneal tissue, two of liver, and one each from kidney, colon and omentum. In addition, there were two further samples of retroperitoneal tissue taken from two patients after steroid therapy.

The results are shown in Table 4. All patients showed, to varying degrees, fibrosis, intense inflammatory cell infiltration with lymphocytes, plasma cells, scattered neutrophils and in some cases eosinophilic aggregates. The majority of lymphocytes expressed CD8 and CD4 positivity (T-cell markers), with B cells present to a lesser degree and with scattered B-cell-rich small lymphoid follicles. In addition, we saw vasculitis affecting small veins, and evidence of obliterative arteritis (Figures 1, 2, 3). In all cases, there was a significant increase in IgG4-positive plasma cells compared with controls (Figure 4). Even when few plasma cells were seen (patients 10–12) the majority expressed IgG4 (Figure 5). In two cases, biopsies before and after steroid treatment were available; only scattered plasma cells were seen after treatment, none of which expressed IgG4 (Fig 3). In all of our patients, the kappa and lambda light chains showed a polytypic pattern. We used PCR to look for evidence of oligoclonal infiltrates for IgH in one case (patient 1), as has been reported from Japan [13], but found none. None of the wide range of

control sections showed significantly increased numbers of IgG4-positive cells.

We also examined biopsy specimens from liver (two patients), large bowel (one) and renal tissue (one). In all of them, we found mild fibrosis and a small increase in lymphoplasmacytic inflammatory cell infiltrate, although IgG4-positive plasma cells were not seen in one liver biopsy, nor in the colon biopsy (Table 4).

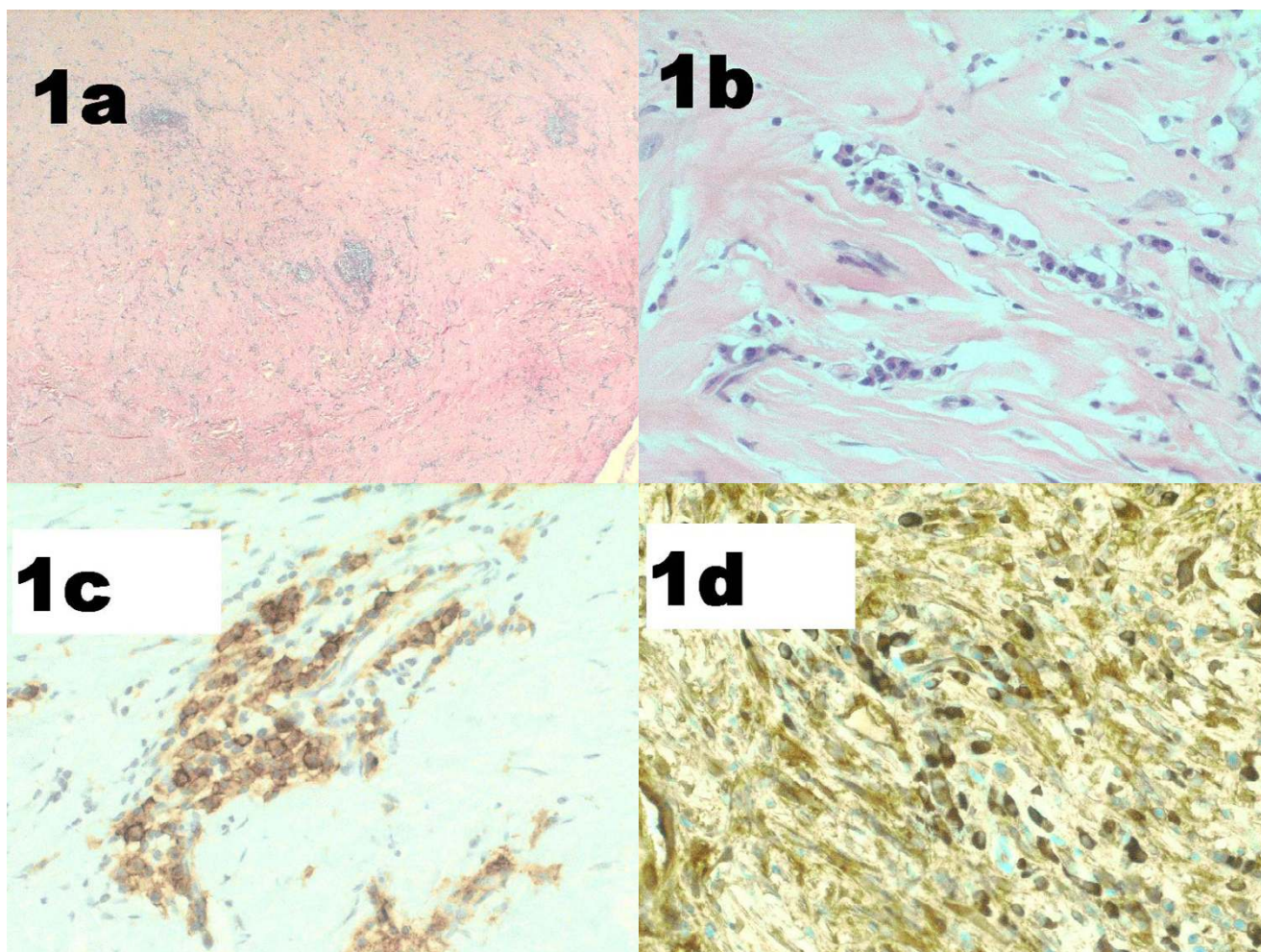
In summary, raised numbers of IgG4-positive plasma cells are seen in both peritoneal and non-peritoneal tissues in patients with hyper-IgG4 disease. The degree of IgG4-positive staining did not necessarily correlate with elevated serum IgG. Our clinical impression was that the number of IgG4-positive plasma cells was associated with disease activity.

#### Discussion

RPF is probably the most common example of the conditions associated with raised serum IgG4 and an IgG4-positive plasma cell infiltrate, which we call hyper-IgG4 diseases. The other most frequently recognised associations are sclerosing pancreatitis, Reidel's thyroiditis, retro-orbital tumour, panniculitis, and sclerosing cholangitis (see Table 2 for synonyms).

It is known that RPF can be associated with a similar fibrotic process in other organs, particularly adjacent tissues such as the mediastinum and pleura. Patients with RPF can have systemic symptoms and be febrile. We used RPF and our knowledge of its aetiology and pathogenesis to review the potential mechanisms of IgG4 disease.





**Figure 1**  
**Mesenteric mass.** Patient 3 (index case): (a, b) fibrosis, lymphoid aggregates and plasma cells (haematoxylin and eosin (a)  $\times$  100, (b)  $\times$ 400); (c) CD138-positive plasma cells; (d) IgG4-positive plasma cells.

### Retroperitoneal disease

Idiopathic RPF generally presents in a non-specific manner with malaise, fatigue, fever and weight loss [11,14-16]. Pain in the back (lumbosacral) region, flank or lower abdomen is most common. The pathognomonic feature of RPF is a thick retroperitoneal fibrotic mass covering the abdominal aorta and compressing the ureters. The process of fibrosis can result in obstruction of the ureters and renal failure, or signs and symptoms may be related to the encasement or entrapment of other structures by the inflammatory mass, such as hydrocoeles or unilateral leg oedema. With renal involvement, severe hypertension is common.

The disease presents typically between the ages of 50 and 70 years, and men are affected 2–3 times more commonly than women [14]. The inflammatory nature of idiopathic RPF is demonstrated by elevated ESR and CRP, reduced

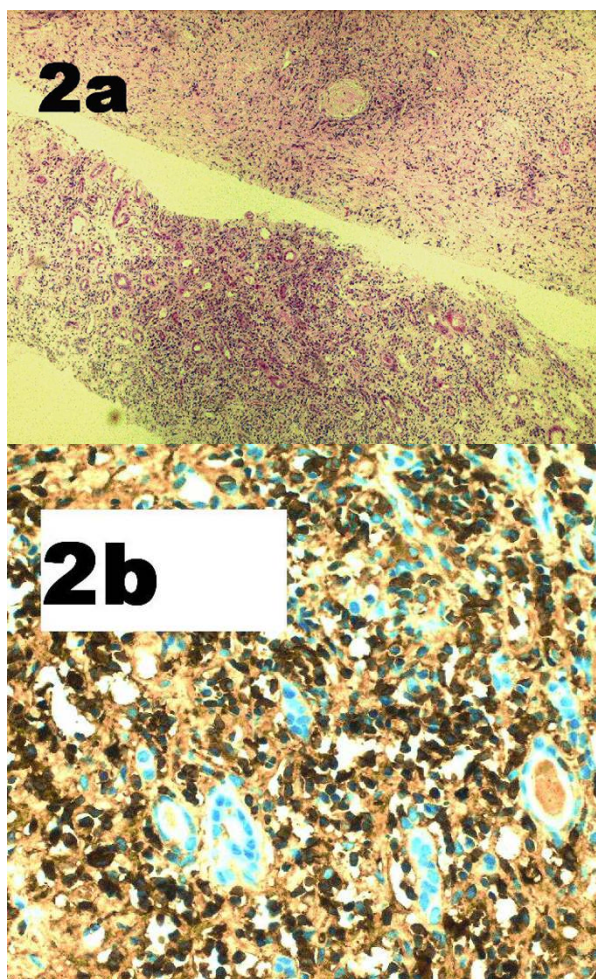
haemoglobin and elevated gammaglobulins at presentation. An autoimmune nature is suggested by the finding of ANA in 10–20% of cases, an occasional association with different autoimmune diseases and good response to glucocorticosteroids. In one series of RPF associated with periaortitis, 10 of 16 patients were ANA-positive [17].

Although there are no randomised studies of treatment for RPF, patients who present during the acute inflammatory phase respond quickly to glucocorticosteroids. Patients with late presentation and dense fibrosis will not respond to medical treatment and surgery is often necessary [11].

### Causes and associations

RPF has many causes, although in about 70% of cases the cause is unknown (idiopathic). The rest (secondary) develop as a result of malignant disease, radiation ther-





**Figure 2**  
**Renal biopsy.** Patient 1, showing renal involvement. (a) Cores of renal tissue with a conspicuous component of inter- and intra-tubular inflammatory cells (haematoxylin and eosin  $\times 100$ ); (b) IgG4-positive plasma cells.

apy, abdominal surgery, pancreatitis, retroperitoneal haemorrhage, urine extravasation, and infections. Carcinoid syndrome can cause systemic fibrosis [18], and RPF has been described without metastatic tumour [19].

#### Drugs

RPF has also been associated with the use of several drugs, but most commonly the ergotamine derivatives, especially methysergide [20] and, more recently, those used as dopamine agonists to treat Parkinson's disease, such as pergolide and cabergoline [21].

From an aetiological perspective, drugs associated with RPF are important as they also cause fibrosis in various

other sites. Systemic fibrosis is a prominent feature of methysergide use, with involvement of heart and lungs, particularly heart valves [20,22]. A similar distribution of pathology has been reported with the dopamine agonists pergolide and cabergoline [23-25].

Of pathogenetic importance is the observation that withdrawal of these offending drugs usually results in a rapid improvement in symptoms, reduction in inflammatory markers and regression of pathology [20]. Drug-induced cases are not associated with ANA [16].

#### Asbestos

Recently, asbestos exposure has been proposed as a causal factor for both pleural and retroperitoneal fibrosis [11,26-28]. Asbestos fibres also cause interstitial lung fibrosis (asbestosis), pleural fibrosis, pleural plaques, lung cancer, and pleural and peritoneal mesothelioma [29]. Patients exposed to asbestos, and particularly those with asbestosis, have an increased incidence of ANA and other autoantibodies, and raised levels of IgG and IgA. There is also a correlation between the degree of immunological abnormality and the likelihood of progression [30,31].

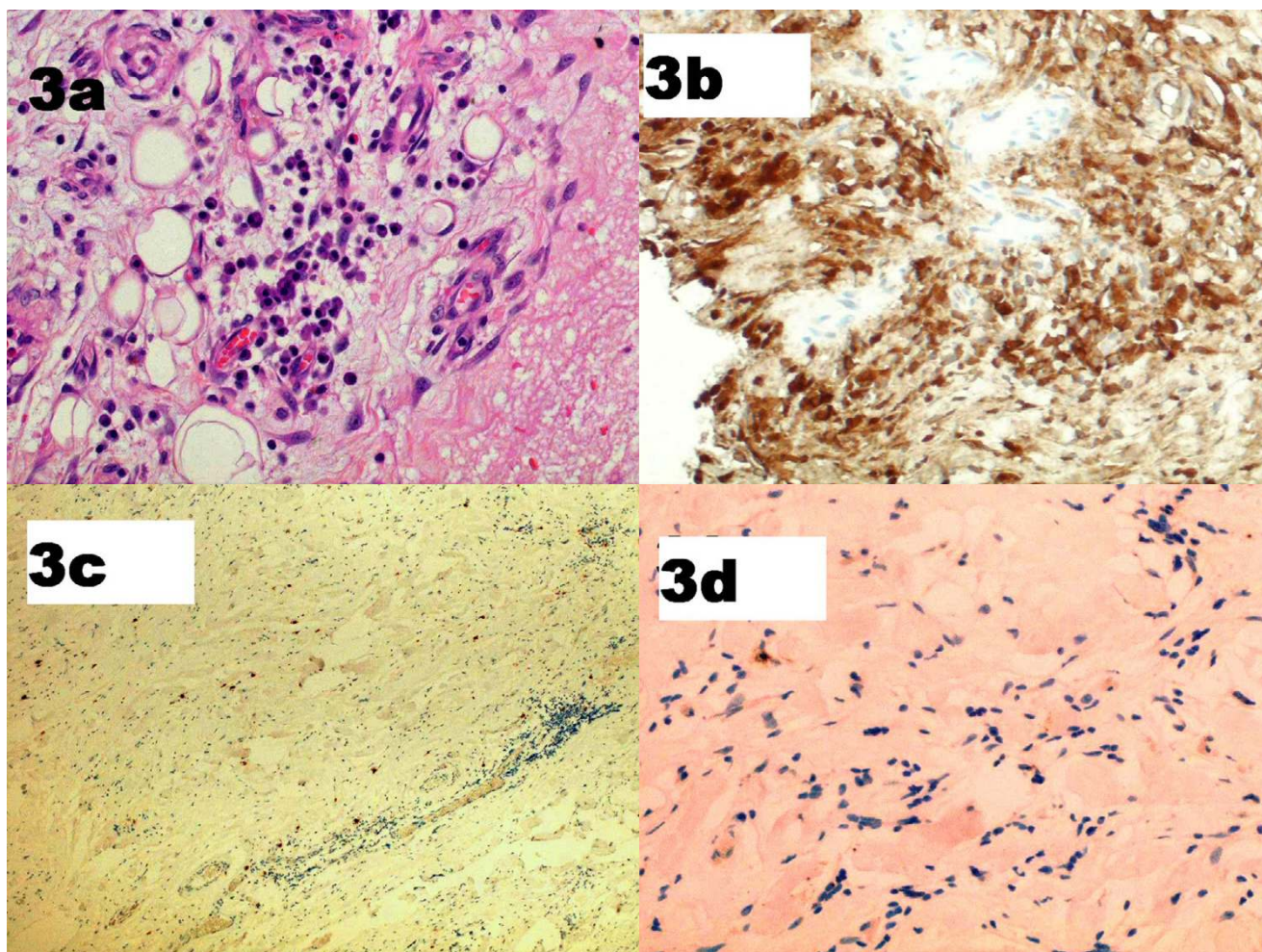
A case-control study in Finland of 43 patients with RPF (86% of eligible cases) found that the age-standardised incidence of RPF was 0.10 per 100000 person-years [11]. For every patient, five population-based matched controls were selected. There was a strong association with asbestos exposure. The odds ratio (OR) was 5.5 for  $<10$  fibre-years of asbestos exposure and 8.8 for  $\leq 10$  fibre-years. Other risk factors were previous use of ergot derivatives (OR = 9.92), abdominal aortic aneurysm (OR = 6.73) and smoking for  $>20$  pack-years (OR = 4.73) [11].

We also saw pleural calcification in three of our patients with RPF, in whom it was not present at the presentation of the illness. One of those cases is included in our archival review (patient 5, Table 4). This raises the question of whether some of the pleural pathology associated with IgG4 disease can heal with calcification as well as fibrosis [32].

#### Aortitis

The relationship of aortic aneurysms with an inflamed and thickened aortic wall, extensive periaortic inflammation and RPF is well known [33]. As the inflammatory aneurysms of the abdominal aorta differ from RPF only in the diameter of the inflamed aorta, it has been suggested that both syndromes represent only variations of the same disease, which has been named 'chronic periaortitis' [34]. RPF has been suggested as the most severe form of chronic periaortitis [35,36]. Vasculitis of the vasa vasorum was thought to be a factor in the aneurysmal dilatation [34,37].





**Figure 3**  
**Retroperitoneal tissue.** Patient 7. Pre-glucocorticoid treatment: (a) fibrosis and plasma cells (haematoxylin and eosin  $\times 400$ ); (b) IgG4-positive plasma cells. Post-glucocorticoid treatment: (c) scattered CD138-positive plasma cells; (d) IgG4 staining reveals no positive cells.

Several observations suggest an immunological pathogenesis for this periaortitis. As well as the periaortal tissue, the media and adventitia of the aorta are infiltrated by polyclonal B lymphocytes, activated CD4-positive T lymphocytes, and plasma cells [35]. In 85% of patients, the necrotic media contains deposits of IgG antibodies in close proximity to extracellular ceroid, and the serum often contains antibodies against ceroid and oxidised low-density lipoprotein [38].

Although it was initially proposed that the aortitis was caused by an autoimmune response to the components of atherosclerotic plaques [38] with antibodies to atheroma, more recent opinion has suggested that in view of the accompanying systemic symptoms and acute phase response, the aortitis is a primary autoimmune disease [17,36,39,40].

#### *Autoimmune and other rare associations*

While there is no one predominant association, a large range of autoimmune diseases has been described in association with RPF (Table 3), and 10–20% of cases will have ANA or other autoantibodies.

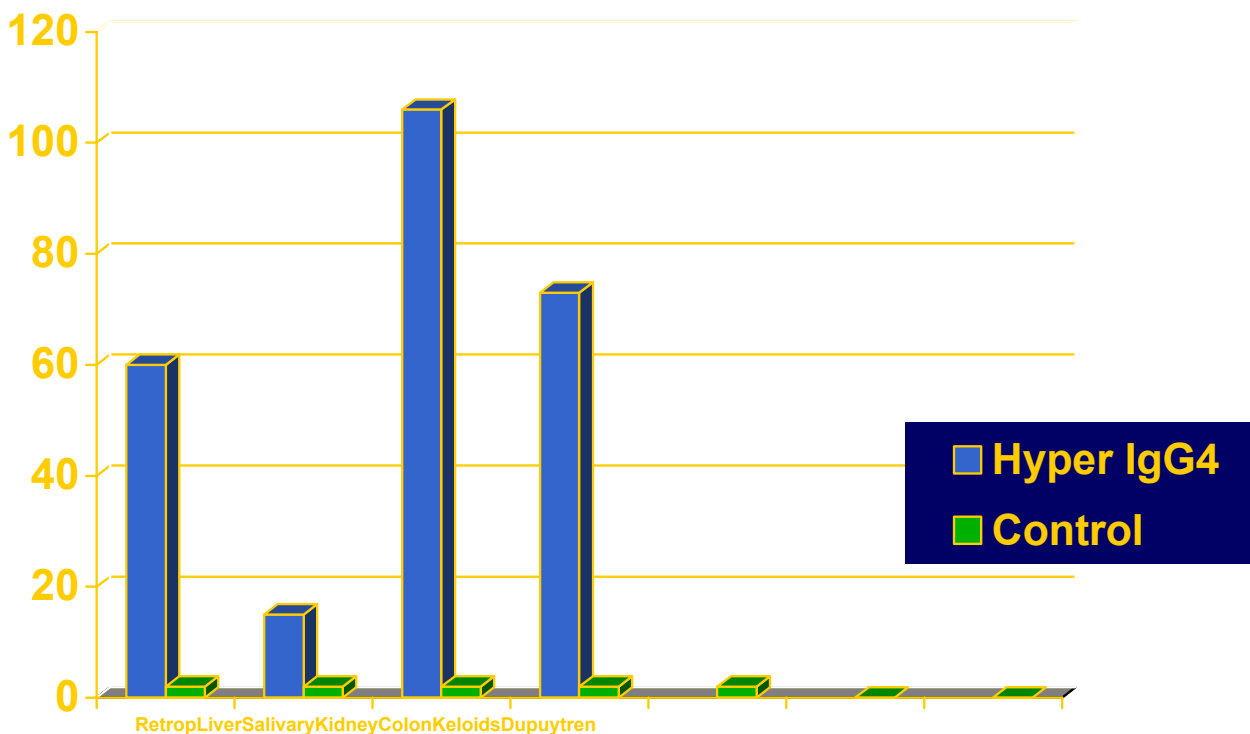
#### *Paediatric*

RPF in the paediatric population is rare with, only 23 cases reported in the English-language literature by 2003 [41]. A family has been reported in which two children had idiopathic retroperitoneal fibrosis, and they and their father had clinical and laboratory evidence of systemic immunological diseases [42].

#### *Familial*

Two brothers from a first-cousin consanguineous marriage were reported, who had different combinations of

# IgG4 immunostaining



## Biopsied tissues

**Figure 4**  
**Histopathology: IgG4 immunostaining (cases versus controls).** Vertical axis (0–120) shows number of IgG4-positive plasma cells/high power field (see Methods for details). Histological data from salivary gland is positive control, (from previously reported study [3,4]).

RPF, mediastinal fibrosis, sclerosing cholangitis, Riedel sclerosing thyroiditis, and pseudotumour of the orbit. One of the brothers had fibrotic contracture of the fingers [43]. Other reports are of RPF in three siblings with sickle-cell trait [44], and mediastinal and retroperitoneal fibrosis in two sisters with seronegative spondyloarthritis [45].

### RPF invading adjacent organs

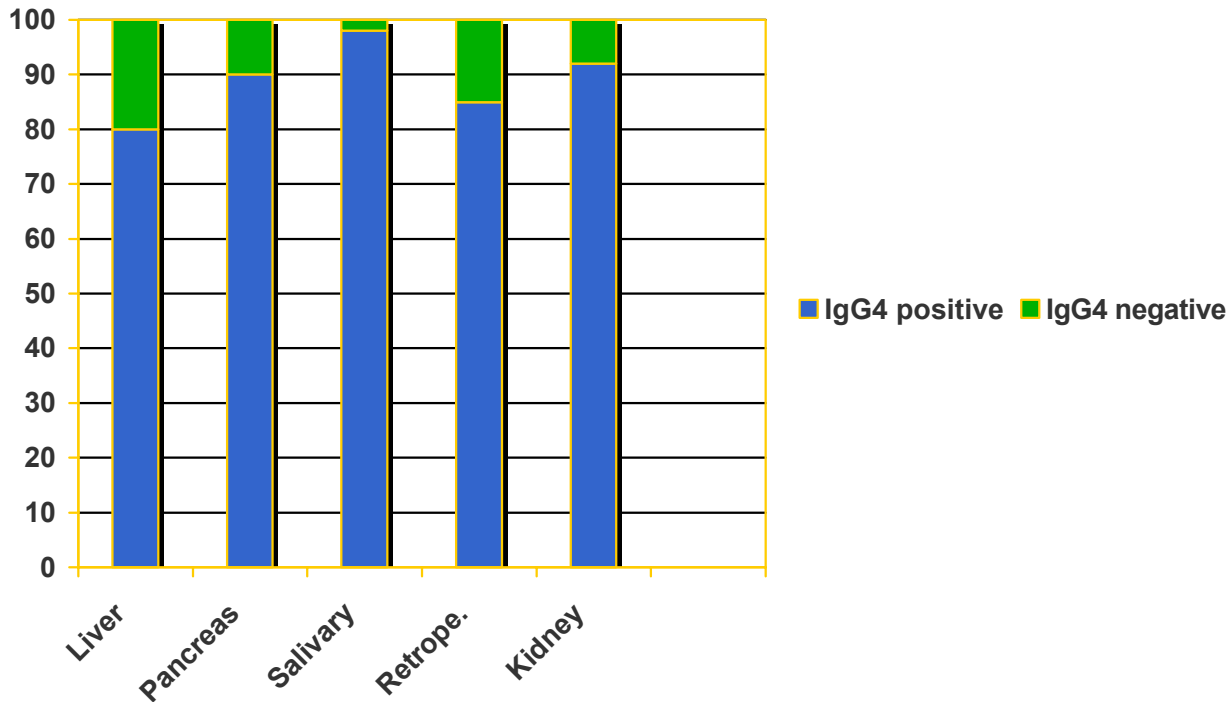
Rarely, the inflammatory tissue seen in RPF can invade the renal parenchyma [46-48] and it can occasionally cause a tumour-like mass away from the retroperitoneum [49]. There are four isolated surgical case reports in the literature, with two being described as idiopathic RPF, one as

systemic hyalinizing granuloma and the other as xanthofibrogranuloma. We have seen one case in which the IgG4-positive inflammatory mass (Figure 2) invaded the kidney and liver (patient 1, Table 4), and another in which it caused a large tumour like mass in the left iliac fossa (patient 2). Both cases responded promptly to steroids.

### Summary

Although all our archival cases of idiopathic RPF have shown evidence of IgG4 involvement, it remains to be seen whether IgG4 plays any role in other types of RPF such as periaortitis, drug-induced and asbestos-related RPF. We certainly found it (in retroperitoneal tissue) in one of our patients who developed pleural calcification.

## Percentage of IgG4-bearing plasma cells in “Hyper IgG4 disease”



**Figure 5**  
Percentage of IgG4-bearing plasma cells.

### Lung disease

Part of the spectrum of disease in patients with hyper-IgG4 disease is parenchymal lung pathology, often described as either bronchiolitis obliterans with organizing pneumonia or cryptogenic organizing pneumonia [50]. This is seen typically as migratory pulmonary infiltrates, and is steroid-responsive. Nevertheless, there are at present no studies that have looked for evidence of IgG4 plasma cells in these conditions [51]. Other conditions associated with migratory pulmonary infiltrates that may be related, but not yet investigated, include pulmonary eosinophilia, hypersensitivity to drugs, parasitic infection, allergic bronchopulmonary aspergillosis and Churg-Strauss vasculitis [52]. Pleural thickening, with and without calcification, is well described [32,32,53]. There are

also reports of calcifying pseudo-tumour of the pleura [54,55] and peritoneum [56].

### Differential diagnosis of febrile illness

Fever of unknown origin (FUO) in an immunocompetent patient is defined as an illness of more than 3 weeks' duration with fever higher than 38.3°C (101°F) on several occasions, and with an uncertain diagnosis after 1 week of investigation [57]. Infection accounts for about one-third of cases (25–32%) of FUO, followed by non-infectious inflammatory disease (21–31%) and neoplasm (12–17%) [58–62]. Although many patients with FUO will be found to have bacterial infection, rarer diagnoses will be considered with time and extensive investigation. Nevertheless, at the end of all investigations, 18–30% of

patients will have no diagnosis, although the majority of this idiopathic group will improve spontaneously [60]. We propose that hyper-IgG4 disease can be added to this list of systemic inflammatory diseases.

### Pathogenesis

#### *Conditions associated with elevated IgG4*

IgG4 is the rarest of the IgG subclasses to be expressed, accounting for only 3–6% of total IgG in normal serum. It has a low affinity for target antigen. It is unique among the IgG subclasses, as it is unable to bind C1q complement and cannot activate the classic complement pathway [63]. IgG4 is a T-helper 2 (Th2)-dependent isotype. Interleukin (IL)-4 directs naive human B cells to switch to IgG4 and IgE production [64]; IL-10 and IL-13 are the other T-cell-derived cytokines that activate this differentiation.

High serum IgG4 concentrations are found in a limited number of other conditions, including atopic dermatitis [65], some parasitic diseases (helminthic diseases) [66], and pemphigus vulgaris (PV) and pemphigus foliaceus (PF) [67,68].

In allergic individuals, a feature of successful immunotherapy is the induction of allergen-specific IgG4 antibodies, even with the persistence of allergen-specific IgE [69,70]. High levels of the immunosuppressive cytokine IL-10 are found both in patients chronically infected with helminths and in those receiving allergen immunotherapy [71]. IL-10 also stimulates IgG4 production [72].

Th2 responses to allergens are suppressed by both CD4+ CD25+ T regulatory cells (Tregs) and IL-10-producing Tregs [73], and suppression by these subsets is decreased in allergic individuals. In animal models, Tregs can be induced by high- or low-dose inhaled antigen, and prior induction of Tregs prevents subsequent development of allergen sensitization and airway inflammation in inhaled challenge models. Allergen-injection immunotherapy may induce IL-10 Tregs, leading to both suppression of Th2 responses and a switch from IgE to IgG4 antibody production [73].

#### *Helminths*

Asymptomatic infections with helminth parasites are correlated with high levels of IgG4, and parasite-specific IgG4 antibodies can inhibit IgE-mediated degranulation of mast cells [66]. In most helminth infections, the Th2 response leads to rapid parasite expulsion or sequestration. During murine *Schistosoma mansoni* infection, however, parasites persist and the chronic Th2 response can induce severe pathological fibrosis in the gut and liver [74]. Evidence both from these mouse models and from human studies suggests that this progression to severe disease with intense fibrosis occurs in only a minority of

cases, and is a consequence of the strongly profibrotic type 2 cytokine response mediated by IL-4 and IL-13 [74].

#### *Pemphigus and pemphigoid*

PV and PF are autoimmune skin diseases caused by autoantibodies against desmoglein 3 and desmoglein 1 respectively. These antibodies are predominantly of the IgG4 subclass [67,68]. Desmogleins are keratinocyte transmembrane proteins localized in the desmosome, and are members of the adhesion molecule family of cadherins. The interaction of antidesmoglein antibodies with their target antigens leads to loss of cell adhesion (acantholysis) and the formation of intraepithelial blisters of the skin and mucous membranes. The antibodies predominantly, but not exclusively, bind to the extracellular domains of the proteins and exert their pathogenic effect not through inhibition of the proteins' adhesive properties, but through an indirect pathway involving cellular signalling pathways, resulting in destabilization of desmoglein 1-based adhesive sites and desmosomes [75].

Bullous pemphigoid (BP) is an autoimmune blistering disease associated with autoantibodies against the hemidesmosomal glycoprotein BP180. The noncollagenous (NC)16A domain of BP180 has major antigenic sites recognized by BP sera. IgG4 and IgE are the major immunoglobulins that preferentially react with two distinct epitopes within this domain. Levels of these autoantibodies correlated with disease activity in BP [76].

#### *Autoimmune pancreatitis*

In sclerosing pancreatitis, evidence had been reported to suggest an immunological pathogenesis even before the description of a role for IgG4. In one study of 17 patients, ANA and antilactoferrin antibodies were detected in 76%, carbonic anhydrase II antibody in 59%, rheumatoid factor in 29% and anti-smooth-muscle antibody in 18% of patients. CD8+ and CD4+ cells were significantly increased in peripheral blood. CD4+ cells produced increased levels of interferon gamma compared with controls, but IL-4 was not increased [77]. However, in another Japanese study, which divided patients with sclerosing pancreatitis into a seronegative and seropositive group, found no differences in presentation, pathology or natural history between the groups [78].

#### *HLA associations with IgG4-associated diseases*

- PV was consistently found to be associated with DR4 and DR14 and, more precisely, with DRB1\*0402 and DRB1\*1401 subtypes [79]. Susceptibility to PF has been correlated with the presence of DR4, DR14 and DR1 alleles; however, in contrast to PV, no single DR4 or DR14 allele was shown to be associated with the disease.



- In an immunogenetic study of patients with autoimmune pancreatitis, a significant increase in DR4 was found. It was concluded that the DRB1\*0405-DQB1\*0401 haplotype was associated with autoimmune pancreatitis in the Japanese population [80].

- Aortoarteritis is a chronic inflammatory disease, mainly affecting the aorta and its major branches. In a Chinese Han population, the DRB1\*04 and DRB1\*07 alleles were significantly associated with aortoarteritis. Furthermore, there was no significant difference in the frequency of the DRB1\*0405 subtype between the patient and control groups [81].

- In China, the HLA-DRB5\*0101 allele and the IL-13 promoter A/A genotype were both found to be elevated in schistosomal hepatic fibrosis, although the two genes are located on different chromosomes. Subjects with both genotypes had odds ratios much higher (OR = 24.5) than the sum of the ratios for each individual genotype. The study strongly suggested that a pathogenic Th2 response directly influenced the prognosis of post-schistosomal liver fibrosis[82].

## Conclusion

We believe that hyper-IgG4 disease is an important condition to recognise as the diagnosis can be verified by histology and simple blood tests, and the outcome with treatment during the acute phase is very good. A raised IgG concentration in the absence of hypergammaglobulinaemia is typical, but ideally IgG4 should also be measured. Even when pathology appears localised, as with RPF, constitutional symptoms can be present with evidence of an acute phase response. Rarely a systemic form of the disease will present with severe constitutional symptoms, and hyper-IgG4 disease can be added to list of unusual causes of FUO. Although the role and relevance of IgG4 is unknown, the dense fibrosis that accompanies healing would appear to be a typical example of Th2-mediated pathology.

## Competing interests

The author(s) declare that they have no competing interests.

## Authors' contributions

GH Neild was involved with clinical management of the patients and was responsible for the writing of the paper. Manuel Rodriguez-Justo reviewed and examined all the histological material and helped to write the paper. Catherine Wall and John O Connolly were both involved with the clinical management of the index case and several of the patients with RPF, and helped to write the paper.

## Acknowledgements

We thank Ms P Munson for performing IgG4 immunostaining. We thank Drs Robin Woolfson and Helen Lachmann for reading the manuscript and making valuable contributions to its preparation. We would like to thank our colleagues Dr FD Thompson, Dr MA Mansell, Dr RG Woolfson and Dr BR Leaker for their help with the management of patients. Written consent was obtained from the patient for publication of the case history.

## References

1. Streuli R, Egger C, Truniger B: **Systemic fibrosis (generalized xanthofibrogranulomatosis)**. *Nephrol Dial Transplant* 1997, **12**:608-609.
2. Kastendieck H, Husselmann H: **[Xanthofibrogranulomatosis. Classification, localization, morphology, pathogenesis] (author's translation)**. *Virchows Arch A Pathol Anat Histol* 1978, **380**:237-259.
3. Webster GJ, Wittman J, Seward E, Pereira SP, Hatfield AR: **Autoimmune pancreatitis/choliopancreatopathy – evidence of multi-system involvement [abstract 048]**. *Gut* 2006, **54**:a1-117.
4. Deheragoda MG, Church NI, Rodriguez-Justo M, Seward E, Novelli MR, Pereira S, Hatfield ARW, Webster GJM: **IgG4 immunostaining in autoimmune pancreatitis and in extra-pancreatic disease [abstract]**. *Pancreatology* 2006, **6**:193.
5. Hamano H, Kawa S, Ochi Y, Unno H, Shiba N, Wajiki M, Nakazawa K, Shimojo H, Kiyosawa K: **Hydronephrosis associated with retroperitoneal fibrosis and sclerosing pancreatitis**. *Lancet* 2002, **359**:1403-1404.
6. Hamano H, Kawa S, Horiuchi A, Unno H, Furuya N, Akamatsu T, Fukushima M, Nikaïdo T, Nakayama K, Usuda N, Kiyosawa K: **High serum IgG4 concentrations in patients with sclerosing pancreatitis**. *N Engl J Med* 2001, **344**:732-738.
7. Kamisawa T, Funata N, Hayashi Y: **Lymphoplasmacytic sclerosing pancreatitis is a pancreatic lesion of IgG4-related systemic disease**. *Am J Surg Pathol* 2004, **28**:1114.
8. Kamisawa T, Nakajima H, Egawa N, Funata N, Tsuruta K, Okamoto A: **IgG4-related sclerosing disease incorporating sclerosing pancreatitis, cholangitis, sialadenitis and retroperitoneal fibrosis with lymphadenopathy**. *Pancreatology* 2006, **6**:132-137.
9. Kamisawa T, Funata N, Hayashi Y, Tsuruta K, Okamoto A, Amemiya K, Egawa N, Nakajima H: **Close relationship between autoimmune pancreatitis and multifocal fibrosclerosis**. *Gut* 2003, **52**:683-687.
10. Kamisawa T: **IgG4-related sclerosing disease**. *Intern Med* 2006, **45**:125-126.
11. Uibu T, Oksa P, Auvinen A, Honkanen E, Metsarinne K, Saha H, Uitti J, Roto P: **Asbestos exposure as a risk factor for retroperitoneal fibrosis**. *Lancet* 2004, **363**:1422-1426.
12. Aoki S, Nakazawa T, Ohara H, Sano H, Nakao H, Joh T, Murase T, Eimoto T, Itoh M: **Immunohistochemical study of autoimmune pancreatitis using anti-IgG4 antibody and patients' sera**. *Histopathology* 2005, **47**:147-158.
13. Oshiro H, Ebihara Y, Serizawa H, Shimizu T, Teshima S, Kuroda M, Kudo M: **Idiopathic retroperitoneal fibrosis associated with immunohematological abnormalities**. *Am J Med* 2005, **118**:782-786.
14. Baker LR, Mallinson WJ, Gregory MC, Menzies EA, Cattell WR, Whitfield HN, Hendry WF, Wickham JE, Joekes AM: **Idiopathic retroperitoneal fibrosis. A retrospective analysis of 60 cases**. *Br J Urol* 1987, **60**:497-503.
15. Yaqoob MM, Junaid I: **The patient with urinary tract obstruction**. In *Oxford Textbook of Clinical Nephrology* Edited by: Davison AM, Cameron JS, Grunfeld J-P, Ponticelli C, Ritz E, Winearls CG, et al. Oxford: Oxford University Press; 2005:2465-2470.
16. van Bommel EF: **Retroperitoneal fibrosis**. *Neth J Med* 2002, **60**:231-242.
17. Vaglio A, Corradi D, Manenti L, Ferretti S, Garini G, Buzio C: **Evidence of autoimmunity in chronic periaortitis: a prospective study**. *Am J Med* 2003, **114**:454-462.
18. Modlin IM, Shapiro MD, Kidd M: **Carcinoid tumors and fibrosis: an association with no explanation**. *Am J Gastroenterol* 2004, **99**:2466-2478.
19. Chander S, Ergun EL, Chugani HT, Chugani DC, Juhasz C, Shields AF, Weaver DW: **High 2-deoxy-2-[18F]fluoro-D-glucose accumu-**



- lation in a case of retroperitoneal fibrosis following resection of carcinoid tumor. *Mol Imaging Biol* 2002, **4**:363-368.
20. Graham JR, Suby HI, LeCompte PR, Sadovsky NL: **Fibrotic disorders associated with methysergide therapy for headache.** *N Engl J Med* 1966, **274**:359-368.
  21. Shaunak S, Wilkins A, Pilling JB, Dick DJ: **Pericardial, retroperitoneal, and pleural fibrosis induced by pergolide.** *J Neurol Neurosurg Psychiatry* 1999, **66**:79-81.
  22. Graham JR: **Cardiac and pulmonary fibrosis during methysergide therapy for headache.** *Am J Med Sci* 1967, **254**:1-12.
  23. Horvath J, Fross RD, Kleiner-Fisman G, Lerch R, Stalder H, Liaudat S, Raskoff WJ, Flachsbarth KD, Rakowski H, Pache JC, Burkhard PR, Lang AE: **Severe multivalvular heart disease: a new complication of the ergot derivative dopamine agonists.** *Mov Disord* 2004, **19**:656-662.
  24. Bleumink GS, Molen-Eijgenraam M, Stribos JH, Sanwikarja S, van Puijenbroek EP, Stricker BH: **Pergolide-induced pleuropulmonary fibrosis.** *Clin Neuropharmacol* 2002, **25**:290-293.
  25. Pritchett AM, Morrison JF, Edwards WVD, Schaff HV, Connolly HM, Espinosa RE: **Valvular heart disease in patients taking pergolide.** *Mayo Clin Proc* 2002, **77**:1280-1286.
  26. Maguire GP, Meggs LG, Addonizio J, Del Guercio LR: **Association of asbestos exposure, retroperitoneal fibrosis, and acute renal failure.** *N Y State J Med* 1991, **91**:357-359.
  27. Boulard JC, Hanslik T, Doleris LM, Prinseau J, Baglin A: **Asbestos and idiopathic retroperitoneal fibrosis.** *Lancet* 1995, **345**:1379.
  28. Sauni R, Oksa P, Jarvenpaa R, Parker JE, Roto P: **Asbestos exposure: a potential cause of retroperitoneal fibrosis.** *Am J Ind Med* 1998, **33**:418-421.
  29. Manning CB, Vallyathan V, Mossman BT: **Diseases caused by asbestos: mechanisms of injury and disease development.** *Int Immunopharmacol* 2002, **2**:191-200.
  30. Nigam SK, Suthar AM, Patel MM, Karnik AB, Dave SK, Kashyap SK, Venkaiah K: **Humoral immunological profile of workers exposed to asbestos in asbestos mines.** *Indian J Med Res* 1993, **98**:274-277.
  31. Pfau JC, Sentissi JJ, Weller G, Putnam EA: **Assessment of autoimmune responses associated with asbestos exposure in Libby, Montana, USA.** *Environ Health Perspect* 2005, **113**:25-30.
  32. Nishi K, Myou S, Ooka T, Fujimura M, Matsuda T: **A case of pleural involvement followed by idiopathic retroperitoneal fibrosis.** *Nihon Kyobu Shikkan Gakkai Zasshi* 1993, **31**:876-880.
  33. Walker DI, Bloor K, Williams G, Gillie I: **Inflammatory aneurysms of the abdominal aorta.** *Br J Surg* 1972, **59**:609-614.
  34. Mitchinson MJ: **Chronic periaortitis and periarteritis.** *Histopathology* 1984, **8**:589-600.
  35. Parums DV, Dunn DC, Dixon AK, Mitchinson MJ: **Characterization of inflammatory cells in a patient with chronic periaortitis.** *Am J Cardiovasc Pathol* 1990, **3**:121-129.
  36. Vaglio A, Salvarani C, Buzio C: **Retroperitoneal fibrosis.** *Lancet* 2006, **367**:241-251.
  37. Lindell OI, Sariola HV, Lehtonen TA: **The occurrence of vasculitis in perianeurysmal fibrosis.** *J Urol* 1987, **138**:727-729.
  38. Parums DV, Brown DL, Mitchinson MJ: **Serum antibodies to oxidized low-density lipoprotein and ceroid in chronic periaortitis.** *Arch Pathol Lab Med* 1990, **114**:383-387.
  39. Vaglio A, Buzio C: **Chronic periaortitis: a spectrum of diseases.** *Curr Opin Rheumatol* 2005, **17**:34-40.
  40. Moroni G, Del Papa N, Moronetti LM, Vitali C, Maglione W, Comina DP, Urganani F, Sandri S, Ponticelli C, Cortelezzi A: **Increased levels of circulating endothelial cells in chronic periaortitis as a marker of active disease.** *Kidney Int* 2005, **68**:562-568.
  41. Miller OF, Smith LJ, Ferrara EX, McAleer IM, Kaplan GW: **Presentation of idiopathic retroperitoneal fibrosis in the pediatric population.** *J Pediatr Surg* 2003, **38**:1685-1688.
  42. Doolin EJ, Goldstein H, Kessler B, Vinocur C, Marchildon MB: **Familial retroperitoneal fibrosis.** *J Pediatr Surg* 1987, **22**:1092-1094.
  43. Comings DE, Skubi KB, Van Eyes J, Motulsky AG: **Familial multifocal fibrosclerosis. Findings suggesting that retroperitoneal fibrosis, mediastinal fibrosis, sclerosing cholangitis, Riedel's thyroiditis, and pseudotumor of the orbit may be different manifestations of a single disease.** *Ann Intern Med* 1967, **66**:884-892.
  44. Phills JA, Geggie P, Hidvegi RI, Oliva LA: **Retroperitoneal fibrosis in three siblings with the sickle cell trait.** *Can Med Assoc J* 1973, **108**:1025-1029.
  45. Goldbach P, Mohsenifar Z, Salick AI: **Familial mediastinal fibrosis associated with seronegative spondylarthropathy.** *Arthritis Rheum* 1983, **26**:221-225.
  46. Chalaoui J, Gregoire P, Sylvestre J, Lefebvre R, Amyot R: **Pulmonary hyalinizing granuloma: a cause of pulmonary nodules.** *Radiology* 1984, **152**:23-26.
  47. Kell HH, Schumann HJ: **Retroperitoneal xanthofibrogranuloma simulating kidney tumor.** *Zentralbl Chir* 1973, **98**:968-971.
  48. Kohler HP, Laeng RH, Egger C, Streuli R: **Systemic fibrosis (generalized form of Ormond's disease). Report of a case which achieved complete remission with cyclophosphamide and corticosteroids.** *Schweiz Med Wochenschr* 1995, **125**:2131-2136.
  49. Takashima T, Onoda N, Ishikawa T, Koyama T, Inaba M, Nishizawa Y, Nakatani T, Wakasa K, Hirakawa K: **Tumor-forming idiopathic retroperitoneal fibrosis: report of a case.** *Surg Today* 2004, **34**:374-378.
  50. Duvic C, Desrame J, Leveque C, Nedelec G: **Retroperitoneal fibrosis, sclerosing pancreatitis and bronchiolitis obliterans with organizing pneumonia.** *Nephrol Dial Transplant* 2004, **19**:2397-2399.
  51. Hirano K, Kawabe T, Komatsu Y, Matsubara S, Togawa O, Arizumi T, Yamamoto N, Nakai Y, Sasahira N, Tsujino T, Toda N, Isayama H, Tada M, Omata M: **High-rate pulmonary involvement in autoimmune pancreatitis.** *Intern Med J* 2006, **36**:58-61.
  52. King TE Jr: **BOOP: an important cause of migratory pulmonary infiltrates?** *Eur Respir J* 1995, **8**:193-195.
  53. Shimizu T, Furuichi S, Takahashi N, Koya Y, Akashiba T, Horie T: **[A case of intrathoracic extension of retroperitoneal fibrosis].** *Nihon Kokyuki Gakkai Zasshi* 2001, **39**:748-752.
  54. Ammar A, El Hammami S, Horchani H, Sellami N, Kilani T: **Calcifying fibrous pseudotumor of the pleura: a rare location.** *Ann Thorac Surg* 2003, **76**:2081-2082.
  55. Cavazza A, Gelli MC, Agostini L, Sgarbi G, De Marco L, Gardini G: **Calcified pseudotumor of the pleura: description of a case.** *Pathologica* 2002, **94**:201-205.
  56. Kocova L, Michal M, Sulc M, Zamecnik M: **Calcifying fibrous pseudotumor of visceral peritoneum.** *Histopathology* 1997, **31**:182-184.
  57. Petersdorf RG, Beeson PB: **Fever of unexplained origin: report on 100 cases.** *Medicine (Baltimore)* 1961, **40**:1-30.
  58. de Kleijn EM, Vandenbroucke JP, van der Meer JW: **Fever of unknown origin (FUO). I. A prospective multicenter study of 167 patients with FUO, using fixed epidemiologic entry criteria. The Netherlands FUO Study Group.** *Medicine (Baltimore)* 1997, **76**:392-400.
  59. Knockaert DC, Vanneste LJ, Bobbaers HJ: **Fever of unknown origin in elderly patients.** *J Am Geriatr Soc* 1993, **41**:1187-1192.
  60. Mourad O, Palda V, Detsky AS: **A comprehensive evidence-based approach to fever of unknown origin.** *Arch Intern Med* 2003, **163**:545-551.
  61. Zhiyong Z, Bingjun L, Xiaoju L, Xinjian F, Ping F, Wenya W: **Fever of unknown origin: a report from China of 208 cases.** *Int J Clin Pract* 2003, **57**:592-596.
  62. Bleeker-Rovers CP, de Kleijn EM, Corstens FH, van der Meer JW, Oyen WJ: **Clinical value of FDG PET in patients with fever of unknown origin and patients suspected of focal infection or inflammation.** *Eur J Nucl Med Mol Imaging* 2004, **31**:29-37.
  63. Van der Zee JS, van Swieten P, Aalberse RC: **Inhibition of complement activation by IgG4 antibodies.** *Clin Exp Immunol* 1986, **64**:415-422.
  64. Punnonen J, Aversa G, Cocks BG, McKenzie AN, Menon S, Zurawski G, de Waal MR, de Vries JE: **Interleukin 13 induces interleukin 4-independent IgG4 and IgE synthesis and CD23 expression by human B cells.** *Proc Natl Acad Sci U S A* 1993, **90**:3730-3734.
  65. Aalberse RC, Van Milligen F, Tan KY, Stapel SO: **Allergen-specific IgG4 in atopic disease.** *Allergy* 1993, **48**:559-569.
  66. Hussain R, Poindexter RW, Ottesen EA: **Control of allergic reactivity in human filariasis. Predominant localization of blocking antibody to the IgG4 subclass.** *J Immunol* 1992, **148**:2731-2737.
  67. Jones CC, Hamilton RG, Jordan RE: **Subclass distribution of human IgG autoantibodies in pemphigus.** *J Clin Immunol* 1988, **8**:43-49.
  68. Futei Y, Amagai M, Ishii K, Kuroda-Kinoshita K, Ohya K, Nishikawa T: **Predominant IgG4 subclass in autoantibodies of pemphigus vulgaris and foliaceus.** *J Dermatol Sci* 2001, **26**:55-61.

69. Ebner C, Siemann U, Bohle B, Willheim M, Wiedermann U, Schenk S, Klotz F, Ebner H, Kraft D, Scheiner O: **Immunological changes during specific immunotherapy of grass pollen allergy: reduced lymphoproliferative responses to allergen and shift from TH2 to TH1 in T-cell clones specific for Phl p I, a major grass pollen allergen.** *Clin Exp Allergy* 1997, **27**:1007-1015.
70. Platts-Mills T, Vaughan J, Squillace S, Woodfolk J, Sporik R: **Sensitization, asthma, and a modified Th2 response in children exposed to cat allergen: a population-based cross-sectional study.** *Lancet* 2001, **357**:752-756.
71. Akdis CA, Blesken T, Akdis M, Wuthrich B, Blaser K: **Role of interleukin 10 in specific immunotherapy.** *J Clin Invest* 1998, **102**:98-106.
72. Jeannin P, Lecoanet S, Delneste Y, Gauchat JF, Bonnefoy JY: **IgE versus IgG4 production can be differentially regulated by IL-10.** *J Immunol* 1998, **160**:3555-3561.
73. Robinson DS, Larche M, Durham SR: **Tregs and allergic disease.** *J Clin Invest* 2004, **114**:1389-1397.
74. Ramalingam TR, Reiman RM, Wynn TA: **Exploiting worm and allergy models to understand Th2 cytokine biology.** *Curr Opin Allergy Clin Immunol* 2005, **5**:392-398.
75. Waschke J, Bruggeman P, Baumgartner W, Zillikens D, Drenckhahn D: **Pemphigus foliaceus IgG causes dissociation of desmoglein 1-containing junctions without blocking desmoglein 1 transinteraction.** *J Clin Invest* 2005, **115**:3157-3165.
76. Dopp R, Schmidt E, Chimanovitch I, Leverkus M, Brocker EB, Zillikens D: **IgG4 and IgE are the major immunoglobulins targeting the NC16A domain of BP180 in bullous pemphigoid: serum levels of these immunoglobulins reflect disease activity.** *J Am Acad Dermatol* 2000, **42**:577-583.
77. Okazaki K, Uchida K, Ohana M, Nakase H, Uose S, Inai M, Matsushima Y, Katamura K, Ohmori K, Chiba T: **Autoimmune-related pancreatitis is associated with autoantibodies and a Th1/Th2-type cellular immune response.** *Gastroenterology* 2000, **118**:573-581.
78. Wakabayashi T, Kawaura Y, Satomura Y, Urabe T, Watanabe H, Motoo Y, Sawabu N: **Duct-narrowing chronic pancreatitis without immunoserologic abnormality: comparison with duct-narrowing chronic pancreatitis with positive serological evidence and its clinical management.** *Dig Dis Sci* 2005, **50**:1414-1421.
79. Tron F, Gilbert D, Mouquet H, Joly P, Drouot L, Makni S, Masmoudi H, Charron D, Zitouni M, Loiseau P, Ben Ayed M: **Genetic factors in pemphigus.** *J Autoimmun* 2005, **24**:319-328.
80. Kawa S, Ota M, Yoshizawa K, Horiuchi A, Hamano H, Ochi Y, Nakayama K, Tokutake Y, Katsuyama Y, Saito S, Hasebe O, Kiyosawa K: **HLA DRB1\*0405-DQB1\*0401 haplotype is associated with autoimmune pancreatitis in the Japanese population.** *Gastroenterology* 2002, **122**:1264-1269.
81. Dang A, Wang B, Zhang Y, Zhang P, Huang J, Liu G, Zheng D, Qiu C, Liu L: **Association of the HLA-DRB1 gene with susceptibility to aortoarteritis in a Chinese Han population.** *Hypertens Res* 2002, **25**:631-634.
82. Hirayama K: **Immunogenetic analysis of post-schistosomal liver fibrosis.** *Parasitol Int* 2004, **53**:193-196.
83. Voss SD, Kruskal JB, Kane RA: **Chronic inflammatory pseudotumor arising in the hepatobiliary-pancreatic system: progressive multisystemic organ involvement in four patients.** *AJR Am J Roentgenol* 1999, **173**:1049-1054.
84. van der Vliet HJ, Perenboom RM: **Multiple pseudotumors in IgG4-associated multifocal systemic fibrosis.** *Ann Intern Med* 2004, **141**:896-897.
85. Clark A, Zeman RK, Choyke PL, White EM, Burrell MI, Grant EG, Jaffe MH: **Pancreatic pseudotumors associated with multifocal idiopathic fibrosclerosis.** *Gastrointest Radiol* 1988, **13**:30-32.
86. Goto Y, Ohaki Y, Ibaraki N: **A clinicopathologic case report of inflammatory pseudotumors involving the conjunctiva and lung.** *Jpn J Ophthalmol* 2004, **48**:573-577.
87. Hosler GA, Steinberg DM, Sheth S, Hamper UM, Erozan YS, Ali SZ: **Inflammatory pseudotumor: a diagnostic dilemma in cytopathology.** *Diagn Cytopathol* 2004, **31**:267-270.
88. Alam M, Morehead RS, Weinstein MH: **Dermatomyositis as a presentation of pulmonary inflammatory pseudotumor (myofibroblastic tumor).** *Chest* 2000, **117**:1793-1795.
89. Tuncozgun B, Ustunsoy H, Bakir K, Ucak R, Elbeyli L: **Inflammatory pseudotumor of the lung.** *Thorac Cardiovasc Surg* 2000, **48**:112-113.
90. Uetsuji S, Nakagawa A, Kwon AH, Komada H, Imamura A, Kamiyama Y: **Inflammatory pseudotumor of the liver: report of a case and review of the literature.** *Surg Today* 1996, **26**:517-521.
91. Sato Y, Harada K, Nakanuma Y: **Hepatic inflammatory pseudotumor related to autoimmune pancreatitis.** *Histopathology* 2004, **45**:418-419.
92. Zen Y, Harada K, Sasaki M, Sato Y, Tsuneyama K, Haratake J, Kurumaya H, Katayanagi K, Masuda S, Niwa H, Morimoto H, Miwa A, Uchiyama A, Portmann BC, Nakanuma Y: **IgG4-related sclerosing cholangitis with and without hepatic inflammatory pseudotumor, and sclerosing pancreatitis-associated sclerosing cholangitis: do they belong to a spectrum of sclerosing pancreatitis?** *Am J Surg Pathol* 2004, **28**:1193-1203.
93. Spivach A, Turoldo A, Pistan V, Colautti I, Zanonati F: **Inflammatory pseudotumor of the liver: case report and review of the literature.** *Chir Ital* 2005, **57**:229-237.
94. Zen Y, Kasahara Y, Horita K, Miyayama S, Miura S, Kitagawa S, Nakanuma Y: **Inflammatory pseudotumor of the breast in a patient with a high serum IgG4 level: histologic similarity to sclerosing pancreatitis.** *Am J Surg Pathol* 2005, **29**:275-278.
95. Toosi MN, Heathcote J: **Pancreatic pseudotumor with sclerosing pancreato-cholangitis: is this a systemic disease?** *Am J Gastroenterol* 2004, **99**:377-382.
96. Esposito I, Bergmann F, Penzel R, di Mola FF, Shrikhande S, Buchler MW, Friess H, Otto HF: **Oligoclonal T-cell populations in an inflammatory pseudotumor of the pancreas possibly related to autoimmune pancreatitis: an immunohistochemical and molecular analysis.** *Virchows Arch* 2004, **444**:119-126.
97. Chutaputti A, Burrell MI, Boyer JL: **Pseudotumor of the pancreas associated with retroperitoneal fibrosis: a dramatic response to corticosteroid therapy.** *Am J Gastroenterol* 1995, **90**:1155-1158.
98. Zhao MF, Tian Y, Guo KJ, Ma ZG, Liao HH: **Common bile duct obstruction due to fibrous pseudotumor of pancreas associated with retroperitoneal fibrosis: a case report.** *World J Gastroenterol* 2004, **10**:3078-3079.
99. Wiesner W, Kocher T, Beglinger C, Harder F, Steinbrich W: **Pseudotumor of the pancreatic head associated with idiopathic retroperitoneal fibrosis.** *Dig Surg* 2001, **18**:418-421.
100. Van Hoe L, Oyen R, Gryspeerdt S, Baert AL, Bobbaers H, Baert L: **Case report: pseudotumoral pelvic retroperitoneal fibrosis associated with orbital fibrosis.** *Br J Radiol* 1995, **68**:421-423.
101. Kondo T, Onitsuka S, Kobayashi H, Ryoji O, Toma H: **A case of retroperitoneal pseudotumor (xanthogranuloma).** *Hinyokika Kiyo* 1998, **44**:21-24.
102. Ruiz-Cabello JM, Martinez Salmeron JF, Perez MJ, Salinas C, Rodrigo MM: **Inflammatory mesenteric pseudotumor.** *Rev Esp Enferm Apar Dig* 1988, **73**:311-314.
103. Sakurai H, Hasegawa T, Watanabe S, Suzuki K, Asamura H, Tsuchiya R: **Inflammatory myofibroblastic tumor of the lung.** *Eur J Cardiothorac Surg* 2004, **25**:155-159.
104. Berman M, Georghiou GP, Schonfeld T, Feinmesser M, Horev G, Vidne BA, Saute M: **Pulmonary inflammatory myofibroblastic tumor invading the left atrium.** *Ann Thorac Surg* 2003, **76**:601-603.
105. Jeon YK, Chang KH, Suh YL, Jung HW, Park SH: **Inflammatory myofibroblastic tumor of the central nervous system: clinicopathologic analysis of 10 cases.** *J Neuropathol Exp Neurol* 2005, **64**:254-259.
106. Ilvan S, Celik V, Paksoy M, Cetinaslan I, Calay Z: **Inflammatory myofibroblastic tumor (inflammatory pseudotumor) of the breast.** *APMIS* 2005, **113**:66-69.
107. Greiner C, Rickert CH, Mollmann FT, Rieger B, Semik M, Heindel W, Wassmann H: **Plasma cell granuloma involving the brain and the lung.** *Acta Neurochir (Wien)* 2003, **145**:1127-1131.
108. Urschel JD, Horan TA, Unruh HW: **Plasma cell granuloma of the lung.** *J Thorac Cardiovasc Surg* 1992, **104**:870-875.
109. Stewart TW Jr, Friberg TR: **Idiopathic retroperitoneal fibrosis with diffuse involvement: further evidence of systemic idiopathic fibrosis.** *South Med J* 1984, **77**:1185-1187.
110. Mitchinson MJ: **Systemic idiopathic fibrosis and systemic Weber-Christian disease.** *J Clin Pathol* 1965, **18**:645-649.

111. Morad N, Strongwater SL, Eypper S, Woda BA: **Idiopathic retroperitoneal and mediastinal fibrosis mimicking connective tissue disease.** *Am J Med* 1987, **82**:363-366.
112. Binder SC, Deterling RA Jr, Mahoney SA, Patterson JF, Wolfe HJ: **Systemic idiopathic fibrosis. Report of a case of the concomitant occurrence of retractile mesenteritis and retroperitoneal fibrosis.** *Am J Surg* 1972, **124**:422-430.
113. Hershkowitz M, Fogari R, Chandra M: **Idiopathic retroperitoneal fibrosis: implications for a systemic disorder.** *Clin Exp Rheumatol* 1983, **1**:157-160.
114. Nakamura Y, Kohzaki S, Suyama N, Yamaguchi T, Kohno S, Hayashi K: **Systemic idiopathic fibrosis with inflammatory pulmonary lesions.** *Br J Radiol* 1997, **70**:956-958.
115. Kuramochi S, Kawai T, Yakumaru K, Mikata A, Torikata C, Kasuga Y, Fujiwara T: **Multiple pulmonary hyalinizing granulomas associated with systemic idiopathic fibrosis.** *Acta Pathol Jpn* 1991, **41**:375-382.
116. Kastendieck H: **Xanthofibrogranulomatosis – a tumor-like lesion of the intestinal adipose tissue with a tendency towards generalization.** *Verh Dtsch Ges Pathol* 1978, **62**(501):501.
117. Miyachi S, Kobayashi T, Takahashi T, Saito K, Hashizume Y, Sugita K: **An intracranial mass lesion in systemic xanthogranulomatosis: case report.** *Neurosurgery* 1990, **27**:822-826.
118. Grunow N, Goertchen R: **Generalized retroperitoneal xanthofibrogranulomatosis with brain involvement.** *Pathologie* 1988, **9**:305-308.
119. Verswijvel G, Stragier J, Verhelle J, Roskams T, Oyen RH: **Bilateral xanthogranulomatous perinephritis without renal parenchymal involvement.** *Eur Radiol* 2000, **10**:900-902.
120. Arvis G, de Boisgisson P, Schrameck E: **Retroperitoneal xanthogranuloma. Apropos of 4 cases.** *J Urol Nephrol (Paris)* 1975, **81**:550-557.
121. Forster R, Ruschoff J, Kleinsorge F: **Retroperitoneal xanthofibrogranulomatosis.** *Rofo* 1989, **151**:688-691.
122. Dauch WA, Rossberg C, Luttgies J: **Xanthofibrogranulomatosis with meningocortical involvement.** *Zentralbl Allg Pathol* 1986, **132**:33-36.
123. Malhotra R, Porter RG, Selva D: **Adult orbital xanthogranuloma with periosteal infiltration.** *Br J Ophthalmol* 2003, **87**:120-121.
124. van der PR, Nieuwenhuis MG, Mourits MP: **Multifocal fibrosclerosis presenting as Grave's orbitopathy. Bilateral exophthalmos associated with retroperitoneal and sellar fibrosis.** *Graefes Arch Clin Exp Ophthalmol* 1999, **237**:256-258.
125. Schnitzler L, Verret JL, Caron C, Tuchsais E, Soret JY, Salaun Y: **[Multifocal fibrosclerosis (retroperitoneal, mediastinal, mesenteric and pelvic involvement) associated with vasculitis and revealed by a livedo: clinical, histopathological and ultrastructural study in a case] (author's translation).** *Ann Dermatol Venereol* 1978, **105**:943-956.
126. Brazier DJ, Sanders MD: **Multifocal fibrosclerosis associated with suprasellar and macular lesions.** *Br J Ophthalmol* 1983, **67**:292-296.
127. Tutuncu NB, Erbas T, Bayraktar M, Gedik O: **Multifocal idiopathic fibrosclerosis manifesting with Riedel's thyroiditis.** *Endocr Pract* 2000, **6**:447-449.
128. Laitt RD, Hubscher SG, Buckels JA, Darby S, Elias E: **Sclerosing cholangitis associated with multifocal fibrosis: a case report.** *Gut* 1992, **33**:1430-1432.
129. Manassero A, Cracco C, Terrone C, Rossetti SR: **Coexistence of orbital and retroperitoneal involvement in multifocal fibrosclerosis: case report.** *Arch Ital Urol Androl* 1998, **70**:11-14.
130. Richards AB, Shalka HW, Roberts FJ, Flint A: **Pseudotumor of the orbit and retroperitoneal fibrosis. A form of multifocal fibrosclerosis.** *Arch Ophthalmol* 1980, **98**:1617-1620.
131. Levine MR, Kaye L, Mair S, Bates J: **Multifocal fibrosclerosis. Report of a case of bilateral idiopathic sclerosing pseudotumor and retroperitoneal fibrosis.** *Arch Ophthalmol* 1993, **111**:841-843.
132. Meijer S, Hoitsma HF, Scholtmeijer R: **Idiopathic retroperitoneal fibrosis in multifocal fibrosclerosis.** *Eur Urol* 1976, **2**:258-260.
133. Nielson HK: **Multifocal idiopathic fibrosclerosis. Two cases with simultaneous occurrence of retroperitoneal fibrosis and Riedel's thyroiditis.** *Acta Med Scand* 1980, **208**:119-123.
134. Aylward GW, Sullivan TJ, Garner A, Moseley I, Wright JE: **Orbital involvement in multifocal fibrosclerosis.** *Br J Ophthalmol* 1995, **79**:246-249.
135. Bonnet C, Arnaud M, Bertin P, Treves R, Gotteron RD: **Idiopathic retroperitoneal fibrosis with systemic manifestations.** *J Rheumatol* 1994, **21**:360-362.
136. Hashimoto S, Fujii W, Takahashi T, Shiroshita K, Sakurai T, Ueda T, Kawata T: **Pulmonary hyalinizing granuloma with hydronephrosis.** *Intern Med* 2002, **41**:463-466.
137. Dent RG, Godden DJ, Stovin PG, Stark JE: **Pulmonary hyalinizing granuloma in association with retroperitoneal fibrosis.** *Thorax* 1983, **38**:955-956.
138. Dejaco C, Ferenci P, Schober E, Kaserer K, Fugger R, Novacek G, Gangl A: **Stenosis of the common bile duct due to Ormond's disease: case report and review of the literature.** *J Hepatol* 1999, **31**:156-159.
139. Kamisawa T, Matsukawa M, Ohkawa M: **Autoimmune pancreatitis associated with retroperitoneal fibrosis.** *JOP* 2005, **6**:260-263.
140. Pereira-Lima JC, Kromer MU, Adamek HE, Riemann JF: **Cholestatic jaundice due to Ormond's disease (primary retroperitoneal fibrosis).** *Hepatogastroenterology* 1996, **43**:992-994.
141. Cappell MS: **Obstructive jaundice due to retroperitoneal fibrosis involving the head of the pancreas.** *J Clin Gastroenterol* 1994, **18**:53-56.
142. Fruh D, Jaeger W, Kafer O: **Orbital involvement in retroperitoneal fibrosis (morbus Ormond).** *Mod Probl Ophthalmol* 1975, **14**(651-6):651-656.
143. Lenhard V, Bommer J, Andrassy K, Krampien B, Orth H, Ritz E: **Retro-orbital fibrosis in Ormond's disease (author's transl).** *Dtsch Med Wochenschr* 1974, **99**:2289-2286.
144. Schonder AA, Clift RC, Brophy JW, Dane LW: **Bilateral recurrent orbital inflammation associated with retroperitoneal fibrosclerosis.** *Br J Ophthalmol* 1985, **69**:783-787.
145. Reittner P, Riepl T, Goritschnig T, Preidler KW, Koele W, Szolar DH: **Bilateral orbital pseudotumour due to Ormond's disease: MR imaging and CT findings.** *Neuroradiology* 2002, **44**:272-274.
146. Kruit WH, den Ottolander GJ: **Riedel's thyroiditis in a patient with retroperitoneal fibrosis.** *Neth J Med* 1991, **39**:17-19.
147. Miro I, Bakir R, Chanu B, Brocheriou C, Brenot F, Rouffy J: **Riedel's thyroiditis and retroperitoneal fibrosis. Apropos of a case of multiple fibrosing disease.** *Ann Med Interne (Paris)* 1984, **135**:212-216.
148. Rao CR, Ferguson GC, Kyle VN: **Retroperitoneal fibrosis associated with Riedel's struma.** *Can Med Assoc J* 1973, **108**:1019-1021.
149. Meyer S, Hausman R: **Occlusive phlebitis in multifocal fibrosclerosis.** *Am J Clin Pathol* 1976, **65**:274-283.
150. Wich M, Steegmuller KW, Junginger T, Teifke A: **Riedel's thyroiditis and idiopathic multifocal fibrosclerosis. A case report.** *Chirurg* 1991, **62**:211-213.
151. Kitagawa S, Zen Y, Harada K, Sasaki M, Sato Y, Minato H, Watanabe K, Kurumaya H, Katayanagi K, Masuda S, Niwa H, Tsuneyama K, Saito K, Haratake J, Takagawa K, Nakanuma Y: **Abundant IgG4-Positive plasma cell infiltration characterizes chronic sclerosing sialadenitis (Kuttner's Tumor).** *Am J Surg Pathol* 2005, **29**:783-791.
152. Leger L, Roberti A, Deloche dN, Lemaigre G: **Mesenteric panniculitis, a variety of retroperitoneal fibrosclerosis.** *Presse Med* 1967, **75**:75-79.
153. Godquin B, Saout R, Loupias P, Garipuy A, Blanchard J: **Inflammatory and necrotic pseudotumor of the mesentery. Classification of mesenteric panniculitis.** *J Chir (Paris)* 1972, **104**:167-175.
154. Paraf A, Menager C, Texier J: **Mesenteric panniculitis, retroperitoneal lipodystrophy and pancreatic diseases. Apropos of a case.** *Presse Med* 1968, **76**:2263-2265.
155. Decker GA, Gaylis H: **Mesenteric panniculitis simulating an abdominal aortic aneurysm.** *S Afr Med J* 1972, **46**:750.
156. Herr W, Lohse AW, Spahn TW, Dienes HP, Trautmann F, Meyer zum Buschenfelde KH, Marker-Hermann E: **Nodular nonsuppurative panniculitis in association with primary biliary cirrhosis and Hashimoto's thyroiditis.** *Z Rheumatol* 1996, **55**:122-126.
157. Proenca NG, Frucchi H: **Weber-Christian febrile recurrent nodular nonsuppurative panniculitis and panniculitis caused by pancreopathy: differential diagnosis and enzymatic mechanisms.** *Rev Paul Med* 1978, **91**:82-83.
158. Motoo Y, Minamoto T, Watanabe H, Sakai J, Okai T, Sawabu N: **Sclerosing pancreatitis showing rapidly progressive changes with recurrent mass formation.** *Int J Pancreatol* 1997, **21**:85-90.

159. Sarles H, Sarles J, Muratore R, Guien C: **Chronic inflammatory sclerosis of the pancreas – an autonomous pancreatic disease?** *Am J Dig Dis* 1961, **6**:688-698.
160. Kawaguchi K, Koike M, Tsuruta K, Okamoto A, Tabata I, Fujita N: **Lymphoplasmacytic sclerosing pancreatitis with cholangitis: a variant of primary sclerosing cholangitis extensively involving pancreas.** *Hum Pathol* 1991, **22**:387-395.
161. Notohara K, Burgart LJ, Yadav D, Chari S, Smyrk TC: **Idiopathic chronic pancreatitis with periductal lymphoplasmacytic infiltration: clinicopathologic features of 35 cases.** *Am J Surg Pathol* 2003, **27**:1119-1127.
162. Ito T, Nakano I, Koyanagi S, Miyahara T, Migita Y, Ogoshi K, Sakai H, Matsunaga S, Yasuda O, Sumii T, Nawata H: **Autoimmune pancreatitis as a new clinical entity. Three cases of autoimmune pancreatitis with effective steroid therapy.** *Dig Dis Sci* 1997, **42**:1458-1468.
163. Erkelens GW, Vleggaar FP, Lesterhuis W, van Buuren HR, van der Werf SD: **Sclerosing pancreato-cholangitis responsive to steroid therapy.** *Lancet* 1999, **354**:43-44.
164. Fukui T, Okazaki K, Yoshizawa H, Ohashi S, Tamaki H, Kawasaki K, Matsuura M, Asada M, Nakase H, Nakashima Y, Nishio A, Chiba T: **A case of autoimmune pancreatitis associated with sclerosing cholangitis, retroperitoneal fibrosis and Sjogren's syndrome.** *Pancreatol* 2005, **5**:86-91.
165. Fukukura Y, Fujiyoshi F, Nakamura F, Hamada H, Nakajo M: **Autoimmune pancreatitis associated with idiopathic retroperitoneal fibrosis.** *AJR Am J Roentgenol* 2003, **181**:993-995.
166. Ichimura T, Kondo S, Ambo Y, Hirano S, Ohmi M, Okushiba S, Morikawa T, Shimizu M, Katoh H: **Primary sclerosing cholangitis associated with autoimmune pancreatitis.** *Hepatogastroenterology* 2002, **49**:1221-1224.
167. Nishino T, Toki F, Oyama H, Oi I, Kobayashi M, Takasaki K, Shiratori K: **Biliary tract involvement in autoimmune pancreatitis.** *Pancreas* 2005, **30**:76-82.
168. Kamisawa T: **IgG4-positive plasma cells specifically infiltrate various organs in autoimmune pancreatitis.** *Pancreas* 2004, **29**:167-168.
169. Kamisawa T, Funata N, Hayashi Y, Eishi Y, Koike M, Tsuruta K, Okamoto A, Egawa N, Nakajima H: **A new clinicopathological entity of IgG4-related autoimmune disease.** *J Gastroenterol* 2003, **38**:982-984.
170. Uchida K, Okazaki K, Konishi Y, Ohana M, Takakuwa H, Hagiuro K, Chiba T: **Clinical analysis of autoimmune-related pancreatitis.** *Am J Gastroenterol* 2000, **95**:2788-2794.
171. Pickartz T, Pickartz H, Lochs H, Ockenga J: **Overlap syndrome of autoimmune pancreatitis and cholangitis associated with secondary Sjogren's syndrome.** *Eur J Gastroenterol Hepatol* 2004, **16**:1295-1299.
172. Shinji A, Sano K, Hamano H, Unno H, Fukushima M, Nakamura N, Akamatsu T, Kawa S, Kiyosawa K: **Autoimmune pancreatitis is closely associated with gastric ulcer presenting with abundant IgG4-bearing plasma cell infiltration.** *Gastrointest Endosc* 2004, **59**:506-511.
173. Taniguchi T, Ko M, Seko S, Nishida O, Inoue F, Kobayashi H, Saiga T, Okamoto M, Fukuse T: **Interstitial pneumonia associated with autoimmune pancreatitis.** *Gut* 2004, **53**:770-771.
174. Arai K, Kawamura O, Naruse I, Tsunekawa K, Hayashi A, Yonezu M, Oya N, Takagi H, Mori M, Kon Y: **A case of chronic pancreatitis with diffuse irregular narrowing of the pancreatic duct complicated by Sjogren's syndrome and interstitial pneumonia.** *Nippon Shokakibyo Gakkai Zasshi* 2001, **98**:847-852.
175. Phillips RH, Carr RA, Preston R, Pereira SP, Wilkinson ML, O'Donnell PJ, Thompson RP: **Sclerosing mesenteritis involving the pancreas: two cases of a rare cause of abdominal mass mimicking malignancy.** *Eur J Gastroenterol Hepatol* 1999, **11**:1323-1329.
176. Harada M, Hashimoto O, Kumemura H, Taniguchi E, Shiratsuchi M, Harada R, Sakamoto M, Yoshida H, Fukuda T, Sakisaka S, Sata M: **Bronchiolitis obliterans organizing pneumonia in a patient with primary biliary cirrhosis and rheumatoid arthritis treated with prednisolone.** *Hepatol Res* 2002, **23**:301.
177. Takahashi K, Sakamoto N, Okada M, Tamechika Y, Ishibashi H: **[Interstitial pneumonia observed during acute exacerbation of autoimmune hepatitis].** *Nippon Shokakibyo Gakkai Zasshi* 2000, **97**:719-722.
178. Yousem SA, Hochholzer L: **Pulmonary hyalinizing granuloma.** *Am J Clin Pathol* 1987, **87**:1-6.
179. Gossot D, Fromont G, Galetta D, Debrosse D, Grunenwald D: **Pulmonary hyalinizing granuloma with mediastinal fibrosis: a rare cause of dysphagia.** *Ann Chir* 2003, **128**:622-625.
180. Burrig KF, Kastendieck H: **Ultrastructural observations on the histogenesis of localized fibrous tumours of the pleura (benign mesothelioma).** *Virchows Arch A Pathol Anat Histopathol* 1984, **403**:413-424.
181. Burrig KF, Kastendieck H, Husselmann H: **Localized fibrous pleural tumor (benign mesothelioma). Clinico-pathological study of 24 cases for classification, morphogenesis and prognosis.** *Pathologe* 1983, **4**:120-129.
182. Lee HY, Chuah KL, Tan PH: **Test and teach. Number fifty-three. Diagnosis: Calcifying fibrous pseudotumour.** *Pathology* 2003, **35**:166-169.
183. Dargent JL, Delplace J, Roufosse C, Laget JP, Lespagnard L: **Development of a calcifying fibrous pseudotumour within a lesion of Castleman disease, hyaline-vascular subtype.** *J Clin Pathol* 1999, **52**:547-549.
184. Zamecnik M, Boudova L, Sulc M, Michal M: **Location of calcifying fibrous pseudotumour: peritoneal predominance.** *Histopathology* 2005, **46**:346.
185. Weynand B, Draguet AP, Bernard P, Marbaix E, Galant C: **Calcifying fibrous pseudotumour: first case report in the peritoneum with immunostaining for CD34.** *Histopathology* 1999, **34**:86-87.
186. Peachell M, Mayo J, Kalloger S, Flint J, English J: **Calcifying fibrous pseudotumour of the lung.** *Thorax* 2003, **58**:1018-1019.
187. Tsuneyama K, Saito K, Ruebner BH, Konishi I, Nakanuma Y, Gershwin ME: **Immunological similarities between primary sclerosing cholangitis and chronic sclerosing sialadenitis: report of the overlapping of these two autoimmune diseases.** *Dig Dis Sci* 2000, **45**:366-372.
188. Sjogren I, Wengle B, Korsgren M: **Primary sclerosing cholangitis associated with fibrosis of the submandibular glands and the pancreas.** *Acta Med Scand* 1979, **205**:139-141.
189. Monteil RA, Saint-Paul MC, Hofman P, Jehl-Pietri C, Michiels JF, Raspaldo H: **Oral inflammatory pseudotumour: immunohistochemical investigation of a case involving the submandibular gland and review of the literature.** *Oral Oncol* 1997, **33**:215-219.
190. Zamboni G, Luttgies J, Capelli P, Frulloni L, Cavallini G, Pederzoli P, Leins A, Longnecker D, Kloppel G: **Histopathological features of diagnostic and clinical relevance in autoimmune pancreatitis: a study on 53 resection specimens and 9 biopsy specimens.** *Virchows Arch* 2004, **445**:552-563.
191. Imasaki T, Yoshii A, Tanaka S, Ogura T, Ishikawa A, Takahashi T: **Polymyositis and Sjogren's syndrome associated with bronchiolitis obliterans organizing pneumonia.** *Intern Med* 1996, **35**:231-235.
192. Doi M, Uji Y: **A case of uveitis associated with idiopathic retroperitoneal fibrosis.** *Am J Ophthalmol* 1994, **117**:358-362.
193. Armigliato M, Paolini R, Bianchini E, Monesi G, Zamboni S, D'Andrea E: **Hashimoto's thyroiditis and Graves' disease associated with retroperitoneal fibrosis.** *Thyroid* 2002, **12**:829-831.
194. Hanley PC, Shub C, Lie JT: **Constrictive pericarditis associated with combined idiopathic retroperitoneal and mediastinal fibrosis.** *Mayo Clin Proc* 1984, **59**:300-304.
195. van Bommel EF, Bouvy ND, Liem E, Boeve ER, Weimar W: **Coexistent idiopathic retroperitoneal and mediastinal fibrosis presenting with portal hypertension.** *Neth J Med* 1994, **44**:174-177.
196. Morgan AD, Loughridge LW, Calne RY: **Combined mediastinal and retroperitoneal fibrosis.** *Lancet* 1966, **1**:67-70.
197. Mitchinson MJ, Wight DG, Arno J, Milstein BB: **Chronic coronary periarteritis in two patients with chronic periaortitis.** *J Clin Pathol* 1984, **37**:32-36.
198. Keith DS, Larson TS: **Idiopathic retroperitoneal fibrosis.** *J Am Soc Nephrol* 1993, **3**:1748-1752.
199. Debrand-Passard A, Wilhelm H: **Ormond's disease or aortic aneurysm? Case reports.** *Int Urol Nephrol* 1996, **28**:295-304.
200. Vaideeswar P, Shenoy AS, Sivaraman A, Deshpande JR, Pandit AA: **Idiopathic retroperitoneal fibrosis: a report of 3 cases.** *J Postgrad Med* 1993, **39**:95-98.
201. Remedios D, Coppen M, Bradbeer J, Theodossi A: **Chronic peri-aortitis presenting as common bile duct obstruction.** *Gut* 1991, **32**:713-714.
202. Zdrojewski Z: **Retroperitoneal fibrosis and chronic peri-aortitis – new hypothesis.** *Pol Merkuriusz Lek* 1998, **4**:50-53.

203. Turo AJ, Torres LJ, Peiro MF, Cabrera Cabrera JA: **Obstructive uropathy caused by retroperitoneal fibrosis secondary to an aneurysm of the abdominal aorta.** *Actas Urol Esp* 2000, **24**:764-766.
204. Breems DA, Haye H, van der MJ: **The role of advanced atherosclerosis in idiopathic retroperitoneal fibrosis. Analysis of nine cases.** *Neth J Med* 2000, **56**:38-44.
205. Serra RM, Engle JE, Jones RE, Schoolwerth AC: **Perianeurysmal retroperitoneal fibrosis. An unusual cause of renal failure.** *Am J Med* 1980, **68**:149-153.
206. Hautekeete ML, Babany G, Marcellin P, Gayno S, Palazzo E, Erlinger S, Benhamou JP: **Retroperitoneal fibrosis after surgery for aortic aneurysm in a patient with periarteritis nodosa: successful treatment with corticosteroids.** *J Intern Med* 1990, **228**:533-536.
207. Izzedine H, Servais A, Launay-Vacher V, Deray G: **Retroperitoneal fibrosis due to Wegener's granulomatosis: a misdiagnosis as tuberculosis.** *Am J Med* 2002, **113**:164-166.
208. Regan F, Tran T, Crofton ME: **Case report: idiopathic retroperitoneal fibrosis: an unusual cause of an ovarian mass.** *Br J Radiol* 1993, **66**:558-560.
209. Tsai TC, Chang PY, Chen BF, Huang FY, Shih SL: **Retroperitoneal fibrosis and juvenile rheumatoid arthritis.** *Pediatr Nephrol* 1996, **10**:208-209.
210. Stey C, Truninger K, Marti D, Vogt P, Medici TC: **Bronchiolitis obliterans organizing pneumonia associated with polymyalgia rheumatica.** *Eur Respir J* 1999, **13**:926-929.
211. Bezza A, Maghraoui AE, Ghadouane M, Tabache F, Abouzahir A, Abbar M, Ghafir D, Ohayon V, Archane MI: **Idiopathic retroperitoneal fibrosis and ankylosing spondylitis. A new case report.** *Joint Bone Spine* 2002, **69**:502-505.
212. Ewald EA, Gikas PV, Castor CW: **Periarticular fibrosis associated with idiopathic retroperitoneal fibrosis.** *J Rheumatol* 1988, **15**:1443-1446.
213. Sozay S, Bayramoglu M, Karatas M, Ozker R: **Diffuse idiopathic skeletal hyperostosis in a patient with idiopathic retroperitoneal fibrosis: a case report.** *Rheumatol Int* 2002, **22**:249-252.
214. Knoell KA, Hook M, Grice DP, Hendrix JD Jr: **Dermatomyositis associated with bronchiolitis obliterans organizing pneumonia (BOOP).** *J Am Acad Dermatol* 1999, **40**:328-330.
215. Fata F, Rathore R, Schiff C, Herzlich BC: **Bronchiolitis obliterans organizing pneumonia as the first manifestation of polymyositis.** *South Med J* 1997, **90**:227-230.
216. Mansell MA, Watts RV: **Retroperitoneal fibrosis and scleroderma.** *Postgrad Med J* 1980, **56**:730-733.
217. Okada H, Takahira S, Sugahara S, Nakamoto H, Suzuki H: **Retroperitoneal fibrosis and systemic lupus erythematosus.** *Nephrol Dial Transplant* 1999, **14**:1300-1302.
218. Wallach PM, Flannery MT, Adelman HM, PowSang J, Saba H, Altus P, Espinoza LR: **Retroperitoneal fibrosis accompanying immune thrombocytopenia.** *Am J Hematol* 1991, **37**:204-205.
219. Nakamura A, Funatomi H, Katagiri A, Katayose K, Kitamura K, Seki T, Yamamura F, Aoyagi Y, Nishida H, Mitamura K: **A case of autoimmune pancreatitis complicated with immune thrombocytopenia during maintenance therapy with prednisolone.** *Dig Dis Sci* 2003, **48**:1968-1971.
220. Iwami S, Ryu T, Kasai S, Tokuda H, Saitoh T: **Idiopathic interstitial pneumonia with autoimmune hemolytic anemia.** *Nippon Naika Gakkai Zasshi* 2003, **92**:1079-1081.
221. Pineau BC, Pattee LP, McGuire S, Sekar A, Scully LJ: **Unusual presentation of primary sclerosing cholangitis.** *Can J Gastroenterol* 1997, **11**:45-48.
222. Briffod M, Berlie J, Clavel B, Hebert H: **Retroperitoneal malignant xanthogranuloma (author's transl).** *Sem Hop* 1982, **58**:113-119.
223. de Sa J, Pimentel J, Carvalho M, Evangelista P, Martins P: **Spinal cord compression secondary to idiopathic retroperitoneal fibrosis.** *Neurosurgery* 1990, **26**:678-681.
224. Sevenet F, Capron-Chivrac D, Delcenserie R, Lelarge C, Delamarre J, Capron JP: **Idiopathic retroperitoneal fibrosis and primary biliary cirrhosis. A new association?** *Arch Intern Med* 1985, **145**:2124-2125.
225. Rozynek M: **Mesenteric lipodystrophy as a variant of Ormond's disease.** *Patol Pol* 1975, **26**:525-528.
226. Verit A, Yeni E, Unal D, Kafali H, Ozturk A, Ozardali I: **Idiopathic retroperitoneal fibrosis mimicking a pelvic tumor: a case of pericystitis plastica.** *Yonsei Med J* 2003, **44**:548-550.
227. Hacıyanlı M, Erkan N, Elverdi B, Avci G, Fuzun M, Dicle O: **Retroperitoneal fibrosis mimicking a rectal tumor: report of a case.** *Dis Colon Rectum* 1998, **41**:664-666.
228. Yamada H, Komatsu R, Nagae H, Fujioka Y, Fujita M: **Idiopathic retroperitoneal fibrosis with duodenal obstruction successfully treated with corticosteroids.** *Intern Med* 1998, **37**:592-598.
229. Jun BM, Lee EY, Yoon YJ, Kim EK, Ahn MS, Lee CK, Cho YS, Yoo B, Moon HB: **Retroperitoneal fibrosis with duodenal stenosis.** *J Korean Med Sci* 2001, **16**:371-374.
230. Realini S, Reiner M, Bernasconi S, Pedrinis E: **Retroperitoneal fibrosis and portal hypertension.** *Schweiz Med Wochenschr* 1993, **123**:26-28.
231. Zabetakis PM, Novich RK, Matarese RA, Michelis MF: **Idiopathic retroperitoneal fibrosis: a systemic connective tissue disease?** *J Urol* 1979, **122**:100-102.
232. Moroni G, Farricciotti A, Cappelletti M, Ponticelli C: **Retroperitoneal fibrosis and membranous nephropathy. Improvement of both diseases after treatment with steroids and immunosuppressive agents.** *Nephrol Dial Transplant* 1999, **14**:1303-1305.
233. Uchiyama-Tanaka Y, Mori Y, Kimura T, Sonomura K, Umemura S, Kishimoto N, Nose A, Tokoro T, Kijima Y, Yamahara H, Nagata T, Masaki H, Umeda Y, Okazaki K, Iwasaka T: **Acute tubulointerstitial nephritis associated with autoimmune-related pancreatitis.** *Am J Kidney Dis* 2004, **43**:e18-e25.
234. Nistal M, Paniagua R, Torres A, Hidalgo L, Regadera J: **Idiopathic peritesticular fibrosis associated with retroperitoneal fibrosis.** *Eur Urol* 1986, **12**:64-68.

### Pre-publication history

The pre-publication history for this paper can be accessed here:

<http://www.biomedcentral.com/1741-7015/4/23/prepub>

Publish with **BioMed Central** and every scientist can read your work free of charge

"BioMed Central will be the most significant development for disseminating the results of biomedical research in our lifetime."

Sir Paul Nurse, Cancer Research UK

Your research papers will be:

- available free of charge to the entire biomedical community
- peer reviewed and published immediately upon acceptance
- cited in PubMed and archived on PubMed Central
- yours — you keep the copyright

Submit your manuscript here:

[http://www.biomedcentral.com/info/publishing\\_adv.asp](http://www.biomedcentral.com/info/publishing_adv.asp)

