

Hypertrophic pachymeningitis: significance of myeloperoxidase anti-neutrophil cytoplasmic antibody

Akiko Yokoseki,¹ Etsuji Saji,¹ Musashi Arakawa,¹ Takayuki Kosaka,² Mariko Hokari,¹ Yasuko Toyoshima,² Kouichirou Okamoto,³ Shigeki Takeda,⁴ Kazuhiro Sanpei,⁵ Hirotoshi Kikuchi,⁶ Shunsei Hirohata,⁷ Kouhei Akazawa,⁸ Akiyoshi Kakita,² Hitoshi Takahashi,² Masatoyo Nishizawa¹ and Izumi Kawachi¹

1 Department of Neurology, Brain Research Institute, Niigata University, Niigata, Japan

2 Department of Pathology, Brain Research Institute, Niigata University, Niigata, Japan

3 Department of Neurosurgery, Brain Research Institute, Niigata University, Niigata, Japan

4 Department of Pathology, Niigata Neurosurgical Hospital and Brain Research Centre, Niigata, Japan

5 Department of Neurology, Sado General Hospital, Niigata, Japan

6 Department of Internal Medicine, Teikyo University School of Medicine, Tokyo, Japan

7 Department of Rheumatology and Infectious diseases, Kitasato University School of Medicine, Kanagawa, Japan

8 Department of Medical Informatics, Niigata University, Niigata, Japan

Correspondence to: Dr. I. Kawachi,
Department of Neurology,
Brain Research Institute,
Niigata University,
1-757 Asahimachi,
Chuo-ku,
Niigata 951-8585,
Japan
E-mail: ikawachi@bri.niigata-u.ac.jp

The aim of this study was to elucidate the characteristics, pathogenesis and treatment strategy of hypertrophic pachymeningitis that is associated with myeloperoxidase anti-neutrophil cytoplasmic antibody (ANCA). We retrospectively investigated clinical, radiological, immunological and pathological profiles of 36 patients with immune-mediated or idiopathic hypertrophic pachymeningitis, including 17 patients with myeloperoxidase-ANCA, four patients with proteinase 3-ANCA, six patients with other immune-mediated disorders, and nine patients with 'idiopathic' variety. Myeloperoxidase-ANCA-positive hypertrophic pachymeningitis was characterized by: (i) an elderly female predominance; (ii) 82% of patients diagnosed with granulomatosis with polyangiitis (previously known as Wegener's granulomatosis) according to Watts' algorithm; (iii) a high frequency of patients with lesions limited to the dura mater and upper airways, developing headaches, chronic sinusitis, otitis media or mastoiditis; (iv) a low frequency of patients with the 'classical or generalized form' of granulomatosis with polyangiitis involving the entire upper and lower airways and kidney, or progressing to generalized disease, in contrast to proteinase 3-ANCA-positive hypertrophic pachymeningitis; (v) less severe neurological damage according to the modified Rankin Scale and low disease activity according to the Birmingham Vasculitis Activity Score compared with proteinase 3-ANCA-positive hypertrophic

pachymeningitis; (vi) increased levels of CXCL10, CXCL8 and interleukin 6 in cerebrospinal fluids, and increased numbers of T cells, neutrophils, eosinophils, plasma cells and monocytes/macrophages in autopsied or biopsied dura mater with pachymeningitis, suggesting T_H1-predominant granulomatous lesions in hypertrophic pachymeningitis, as previously reported in pulmonary or renal lesions of granulomatosis with polyangiitis; and (vii) greater efficacy of combination therapy with prednisolone and cyclophosphamide compared with monotherapy with prednisolone. Proteinase 3-ANCA may be considered a marker for more severe neurological damage, higher disease activity and a higher frequency of the generalized form compared with myeloperoxidase-ANCA-positive hypertrophic pachymeningitis. However, categorization into 'granulomatosis with polyangiitis' according to Watts' algorithm and immunological or pathological features were common in both proteinase 3- and myeloperoxidase-ANCA-positive hypertrophic pachymeningitis. These data indicate that most patients with myeloperoxidase-ANCA-positive hypertrophic pachymeningitis should be categorized as having the central nervous system-limited form of ANCA-associated vasculitis, consistent with the concept of ophthalmic-, pulmonary- or renal-limited vasculitis.

Keywords: hypertrophic pachymeningitis; MPO-ANCA; PR3-ANCA; granulomatosis with polyangiitis; limited form

Abbreviations: ANCA = anti-neutrophil cytoplasmic antibody; BVAS = Birmingham Vasculitis Activity Score; EULAR = European League Against Rheumatism; IL = interleukin; MPO = myeloperoxidase; PR3 = proteinase 3

Introduction

Hypertrophic pachymeningitis is a rare clinical disorder involving localized or diffuse thickening of the dura mater. Most patients with hypertrophic pachymeningitis have chronic headaches with or without neurological manifestations including cranial neuropathies, pituitary dysfunction, cerebellar ataxia, seizures, myelopathy and neuro-ophthalmic complications that include papilloedema, optic neuropathy, visual field loss and even blindness (Kupersmith *et al.*, 2004). Hypertrophic pachymeningitis is thought to be associated with several granulomatous disorders: (i) autoimmune diseases such as rheumatoid arthritis, sarcoidosis, and IgG4-related disorder; (ii) infections such as tuberculosis, syphilis, and bacterial or fungus diseases; (iii) neoplasms such as lymphoma; and (iv) the 'idiopathic' variety when evaluation fails to reveal a cause (Kupersmith *et al.*, 2004; Bruggemann *et al.*, 2010). Single case reports have described that some patients with hypertrophic pachymeningitis may have myeloperoxidase anti-neutrophil cytoplasmic antibody (MPO-ANCA)-positive status (Sugiyama *et al.*, 1999; Nagashima *et al.*, 2000; Takuma *et al.*, 2001; Akahoshi *et al.*, 2004; Jacobi *et al.*, 2005; Nakamura *et al.*, 2007; Liewluck *et al.*, 2008). However, the clinical characteristics and specific treatments for MPO-ANCA-positive hypertrophic pachymeningitis remain elusive, and its position among ANCA-related disorders including granulomatosis with polyangiitis (previously known as Wegener's granulomatosis), microscopic polyangiitis, and eosinophilic granulomatosis with polyangiitis (previously known as Churg-Strauss syndrome) (Jennette *et al.*, 2013) is debatable (Nagashima *et al.*, 2000; Akahoshi *et al.*, 2004). Therefore, we investigated clinical and laboratory evaluations including radiological, immunological and pathological findings of 36 patients with immune-mediated or idiopathic hypertrophic pachymeningitis, including 17 patients with MPO-ANCA-positive hypertrophic pachymeningitis. Our results emphasize that MPO-ANCA-positive hypertrophic pachymeningitis should be categorized, diagnosed and treated as a CNS-limited form of ANCA-associated vasculitis.

Materials and methods

Patients and diagnostic criteria

We retrospectively reviewed the medical records of 36 Japanese patients with immune-mediated or idiopathic hypertrophic pachymeningitis (19 females, 17 males) between 1996 and 2012 at Niigata University Hospital, which has served as a centre (tertiary hospital) in Niigata prefecture. Entry criteria of immune-mediated hypertrophic pachymeningitis were defined as follow: (i) to make a diagnosis of hypertrophic pachymeningitis, all patients had thickening and abnormal enhancement of the dura mater as demonstrated on gadolinium MRI T₁ sequences performed before lumbar punctures; (ii) to make a diagnosis of immune-mediated disorders, all patients had either seropositivity for MPO-ANCA or proteinase 3 (PR3)-ANCA, or other immune-mediated disorders, including sarcoidosis; (iii) there was no better explanation for infection, including syphilis or tuberculosis, malignant tumours, malignant lymphoma, meningioma, intracranial hypotension, or those using certain drugs, including hydralazine, propylthiouracil, cocaine and allopurinol; and (iv) lesions localized within the cavernous sinus or of orbital pseudotumor were excluded. Moreover, when evaluation failed to reveal seropositivity for ANCA, or signs and symptoms of other immune-mediated disorders, the 'idiopathic' variety was assigned and included in this study carried out previously (Kupersmith *et al.*, 2004). Consequently, we categorized the immune-mediated or idiopathic hypertrophic pachymeningitis into four subtypes: MPO-ANCA-positive hypertrophic pachymeningitis; PR3-ANCA-positive hypertrophic pachymeningitis; hypertrophic pachymeningitis with other immune-mediated disorders; or idiopathic hypertrophic pachymeningitis. Patients with MPO-ANCA-positive hypertrophic pachymeningitis were diagnosed based on seropositivity for MPO-ANCA and were subsequently classified as granulomatosis with polyangiitis, microscopic polyangiitis or eosinophilic granulomatosis with polyangiitis according to 2012 Chapel Hill Consensus Conference definitions (Jennette *et al.*, 2013) and Watts' algorithm (Watts *et al.*, 2007). Patients with rheumatoid arthritis, sarcoidosis or IgG4-related disorder were diagnosed based on the 2010 American College Rheumatology/European League Against Rheumatism (EULAR) Classification Criteria for rheumatoid arthritis (Neogi *et al.*, 2010), the recommendations of an expert panel for sarcoidosis

(Baughman *et al.*, 2003), or the 2011 Comprehensive Diagnostic Criteria for IgG4-related disease (Umehara *et al.*, 2012). Clinical evaluations during follow-up included neurological examination, standard blood profile and MRI assessments. Activity was measured using the Birmingham Vasculitis Activity Score (BVAS) (Luqmani *et al.*, 1997). Outcomes of interest included the modified Rankin Scale (van Swieten *et al.*, 1988), treatment resistance, time to relapse and death. The clinical outcome of the neurological status was measured with the modified Rankin Scale. Relapse was defined as the deterioration of radiological findings, the development of clinical symptoms including headaches or cranial neuropathies, or the reactivation of vasculitis in any organ system, according to the EULAR recommendations (Hellmich *et al.*, 2007). The definition of disease relapse required an initial response to treatment, and patients with treatment-resistant disease were not included in the disease relapse group. The present study was approved by the institutional review board of the Niigata University School of Medicine, Niigata, Japan.

Radiological, immunological and pathological examinations

MRI was performed using a 1.5 T scanner (GE Medical Systems), and 5-mm thick slices were obtained.

Serological studies included antinuclear antibodies, rheumatoid factor, MPO-ANCA, PR3-ANCA and angiotensin converting enzyme were performed. ANCA tests were done by antigen-specific ELISA and/or indirect immunofluorescence microscopy (Watts *et al.*, 2007; Ito-Ihara *et al.*, 2008; Mukhtyar *et al.*, 2009; Lionaki *et al.*, 2012). ANCA testing was performed by ELISA, but the indirect immunofluorescence microscopy result alone was acceptable only if ELISA was unavailable or the diagnosis was made before 2000. Of 36 patients with immune-mediated or idiopathic hypertrophic pachymeningitis, ANCA testing was assessed by ELISA in 29, by indirect immunofluorescence microscopy in two, and by ELISA plus indirect immunofluorescence microscopy in five patients. Specifically, in 17 patients with MPO-ANCA-positive hypertrophic pachymeningitis, ANCA testing was assessed by ELISA in 11, indirect immunofluorescence microscopy in two, and ELISA plus indirect immunofluorescence microscopy in four patients. Because a positive test for cytoplasmic-ANCA targeted to PR3, or perinuclear-ANCA against MPO has a high sensitivity and specificity for the diagnosis of ANCA-associated vasculitis, cytoplasmic-ANCA, PR3-ANCA, or both were referred to collectively as PR3-ANCA, and perinuclear-ANCA, MPO-ANCA or both were referred to collectively as MPO-ANCA. Serum and CSF were analysed simultaneously for 15 different cytokines and chemokines, namely interleukin (IL)-1 β , IL-2, IL-4, IL-5, IL-6, CXCL8, IL-10, IL-12p70, IL-17A, interferon γ , tumor necrosis factor α , CCL2, CCL5, CXCL9, and CXCL10 using BDTM cytometric bead arrays (BD Pharmingen) and ELISA (human IL-17A ELISA kit from eBioscience). We assessed materials from patients with MPO-ANCA-positive (CSF, $n = 11$; serum, $n = 8$), PR3-ANCA-positive (CSF, $n = 4$; serum, $n = 4$), and idiopathic hypertrophic pachymeningitis (CSF, $n = 7$; serum, $n = 8$), and hypertrophic pachymeningitis with other causes (CSF, $n = 5$; serum, $n = 4$). We also measured cytokines and chemokines in the CSF of 12 patients with sporadic amyotrophic lateral sclerosis ($n = 12$), and in the serum of 11 patients with sporadic amyotrophic lateral sclerosis ($n = 9$), clinically probable hereditary spastic paraplegia ($n = 1$) and thoracic spondylosis ($n = 1$) as the 'other non-inflammatory neurological diseases' group.

Pathological studies were performed using one autopsy and six biopsy specimens including the meninges of patients with MPO-ANCA-positive

hypertrophic pachymeningitis. Paraffin-embedded sections (4- μ m thick) were stained with haematoxylin and eosin and Elastica-Goldner. For immunohistochemistry, primary antibodies specific for CD4 (clone 1F6, Serotec), CD8 (clone EP1150Y, Epitomics), CD45RO (clone UCHL-1, Dako), CD20 (clone L26, Dako), CD21 (clone 1F8, Dako), and CD35 (clone Ber-MAC-DRC, Dako) were used. Antibody binding was visualized using the avidin–biotin–peroxidase complex method (Vectastain ABC kit; Vector Laboratories). Diaminobenzidine was used as the chromogen, and the sections were counterstained with 0.05% methylene blue.

Statistical analyses

Data analyses were performed using GraphPad Prism 5 (GraphPad Software Inc.) and IBM SPSS 19 (IBM) software. Statistical analyses between the two groups of MPO-ANCA-positive hypertrophic pachymeningitis and other non-inflammatory neurological diseases, or between the two treatment subgroups in patients with MPO-ANCA-positive hypertrophic pachymeningitis were performed using the Mann-Whitney U-test or Fisher's exact test, as appropriate. Statistical analyses among the four subgroups of MPO-ANCA-positive, PR3-ANCA-positive and idiopathic hypertrophic pachymeningitis, hypertrophic pachymeningitis, and hypertrophic pachymeningitis with other immune-mediated disorders, or among the three subgroups of MPO-ANCA-positive, PR3-ANCA-positive and idiopathic hypertrophic pachymeningitis were performed using ANOVA, the Kruskal-Wallis H test, or Fisher's exact test, as appropriate. When significant results were obtained, multiple comparisons among subgroups were performed using the Bonferroni or Bonferroni-Dunn multiple comparison tests. Cumulative probabilities of disease progression as assessed with the modified Rankin Scale and relapse-free survival rates were estimated by Kaplan-Meier method, and the significance test among several curves of cumulative probabilities and survival rates was performed by the log-rank test. Changes in annual relapse rate before and after cyclophosphamide administration were analysed by the Wilcoxon signed-rank test. All statistical analyses were considered significant at P -values < 0.05 .

Results

Demographics

Among the 36 Japanese patients with immune-mediated or idiopathic hypertrophic pachymeningitis, 17 patients (47%) had MPO-ANCA-positive hypertrophic pachymeningitis, nine (25%) had idiopathic hypertrophic pachymeningitis, four (11%) had PR3-ANCA-positive hypertrophic pachymeningitis, and six (17%) had other immune-mediated disorders including IgG4-related disorder, sarcoidosis, rheumatoid arthritis and anti-centromere antibody-positive status (Fig. 1A). Female predominance was seen for MPO-ANCA-positive hypertrophic pachymeningitis (male/female = 4/13) (Table 1). The median age at onset in patients with MPO-ANCA-positive hypertrophic pachymeningitis was 66 years. Each subset of hypertrophic pachymeningitis was more common in elderly persons. The median [interquartile range (IQR)] observation periods of MPO-ANCA-positive and PR3-ANCA-positive hypertrophic pachymeningitis, hypertrophic pachymeningitis with other immune-mediated disorders, and idiopathic hypertrophic pachymeningitis were 25 (IQR 20–95), 30

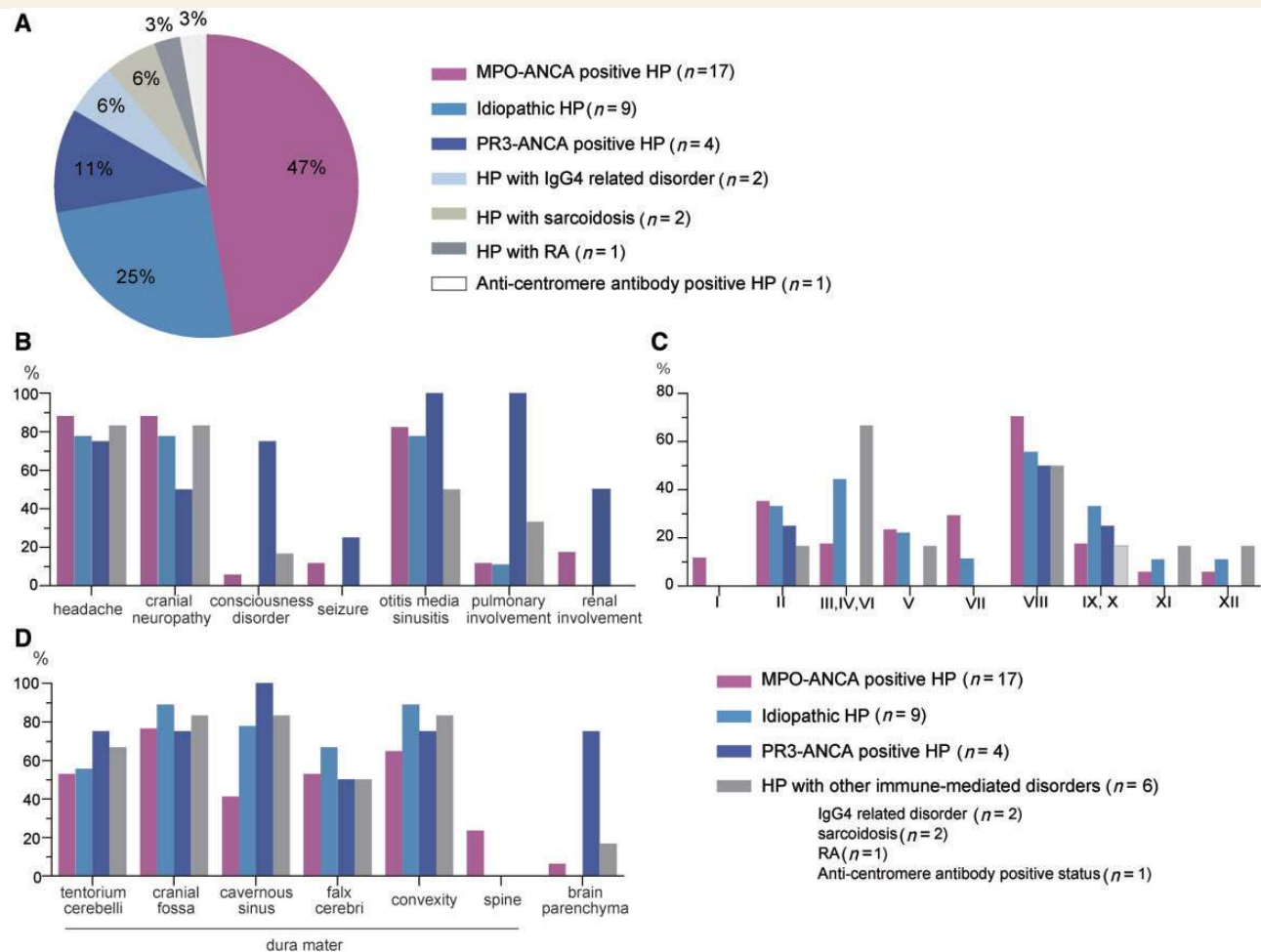


Figure 1 Demographic information, cumulative symptoms, and distribution by lesions in immune-mediated or idiopathic hypertrophic pachymeningitis (HP). Among the 36 Japanese patients with immune-mediated or idiopathic hypertrophic pachymeningitis, 17 patients (47%) had MPO-ANCA-positive hypertrophic pachymeningitis, nine patients (25%) had idiopathic hypertrophic pachymeningitis, four patients (11%) had PR3-ANCA-positive hypertrophic pachymeningitis, and six patients (17%) had other immune-mediated disorders including IgG4-related disorder, sarcoidosis, rheumatoid arthritis (RA), and anti-centromere antibody-positive status (A). Cumulative symptoms (B), distribution of cranial nerve involvement (C), and lesions with thickened dura mater with abnormal enhancement or parenchymal abnormalities on MRI studies (D).

(IQR 11–139), 22 (IQR 5–63), and 39 (IQR 21–79) months, respectively.

Clinical features of myeloperoxidase ANCA-positive hypertrophic pachymeningitis

All 17 (100%) patients with MPO-ANCA-positive hypertrophic pachymeningitis, two of four (50%) patients with PR3-ANCA-positive hypertrophic pachymeningitis, four of six (67%) patients with hypertrophic pachymeningitis as a result of other immune-mediated disorders, and all nine (100%) patients with idiopathic hypertrophic pachymeningitis were diagnosed with hypertrophic pachymeningitis as the first clinical episode. Headaches, cranial polyneuropathy and chronic sinusitis or otitis media were common in patients with MPO-ANCA-positive and PR3-ANCA-positive

hypertrophic pachymeningitis, hypertrophic pachymeningitis with other immune-mediated disorders, and idiopathic hypertrophic pachymeningitis (Fig. 1B and Table 2). In particular, >78% of patients with MPO-ANCA-positive, PR3-ANCA-positive, and idiopathic hypertrophic pachymeningitis showed signs of chronic sinusitis, otitis media, or mastoiditis for >3 months, which are surrogate markers of granulomatous inflammation in the upper airways for granulomatosis with polyangiitis (Fig. 1B and Table 2). Chronic sinusitis was evident in 5/17 (29%), 4/4 (100%), 4/9 (44%), and 3/6 (50%) patients with MPO-ANCA-positive, PR3-ANCA-positive and idiopathic hypertrophic pachymeningitis, and hypertrophic pachymeningitis with other immune-mediated disorders, respectively. Otitis media was evident in 11/17 (65%), 3/4 (75%), 5/9 (56%), and 0/6 (0%) patients with MPO-ANCA-positive, PR3-ANCA-positive and idiopathic hypertrophic pachymeningitis, and hypertrophic pachymeningitis with other immune-mediated disorders, respectively. Mastoiditis was

Table 1 Clinical and demographic characteristics of immune-mediated or idiopathic hypertrophic pachymeningitis

	MPO-ANCA-positive HP (n = 17)	PR3-ANCA-positive HP (n = 4)	Idiopathic HP (n = 9)	HP with other immune-mediated disorders ^a (n = 6)
No. of males/females	4/13 (1:3.25) ^c	2/2 (1:1)	5/4 (1:0.8)	6/0 (1:0) ^c
Age at onset (years) ^b	66 (58–71)	64 (43–75)	61 (57–75)	53 (38–67)
Observation periods (m) ^b	25 (20–95)	30 (11–139)	39 (21–79)	22 (5–63)
CSF findings				
Marked pleocytosis (≥ 50 / μ l)	2/16 (13%)	1/4 (25%)	0/9 (0%)	1/5 (20%)
Mild pleocytosis (49–10 / μ l)	6/16 (38%)	0/4 (0%)	2/9 (22%)	2/5 (40%)
Protein (≥ 50 mg/dl)	9/16 (56%)	2/4 (50%)	3/9 (33%)	3/5 (60%)
IgG index (≥ 0.658)	10/12 (83%) ^d	2/4 (50%)	2/8 (25%) ^d	3/5 (60%)
Serum findings				
Seropositivity for MPO-ANCA	17/17 (100%) ^e	0/4 (0%) ^e	0/9 (0%) ^e	0/6 (0%) ^e
Seropositivity for PR3-ANCA	0/17 (0%) ^f	4/4 (100%) ^f	0/9 (0%) ^f	0/6 (0%) ^f
Seropositivity for rheumatoid factor	13/17 (76%)	3/4 (75%)	4/9 (44%)	3/5 (60%)
CRP (≥ 0.3 mg/dl)	9/13 (69%)	4/4 (100%) ^g	5/9 (56%)	1/6 (17%) ^g
ESR (≥ 20 mm/h)	10/12 (83%)	3/3 (100%)	7/8 (88%)	2/4 (50%)

^aHypertrophic pachymeningitis with other immune-mediated disorders (n = 6) was associated with IgG4-related disorder (n = 2), sarcoidosis (n = 2), rheumatoid arthritis (n = 1), and anti-centromere antibody positive status (n = 1).

^bMedian (IQR).

^{c,d,g}Statistically significant in comparison between the linked values ($P < 0.05$).

^eStatistically significant in comparison between MPO-ANCA-positive hypertrophic pachymeningitis and each other hypertrophic pachymeningitis (PR3-ANCA-positive, idiopathic, and hypertrophic pachymeningitis with other immune-mediated disorders) ($P < 0.05$).

^fStatistically significant in comparison between PR3-ANCA-positive hypertrophic pachymeningitis and each other hypertrophic pachymeningitis (MPO-ANCA-positive, idiopathic, and hypertrophic pachymeningitis with other immune-mediated disorders) ($P < 0.05$).

CRP = C-reactive protein; ESR = erythrocyte sedimentation rate; HP = hypertrophic pachymeningitis.

Table 2 Surrogate markers for granulomatosis with polyangiitis and microscopic polyangiitis

	MPO-ANCA- positive HP (n = 17)	PR3-ANCA- positive HP (n = 4)	Idiopathic HP (n = 9)	HP with other immune-mediated disorders ^a (n = 6)
Granulomatosis with polyangiitis				
X-ray evidence of fixed pulmonary infiltrates, nodules or cavitations present >1 month (%)	2 (12) ^b	4 (100) ^{b,c}	1 (11) ^c	2 (33)
Bronchial stenosis (%)	0	0	0	0
Bloody nasal discharge and crusting for >1 month, or nasal ulceration (%)	0 ^d	2 (50) ^d	0	0
Chronic sinusitis, otitis media or mastoiditis for >3 months (%)	14 (82)	4 (100)	7 (78)	3 (50)
Retro-orbital mass or inflammation (pseudotumour) (%)	1 (6)	1 (25)	2 (22)	2 (33)
Subglottic stenosis (%)	0	0	0	0
Saddle nose deformity/destructive sinonasal disease (%)	0	0	0	0
Microscopic polyangiitis				
Haematuria associated with red cell casts or >10% dysmorphic erythrocytes (%)	1 (6)	1 (25)	0	0
2+ haematuria and 2+ proteinuria on urinalysis (%)	1 (6)	1 (25)	0	0

^ahypertrophic pachymeningitis with other immune-mediated disorders (n = 6) was associated with IgG4-related disorder (n = 2), sarcoidosis (n = 2), rheumatoid arthritis (n = 1), and anti-centromere antibody positive status (n = 1).

^{b,c,d}Statistically significant in comparison between the linked values (^b $P < 0.01$; ^c $P < 0.05$; ^d $P < 0.05$).

HP = hypertrophic pachymeningitis.

evident in 8/17 (47%), 4/4 (100%), 5/9 (56%), and 2/6 (33%) patients with MPO-ANCA-positive, PR3-ANCA-positive and idiopathic hypertrophic pachymeningitis, and hypertrophic pachymeningitis with other immune-mediated disorders, respectively. The frequency of patients having chronic sinusitis, otitis media or mastoiditis was higher in patients with PR3-ANCA-positive

hypertrophic pachymeningitis compared with those with MPO-ANCA-positive and idiopathic hypertrophic pachymeningitis, and hypertrophic pachymeningitis with other immune-mediated disorders. Hearing loss caused by involvement of otitis media and/or cranial nerve VIII preceded the recognition of hypertrophic pachymeningitis in 13/17 (76%) patients with MPO-ANCA-positive, 3/4

(75%) patients with PR3-ANCA-positive and 5/9 (56%) patients with idiopathic hypertrophic pachymeningitis, and 3/6 (50%) patients with hypertrophic pachymeningitis because of other immune-mediated disorders. Bilateral hearing loss was evident in 7/17 (41%) patients with MPO-ANCA-positive, 2/4 (50%) patients with PR3-ANCA-positive and 3/9 (33%) patients with idiopathic hypertrophic pachymeningitis, and 1/6 (17%) patients with hypertrophic pachymeningitis because of other immune-mediated disorders. Audiometry assessments were performed in 22/36 patients (61%) with immune-mediated or idiopathic hypertrophic pachymeningitis. Based on assessments by audiometry, severe or profound hearing impairment (>70 dB level; air-conduction pure-tone average thresholds in the four conversational frequencies of 0.5, 1, 2 and 4 kHz) was evident in 6/11 (55%) patients with MPO-ANCA-positive, 3/3 (100%) patients with PR3-ANCA-positive and 2/6 (33%) patients with idiopathic hypertrophic pachymeningitis, and 0/2 (0%) patients with hypertrophic pachymeningitis because of other immune-mediated disorders. Moreover, in patients with MPO-ANCA-positive hypertrophic pachymeningitis, 3/11 (27%) had a mixed hearing loss pattern, 7/11 (64%) had only a sensorineural hearing loss pattern, and 1/11 (9%) had only a conductive hearing loss pattern. The frequency of patients with consciousness disturbance among those with PR3-ANCA-positive hypertrophic pachymeningitis was significantly higher than that in patients with MPO-ANCA-positive or idiopathic hypertrophic pachymeningitis ($P < 0.05$) (Fig. 1B). MRI findings demonstrated that all patients with PR3-ANCA-positive hypertrophic pachymeningitis with consciousness disturbance definitely had brain parenchymal involvement. These data suggest that parenchymal involvement in the brain was significantly more common in PR3-ANCA-positive hypertrophic pachymeningitis compared with MPO-ANCA-positive and idiopathic hypertrophic pachymeningitis.

Importantly, the frequency of patients with renal or pulmonary involvement among those with PR3-ANCA-positive hypertrophic pachymeningitis was significantly higher than that in patients with MPO-ANCA-positive or idiopathic hypertrophic pachymeningitis ($P < 0.01$; Fig. 1B and 2I). Most patients with MPO-ANCA-positive and idiopathic hypertrophic pachymeningitis may be characterized as having the limited form within the CNS, in contrast with PR3-ANCA-positive hypertrophic pachymeningitis.

Radiological findings in myeloperoxidase-ANCA-positive hypertrophic pachymeningitis

In this study, a gadolinium-enhanced MRI study of the brain or spine revealed thickening of the dura mater in all patients with immune-mediated or idiopathic hypertrophic pachymeningitis (Fig. 2A–D, F and G). We categorized dural-enhanced lesions into six distinct patterns: (i) tentorium cerebelli; (ii) cranial fossa; (iii) cavernous sinus; (iv) falx cerebri; (v) convexity; and (vi) spine (Figs 1D, 2A–D, F and G). The distribution pattern of dural enhancement was similar among patients with MPO-ANCA-positive hypertrophic pachymeningitis and each of the other three subsets (Figs 1D, 2A–D and F). Importantly, leptomeningeal and parenchymal involvement in the brain were significantly more common

in PR3-ANCA-positive hypertrophic pachymeningitis compared with MPO-ANCA-positive and idiopathic hypertrophic pachymeningitis (Figs 1D and 2G). Mastoiditis and sinusitis were observed in patients with MPO-ANCA-positive and PR3-ANCA-positive hypertrophic pachymeningitis on axial T₂-weighted MRI. The radiological abnormalities became normal in 6/17 (35%) patients with MPO-ANCA-positive hypertrophic pachymeningitis, 0/4 (0%) patients with PR3-ANCA-positive hypertrophic pachymeningitis, 5/9 patients (56%) with idiopathic hypertrophic pachymeningitis, and 2/6 patients (33%) with hypertrophic pachymeningitis with other immune-mediated disorders after treatments.

Immunological findings in myeloperoxidase ANCA-positive hypertrophic pachymeningitis

We performed semi-quantitative analyses of the ANCA and tried to assess correlation between the ANCA titre and disease activity or clinical presentation in 14/17 patients (82%) with MPO-ANCA-positive hypertrophic pachymeningitis, because their sera were available for longitudinal assessment. In all 14 of these patients, MPO-ANCA was a useful marker of disease activity during the initial immunosuppressive treatments, and 2/14 (14%) patients with MPO-ANCA-positive hypertrophic pachymeningitis showed MPO-ANCA seroconversion from seronegative at initial presentation to seropositive after clinical relapses. However, three patients remained seronegative even during clinical relapses, after seroconversion from positive to negative by initial treatments (Supplementary Fig. 5). In patients with MPO-ANCA-positive hypertrophic pachymeningitis, serum rheumatoid factor was positive in 13/17 (76%) patients, C reactive protein was elevated in 9/13 (69%) patients, and the erythrocyte sedimentation rate was elevated in 10/12 (83%) patients; similar results were found in patients with PR3-ANCA-positive hypertrophic pachymeningitis and idiopathic hypertrophic pachymeningitis.

In the CSF of patients with MPO-ANCA-positive hypertrophic pachymeningitis, 8/16 (50%) patients showed mild to marked pleocytosis, 10/12 (83%) patients had increased IgG index levels, and 9/16 (56%) patients had increased protein levels (Table 1). Moreover, we found higher amounts of IL-6, CXCL8, and CXCL10 in CSF and IL-6 in blood in patients with MPO-ANCA-positive hypertrophic pachymeningitis compared to patients with other non-inflammatory neurological diseases (Fig. 3). The ratio of IL-6 to CCL5 in CSF and serum of patients with MPO-ANCA-positive hypertrophic pachymeningitis was significantly higher than that in patients with other non-inflammatory neurological diseases. Patients with MPO-ANCA-positive hypertrophic pachymeningitis did not have other autoimmune diseases more frequently than patients with other non-inflammatory neurological diseases. These data suggest the immunopathological relevance of T_H1 cells and innate cells including monocytes, macrophages, and neutrophils in MPO-ANCA-positive hypertrophic pachymeningitis, because CXCL8 mainly targets neutrophils, CXCL10 mainly targets activated T cells including T_H1 cells, and IL-6 is produced by monocytes, macrophages, T cells

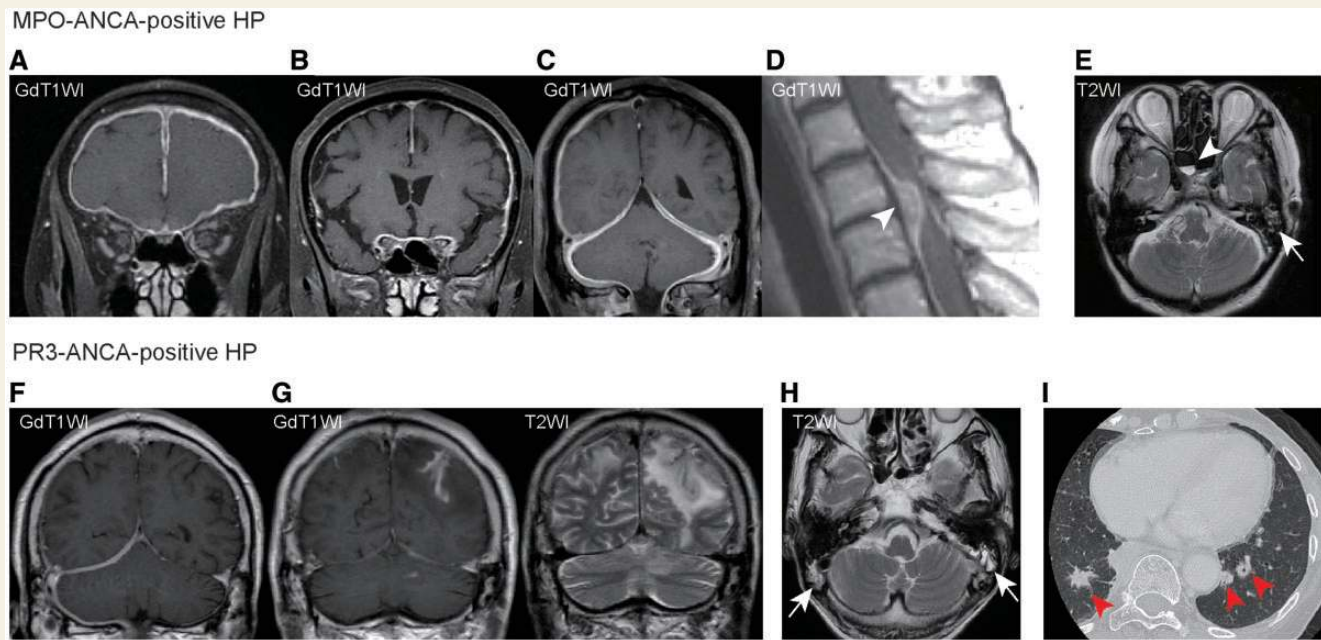


Figure 2 Radiological profiles of MPO-ANCA-positive hypertrophic pachymeningitis. In radiological studies, extra-axial enhancement in the CNS is classified as either pachymeningeal or leptomeningeal (Smirniotopoulos *et al.*, 2007). Pachymeningeal pattern of enhancement involves the dural reflections of the tentorium cerebelli, cranial fossa, cavernous sinus, falx cerebri, convexity, and the spine, whereas leptomeningeal pattern of enhancement occurs along the pial surface of the brain, and fits the subarachnoid spaces of the sulci and cisterns. Thickened dura mater (a pure pachymeningeal pattern of enhancement) was seen in tentorium cerebelli, cranial fossa, cavernous sinus, falx cerebri, convexity, and the spine (arrowhead) in patients with MPO-ANCA-positive hypertrophic pachymeningitis (A–D) and PR3-ANCA-positive hypertrophic pachymeningitis (F) on T₁-weighted post-gadolinium magnetic resonance images (GdT1WI). Thickened dura mater with leptomeningeal and parenchymal involvement (pachymeningeal and leptomeningeal patterns of enhancement) in the brain was significantly more common in PR3-ANCA-positive hypertrophic pachymeningitis (G) compared to MPO-ANCA-positive and idiopathic hypertrophic pachymeningitis (see Fig. 1D). Mastoiditis (arrows) and sinusitis (arrowhead) were observed in patients with MPO-ANCA-positive hypertrophic pachymeningitis (E) and PR3-ANCA-positive hypertrophic pachymeningitis (H) on axial T₂-weighted magnetic resonance images (T2WI). Nodular lesions (arrowheads) were observed in the lung of patients with PR3-ANCA-positive hypertrophic pachymeningitis on CT scans (I).

and endothelial cells. The pattern of expression of cytokines and chemokines in serum and CSF in MPO-ANCA-positive hypertrophic pachymeningitis was similar to that in PR3-ANCA-positive hypertrophic pachymeningitis and idiopathic hypertrophic pachymeningitis except for the ratio of IL-6 to CCL5 in serum (Supplementary Fig. 1).

Pathological findings in myeloperoxidase ANCA-positive hypertrophic pachymeningitis

Pathological studies were performed with material from an autopsied case and six biopsied cases with immune-mediated hypertrophic pachymeningitis (MPO-ANCA-positive hypertrophic pachymeningitis, $n = 5$; PR3-ANCA-positive hypertrophic pachymeningitis, $n = 2$) (Table 3). All dura mater samples showed severe to moderate thickening with fibrosis (Fig. 4). According to 2012 or 1994 Chapel Hill Consensus Conference definitions, ANCA-associated vasculitis was defined by two criteria: (i) necrotizing vasculitis, predominantly affecting small to medium vessels; and (ii) necrotizing granulomatous inflammation, which should be common in granulomatosis with

polyangiitis and absent in microscopic polyangiitis (Devaney *et al.*, 1990; Jennette *et al.*, 1994, 2013). Two of five (40%) patients with MPO-ANCA-positive hypertrophic pachymeningitis (Cases 1 and 4 in Table 3) and 1/2 (50%) patients with PR3-ANCA-positive hypertrophic pachymeningitis (Case 2 in Table 3) showed granulomatous inflammation including multinucleated giant cells, necrosis, and vasculitis in thickened dura mater. Inflammatory cells in the dura mater of MPO-ANCA-positive hypertrophic pachymeningitis included CD4⁺ and CD8⁺ T cells, CD20⁺ B cells, neutrophils, eosinophils, plasma cells, monocytes, and macrophages. The pathological and immunological data of serum and CSF indicated that T_H1-predominant granulomatous lesions were mainly evident in MPO-ANCA-positive and PR3-ANCA-positive hypertrophic pachymeningitis as previously reported in pulmonary or renal lesions of ANCA-associated vasculitis (Lamprecht and Kabelitz, 2011). Intriguingly, CD20⁺ B cell clusters with CD21⁺ CD35⁺ follicular dendritic cells, which are essential for B cell maturation owing to their ability to retain antigens on their membrane in the form of immunocomplexes, and to stimulate proliferation and prevent apoptosis of germinal centre B cells, were evident in granulomatous inflammation of the thickened dura mater of two patients with MPO-ANCA-positive hypertrophic pachymeningitis (Cases 1 and 4 in Table 3; Fig. 4) and a patient with PR3-ANCA-

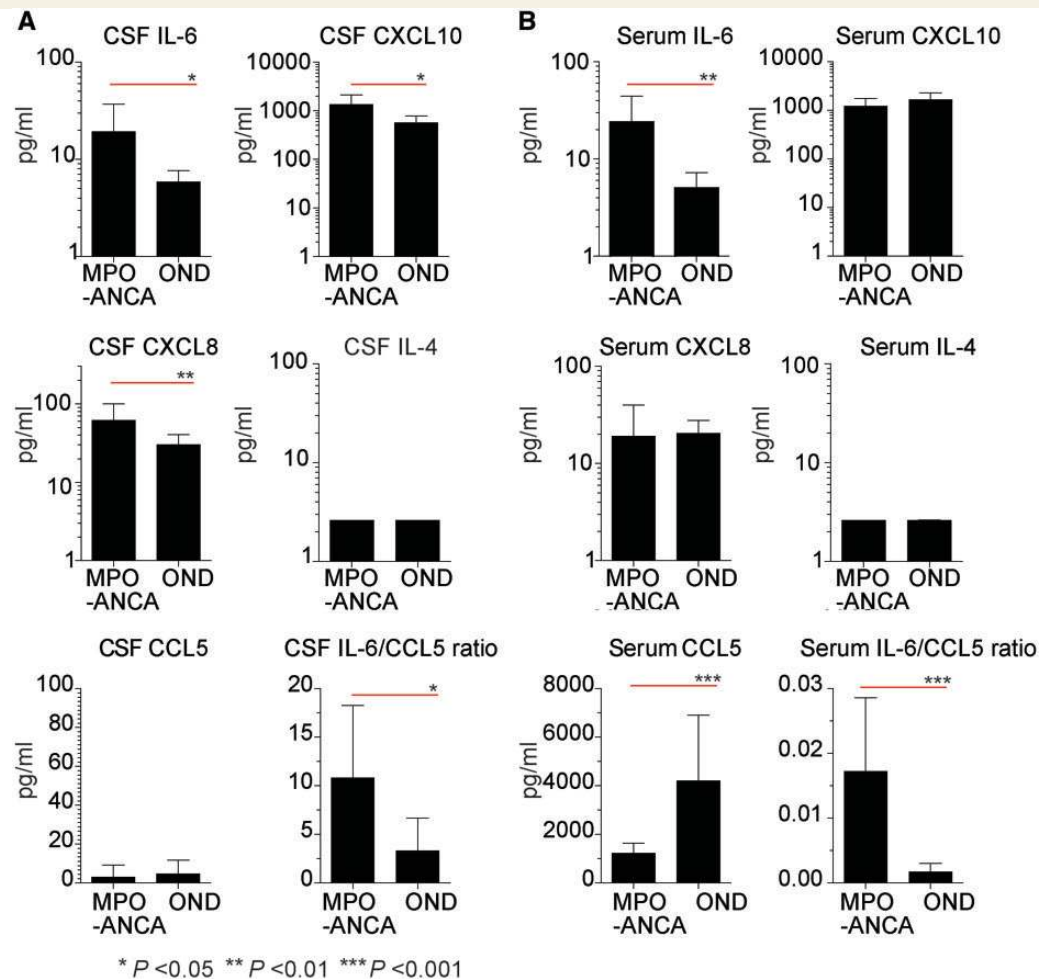


Figure 3 Immunological profiles of MPO-ANCA-positive hypertrophic pachymeningitis (HP). Cytokine and chemokine levels in CSF (A) and serum (B) from patients with MPO-ANCA-positive hypertrophic pachymeningitis (MPO-ANCA) and patients with other non-inflammatory neurological disorders (OND) were assessed with the multiplexed fluorescent bead-based immunoassay and an ELISA. Patients with MPO-ANCA-positive hypertrophic pachymeningitis showed significantly higher levels of IL-6, CXCL8, and CXCL10 in CSF during attacks than patients with other non-inflammatory neurological diseases. Other cytokine and chemokine levels, including IL-1 β , IL-2, IL-4, IL-5, IL-10, IL-12p70, IL-17A, interferon (IFN) γ , tumor necrosis factor (TNF) α , CCL2, CCL5, and CXCL9 in CSF did not differ in the groups (data not shown). The serum of patients with MPO-ANCA-positive hypertrophic pachymeningitis displayed significantly higher levels of IL-6 and lower levels of CCL5 during attacks than patients with other non-inflammatory neurological diseases. Other cytokine and chemokine levels in serum, including IL-1 β , IL-2, IL-4, IL-5, IL-10, IL-12p70, IL-17A, interferon γ , tumour necrosis factor α , CCL2, CXCL8, CXCL9, and CXCL10 did not differ between in the groups (data not shown). The ratio of IL-6 to CCL5 in the CSF and serum of patients with MPO-ANCA-positive hypertrophic pachymeningitis was significantly higher than that in patients with other non-inflammatory neurological diseases. The error bars represent the standard deviation.

positive hypertrophic pachymeningitis (Case 2 in Table 3), indicating the ectopic lymphoid neogenesis (Aloisi and Pujol-Borrell, 2006).

Classification of patients with myeloperoxidase ANCA-positive hypertrophic pachymeningitis according to a new consensus algorithm for ANCA-associated vasculitis

According to Watts' algorithm (Watts *et al.*, 2007), we classified all patients with immune-mediated or idiopathic hypertrophic

pachymeningitis into eosinophilic granulomatosis with polyangiitis, granulomatosis with polyangiitis, microscopic polyangiitis, polyarteritis nodosa, or unclassifiable entity (Fig. 5, Table 2 and Supplementary Figs 2, 3 and 4). Importantly, 14/17 (82%) patients with MPO-ANCA-positive hypertrophic pachymeningitis, all (100%) patients with PR3-ANCA-positive hypertrophic pachymeningitis, and no (0%) patients with idiopathic hypertrophic pachymeningitis were categorized as 'granulomatosis with polyangiitis' according to Watts' algorithm. Both seropositivity for MPO-ANCA and one surrogate marker for granulomatosis with polyangiitis (chronic sinusitis, otitis media, or mastoiditis for >3 months) were important for classification as 'granulomatosis with

Table 3 Pathological findings of patients with immune-mediated hypertrophic pachymeningitis

Case	Age at biopsy/autopsy (years)	Biopsy/autopsy	Dura matter					Brain parenchymal involvement
			Thickening of dura matter	Granulomatous inflammation ^a	Necrosis ^a	Vasculitis ^a	Inflammatory cells	
MPO-ANCA-positive hypertrophic pachymeningitis								
1*	71	Autopsy	Positive	Positive ^{b,c}	Positive ^{d,e}	Positive ^{f,h}	CD4 ⁺ T, CD8 ⁺ T, CD20 ⁺ B, P, E, N, M	Positive
2	65	Biopsy	Positive	Negative	Negative	Negative	CD4 ⁺ T, CD8 ⁺ T, CD20 ⁺ B, E, N, M	Negative
3	67	Biopsy	Positive	Positive	Negative	Negative	CD4 ⁺ T, CD8 ⁺ T, CD20 ⁺ B, E, N, M	Negative
4	52	Biopsy	Positive	Positive ^{b,c}	Positive ^e	Positive ^{f,h}	CD4 ⁺ T, CD8 ⁺ T, CD20 ⁺ B, P, E, N, M	Negative
5	52	Biopsy	Positive	Negative	Negative	Negative	NA	Negative
PR3-ANCA-positive hypertrophic pachymeningitis								
1	54	Biopsy	Positive	Negative	Negative	Negative	L, P, M	Negative**
2	75	Biopsy	Positive	Positive ^{b,c}	Positive ^{d,e}	Positive ^{f,g,h}	CD45RO ⁺ T, CD20 ⁺ B, P, E, N, M	Positive

^aGranulomatous inflammation, necrosis, and vasculitis were defined by pathological criteria for granulomatosis with polyangiitis in previous reports (Devaney *et al.*, 1990; Jennette *et al.*, 1994, 2013).

^bPoorly formed granulomatous inflammation.

^cMicro-abscesses with granulomatous inflammation.

^dGeographic necrosis.

^eMicro-abscesses.

^fGranulomatous vasculitis.

^gNecrotizing vasculitis.

^hLymphocytes around small vessels.

*Pathological findings in systemic organs of the patient: multiple nodules in the bilateral kidneys consisting of granulomatous necrosis with multinucleated giant cells; no apparent angitis or crescent glomerulonephritis; aspiration pneumonia.

**The patient developed brain parenchymal lesions after biopsy of dura mater.

B = B cells; E = eosinophils; L = lymphocytes; M = monocytes; N = neutrophils; NA = not applicable; P = plasma cells; T = T cells.

polyangiitis' in patients with MPO-ANCA-positive hypertrophic pachymeningitis. Both seropositivity for PR3-ANCA and two surrogate markers for granulomatosis with polyangiitis ('chronic sinusitis, otitis media or mastoiditis for >3 months' and 'X-ray evidence of fixed pulmonary infiltrates, nodules, or cavitations present for >1 month') were important for classification as granulomatosis with polyangiitis in patients with PR3-ANCA-positive hypertrophic pachymeningitis. All (100%) patients with idiopathic hypertrophic pachymeningitis were categorized into the 'unclassifiable entity' according to the Watts' algorithm. However, 7/9 (78%) patients had one surrogate marker for granulomatosis with polyangiitis ('chronic sinusitis, otitis media or mastoiditis for >3 months'), but seropositivity for neither MPO-ANCA nor PR3-ANCA was seen in patients with idiopathic hypertrophic pachymeningitis (Table 2). These data suggest that some idiopathic hypertrophic pachymeningitis cases may be characterized as the CNS-limited form of ANCA-associated vasculitis with seronegativity for MPO-ANCA and PR3-ANCA.

Disease activity and progression of patients with myeloperoxidase ANCA-positive hypertrophic pachymeningitis

The annual relapse rates of MPO-ANCA-positive, PR3-ANCA-positive, and idiopathic hypertrophic pachymeningitis were 0.48 ± 0.84 , 0.90 ± 1.52 , and 0.08 ± 0.25 relapses/year (mean \pm SD), respectively. Disease activity was assessed with the BVAS index. The total score of BVAS during the most active phase in patients with PR3-ANCA-positive hypertrophic pachymeningitis was significantly higher

than that in patients with MPO-ANCA-positive and idiopathic hypertrophic pachymeningitis (Fig. 6A and B). BVAS is a clinical checklist of items organized into nine categories: general, cutaneous, mucous membranes/eyes, ear, nose and throat, chest, cardiovascular, abdominal, renal, and nervous systems. High scores for nervous system and ear, nose and throat were common in patients with MPO-ANCA-positive, PR3-ANCA-positive and idiopathic hypertrophic pachymeningitis. However, the scores for the chest and renal system in patients with PR3-ANCA-positive hypertrophic pachymeningitis were significantly higher than those in MPO-ANCA-positive and idiopathic hypertrophic pachymeningitis. Moreover, Kaplan-Meier estimates for the proportion of patients achieving a modified Rankin Scale score of >3 at 3000 days in PR3-ANCA-positive, MPO-ANCA-positive, and idiopathic hypertrophic pachymeningitis were 75%, 45% and 22%, respectively (Fig. 6C), indicating that neurological disease progression may be different in patients with each subset. These data suggest that most patients with MPO-ANCA-positive and idiopathic hypertrophic pachymeningitis may show the CNS-limited form and a less severe phenotype compared with patients with PR3-ANCA-positive hypertrophic pachymeningitis. Representative cases with MPO-ANCA-positive, PR3-ANCA-positive and idiopathic hypertrophic pachymeningitis are shown in Supplementary Figs 5–7.

Treatment in patients with myeloperoxidase ANCA-positive hypertrophic pachymeningitis

We evaluated the efficacy and tolerability of immune treatments for patients with MPO-ANCA-positive, PR3-ANCA-positive or idiopathic hypertrophic pachymeningitis. The treatment consisted

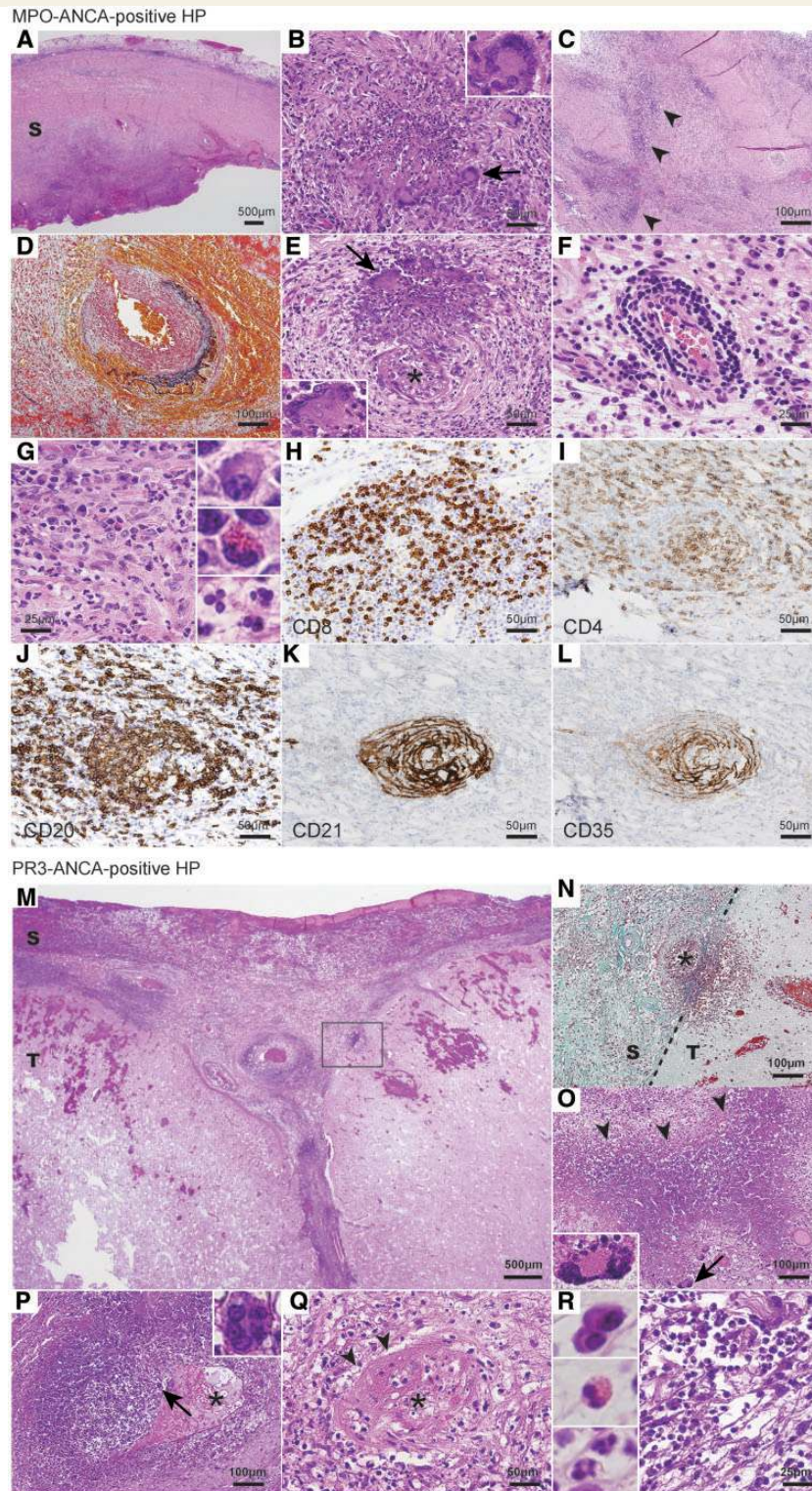


Figure 4 Pathological findings in MPO-ANCA-positive hypertrophic pachymeningitis (HP). Pathological findings in MPO-ANCA-positive hypertrophic pachymeningitis (A–L) and PR3-ANCA-positive hypertrophic pachymeningitis (M–R). All patients with MPO-ANCA- and PR3-ANCA-positive hypertrophic pachymeningitis showed thickened dura mater with fibrosis (A–R; Table 3). Two of five patients with MPO-ANCA-positive hypertrophic pachymeningitis and one of two patients with PR3-ANCA-positive hypertrophic pachymeningitis showed granulomatous inflammation characterized by appearance of multinucleated giant cells (A, B, E, M, O and P, arrows), geographic necrosis (C, O, arrowheads), and vasculitis (D, E, F, N, P and Q) in thickened dura mater. Multinucleated giant cells were scattered in granulomatous inflammatory area or necrosis foci (B, E, O and P). Geographic necrosis was characterized by large areas of necrosis with a basophilic centre and a serpiginous border surrounded by epithelioid histiocytes and multinucleated giant cells (C and O). Vascular changes

(continued)

of three patterns: (i) patients treated with prednisolone only; (ii) patients treated with cyclophosphamide in conjunction with prednisolone at the initial admission; and (iii) patients treated with prednisolone only at the initial admission, but treated with prednisolone and cyclophosphamide after relapses. Prednisolone treatment included a methylprednisolone pulse treatment (either 0.5 g/day or 1 g per day) for 3 days and high-dose oral prednisolone treatment (1.0 mg/kg per day) followed by prednisolone tapered slowly to maintenance level. Cyclophosphamide treatment included monthly intravenous pulses (0.5 g/m² per month) for several months or daily oral doses (1 mg/kg per day). Therapy was not randomly assigned, but no significant differences were found in baseline date of age, gender, observation period, clinical appearances, or immunological findings among the treatment subgroups in all subsets of immune-mediated or idiopathic hypertrophic pachymeningitis (data not shown). By the time this cohort was closed for analysis, two patients (one patient with MPO-ANCA-positive and one patient with PR3-ANCA-positive hypertrophic pachymeningitis) had died of high ANCA-related hypertrophic pachymeningitis disease activity. The frequencies of patients receiving only prednisolone among those with MPO-ANCA-positive PR3-ANCA-positive and idiopathic hypertrophic pachymeningitis were 7/17 (41%), 2/4 (50%), and 7/9 (78%), respectively. Relapses on therapy occurred in 13/30 (43%) patients with immune-mediated or idiopathic hypertrophic pachymeningitis: 10/17 (59%) patients with MPO-ANCA-positive hypertrophic pachymeningitis; 2/4 (50%) patients with PR3-ANCA-positive hypertrophic pachymeningitis; and 1/9 (11%) patients with idiopathic hypertrophic pachymeningitis. In MPO-ANCA-positive hypertrophic pachymeningitis, Kaplan-Meier estimates for the relapse-free proportion at 1000 days in patients treated with 'prednisolone only' and in patients treated with 'prednisolone and cyclophosphamide' at the initial admission were 16% and 75%, respectively (Fig. 7A). In patients treated with prednisolone only at the initial admission, but treated with prednisolone and cyclophosphamide after relapses, the addition of cyclophosphamide to prednisolone significantly reduced the annual relapse rate in patients with relapses of MPO-ANCA-positive hypertrophic pachymeningitis (Fig. 7B).

The adverse events were identified during the observation periods in 30 patients with MPO-ANCA-positive, PR3-ANCA-positive and idiopathic hypertrophic pachymeningitis, who were treated with prednisolone only or prednisolone and

cyclophosphamide: adverse events included infection in nine patients, diabetes mellitus in six patients, osteoporosis in four patients, liver dysfunction in four patients, deep vein thrombosis in three patients, haemorrhagic cystitis in two patients, and malignancy in two patients. Although no significant differences in adverse events were found between patients treated with prednisolone only and patients treated with prednisolone and cyclophosphamide, two patients with haemorrhagic cystitis (one patient with MPO-ANCA-positive hypertrophic pachymeningitis and one with idiopathic hypertrophic pachymeningitis) were treated with both prednisolone and cyclophosphamide. Bone marrow suppression and renal dysfunction were not observed in this study.

Discussion

We assessed 36 patients with immune-mediated or idiopathic hypertrophic pachymeningitis including 17 patients with MPO-ANCA-positive hypertrophic pachymeningitis and demonstrated that MPO-ANCA-positive hypertrophic pachymeningitis can be characterized by the following features: (i) an elderly female predominance; (ii) 82% of patients diagnosed with granulomatosis with polyangiitis according to Watts' algorithm; (iii) a high frequency of patients with lesions limited to the dura mater and upper airways, developing headaches, chronic sinusitis, otitis media, or mastoiditis; (iv) a low frequency of patients with the 'classical or generalized form' of granulomatosis with polyangiitis involving the entire upper and lower airways and kidney, or progressing to generalized disease, in contrast with PR3-ANCA-positive hypertrophic pachymeningitis; (v) less severe neurological damage as determined with the modified Rankin Scale and lower disease activity on BVAS compared with PR3-ANCA-positive hypertrophic pachymeningitis; (vi) increased levels of CXCL10, CXCL8, and IL-6 in CSF, and increased numbers of CD4⁺ and CD8⁺ T cells, CD20-positive B cells, neutrophils, eosinophils, plasma cells, monocytes, and macrophages in autopsied or biopsied dura mater with pachymeningitis, suggesting T_H1-predominant granulomatous lesions in hypertrophic pachymeningitis, as previously reported for pulmonary or renal lesions of ANCA-associated vasculitis (Lamprecht and Kabelitz, 2011); and (vii) greater efficacy of combination therapy with prednisolone and cyclophosphamide compared to prednisolone monotherapy. PR3-ANCA-positive hypertrophic pachymeningitis may involve more severe

Figure 4 Continued

(asterisks) were characterized by fibrinoid necrosis (Q), granulomatous vasculitis (D, E, N and P), and acute or chronic inflammation of the vessel walls (F). Inflammatory cells in all pachymeningitis materials from patients with MPO-ANCA-positive and PR3-ANCA-positive were characterized as having CD8-positive (H) and CD4-positive T cells (I), CD20-positive B cells (J), neutrophils (G and R), plasma cells (G and R), eosinophils (G and R), and monocytes. CD20⁺ B cell clusters (J) with CD21⁺CD35⁺ follicular dendritic cells (K and L), which had a process-bearing morphology, were evident in granulomatous inflammation of the thickened dura mater in two patients with MPO-ANCA-positive hypertrophic pachymeningitis (J, K and L; Cases 1 and 4 in Table 3) and one patient with PR3-ANCA-positive hypertrophic pachymeningitis (data not shown; Case 2 in Table 3). One of five patients with MPO-ANCA-positive hypertrophic pachymeningitis and two of two patients with PR3-ANCA-positive hypertrophic pachymeningitis (M) showed parenchymal involvement of the brain according to clinical and pathological studies (S = dura mater; T = parenchyma). The tissue in the box in M is shown at higher magnification in N. Sections were stained with haematoxylin and eosin (A–C, E–G, M and O–R). Sections were stained with Elastica-Goldner stains (D and N). Immunohistochemistry was assessed with primary antibodies specific for CD8 (H), CD4 (I), CD20 (J), CD21 (K), and CD35 (L).

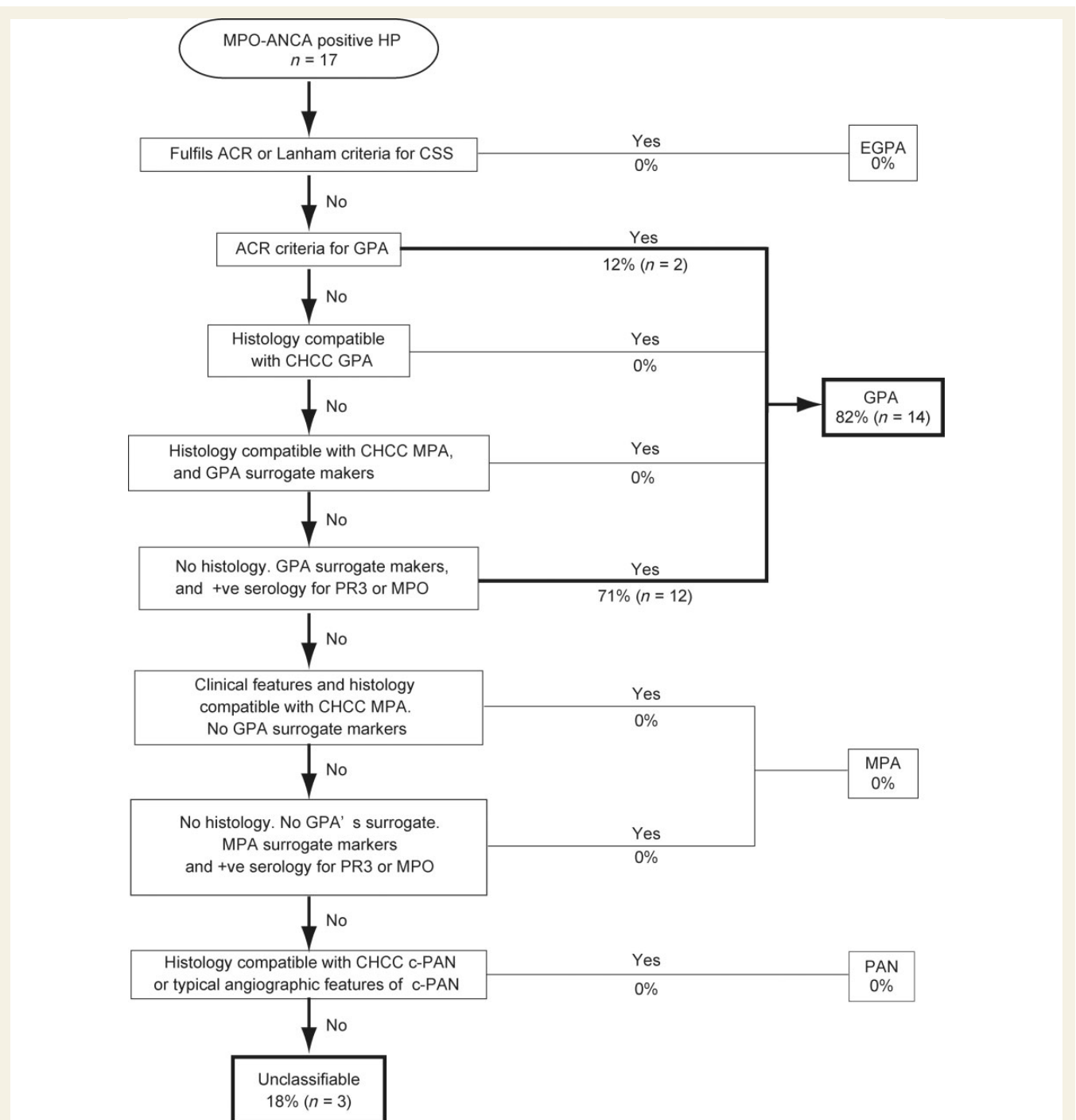


Figure 5 Classification of MPO-ANCA-positive hypertrophic pachymeningitis patients according to Watts' algorithm. HP = hypertrophic pachymeningitis; ACR = American College of Rheumatology criteria; CHCC = Chapel Hill Consensus Conference criteria; CSS = Churg–Strauss syndrome; EGPA = eosinophilic granulomatosis with polyangiitis; GPA = granulomatosis with polyangiitis; MPA = microscopic polyangiitis, cPAN = classic polyarteritis nodosa.

neurological damage, higher disease activity and a higher frequency of the generalized form compared with MPO-ANCA-positive- or idiopathic hypertrophic pachymeningitis. However, categorization into 'granulomatosis with polyangiitis' according to Watts' algorithm and immunological or pathological features were common in patients with PR3-ANCA-positive and MPO-ANCA-positive hypertrophic pachymeningitis. These data indicate

that most patients with MPO-ANCA-positive hypertrophic pachymeningitis should be categorized as having the CNS-limited form of ANCA-associated vasculitis, consistent with the recently proposed concept of 'ophthalmic-limited granulomatosis with polyangiitis', 'pulmonary-limited vasculitis', or 'renal-limited vasculitis' (Carrington and Liebow, 1966; Holle *et al.*, 2010; Isa *et al.*, 2012).

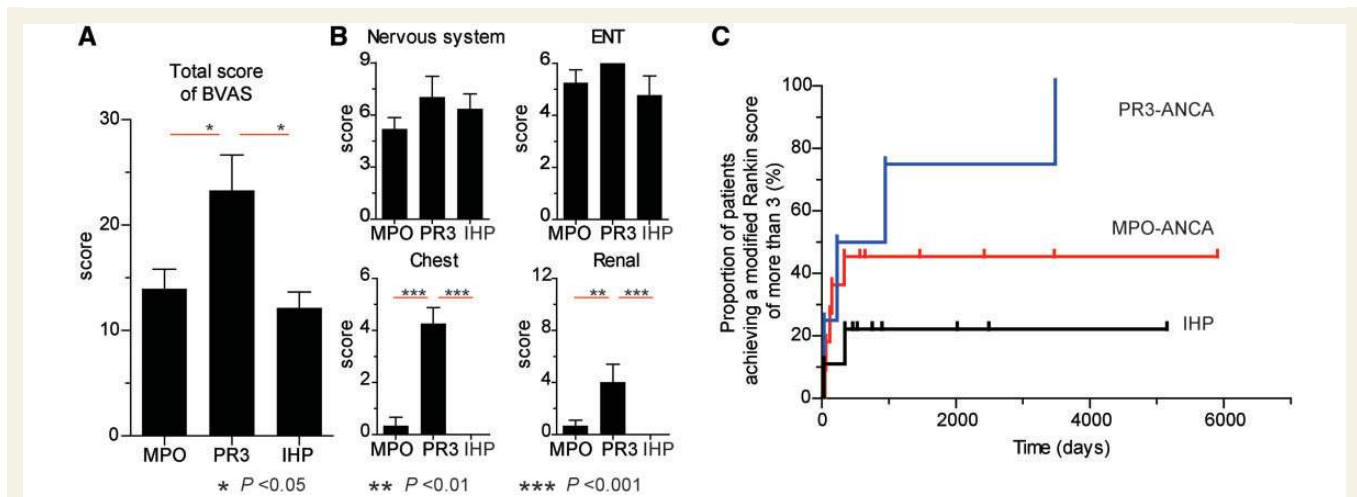


Figure 6 Disease activity and progression in MPO-ANCA-positive hypertrophic pachymeningitis. Disease activity was assessed with the BVAS index. The total score of BVAS during the most active phases in patients with PR3-ANCA-positive hypertrophic pachymeningitis was significantly higher than that in patients with MPO-ANCA-positive and idiopathic hypertrophic pachymeningitis (IHP) (A). BVAS is a clinical checklist of items organized into nine categories: general, cutaneous, mucous membranes/eyes, ear, nose and throat (ENT), chest, cardiovascular, abdominal, renal, and nervous systems (B). High scores for the nervous system and ear, nose and throat were common in patients with MPO-ANCA-positive hypertrophic pachymeningitis, PR3-ANCA-positive hypertrophic pachymeningitis, and idiopathic hypertrophic pachymeningitis. However, the scores for chest and renal systems in PR3-ANCA-positive hypertrophic pachymeningitis were significantly higher than those in patients with MPO-ANCA-positive hypertrophic pachymeningitis and idiopathic hypertrophic pachymeningitis (B). Disease progression according to the neurological status was measured with the modified Rankin Scale. Kaplan-Meier estimates for the proportion of patients achieving a modified Rankin score of >3 at 3000 days in PR3-ANCA-positive, MPO-ANCA-positive, and idiopathic hypertrophic pachymeningitis were 75%, 45% and 22%, respectively (C). These data suggest that neurological disease progression may be different in patients with each subset. The error bars represent the standard error of the mean.

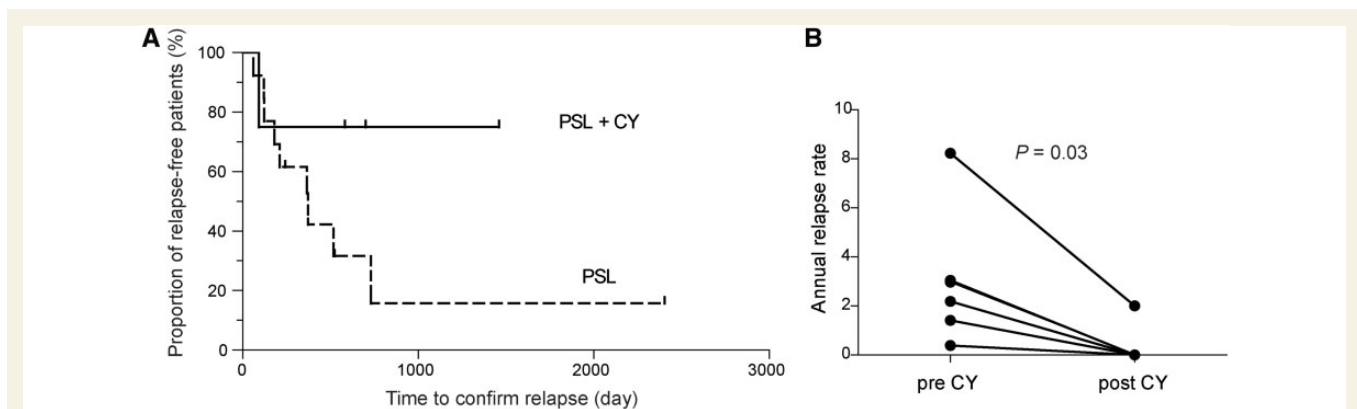


Figure 7 Treatment course in patients with MPO-ANCA-positive hypertrophic pachymeningitis. Kaplan-Meier estimates for the relapse-free proportion at 1000 days in patients treated with 'prednisolone (PSL) only' and in patients treated with 'prednisolone and cyclophosphamide (CY)' at the initial admission were 16% and 75%, respectively, in myeloperoxidase antibodies to the neutrophil cytoplasmic antibody (MPO-ANCA)-positive hypertrophic pachymeningitis (A). In patients treated with prednisolone only at the initial admission, but treated with prednisolone and cyclophosphamide after relapses, the addition of cyclophosphamide to prednisolone significantly reduced the annual relapse rate in patients with relapses of MPO-ANCA-positive hypertrophic pachymeningitis (B).

Granulomatosis with polyangiitis, previously known as Wegener's granulomatosis, is considered a systemic necrotizing granulomatous ANCA-associated vasculitis that mainly affects the upper and lower respiratory tracts and kidneys, whereas microscopic polyangiitis is a systemic necrotizing ANCA-associated vasculitis that typically causes rapidly progressive

glomerulonephritis and haemorrhagic pneumonitis (Leavitt *et al.*, 1990; Jennette *et al.*, 1994). However, limited expressions of ANCA-associated vasculitis, also known as 'ophthalmic-limited granulomatosis with polyangiitis', 'pulmonary-limited vasculitis', or 'renal-limited vasculitis' occur, especially in disease that is confined to eyes, upper or lower respiratory tract, or kidneys (Holle

et al., 2010; Isa *et al.*, 2012; Jennette *et al.*, 2013). Approximately 90% of patients with pulmonary-limited vasculitis, 46% of whom were ANCA-positive, had localized long-term disease, but 10% of patients developed a generalized disease state (Holle *et al.*, 2010). In our cohort, 3/17 (18%) patients with MPO-ANCA-positive hypertrophic pachymeningitis, 2/4 (50%) with PR3-ANCA-positive hypertrophic pachymeningitis, and 0/9 (0%) with idiopathic hypertrophic pachymeningitis developed systemic disease after a median course of 11.1 months (range, 6.1–121.7 months). These previous reports and our current data suggest the idea that limited manifestation of ANCA-associated vasculitis occurs not only in the eye, upper or lower respiratory tract, and kidney, but also in the meninges, especially in the dura mater, and that long-term limited diseases may still carry the danger of developing into generalized disease. Patients with MPO-ANCA-positive hypertrophic pachymeningitis might be included in the 'granulomatosis with polyangiitis' category, although whether MPO-ANCA-positive hypertrophic pachymeningitis as a limited form is a long-term disease phenotype or a short-term disease stage that occurs very early in the generalized granulomatosis with polyangiitis course remains unclear (Holle *et al.*, 2010; Jennette *et al.*, 2013).

This study in patients with MPO-ANCA-positive, PR3-ANCA-positive or idiopathic hypertrophic pachymeningitis emphasized the significance of the sign of 'chronic sinusitis, otitis media, or mastoiditis for >3 months', which are surrogate markers of granulomatous inflammation in upper airways for granulomatosis with polyangiitis. A previous paper suggested that the chronic inflammation of the middle ear may cause immune-mediated hypertrophic pachymeningitis as a result of local circulation through venous return, rather than direct invasion or labyrinthine (through the round or oval window membranes), because no patients with hypertrophic pachymeningitis and middle ear inflammation showed any destruction of the tympanic tegmentum, and 67% of patients had only conductive hearing loss with no labyrinthine dysfunction (Iwasaki *et al.*, 2006). The inflammatory mediators in the middle ear may spread to the dura mater in the middle and the posterior plexus of the veins, because the veins of the middle ear can communicate with the superior petrosal sinus and the pterygoid plexus of veins through emissary veins including the petrosquamosal sinus (Marsot-Dupuch *et al.*, 2001; Iwasaki *et al.*, 2006). Meanwhile, other factors rather than common antigenic epitopes in the dura mater and upper airway may be present in granulomatosis with polyangiitis, because some patients with MPO-ANCA-positive, PR3-ANCA-positive, and idiopathic hypertrophic pachymeningitis showed thickened dura mater, independently of time or lesion sequences between hypertrophic pachymeningitis and otological events.

Originally, PR3-ANCA was thought to be more specific for granulomatosis with polyangiitis, and MPO-ANCA was considered more specific for microscopic polyangiitis (Chen and Kallenberg, 2010). However, 54% of patients diagnosed with granulomatosis with polyangiitis according to Watts' algorithm were recently reported to be PR3-ANCA-positive, and 46% were MPO-ANCA-positive (Lionaki *et al.*, 2012). Seventy-five per cent of patients diagnosed with microscopic polyangiitis according to Watts' algorithm were MPO-ANCA-positive, and 25% were PR3-ANCA-positive (Lionaki *et al.*, 2012). Whether the clinical syndromes of

granulomatosis with polyangiitis and microscopic polyangiitis or the specificity for MPO- and PR3-ANCA represent distinct pathomechanisms and contribute to the disease course remains debatable. Specificity for MPO- or PR3-ANCA independently predicts relapse in patients with ANCA-associated vasculitis with renal disease, with PR3-ANCA-positive patients almost twice as likely to relapse as those with MPO-ANCA (Lionaki *et al.*, 2012). A genome-wide association study demonstrated that the strongest associations were with the antigenic specificity for MPO- or PR3-ANCA, not with the clinical syndrome of granulomatosis with polyangiitis and microscopic polyangiitis (Lyons *et al.*, 2012). PR3-ANCA is associated with *HLA-DP* and the genes encoding α 1-antitrypsin (*SERPINA1*) and proteinase 3 (*PRTN3*), whereas MPO-ANCA is associated with *HLA-DQ* (Lyons *et al.*, 2012). From our study of immune-mediated hypertrophic pachymeningitis, it may be considered that the specificity for MPO- and PR3-ANCA represents a distinct pathomechanism and contributes to the disease course, but the clinical syndromes of granulomatosis with polyangiitis and microscopic polyangiitis does not. Based on these concepts and our data, we emphasize that PR3-ANCA-positive- and MPO-ANCA-positive hypertrophic pachymeningitis are distinct autoimmune syndromes and that classification and diagnostic systems that incorporate ANCA specificity, such as MPO- or PR3-ANCA positivity, provide a more useful tool than only clinicopathological categories such as granulomatosis with polyangiitis or microscopic polyangiitis for predicting severity and prognosis. Distinct genetic risk factors (Lyons *et al.*, 2012) may provide evidence for clinicopathological differences between MPO-ANCA-positive and PR3-ANCA-positive hypertrophic pachymeningitis regarding the distribution of meningeal and/or parenchymal inflammation, involvement of systemic organs, severity and treatment course.

Categories of organ system involvement are ranked by the prevalence of PR3-ANCA and inversely by the prevalence of MPO-ANCA (Lionaki *et al.*, 2012). The majority of patients with renal-limited vasculitis (81%) were MPO-ANCA-positive, and those with destructive lesions of the upper airways (94%) were PR3-ANCA-positive (Lionaki *et al.*, 2012). Moreover, MPO-ANCA positivity is predominant in Asian countries, whereas PR3-ANCA positivity is predominant in northern Europe, suggesting an association between ANCA-associated vasculitis and some environmental factors such as silica, microbes or concomitant diseases (Lionaki *et al.*, 2012), or a genetic background such as *HLA* (Fujimoto *et al.*, 2011). In this study, we showed that MPO-ANCA positivity was more frequent compared with PR3-ANCA positivity in immune-mediated hypertrophic pachymeningitis among Japanese patients, although whether the predominance of MPO-ANCA-positive status in immune-mediated hypertrophic pachymeningitis is associated with organ-specific features or Asian-specific features remains unclear.

The pro-inflammatory pathogenic effects of ANCA are contingent on interactions with target antigens (PR3 and MPO) expressed on the surface of primed neutrophils and monocytes (Cartin-Ceba *et al.*, 2012). MPO- and PR3-ANCA can activate primed neutrophils and monocytes by binding directly to their antigens expressed on the surface or by Fc-receptor engagement. Activated leucocytes may cause small vessel injury in

ANCA-associated vasculitis. The binding of ANCA to primed leucocytes induces the production and release of CXCL8, which can attract more neutrophils and monocytes to the site of inflammation, leading to further accumulation of fully activated neutrophils in the vessel wall and amplification of inflammation (Ralston *et al.*, 1997). Moreover, T_H1 -type necrotizing granulomatous lesions may be evident in granulomatosis with polyangiitis because granulomatous lesions display abundant interferon γ expression (Muller *et al.*, 2000; Lamprecht and Gross, 2004). In this study, we found that CXCL10, CXCL8, and IL-6 were elevated in the CSF of patients with MPO-ANCA- and PR3-ANCA-positive hypertrophic pachymeningitis, suggesting accumulation of activated macrophages and neutrophils with T_H1 lymphocytes in inflammation in hypertrophic pachymeningitis. These data for ANCA-positive hypertrophic pachymeningitis are consistent with those in previous papers describing the immunopathogenesis of ANCA-associated vasculitis. Intriguingly, $CD20^+$ B cell clusters with $CD21^+CD35^+$ follicular dendritic cells were evident in granulomatous inflammation of the thickened dura mater of two patients with MPO-ANCA-positive hypertrophic pachymeningitis (Cases 1 and 4 in Table 3; Fig. 4) and a patient with PR3-ANCA-positive hypertrophic pachymeningitis (Case 2 in Table 3), indicating the ectopic lymphoid neogenesis (Aloisi and Pujol-Borrell, 2006). The observation of organized lymphoid structures that resemble secondary lymphoid organs in tissues that are targeted by chronic inflammation processes, indicates that lymphoid neogenesis might have a role in maintaining immune responses against persistent antigens (Aloisi and Pujol-Borrell, 2006). It has been reported that ectopic lymphoid neogenesis was evident in the target organ of several autoimmune disorders: joints of rheumatoid arthritis (Takemura *et al.*, 2001); the thyroid gland of Hashimoto's thyroiditis (Armengol *et al.*, 2001); the salivary glands of Sjögren's syndrome (Salomonsson *et al.*, 2003); or the brain leptomeninges of multiple sclerosis (Magliozzi *et al.*, 2007). Moreover, it has been reported that ectopic lymphoid neogenesis was also evident in the nasal passages and lungs of patients with granulomatosis with polyangiitis (Mackiewicz *et al.*, 2005), and differential mutated members of one B cell clone were present in granulomatous lesions of granulomatosis with polyangiitis, indicative of clonal expansion and intraclonal diversification within the granulomatous lesions (Kramer *et al.*, 2007). In this study, we demonstrated that ectopic lymphoid neogenesis including B cell clusters with follicular dendritic cells were present in granulomatous lesions of hypertrophic pachymeningitis in MPO- or PR3-ANCA-positive hypertrophic pachymeningitis (Fig. 4). These data may suggest that *in situ* formation of ectopic lymphoid neogenesis in granulomatous lesions of not only nasal passages and lungs, but also dura mater, may play an important role for initiating, maintaining and localizing immune responses (e.g. *in situ* production of autoantibodies including ANCA) in MPO- or PR3-ANCA-positive hypertrophic pachymeningitis.

In vivo animal models have been used to demonstrate that the transfer of MPO-ANCA into wild-type mice results in pauci-immune crescentic necrotizing glomerulonephritis (Xiao *et al.*, 2002), and the transfer of PR3-ANCA into wild-type mice causes an increased inflammatory response at the site of tissue injury (Pfister *et al.*, 2004). However, not all animal

models have provided evidence for an association between ANCA and hypertrophic pachymeningitis, and the primary immunopathogenic events that initiate the process of MPO- and PR3-ANCA-positive hypertrophic pachymeningitis are still largely unknown.

Although idiopathic hypertrophic pachymeningitis is supposed to be a 'heterogeneous' syndrome, we demonstrated that idiopathic hypertrophic pachymeningitis might share some common characteristic features with MPO-ANCA-positive hypertrophic pachymeningitis. The concept of granulomatosis with polyangiitis starting as a localized, often ANCA-negative disease with predominant upper airway involvement and later progressing to generalized ANCA-associated vasculitis has been supported by larger studies and a case report. Therefore, the EULAR has recommended that the absence of a positive test for ANCA should not rule out a diagnosis for primary small and medium vessel vasculitis including granulomatosis with polyangiitis or microscopic polyangiitis, and that patients with less severe disease, especially those with isolated granulomatous disease of the upper or lower respiratory tract, may not have a positive ANCA (Mukhtyar *et al.*, 2009). The 2012 Chapel Hill Consensus Conference definitions (Jennette *et al.*, 2013) suggest that patients with ANCA-negative ANCA-associated vasculitis may have ANCA that cannot be detected with current methods or may have ANCA of as yet undiscovered specificity, or that pathogenic mechanisms that do not involve ANCA at all may be occurring. Based on this concept, our data suggest that some patients with idiopathic hypertrophic pachymeningitis may be characterized as having a CNS-limited form of ANCA-associated vasculitis with seronegativity for MPO- or PR3-ANCA. It is possible that serological investigation of idiopathic hypertrophic pachymeningitis by indirect immunofluorescence microscopy identifies a new pattern of fixation and eventually a new antigen target. Further studies, including pathological and immunological assessments, are needed to reclassify patients with idiopathic hypertrophic pachymeningitis.

According to our data and previous single case reports, most patients with MPO-ANCA-positive hypertrophic pachymeningitis require treatment for combination therapy with prednisolone and other immunosuppressive agents such as cyclophosphamide (Sugiyama *et al.*, 1999; Takuma *et al.*, 2001; Akahoshi *et al.*, 2004; Furukawa *et al.*, 2004) or azathioprine (Nagashima *et al.*, 2000). The EULAR has recommended that patients with ANCA-associated vasculitis should be categorized according to different levels of severity to assist treatment decisions; a combination of cyclophosphamide and prednisolone should be used for remission and induction in patients with ANCA-associated vasculitis and renal or other organ threatening disease, whereas a combination of methotrexate and prednisolone should be used for remission and induction in patients with ANCA-associated vasculitis with non-organ threatening or non-life threatening disease (Mukhtyar *et al.*, 2009). Because elderly predominance is evident in immune-mediated or idiopathic hypertrophic pachymeningitis including MPO-ANCA-positive hypertrophic pachymeningitis based on this study, further studies investigating dose adjustment of cyclophosphamide based on age, alternative immunosuppressive agents such as methotrexate or azathioprine in patients with less severe disease, alternative immunomodulatory therapy

including intravenous immunoglobulin, rituximab or infliximab in patients with severe progressive disease, or remission-maintenance therapy are needed to clarify the details of management of the immune-mediated or idiopathic hypertrophic pachymeningitis.

There are several limitations to the study. First, the cohort was small ($n = 36$) and the follow-up period was short (median, 2.7 years). Second, pathological results were not always available because patients were often older with a higher risk of procedure-related complications. Even if available, pathological assessments were usually conducted using biopsy materials of thickened dura mater, but not autopsy materials, and pathological findings of vasculitis, necrosis and granulomatous inflammation together were seen in only 16% of biopsy specimens from head and neck lesions in patients with granulomatosis with polyangiitis (Devaney *et al.*, 1990; Bacon, 2005). Therefore, the 1994 Chapel Hill Consensus Conference definitions of the requirement for granulomatous inflammation in the definition of granulomatosis with polyangiitis did not necessarily indicate that histological proof of granulomatous inflammation would ultimately be a classification or diagnostic criterion for the disease (Jennette *et al.*, 1994). In this study, although we did not obtain histological proof of granulomatous inflammation in all patients with MPO-ANCA- and PR3-ANCA-positive hypertrophic pachymeningitis, we consider that our data assessing 36 patients with immune-mediated or idiopathic hypertrophic pachymeningitis and previous single case reports (Kono *et al.*, 2000; Nagashima *et al.*, 2000; Akahoshi *et al.*, 2004; Furukawa *et al.*, 2004; Liewluck *et al.*, 2008) can accurately be used to categorize and characterize disease profiles.

Our findings are consistent with a new concept that MPO-ANCA-positive hypertrophic pachymeningitis should be recognized as CNS-limited ANCA-associated vasculitis, consistent with the concept of ophthalmic-, pulmonary-, or renal-limited ANCA-associated vasculitis. MPO-ANCA-positive hypertrophic pachymeningitis may be a distinct disease subset from PR3-ANCA-positive hypertrophic pachymeningitis, according to the clinical, immunological, radiological and pathological features. In the future, prospective, long-term follow-up, and larger cohort studies are needed to further characterize the phenotype of patients and to determine beneficial treatments.

Acknowledgements

We wish to thank S. Kawaguchi and M. Kaneko (Department of Neurology, Brain Research Institute, Niigata University, Japan) for technical assistance.

Funding

This work was supported in part by a JSPS KAKENHI Grant Number 23591236 (I.K.), a Grant for the Promotion of Niigata University Research Projects (I.K.), and the Health and Labour Sciences Research Grant on Intractable Diseases (Neuroimmunological Diseases) from the Ministry of Health, Labour and Welfare of Japan (M.N.).

Supplementary material

Supplementary material is available at *Brain* online.

References

- Akahoshi M, Yoshimoto G, Nakashima H, Miyake K, Inoue Y, Tanaka Y, et al. MPO-ANCA-positive Wegener's granulomatosis presenting with hypertrophic cranial pachymeningitis: case report and review of the literature. *Mod Rheumatol* 2004; 14: 179–83.
- Aloisi F, Pujol-Borrell R. Lymphoid neogenesis in chronic inflammatory diseases. *Nat Rev Immunol* 2006; 6: 205–17.
- Armengol MP, Juan M, Lucas-Martin A, Fernandez-Figueras MT, Jaraquemada D, Gallart T, et al. Thyroid autoimmune disease: demonstration of thyroid antigen-specific B cells and recombination-activating gene expression in chemokine-containing active intrathyroidal germinal centers. *Am J Pathol* 2001; 159: 861–73.
- Bacon PA. The spectrum of Wegener's granulomatosis and disease relapse. *N Engl J Med* 2005; 352: 330–2.
- Baughman RP, Lower EE, du Bois RM. Sarcoidosis. *Lancet* 2003; 361: 1111–8.
- Bruggemann N, Gottschalk S, Holl-Ulrich K, Stewen J, Heide W, Seidel G. Cranial pachymeningitis: a rare neurological syndrome with heterogeneous aetiology. *J Neurol Neurosurg Psychiatry* 2010; 81: 294–8.
- Carrington C, Liebow A. Limited forms of angiitis and granulomatosis of Wegener's type. *Am J Med* 1966; 41: 497.
- Cartin-Ceba R, Peikert T, Specks U. Pathogenesis of ANCA-associated vasculitis. *Curr Rheumatol Rep* 2012; 14: 481–93.
- Chen M, Kallenberg CG. ANCA-associated vasculitides—advances in pathogenesis and treatment. *Nat Rev Rheumatol* 2010; 6: 653–64.
- Devaney KO, Travis WD, Hoffman G, Leavitt R, Lebovics R, Fauci AS. Interpretation of head and neck biopsies in Wegener's granulomatosis. A pathologic study of 126 biopsies in 70 patients. *Am J Surg Pathol* 1990; 14: 555–64.
- Fujimoto S, Watts RA, Kobayashi S, Suzuki K, Jayne DR, Scott DG, et al. Comparison of the epidemiology of anti-neutrophil cytoplasmic antibody-associated vasculitis between Japan and the U.K. *Rheumatology (Oxford)* 2011; 50: 1916–20.
- Furukawa Y, Matsumoto Y, Yamada M. Hypertrophic pachymeningitis as an initial and cardinal manifestation of microscopic polyangiitis. *Neurology* 2004; 63: 1722–4.
- Hellmich B, Flossmann O, Gross WL, Bacon P, Cohen-Tervaert JW, Guillevin L, et al. EULAR recommendations for conducting clinical studies and/or clinical trials in systemic vasculitis: focus on anti-neutrophil cytoplasm antibody-associated vasculitis. *Ann Rheum Dis* 2007; 66: 605–17.
- Holle JU, Gross WL, Holl-Ulrich K, Ambrosch P, Noelle B, Both M, et al. Prospective long-term follow-up of patients with localised Wegener's granulomatosis: does it occur as persistent disease stage? *Ann Rheum Dis* 2010; 69: 1934–9.
- Isa H, Lightman S, Luthert PJ, Rose GE, Verity DH, Taylor SR. Histopathological features predictive of a clinical diagnosis of ophthalmic granulomatosis with polyangiitis (GPA). *Int J Clin Exp Pathol* 2012; 5: 684–9.
- Ito-Ihara T, Muso E, Kobayashi S, Uno K, Tamura N, Yamanishi Y, et al. A comparative study of the diagnostic accuracy of ELISA systems for the detection of anti-neutrophil cytoplasm antibodies available in Japan and Europe. *Clin Exp Rheumatol* 2008; 26: 1027–33.
- Iwasaki S, Ito K, Sugawara M. Hypertrophic cranial pachymeningitis associated with middle ear inflammation. *Otol Neurotol* 2006; 27: 928–33.
- Jacobi D, Maillot F, Hommet C, Arsene S, Cottier JP, Lammie F, et al. P-ANCA cranial pachymeningitis: a case report. *Clin Rheumatol* 2005; 24: 174–7.

- Jennette JC, Falk RJ, Andrassy K, Bacon PA, Churg J, Gross WL, et al. Nomenclature of systemic vasculitides. Proposal of an international consensus conference. *Arthritis Rheum* 1994; 37: 187–92.
- Jennette JC, Falk RJ, Bacon PA, Basu N, Cid MC, Ferrario F, et al. 2012 revised international chapel hill consensus conference nomenclature of vasculitides. *Arthritis Rheum* 2013; 65: 1–11.
- Kono H, Inokuma S, Nakayama H, Yamazaki J. Pachymeningitis in microscopic polyangiitis (MPA): a case report and a review of central nervous system involvement in MPA. *Clin Exp Rheumatol* 2000; 18: 397–400.
- Kramer JA, Muller A, Herlyn K, Pitann S, Lamprecht P, Holl-Ulrich K, et al. B lymphocyte differentiation in granulomatous tissues of the lung and the nasal mucosa in Wegener's granulomatosis: origin of antineutrophil cytoplasmic antibody formation? *Z Rheumatol* 2007; 66: 421–9.
- Kupersmith MJ, Martin V, Heller G, Shah A, Mitnick HJ. Idiopathic hypertrophic pachymeningitis. *Neurology* 2004; 62: 686–94.
- Lamprecht P, Gross WL. Wegener's granulomatosis. *Herz* 2004; 29: 47–56.
- Lamprecht P, Kabelitz D. T-cells in ANCA-associated vasculitis. *Z Rheumatol* 2011; 70: 698–700.
- Leavitt RY, Fauci AS, Bloch DA, Michel BA, Hunder GG, Arend WP, et al. The American College of Rheumatology 1990 criteria for the classification of Wegener's granulomatosis. *Arthritis Rheum* 1990; 33: 1101–7.
- Liewluck T, Schatz NJ, Potter PF, Romaguera RL. Compressive retrobulbar optic neuropathy due to hypertrophic pachymeningitis. *Intern Med* 2008; 47: 1761–2.
- Lionaki S, Blyth ER, Hogan SL, Hu Y, Senior BA, Jennette CE, et al. Classification of antineutrophil cytoplasmic autoantibody vasculitides: the role of antineutrophil cytoplasmic autoantibody specificity for myeloperoxidase or proteinase 3 in disease recognition and prognosis. *Arthritis Rheum* 2012; 64: 3452–62.
- Luqmani RA, Exley AR, Kitis GD, Bacon PA. Disease assessment and management of the vasculitides. *Bailliere's clinical rheumatology* 1997; 11: 423–46.
- Lyons PA, Rayner TF, Trivedi S, Holle JU, Watts RA, Jayne DR, et al. Genetically distinct subsets within ANCA-associated vasculitis. *N Engl J Med* 2012; 367: 214–23.
- Mackiewicz Z, Rimkevicius A, Petersen J, Andersen CB, Dudek E, Vytrasova M, et al. Macrophages overloaded with tissue debris in Wegener's granulomatosis. *Ann Rheum Dis* 2005; 64: 1229–32.
- Magliozzi R, Howell O, Vora A, Serafini B, Nicholas R, Puopolo M, et al. Meningeal B-cell follicles in secondary progressive multiple sclerosis associate with early onset of disease and severe cortical pathology. *Brain* 2007; 130: 1089–104.
- Marsot-Dupuch K, Gayet-Delacroix M, Elmaleh-Berges M, Bonneville F, Lasjaunias P. The petrosquamosal sinus: CT and MR findings of a rare emissary vein. *AJNR Am J Neuroradiol* 2001; 22: 1186–93.
- Mukhtyar C, Guillevin L, Cid MC, Dasgupta B, de Groot K, Gross W, et al. EULAR recommendations for the management of primary small and medium vessel vasculitis. *Ann Rheum Dis* 2009; 68: 310–7.
- Muller A, Trabandt A, Gloeckner-Hofmann K, Seitzer U, Csernok E, Schonermarck U, et al. Localized Wegener's granulomatosis: predominance of CD26 and IFN-gamma expression. *J Pathol* 2000; 192: 113–20.
- Nagashima T, Maguchi S, Terayama Y, Horimoto M, Nemoto M, Nunomura M, et al. P-ANCA-positive Wegener's granulomatosis presenting with hypertrophic pachymeningitis and multiple cranial neuropathies: case report and review of literature. *Neuropathology* 2000; 20: 23–30.
- Nakamura T, Hirakawa K, Higashi S, Tomoda K, Tsukano M, Iyama K, et al. CD8+ T lymphocytes infiltrate predominantly in the inflammatory foci of MPO-ANCA-positive thoracic hypertrophic pachymeningitis in a patient with HLA-A24. *Mod Rheumatol* 2007; 17: 75–80.
- Neogi T, Aletaha D, Silman AJ, Naden RL, Felson DT, Aggarwal R, et al. The 2010 American College of Rheumatology/European League Against Rheumatism classification criteria for rheumatoid arthritis: Phase 2 methodological report. *Arthritis Rheum* 2010; 62: 2582–91.
- Pfister H, Ollert M, Frohlich LF, Quintanilla-Martinez L, Colby TV, Specks U, et al. Antineutrophil cytoplasmic autoantibodies against the murine homolog of proteinase 3 (Wegener autoantigen) are pathogenic in vivo. *Blood* 2004; 104: 1411–8.
- Ralston DR, Marsh CB, Lowe MP, Wewers MD. Antineutrophil cytoplasmic antibodies induce monocyte IL-8 release. Role of surface proteinase-3, alpha1-antitrypsin, and Fc gamma receptors. *J Clin Invest* 1997; 100: 1416–24.
- Salomonsson S, Jonsson MV, Skarstein K, Brokstad KA, Hjelmstrom P, Wahren-Herlenius M, et al. Cellular basis of ectopic germinal center formation and autoantibody production in the target organ of patients with Sjogren's syndrome. *Arthritis Rheum* 2003; 48: 3187–201.
- Smirniotopoulos JG, Murphy FM, Rushing EJ, Rees JH, Schroeder JW. Patterns of contrast enhancement in the brain and meninges. *Radiographics* 2007; 27: 525–51.
- Sugiyama Y, Shimizu M, Hoshi A, Aoki T, Matsuura Y, Tochikubo S, et al. An old man presenting with fluctuating bilateral multiple cranial nerve palsies and positive test for perinuclear antineutrophil cytoplasmic antibody. *No To Shinkei* 1999; 51: 825–32.
- Takemura S, Braun A, Crowson C, Kurtin PJ, Cofield RH, O'Fallon WM, et al. Lymphoid neogenesis in rheumatoid synovitis. *J Immunol* 2001; 167: 1072–80.
- Takuma H, Shimada H, Inoue Y, Ishimura E, Himuro K, Miki T, et al. Hypertrophic pachymeningitis with anti-neutrophil cytoplasmic antibody (p-ANCA), and diabetes insipidus. *Acta Neurol Scand* 2001; 104: 397–401.
- Umehara H, Okazaki K, Masaki Y, Kawano M, Yamamoto M, Saeki T, et al. Comprehensive diagnostic criteria for IgG4-related disease (IgG4-RD), 2011. *Mod Rheumatol* 2012; 22: 21–30.
- van Swieten JC, Koudstaal PJ, Visser MC, Schouten HJ, van Gijn J. Interobserver agreement for the assessment of handicap in stroke patients. *Stroke* 1988; 19: 604–7.
- Watts R, Lane S, Hanslik T, Hauser T, Hellmich B, Koldingsnes W, et al. Development and validation of a consensus methodology for the classification of the ANCA-associated vasculitides and polyarteritis nodosa for epidemiological studies. *Ann Rheum Dis* 2007; 66: 222–7.
- Xiao H, Heeringa P, Hu P, Liu Z, Zhao M, Aratani Y, et al. Antineutrophil cytoplasmic autoantibodies specific for myeloperoxidase cause glomerulonephritis and vasculitis in mice. *J Clin Invest* 2002; 110: 955–63.