

Hypoglycemic and Hepatoprotective Effects of Processed *Aloe vera* Gel in a Mice Model of Alloxan Induced Diabetes Mellitus

Bhaskar Sharma^{1*}, Sufiyan Siddiqui¹, Gurudayal Ram¹, Manisha Chaudhary¹ and Gaurav Sharma²

¹Department of Biochemistry, Sam Higginbottom Institute of Agriculture, Technology & Sciences, Allahabad, India

²Suresh Gyan Vihar University, Jaipur, India

Abstract

Diabetes mellitus is a heterogeneous disease characterized by altered cellular metabolism. So many traditional herbs are being used by diabetic patients to control this disease. The aim of this study was to investigate the effects of aqueous extract of *aloe vera* leaves on hypoglycemic activity and hepatoprotective effects after alloxan injection in Swiss albino mice. In this study, aqueous leaf extract of *aloe vera* was carried out. Diabetes was induced in mice by alloxan monohydrate at dose of 150 mg/kg body weight injected intraperitoneally. Also alloxanized induced mice were administered with 300 and 500 mg/kg body weight orally daily of extract for a period of 21 days. At the end of the administration period, the mice were anaesthetized and dissect for the collection of blood and liver tissues. In diabetic mice, the SGOT, SGPT and bilirubin level as well as serum glucose levels were significantly increased ($p < 0.05$) in comparison with the control groups. Diabetic mice group treated by extract at the dose of 300 and 500 mg/kg body weight orally significantly ($p < 0.05$) reduced and normalised these biochemical parameters compared with alloxan induced diabetic group. Histopathological study also did show adverse alternation in the morphological architecture of the liver tissue. The results suggested that aqueous extract of *aloe vera* leaves possesses protective effect against alloxan induced diabetic mice.

Keywords: Aqueous leaf extract of *aloe vera*; Alloxanized diabetes; Bilirubin

Abbreviations: SGOT: Serum Glutamate Oxaloacetate Transaminase; SGPT: Serum Glutamate Pyruvate Transaminase

Introduction

Diabetes mellitus (DM) has been defined by a persistently elevated blood glucose concentration, leading to complications that can be acute and long term [1]. Globally, DM presents enormous and increasingly important public health issues. The prevalence of DM in all age groups was estimated to be 2.8% (170 million) in 2000 and the rate is expected to rise to 4.4% (366 million) in 2030 [2]. The occurrence and consequences associated with diabetes are found to be high in countries like India (31.7%), China (20.8%) and USA (17.7%). The rate is expected to rise to 79.4%, 42.3% and 30.3%, respectively, by 2030 in the above countries [3]. The worldwide survey on diabetes reveals that among the entire diabetes cases more than 90% are account to type-II [4]. The overall death rate in people with diabetes is about twice that of people without diabetes [5].

The mechanism of alloxan action has been intensively studied, predominantly *in vitro*, and is now characterized quite well. Using isolated islets [6] and perfused rat pancreas [7] it was demonstrated that alloxan evokes a sudden rise in insulin secretion in the presence or absence of glucose. This phenomenon appeared just after alloxan treatment and was not observed after repetitive exposure of islets to this diabetogenic agent [6]. The sudden rise in blood insulin concentration was also observed *in vivo* just after alloxan injection to rats [8]. Alloxan-induced insulin release is, however, of short duration and is followed by complete suppression of the islet response to glucose even when high concentrations (16.6 mM) of this sugar were used [7]. The action of alloxan in the pancreas is preceded by its rapid uptake by the β -cells [9,10]. Rapid uptake by insulin-secreting cells has been proposed to be one of the important features determining alloxan diabetogenicity.

The diabetogenic agent, alloxan, is a hydrophilic and chemically unstable compound. The logarithm of the octanol/water partition

coefficient of alloxan was found to be -1.86; its half-life at pH 7.4 and 37°C in phosphate buffer was 1.5 min. The partition coefficients and half-lives of the alloxan reduction products, alloxantin and dialuric acid, were very similar to those of the parent compound; N-methylalloxan and N,N'-dimethylalloxan were less hydrophilic but more unstable. Alloxan and its N-methyl derivatives were reduced by thiols and in the presence of glutathione and cysteine, rapid redox cycling occurred, with formation of 'active oxygen' species [11]. On the other hand, when a diabetogenic dose is used, the time of alloxan decomposition is sufficient to allow it to reach the pancreas in amounts that are deleterious [12].

Insulin therapy and oral hypoglycaemic agents offer effective glycaemic control, but insulin therapy has shortcomings such as ineffectiveness following oral administration, short shelf life, the need for constant refrigeration, and fatal hypoglycaemia, in the event of excess dosage [13]. As a result, there is a need to search for compounds with effective antidiabetic activity when taken orally. The oral hypoglycemic agents that are capable of reducing blood sugar level belong to two chemical classes; sulfonylureas and biguanides [14].

However, the use of oral anti-diabetics is limited due to their adverse side effects including hematological, cutaneous and gastrointestinal

***Corresponding author:** : Bhaskar Sharma, Department of Biochemistry, Sam Higginbottom Institute of Agriculture, Technology & Sciences, Allahabad- 211008, U.P, India, Tel: +91-9696907157/+91- 8005319392; E-mail: : reserachpaper26@gmail.com

Received August 17, 2013; **Accepted** October 19, 2013; **Published** October 24, 2013

Citation: Sharma B, Siddiqui S, Ram G, Chaudhary M, Sharma G (2013) Hypoglycemic and Hepatoprotective Effects of Processed *Aloe vera* Gel in a Mice Model of Alloxan Induced Diabetes Mellitus. J Diabetes Metab 4: 303. doi:10.4172/2155-6156.1000303

Copyright: © 2013 Sharma B, et al. This is an open-access article distributed under the terms of the Creative Commons Attribution License, which permits unrestricted use, distribution, and reproduction in any medium, provided the original author and source are credited.

reactions, hypoglycaemic coma and disturbances of liver and kidney functions. In addition, they are not suitable for use during pregnancy. The beneficial uses of medicinal plants in traditional system of medicine of many cultures are extensively documented. Several plants have been used as dietary adjuvant and in treating the number of diseases even without any knowledge on their proper functions and constituents. This practice may be attributed to the uncompromised cost and side effects of synthetic hypoglycemic agents [15]. Since antique era, plants with medicinal properties are enormously used in treating diabetes throughout the world. Many recent scientific investigations have also confirmed the efficacy of plant preparations, few of which are remarkably effective [16]. *Aloe vera* is a traditional remedy for diabetes mellitus (DM) in many parts of the world, including Latin America [17] and the Arabian Peninsula [18]. Some evidence in humans and animals suggests that *Aloe vera* is able to alleviate the chronic hyperglycemia and perturbed lipid profile that are characteristic of DM, which are major risk factors for cardiovascular complications in the disease. Present study was therefore aimed to investigate the anti hyperglycemic and anti hepatoprotectivity effect of aqueous extract of *aloe vera* leaf against alloxan induced diabetic mice.

Material and Methods

Plant material

The basic plant material of *aloe vera* leaves used for the investigation was obtained from local garden (Allahabad, U.P). The plant can be identified authenticated by Department of Botany, Sam Higginbottom Institute of Agriculture, Technology & Sciences, Allahabad, UP (India).

Preparation of plant extract

The fresh leaves of *aloe vera* were collected, washed with distilled water and shadow dried. The shadow dried leaves of *aloe vera* were subjected to pulverization to get coarse powder. Aqueous extract was made by dissolving it in distilled water using by mortar and pestle. The dose was finally made to 300 mg/kg and 500 mg/kg body weight for oral administration after the LD₅₀ estimation.

Maintenance of animals and approval of protocol

Healthy Swiss albino mice (*Mus musculus*) (4-6 months old, weighing 28-32 g). They were maintained in an air-conditioned experimental room at 12 hour light: dark cycles. The animals were randomized into experimental and control groups and were housed in a polypropylene cage. Standard pellets were used as a basal diet during the experimental period. The control and experimental animals were provided with purified drinking water ad libitum. The animals were maintained in accordance with the "CPCSEA guidelines for laboratory animal facility" (Committee for the Purpose of Control and Supervision on Experiments on Animals) and the approval number is (CPCSEA Regd. No. 1129/bc/07/CPCSEA, dated 13/02/2008). Before starting the experiment the animals were carefully marked on different parts of their body, which was later used as identification mark for a particular animal, so that the response of a particular mouse prior to and after the administration could be noted separately.

Acute oral toxicity studies

Aloe vera at the dose range of 100-2000 mg/kg body weight oral gavage administration different group of mice comprised of 6 mice in each group. Animals were kept under close observation for 4 hours after administering the fraction for behavior, neurological and autonomic profile and then observed for any change in the general behavior and

/ or physical activities, mortality were recorded within 72 hours. Acute toxicity was determined according to the method of Lorke [19].

Experimental design

Four groups of mice, six mice in each received the following treatment schedule.

Group I: Normal control (saline)

Group II: Alloxan treated control (150 mg/kg body weight i.p)

Group III: Alloxan (15 mg/kg body weight i.p) + *aloe vera* (leaf extract at the dose of 300 mg/kg b.w).

Group IV: Alloxan (150 mg/kg body weight i.p) + *aloe vera* (leaf extract at the dose of 500 mg /kg b.w).

Aloe vera leaf extract and saline were administered by Gavage's method. Group I serve as normal control, which received saline for 21 days. Group II to Group IV diabetic control mice (which previously received alloxan) are given fixed dose *aloe vera* leaf extract (300 mg/kg b.w and 500 mg/kg b.w) for 21 consecutive days.

Induction of diabetes to test animals

The selected mice were weighed, marked for individual identification and fast for overnight. The alloxan monohydrates at the rate of 150 mg/kg body weight [12] were administered intraperitoneal (i.p) for making the alloxan induced diabetic mice model. Blood glucose level of these mice were estimated 72 hr after alloxan administration, diabetes was confirmed by blood samples collected from the tip of the tail using a blood glucometer (Accusure, Taiwan). Animals with blood glucose level equal or more than 200 mg/dl were declared diabetic and were used in entire experimental group [20].

Collection and analyses of blood

After the last dose, animals were fasted for 12 hours and sacrificed. Blood samples were collected by orbital sinus puncture method [21]. Serum was prepared following procedure. Briefly, blood samples were withdrawn from orbital sinus using non-heparinised capillary tubes, collected in dried centrifuge tubes and allowed to clot. Serum was separated from the clot by centrifuged at 3000 rpm for 15 min at room temperature. Serum was collected carefully and kept at -20°C until analysis Glucose [22]. Glutamic Pyruvate Transaminase (SGPT) and Serum Glutamic Oxaloacetate Transaminase (SGOT) activities were measured according to the method described by [23] while Bilirubin [24] activity were measured.

Histopathological studies

A portion of the liver was cut into two to three pieces of approximately 6 mm³ sizes and fixed in 10% formaldehyde solution. After embedding in paraffin wax, thin sections of 5 μm thickness of liver tissue were cut and stained with haematoxylin-eosin. The thin sections of liver were made into permanent slides and examined [25] under high resolution microscope with photographic facility and photomicrographs were taken.

Statistical analysis

Results were presented as mean ± S.D and total variation present in a set of data was analysed through one-way analysis of variance (ANOVA). Difference among means had been analysed by applying Tukey's multiple comparison test at 95% ($p < 0.05$) confidence level. Calculations were performed with the GraphPad Prism Program (GraphPad Software, Inc., San Diego, USA).

Results

Serum glucose level

The effect of aqueous extract of *aloe vera* leaf on blood glucose levels is shown in Figure 1. The mean level of glucose in the control group of mice was evaluated to be 77.24 ± 6.78 mg/dl (range 70- 88.98) whereas it was 226.4 ± 8.88 mg/dl (range values 215 to 239, 95% CI of differences from -163.1 to -135.2 respectively) in alloxanized group. After the treatment of mice with the leaf extract of *aloe vera* (300 mg/kg body weight) the glucose level decreased down to 117.2 ± 12.17 mg/dl (95% CI- 95.25 to 123.2) having a range of 102-132 mg/dl and at the dose of 500 mg/kg body weight of extract the level of glucose also significantly decreased to 98.06 ± 5.06 mg/dl (95% CI- 114.4 to 142.3) having range of 89.09-103 mg/dl. These variations in glucose concentrations are evident from Figure 1. The significant increase in glucose concentration in the diabetic animals than that of the control mice is evident on alloxanization. However, the oral administration of aqueous extract of *aloe vera* significantly reduced the glucose level in serum when compared with alloxan induced diabetic mice.

Serum Glutamate Oxaloacetate Transaminase (SGOT)

In Control group of mice SGOT activity was found to be 23 ± 3.16 IU/ml having the range of 20 to 32 IU/ml. In diabetics, its activity got raised to 40.12 ± 2.40 IU/ml (95% CI of differences value from -21.81 to -12.42) with variations range from 37.80 to 43.90. However, extract (300 and 500 mg/kg b.w) treatment of this group for three weeks resulted in decrease of SGOT activity to 35 ± 2.68 and 30 ± 3.28 (95% CI- 0.4199 to 9.813 and 5.420 to 14.81) having values ranging from 31.98 to 39.98 IU/ml and 25 to 34 IU/ml. These variations are depicted by the box-plot in Figure 2.

Serum Glutamate Pyruvate Transaminase (SGPT)

In control mice group SGPT activity was found to be 21 ± 2.00 having range values between 19 to 24 IU/ml. In diabetics, mean value was 40.67 ± 3.01 with ranging from 37 to 45 IU/ml (95% CI of differences value from -24.07 to -15.26) in diabetic mice. However, after the treatment of mice with the leaf extract of *aloe vera* (300 and 500 mg/kg b.w), the activity decreased down to 34.82 ± 3.58 and 28.17 ± 1.94

(ranging between 30.71 to 40.01 and 25 to 30) IU/ml and 95% CI- 1.448 to 10.25 and 8.098 to 16.90. These values are compared by the box-plot as evident in Figure 3.

Bilirubin levels in various groups

Bilirubin level of control mice was observed to be 0.55 ± 0.043 mg/dl (values ranging between 0.49 and 0.60) which got increased to 0.92 ± 0.043 mg/dl in alloxan induced diabetic mice. Bilirubin contents ranged from 0.87 to 1.00 (95% CI of differences value from -0.4427 to -0.2973) in diabetic mice. However, after the treatment of diabetic mice with the leaf extract of *aloe vera* at the dose of 300 and 500 mg/kg b.w, the bilirubin level decreased down to the mean value of 0.72 ± 0.035 and 0.64 ± 0.55 (95% CI of differences value- 0.1273 to 0.2727 and 0.2023 to 0.3477) having values ranging from 0.69 to 0.78 mg/dl, 0.50 to 0.72 mg/dl. These variations along with statistical significance are depicted by box-plot as shown in Figure 4.

Histopathology

Figures 5 and 6 Show histological section of the liver tissue of the

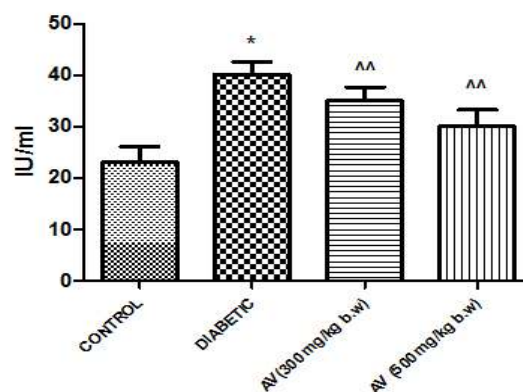


Figure 2: Effect of *Aloe vera* (AV) on diabetic induced group showing Serum Glutamate Oxaloacetate Transaminase level (n=6, values are mean ± S.D). * p<0.05 (as compared to control group), p<0.05 (as compared to diabetic group).

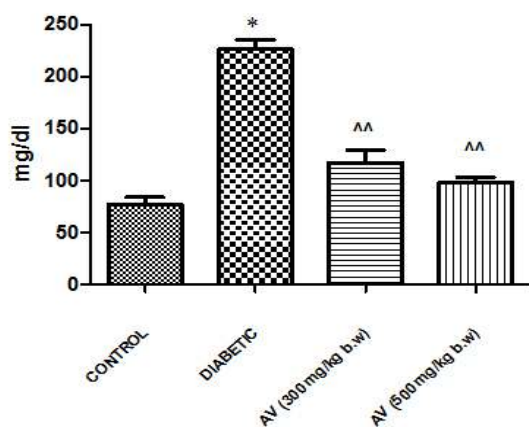


Figure 1: Effect of *Aloe vera* (AV) on diabetic induced group showing serum glucose level (n=6, values are mean ± S.D). p<0.05(as compared to control group), p<0.05 (as compared to diabetic group).

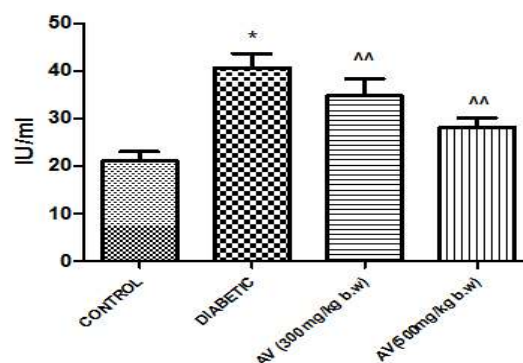


Figure 3: Effect of *Aloe vera* (AV) on diabetic induced group showing Serum glutamate pyruvate transaminase level (n=6, values are mean ± S.D). * p<0.05 (as compared to control group), p<0.05 (as compared to diabetic group).

control and diabetic group mice, while Figure 7 shows the histological section of the liver tissue of the extract treated. The liver section of the animal in control groups showed a central vein with prominent small-sized nuclei, with the hepatocytes well arranged in sinusoids. While the tissue section of the diabetic group showed abnormal central vein with a relatively large sized nuclei also, the hepatocytes are not well arranged in sinusoids in the diabetic mice. Liver section of extract group showed that the central vein is towards normal, hepatocytes well preserved and the sinusoids well demarcated.

Discussion

Plants generally have varied chemical compositions depending upon species. A good number of plants are known to be of economic and medicinal value. Those that are of medicinal value are often used as herbal remedy for the restoration and maintenance of good health. Some herbs have been considered as drugs and therefore generally safe and effective. Most herbs have been associated with broad actions on a number of physiological systems in concert unlike the pharmaceutical drugs which are usually designed to elicit a specific effect. Some researchers on medicinal plants are of the opinion that some herbal plants are usually oriented in the same general therapeutic direction

and are complementary or synergistic, often non-specific but very rarely adverse [26]. Medicinal plants are being used traditionally in many parts of the world in the treatment of diabetes mellitus where access to formal healthcare is limited [27] and these medicinal plants could play important roles in the lives of rural people, particularly those in remote parts of developing countries.

The present work was aimed to study the anti-hyperglycemic activity of *aloe vera* in alloxan induced diabetic mice. The results of this study revealed that aloe vera at the dose of 300 and 500 mg/kg body weight significantly normalized the elevated blood glucose level and restored serum marker enzymes toward normal values.

Alloxan is the most commonly employed agent for the induction of diabetes in experimental animal model. There is increasing evidence that alloxan causes diabetes by rapid depletion of β - cells by DNA alkylation and accumulation of cytotoxic free radicals that is suggested to result from initial islet inflammation, followed by infiltration of activated macrophages and lymphocyte in the inflammatory focus. It leads to a reduction in plasma insulin concentration leading to a stable hyperglycemia state [12]. Hyperglycemia was observed after 3

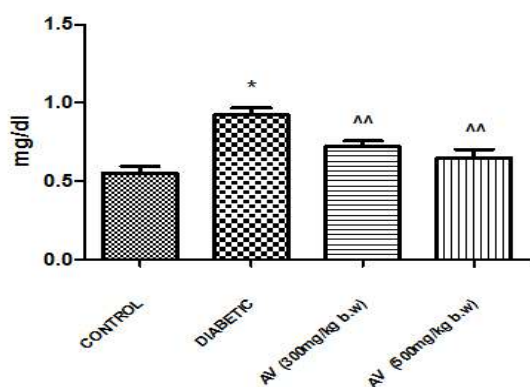


Figure 4: Effect of *Aloe vera* (AV) on diabetic induced group showing bilirubin level (n=6, values are mean \pm S.D). * p<0.05 (as compared to control group), ^^ p<0.05 (as compared to diabetic group)

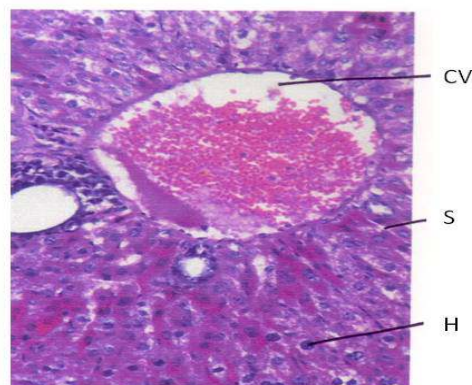


Figure 6: In diabetic mice liver section showed abnormal structure of central vein (CV), sinusoid (S) and hepatocyte (H) are not arranged in sinusoid, cytoplasm is vacuolated (H and Ex 200).

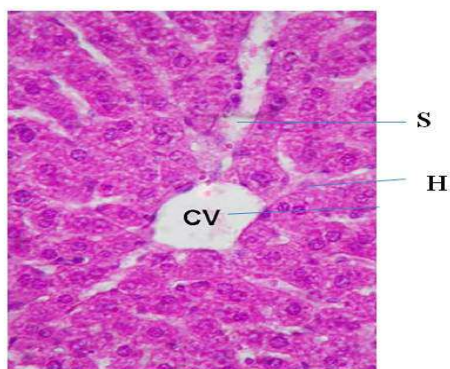


Figure 5: In control mice liver section showed normal structure of central vein (CV), hepatocytes (H) well preserved and essentially normal, cytoplasm not vacuolated, sinusoid (S) well demarcated (H and Ex 200).

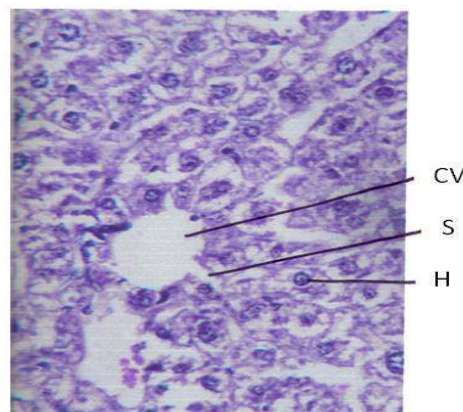


Figure 7: In *aloe vera* mice liver section showed towards normal structure of central vein (CV), sinusoid (S) and also arranged hepatocyte (H) in sinusoid. Cytoplasm not vacuolated (H and Ex 200).

days of alloxan induction. Treatment of *aloe vera* in alloxan induced diabetic mice started reducing glucose level. The antihyperglycemic effect of *aloe vera* at 500 mg/kg b.w dose was found to be more effect than 300 mg/kg b.w. This results are agree with another finding [28-31]. In this respect, Ayesha et al. [32] reported that there are two possible explanations for the antidiabetic property of *aloe barbadensis*. It may have exerted its effect by preventing the death of β -cells and it may permit recovery of partially destroyed β -cells, *aloe vera* may also have initiated cell proliferation.

The liver is the most vital organ for the metabolism of drugs and other toxicants. The destruction of the liver cell results in the impairment of the liver cell membrane permeability which results in the leakage of tissue contents into the blood stream [33]. In addition, physical trauma or disease process can cause lyses, resulting in the release of these intracellular enzymes into the blood. It has been reported that the liver is necrotized in diabetic rats which leads to increased activities of SGOT, SGPT enzymes as they leak from the liver cytosol into the blood stream [33] and this is also an indicator of the hepatotoxicity of alloxan. Therefore, in the present experiment, elevation of serum biomarker enzymes such as SGOT and SGPT was observed in diabetic mice as compared to normal group, these increment is mainly due to the leakage of these enzymes from the liver cytosol into the blood stream [34,35]. On the other hand, the oral administration of *aloe vera* at the dose of 300 and 500 mg/kg b.w for 21 days, the elevated level were significantly decreased. Similar effects through various other medicinal plants have been well observed [36,37].

Furthermore, the improvement of the liver damage by oral administration of *aloe vera* could be confirmed by studying their effects on the level of serum bilirubin. Bilirubin in the body maintains balance between production and removal of pigments in body. Hyper bilirubemia results from the overproduction or impaired uptake, conjugation or excretion/regurgitation of unconjugated or conjugated bilirubin from hepatocytes and its release to bile ducts. Our present result showed that the experimentally induced diabetes increased the level of serum bilirubin compare to the control [38].

Also, the elevation in serum bilirubin indicates liver damage as confirmed by the changes in the activities of liver enzymes (SGOT and SGPT). Thus, the increased level of bilirubin observed in mice in diabetic control group could be attributed to liver damage. However, the decrease in bilirubin levels in treated mice is indicative of reversal of liver damage by *aloe vera* [39,40].

Conclusion

Thus, from the present study it can be concluded that administration of *aloe vera* significantly reduced the of serum glucose level as well as showed the hepatoprotective effect in alloxan induced diabetic mice. In the light of our pharmacological studies the study of *aloe vera* extract might offer a natural key of hypoglycaemic and hepatoprotective activity. Further chemical and pharmacological investigations are in progress to elucidate in detail the active principles and the exact mechanism of action.

Acknowledgement

The authors wish to thank the management of Mahavir Cancer Institute and Research Centre for providing the necessary facilities for the completion of this study. We are also grateful to the Head (Research section) Mahavir Cancer Institute and Research Centre, Phulwarisharif, Patna for permitting us to utilize their animal house facility to conduct this study.

References

- Greenbaum CJ, Harrison LC (2008) Diabetes: Translating Research into Practice. Informa Health Care, New York, London: 1-2.
- Fonseca VA (2006) Clinical Diabetes: Translating Research into Practice. Saunders – An Imprint of Elsevier: 2-3.
- Wild S, Roglic G, Green A, Sicree R, King H (2004) Global prevalence of diabetes: estimates for the year 2000 and projections for 2030. Diabetes Care 27: 1047-1053.
- Centres for Disease Control and Prevention (2005) National Diabetes Fact sheet, 2005.
- Harrigan RA, Nathan MS, Beattie P (2001) Oral agents for the treatment of type 2 diabetes mellitus: pharmacology, toxicity, and treatment. Ann Emerg Med 38: 68-78.
- Weaver DC, McDaniel ML, Naber SP, Barry CD, Lacy PE (1978) Alloxan stimulation and inhibition of insulin release from isolated rat islets of Langerhans. Diabetes 27: 1205-1214.
- Kliber A, Szkudelski T, Chichowska J (1996) Alloxan stimulation and subsequent inhibition of insulin release from in situ perfused rat pancreas. J Physiol Pharmacol 47: 321-328.
- Weaver DC, McDaniel ML, Lacy PE (1978) Alloxan uptake by isolated rat islets of Langerhans. Endocrinology 102: 1847-1855.
- Szkudelski T, Kandulska K, Okulicz M (1998) Alloxan in vivo does not only exert deleterious effects on pancreatic B cells. Physiol Res 47: 343-346.
- Boquist L, Nelson L, Lorentzon R (1983) Uptake of labeled alloxan in mouse organs and mitochondria in vivo and in vitro. Endocrinology 113: 943-948.
- Lenzen S, Munday R (1991) Thiol-group reactivity, hydrophilicity and stability of alloxan, its reduction products and its N-methyl derivatives and a comparison with ninhydrin. Biochem Pharmacol 42: 1385-1391.
- Szkudelski T (2001) The mechanism of alloxan and streptozotocin action in B cells of the rat pancreas. Physiol Res 50: 537-546.
- Anuradha CV, Ravikumar P (2001) Restoration on tissue antioxidants by fenugreek seeds (*Trigonella Foenum Graecum*) in alloxan-diabetic rats. Indian J Physiol Pharmacol 45: 408-420.
- Trejo-González A, Gabriel-Ortiz G, Puebla-Pérez AM, Huízar-Contreras MD, Munguía-Mazariegos MR, et al. (1996) A purified extract from prickly pear cactus (*Opuntia fuliginosa*) controls experimentally induced diabetes in rats. J Ethnopharmacol 55: 27-33.
- Taylor JB, Triggler DJ (2006) Comprehensive Medicinal Chemistry – II. global perspective, Text Book 1: 357.
- Marles RJ, Farnsworth NR (1995) Antidiabetic plants and their active constituents. Phytomedicine 2: 133-169.
- Coronado GD, Thompson B, Tejada S, Godina R (2004) Attitudes and beliefs among Mexican Americans about type 2 diabetes. J Health Care Poor Underserved 15: 576-588.
- Yeh GY, Eisenberg DM, Kaptchuk TJ, Phillips RS (2003) Systematic review of herbs and dietary supplements for glycemic control in diabetes. Diabetes Care 26: 1277-1294.
- Lorke D (1983) A new approach to practical acute toxicity testing. Arch Toxicol 54: 275-287.
- Lenzen S (2008) The mechanisms of alloxan- and streptozotocin-induced diabetes. Diabetologia 51: 216-226.
- van Herck H, Baumans V, Brandt CJ, Hesp AP, Sturkenboom JH, et al. (1998) Orbital sinus blood sampling in rats as performed by different animal technicians: the influence of technique and expertise. Lab Anim 32: 377-386.
- Veiga F, Fernandes C, Teixeira F (2000) Oral bioavailability and hypoglycaemic activity of tolbutamide/cyclodextrin inclusion complexes. Int J Pharm 202: 165-171.
- REITMAN S, FRANKEL S (1957) A colorimetric method for the determination of serum glutamic oxalacetic and glutamic pyruvic transaminases. Am J Clin Pathol 28: 56-63.
- Jendrassik L, Grof (1938) Vereinfachte, Photometrische Methoden zur Bestimmung des Blubilirubins, Biochem Z 297: 81-89.
- Kleiner DE, Brunt EM, Van Natta M, Behling C, Contos MJ, et al. (2005) Design

- and validation of a histological scoring system for non alcoholic fatty liver disease. *Hepatology* 41: 1313-1321.
26. Uboh FE, Okon IE, Ekong MB (2010) Effect of aqueous extract of psidium guajava Leaves on liver Enzymes, histological integrity and hematological indices in Rats. *Gastroentology Research* 3: 32-38.
 27. Pushparaj P, Tan CH, Tan BK (2000) Effects of Averrhoa bilimbi leaf extract on blood glucose and lipids in streptozotocin-diabetic rats. *J Ethnopharmacol* 72: 69-76.
 28. Adesokan AA, Akanji MA, Aderibigbe A (2006) Serum glucose and lipid levels in alloxan-induced diabetic rats following oral administration of aloe barbadensis miller juice extract. *Tropical Journal of Health Sciences* 13: 11-14.
 29. Chacko SM, Sabitha T, Kuttan R (2008) Amelioration of alloxan-induced hyperglycaemia by aloe arborescens miller. And its possible mechanism. *Pharmacologyonline* 2: 112-125.
 30. Mohamed EAK (2011) Antidiabetic, antihypercholesterolemic and antioxidative effect of aloe vera gel extract in alloxan induced diabetic rats. *Aus J Basic Appl Sci* 5: 1321- 1327.
 31. Matheka DM, Alkizim FO (2012) Complementary and alternative medicine for type 2 diabetes mellitus: Role of medicinal herbs. *Journal of Diabetes and Endocrinology* 3: 44-56.
 32. Ayesha Noor S, Gunasekaran A, Manickam S, Vijayalakshmi MA (2008) Antidiabetic activity of aloe vera and histology of organs in streptozotocin induced diabetic rats. *Curr Sci* 94: 1070-1076.
 33. Saeed MK, Deng Y, Dai R (2008) Attenuation of Biochemical Parameters in Streptozotocin-induced Diabetic Rats by Oral Administration of Extracts and Fractions of *Cephalotaxus sinensis*. *J Clin Biochem Nutr* 42: 21-28.
 34. Whitehead MW, Hawkes ND, Hainsworth I, Kingham JG (1999) A prospective study of the causes of notably raised aspartate aminotransferase of liver origin. *Gut* 45: 129-133.
 35. Mansour HA, Newairy AS, Yousef MI, Sheweita SA (2002) Biochemical study on the effects of some Egyptian herbs in alloxan-induced diabetic rats. *Toxicology* 170: 221-228.
 36. Adesokan AA, Oyewole OI, Turay BMS (2009) Kidney and liver function parameters in alloxan-induced diabetic rats treated with aloe barbadensis juice extract. *Sierra Leone Journal of Biomedical Research* 1: 33-37.
 37. Arun Kumar, Bhaskar Sharma, Mohammad Ali, Ranjit Kumar, Nath A, et al. (2013) *Momordica charantia* Protects the liver from hyperglycemia induced toxicity during Diabetes in Swiss Albino Mice. *Open Access Scientific Reports* 2: 599.
 38. El-Demerdash FM, Yousef MI, El-Naga NI (2005) Biochemical study on the hypoglycemic effects of onion and garlic in alloxan-induced diabetic rats. *Food Chem Toxicol* 43: 57-63.
 39. Agarwal V, Sharma AK, Upadhyay A, Singh G, Gupta R (2012) Hypoglycemic effects of *Citrullus colocynthis* roots. *Acta Pol Pharm* 69: 75-79.
 40. Viridi J, Sivakami S, Shahani S, Suthar AC, Banavalikar MM, et al. (2003) Antihyperglycemic effects of three extracts from *Momordica charantia*. *J Ethnopharmacol* 88: 107-111.