

Hypothyroidism: morphological and metabolic changes in the testis of adult albino rat and the amelioration by alpha-lipoic acid

A.A. Ibrahim¹, N.A. Mohammed², K.A. Eid³ , M.M. Abomughaid⁴, A.M. Abdelazim^{4, 5} ,
A.M. Aboregela^{1, 6} 

¹Human Anatomy and Embryology Department, Faculty of Medicine, Zagazig University, Zagazig, Egypt

²Medical Physiology Department, Faculty of Medicine, Zagazig University, Zagazig, Egypt

³House Officer, Faculty of Medicine, Zagazig University, Zagazig, Egypt

⁴Laboratory Medical Sciences, College of Applied Medical Sciences, University of Bisha, Saudi Arabia

⁵Biochemistry Department, Faculty of Veterinary Medicine, Zagazig University, Zagazig, Egypt

⁶Basic Medical Sciences, College of Medicine, University of Bisha, Saudi Arabia

[Received: 6 June 2020; Accepted: 29 June 2020]

Background: The objective of this study is to evaluate the influence of carbimazole-induced hypothyroidism on the testes of adult albino rats and the probable protective effect of alpha-lipoic acid (ALA).

Materials and methods: The rats were divided into four groups; control group, ALA group, carbimazole, and carbimazole + ALA groups. Rats were exposed to ALA (60 mg/kg body weight) or carbimazole (1.35 mg/kg body weight), or both, administered via gavages for 30 days.

Results: Morphometric analysis revealed a significant decrease in tubular diameter, germinal epithelium thickness, and interstitial space as compared to the controls. Also, rats exposed to carbimazole showed a significant decline in testicular weight, sperm motility, and count. Additionally, deterioration of the testicular architecture was observed. ALA supplementation resulted in a significant improvement in the tubular diameter and germinal epithelium thickness, but no significant improvement regarding interstitial space was observed. Another observation was the significant decline in serum testosterone and follicle-stimulating hormone (FSH) in the carbimazole group, indicating reduced steroidogenesis. A significant reduction in reduced glutathione content was detected in the testes of the carbimazole group compared with the controls, while malonaldehyde concentration significantly increased. Conversely, ALA supplementation ameliorated the toxicity induced by hypothyroidism as illustrated by enhanced reproductive organ weights, testosterone, luteinizing hormone, and FSH levels, testicular steroidogenesis, and oxidative stress parameters.

Conclusions: Hypothyroidism altered testicular antioxidant balance and negatively affected spermatogenesis. On the other hand, ALA through its antioxidant properties alleviated testicular toxicity in carbimazole-exposed rats. (Folia Morphol 2021; 80, 2: 352–362)

Key words: alpha-lipoic acid, carbimazole, hypothyroidism, testis, rat

Address for correspondence: Dr. A.M. Aboregela, Faculty of Medicine, Zagazig University, 44519, Egypt; College of Medicine, University of Bisha, 61992, Kingdom Saudi Arabia, tel: +966505163578/+201001498234, e-mail: amaboregela@zu.edu.eg; aaboregela@ub.edu.sa

This article is available in open access under Creative Commons Attribution-Non-Commercial-No Derivatives 4.0 International (CC BY-NC-ND 4.0) license, allowing to download articles and share them with others as long as they credit the authors and the publisher, but without permission to change them in any way or use them commercially.

INTRODUCTION

In the past decades, clinical studies revealed that the thyroid hormone plays a mandatory role in spermatogenesis and steroidogenesis. It is now known that T3 regulates the testicular growth and maturation, in different mammals [27]. The efficiency of spermatogenesis is directly correlated to the number of functional Sertoli cells entrenched during adulthood [40]. Thyroid hormones have a well-known physiological role in modulating the process of oxidative stress caused by reactive oxygen species [28]. Its deficiency is known to induce hypothyroidism and oxidative stress and perhaps might lead to testicular dysfunction and infertility [20]. In males, hypothyroidism is accompanied by hypogonadism and other abnormalities, like a declined serum testosterone [24]. Furthermore, hypothyroidism can alter sperm morphology and motility [23]. Carbimazole mode of action is through its active form methimazole (1-methyl-2-mercaptoimidazole), which inhibits the iodination of tyrosine catalysed by thyroid peroxidase inducing lowering of circulating thyroid hormones [31]. In this regard, carbimazole has been used to induce experimental hypothyroidism [6]. Alpha-lipoic acid (ALA), is one of the cofactors for multi-enzyme complexes in mitochondria, enhances the uptake of glucose by the cells, and modulates the activity of various signalling molecules and transcription factors [41]. Moreover, ALA has a lipophilic character, it is can cross cell membranes, and, with dihydrolipoic acid (DHLLA), it can overcome free radicals efficiently in both lipid and watery phases [16]. Various reports in the literature suggested that ALA can improve body resistance to free radicals [42]. Also, ALA can recycle other important antioxidants, including glutathione and vitamin C [21]. To date, less attention has been directed towards identifying the precise role of ALA in ameliorating the toxic effects caused by oxidative stress, especially in the hypothyroid state. From this perspective, we designed this study to determine the effects of carbimazole-induced hypothyroidism on testicular structure and function and the possible ameliorating role of ALA supplementation.

MATERIALS AND METHODS

Animal models and groups treatment

Forty healthy adult males (21 weeks old and weighing 200 to 250 g) albino rats of Wister strain were obtained from Zagazig Veterinary Medicine Animal House, Egypt. All rats were fed *ad libitum*

and were grouped (n = 5 per cage) in standard special cages made from plastic. Before experimentation, all animals were accommodated for 2 weeks at temperature: 24–26°C and in a 12 h light/12 h dark cycle. Then, rats were divided into four main groups (10/group). Group 1 (control) received 2 mL of distilled water with 2 mL of olive oil orally. Group 2 (ALA group) was administered 2 mL of distilled water plus ALA (60 mg/kg body weight) [11] dissolved in 2 mL of olive oil. Group 3 (carbimazole group) was administered 2 mL of olive oil plus carbimazole (1.35 mg/kg body weight) [32] dissolved in 2 mL of distilled water. Group 4 (carbimazole + ALA group) was administered ALA (60 mg/kg body weight) dissolved in 2 mL of olive oil and carbimazole (1.35 mg/kg body weight) dissolved in 2 mL distilled water. Each rat was administered daily a fresh single oral dose via gavages for 30 days. The Guide for the Care and Use of Laboratory Animals, 8th edition was our guide during all experimental processes [1]. The Institutional Animal Care and Use Committee at Zagazig University (ZU-IACUC/3/F/29/2018) approved the present study. All chemicals were purchased from Sigma Chemicals Company (St. Louis, MO).

Blood collection

The rats were sacrificed under ethyl ether anaesthesia after 24 hours of the last dose [13]. Blood samples were obtained by cardiac puncture and then centrifuged at 4000 rpm for a quarter of an hour after allowing the blood to clot for 2 hours at room temperature. The sera from all rats were kept at –20°C till the proceeding of the biochemical determinations. We take in mind, to avoid the repeated freezing and thawing of preserved samples.

Extraction and preparation of gonads

The testes were removed from all groups by laparotomy and the epididymis was obtained, removed, and homogenised at 37°C in 2 mL of Hank's buffer solution. Then caudal epididymis sperms numbers were detected by haemocytometry technique [37].

The right testes were weighed and washed in cold physiologic saline and dried with filter paper. The volume of the testes was estimated. Next, the testes were fixed in 10% buffered formaldehyde solution, and then processed and embedded in paraffin wax. The left testes from all animals were weighed and their volume was estimated and recorded. Testes of all groups were homogenised in 50 mM phosphate

buffer (pH 7) containing 0.1 mM EDTA to give 10% homogenate (w/v). The testicular homogenates were centrifuged for 10 min at 1000 rpm and the supernatant was separated and then after used for oxidative stress evaluation [37].

Light microscopic analysis

Sections from the testis at 4–5 μm thickness were obtained and stained with eosin and haematoxylin to assess general histological architecture [3]. Thirty different testicular sections from 10 different rats in each group were processed for immunohistochemistry [39]. In brief, 3% H_2O_2 in phosphate buffered saline was used to block the endogenous peroxidase activity. Immersing the slides in citrate sodium solution (10 mM, pH 6.0) for 15 min at 95°C was done for antigenic retrieval. The sections were kept in diluted primary antibodies overnight at 4°C; (myoid cell marker) rabbit polyclonal anti- α -smooth muscle actin (SMA) (diluted 1:3000; Catalogue No. ab5694, Abcam, Cambridge, UK), (androgen receptor antibody) mouse anti-“androgen receptor” (N-20, sc-816; Santa Cruz Biotechnology, Inc., Santa Cruz, CA, USA) diluted 1:100, and mice anti-Vimentin as (Sertoli cell marker, 1:50, Santa Cruz, CA, USA). After addition of avidin-biotin complex, Mayer’s haematoxylin was used as a counterstain. All sections were photographed and examined using a photomicroscope (Leica DM500, German).

Morphometry

ImageJ software was used for image analysis and morphometry according to Wayne Rasband — National Institute of Mental Health (Bethesda, Maryland, USA). Seminiferous tubule diameter, germinal epithelium thickness, and interstitial space thickness (μm) were measured in six sections per testis from ten different rats in each group at magnification power $\times 400$. Numbers of Sertoli cells and Leydig cells were also counted in the same slides. In addition, the area percentages of androgen receptor, α -SMA, and vimentin expression were assessed.

Biochemical analysis

Blood samples from 10 different rats in each group were used to determine the hormone levels in the serum. Serum levels of triiodothyronine (T3) (mouse/rat ELISA Kit) (Abnova, Taiwan), and thyroxine (T4) (rat ELISA Kit) (MyBioSource, Inc. USA) were determined by colorimetric method according to the

manufacturer instructions. rTSH kit — Biotrak Assay System was used to determine thyroid-stimulating hormone (TSH) levels. The sensitivity of the rTSH assay was 0.05 ng/tube, with cross-reactivity 100% with rat TSH and 15% non-specific binding. The procedures were performed following the specifications of the manufacturer’s manual. Follicle-stimulating hormone (FSH) level was estimated using rat FSH ELISA Kit, Novus Biologicals (KA2330) by colorimetric method [33]. Luteinizing hormone (LH) level was estimated using rat LH ELISA kit, Novus Biologicals (NBP2-61257) by colorimetric method range from 1.2 to 280 mIU/mL according to the manufacturer instructions. Testosterone level was estimated using rat testosterone ELISA Kit, Aviva Systems Biology (OKCA00179) by a colorimetric method (OD450 nm) [4]. Malondialdehyde (MDA) level was assessed by incubating the testis homogenate at 100°C in 1 mL of trichloroacetic acid (10%) and 1 mL of thiobarbituric acid (0.67%) for a half of an hour. The amount of MDA concentration was expressed by the coloured complex obtained at 535 nm absorbance [30]. Reduced glutathione (GSH) content in the tissue homogenate was determined, where a mixture formed from 250 μL of testicular homogenate (10%), 250 μL distilled water, 50 μL of trichloroacetic acid (50%). The mixture was shaken for 15 min and centrifuged for 10 min at 3000 rpm. The 10 μL of supernatant was mixed with 400 μL Tris buffer (0.4 M) and (pH = 8.9) and 10 μL of 5,5-dithio-bis-2 nitrobenzoic acid (DTNB). The obtained colour complex was detected by a spectrophotometer at 512 nm [38].

Statistical analysis

The obtained data of our results were statistically analysed by Graph Pad Prism 5.01 (GraphPad Software, San Diego, CA, USA). Quantitative data were tabulated as mean and standard deviation when normally distributed or median and interquartile range if not normally distributed. Analysis of variance (ANOVA) used to test mean values differences for all experimental groups and Bonferroni’s multiple comparison test was used as a *post hoc* test. The statistical significance of the results was considered at (p-value < 0.05).

RESULTS

Hypothyroidism was induced by administering carbimazole (1.35 mg/kg body weight). This resulted in a decrease in serum concentrations of total T3, and T4.

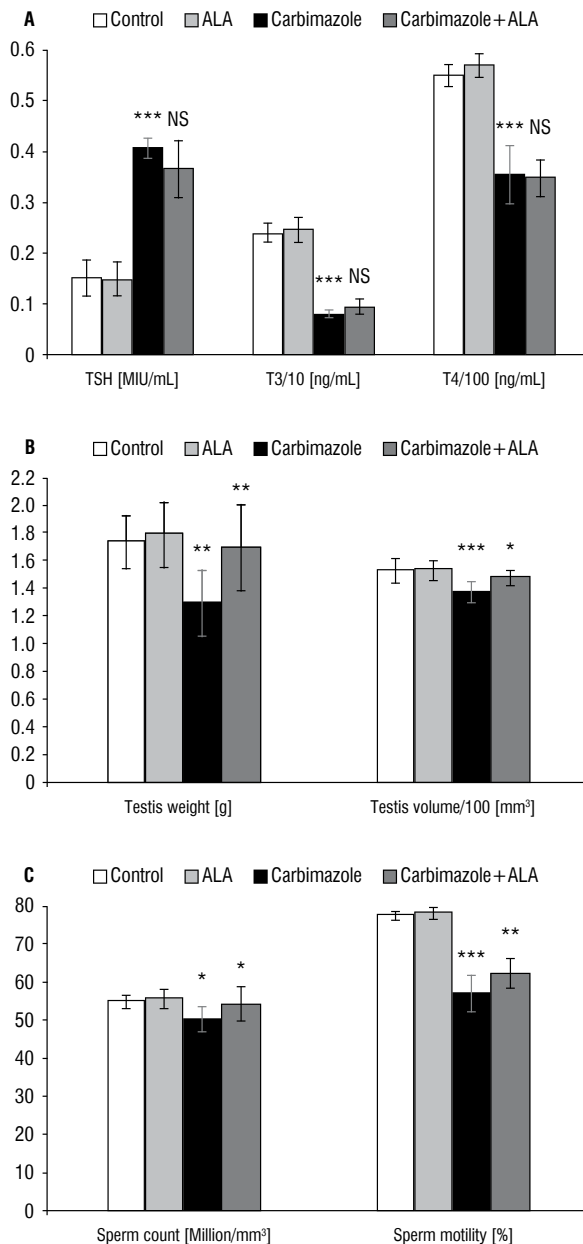


Figure 1. A. Histogram showing thyroid function tests after different treatment strategies confirming the hypothyroid state; **B, C.** Histograms representing the effects of carbimazole-induced hypothyroidism and alpha-lipoic acid (ALA) on gross measurements and semen analysis, respectively. Data are presented as mean \pm standard deviation; TSH — thyroid-stimulating hormone; T3 — thyroxine 3; T4 — thyroxine 4; NS — no significance; * $p < 0.05$; ** $p < 0.01$; *** $p < 0.001$.

Also, this was accompanied by a significant increase in the serum TSH levels. Moreover, ALA supplementation did not affect the hypothyroid state in the carbimazole + ALA group (Fig. 1A). A decrease in testicular weight and volume of hypothyroid rats was observed (Fig. 1B).

Gross measurements and semen analysis

The average testicular sperm count was significantly reduced in the carbimazole group when compared to the control group. Supplementation of ALA significantly restored the sperm count in the testis of the carbimazole + ALA group (Fig. 1C). The mean sperm motility in the carbimazole group was significantly low when compared to the control group. However, a significant elevation was detected in the carbimazole + ALA group after ALA supplementation.

Light microscopic analysis

In the control group, the testicular sections expressed normal architecture with average sperm density (Fig. 2A, B). However, in the carbimazole group, there was a deposition of homogenous substance in the interstitial spaces, which was associated with congestion and disturbance in the tubular contour. Also, destruction in some tubular walls was noted. Besides, testicular sections expressed a remarkable detachment of germinal epithelium with decreased spermatocytes density. Furthermore, vacuolations in the interstitial space and in between spermatocytes, and scarce Sertoli cells with scattering and stripping off spermatids were observed and Leydig cells nearly disappeared (Fig. 2C, D). Moreover, the tubular diameter, germinal epithelium thickness, and interstitial space were decreased when compared to the control group. On the other hand, the supplementation of ALA resulted in a significant improvement in the tubular diameter and germinal epithelium thickness. However, no significant improvement regarding interstitial space was observed (Table 1). In the carbimazole + ALA group, the integrity of germinal epithelium was maintained with minute areas of detachment and Leydig cell clusters were preserved. Besides, refinement in spermatocyte density was noted. However, any deposition of homogenous substance and the regularity and maintenance of the tubular contour were not observed. Also, spermatids appeared scattered (Fig. 2E, F). Sertoli cell and Leydig cell numbers were significantly decreased in the carbimazole group when compared to the control. Moreover, their numbers were significantly higher in the group receiving combination of carbimazole and ALA than in the carbimazole group (Table 1).

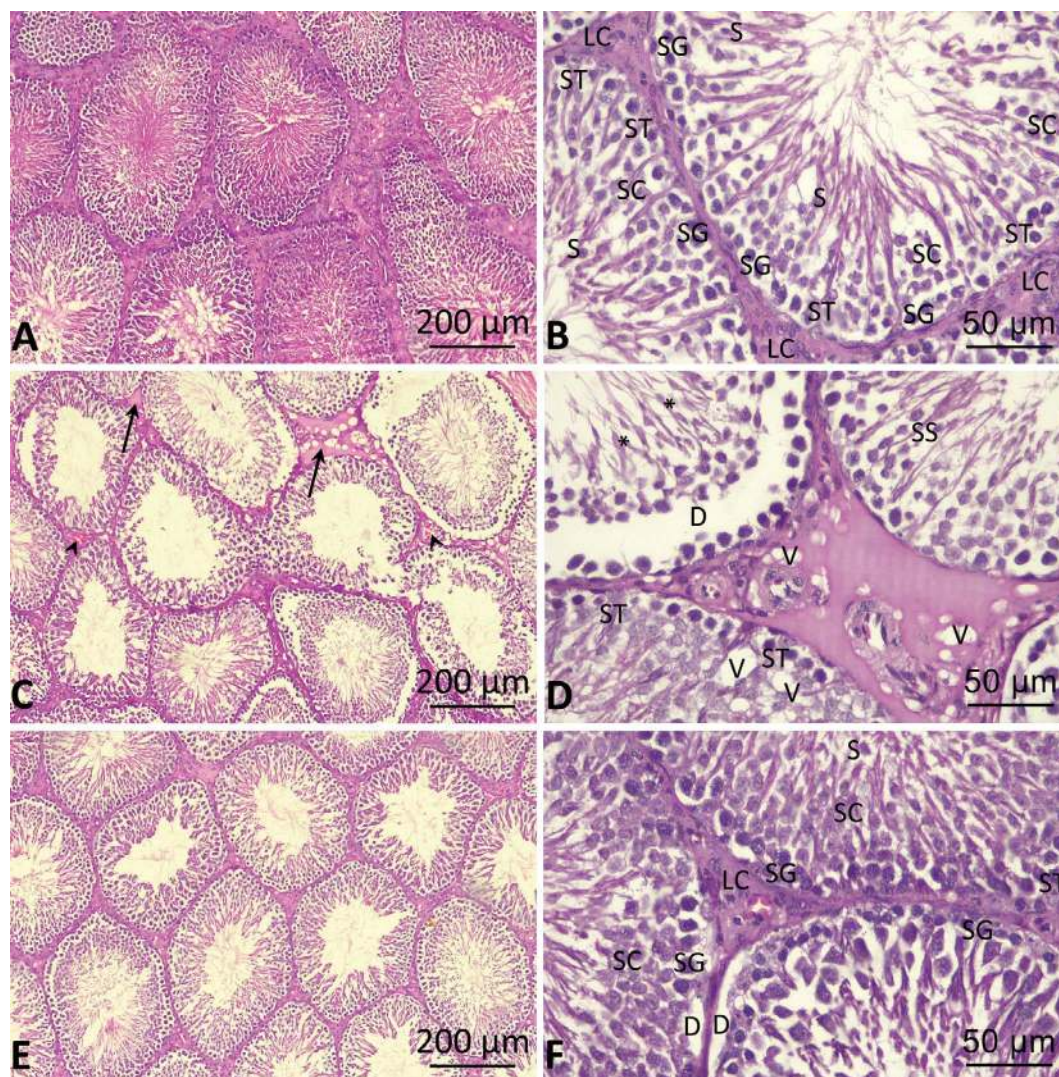


Figure 2. Representative microphotograph of the testis in different groups. **A, B.** Control group. The testis shows different types of cells; LC — Leydig cells; ST — Sertoli cells; SG — spermatogonia; SC — spermatocyte; S — spermatid; **C, D.** Hypothyroid group (carbimazole-treated) the testis represents homogenous substance in the interstitial space (straight arrow), congestion (arrowhead), vacuolation (V), scarce Sertoli cells (ST), stripped off spermatids (SS), scattered spermatids (*) and detached germinal epithelium (D); **E, F.** Carbimazole + α -lipoic acid group expressing few Sertoli cells (ST), Leydig cells (LC), spermatogonia (SG), spermatocyte (SC), spermatid (S) and detached germinal epithelium (D) (H&E, bars = 200 and 50 μ m).

Immunohistochemistry

In the testes of the control group, androgen receptor expression was prominent in interstitial cells of Leydig and the peritubular myoid cells, but it was weak in the Sertoli cells in all stages of spermatogenesis. In contrast, the androgen receptor expression was limited to certain interstitial cells with a decrease in the area per cent in the carbimazole group. The decrease in androgen receptor expression in Sertoli cells was prominent in all stages of spermatogenesis especially stage IV–VIII. Interestingly, the group that received carbimazole + ALA showed maintenance of the androgen receptor expression in Leydig cells and some peritubular myoid

cells with improvement in the area percentage (Table 1, Fig. 3A–C). Regarding α -SMA expression, it was limited to the peritubular myoid cells and it appeared as a very thin bilaminar line with very potential space in between laminae, and in the wall of the interstitial blood vessels in the control group. In contrast, α -SMA expression in the carbimazole group showed areas of thickening and fusion between the laminae. Besides, it was associated with prominent thickening in the wall of blood vessels, which in turn increased the surface area percentage. However, the testes of the carbimazole + ALA group displayed maintenance of the control expression pattern (Table 1, Fig. 3D–F). We also

Table 1. Effects of carbimazole-induced hypothyroidism and alpha-lipoic acid (ALA) on the histomorphometry and immunomorphometry of the testis in albino rats

Parameter	Control	ALA	Carbimazole	Carbimazole + ALA	ANOVA
Seminiferous tubule diameter [μm]	241.80 \pm 34.47	242.90 \pm 29.80 ^{NS}	181.40 \pm 12.06 ^{***}	218.7 \pm 5.554 [*]	< 0.0001 ^{***}
Germinal epithelium thickness [μm]	52.42 \pm 6.505	54.66 \pm 5.685 ^{NS}	29.26 \pm 3.760 ^{***}	38.46 \pm 3.068 ^{**}	< 0.0001 ^{***}
Interstitial space [μm]	12.25 \pm 2.639	13.13 \pm 3.052 ^{NS}	6.74 \pm 1.346 ^{***}	7.15 \pm 1.215 ^{NS}	< 0.0001 ^{***}
Sertoli cell number/tubule	33.63 \pm 2.973	34.25 \pm 3.196 ^{NS}	11.13 \pm 2.232 ^{***}	21.5 \pm 2.449 ^{***}	< 0.0001 ^{***}
Leydig cell number/cluster	14.75 \pm 1.282	15.13 \pm 1.885 ^{NS}	2.38 \pm 1.408 ^{***}	9.88 \pm 1.458 ^{***}	< 0.0001 ^{***}
Androgen receptor area [%]	1.20 \pm 0.345	1.13 \pm 0.195 ^{NS}	0.60 \pm 0.119 ^{***}	0.93 \pm 0.102 [*]	< 0.0001 ^{***}
Alpha smooth muscle actin area [%]	2.03 \pm 0.388	2.09 \pm 0.234 ^{NS}	4.76 \pm 0.305 ^{***}	3.88 \pm 0.678 ^{**}	< 0.0001 ^{***}
Vimentin area [%]	14.63 \pm 2.547	15.25 \pm 1.949 ^{NS}	7.74 \pm 1.516 ^{***}	10.65 \pm 0.611 [*]	< 0.0001 ^{***}

Values are expressed in mean \pm standard deviation. One-way ANOVA and post-hoc Bonferroni's multiple comparison test (ALA and carbimazole vs. control, carbimazole + ALA vs. carbimazole); * p < 0.05, ** p < 0.01, *** p < 0.001; NS — no significance

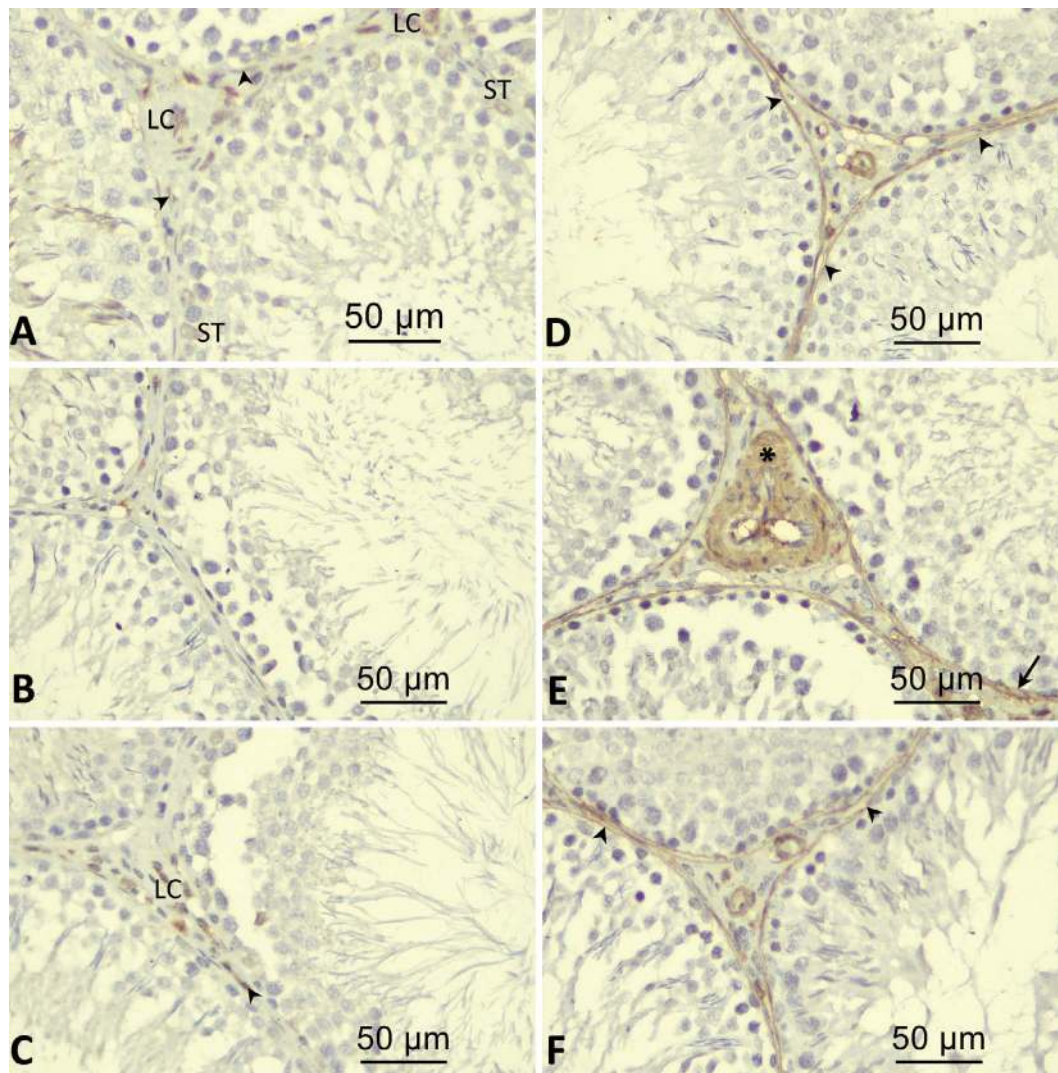


Figure 3. Representative microphotograph of the immunohistochemical expression in the testis. The groups are arranged as control, carbimazole-treated and carbimazole + alpha-lipoic acid-treated group, respectively. **A, B, C.** Androgen receptor. The testis shows Leydig cells (LC), Sertoli cells (ST), and peritubular myoid cells (arrowhead); **D, E, F.** Alpha-smooth muscle actin. The testis represents bilaminar peritubular myoid cells expression (arrowhead), thickening and fusion of the two laminae (arrow), and thickening in the interstitial vessel wall (*). (Bars = 50 μm).

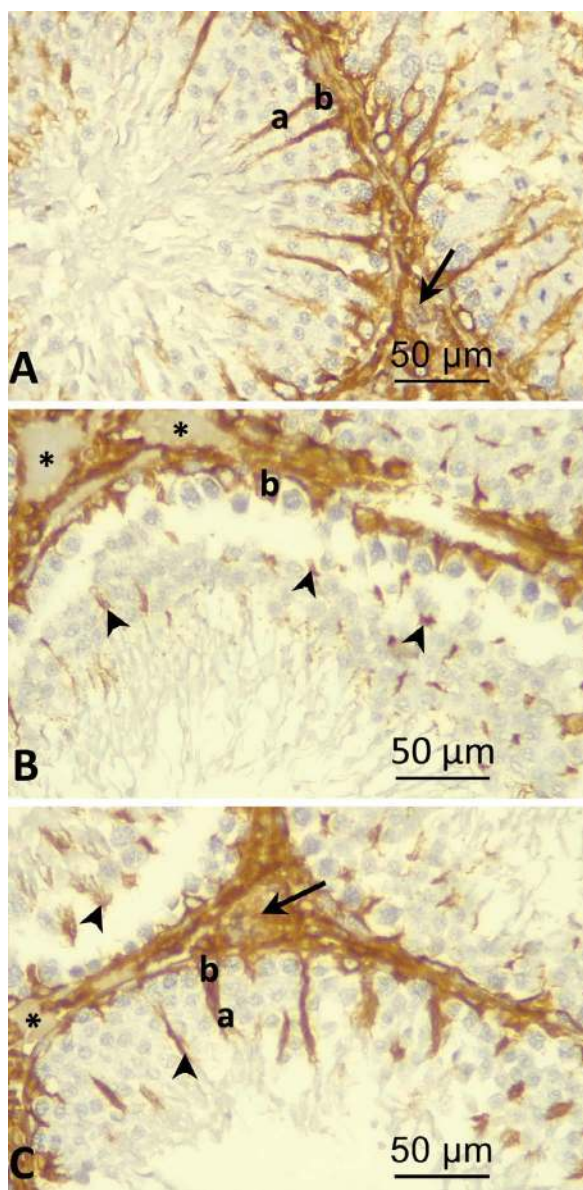


Figure 4. Representative microphotograph of vimentin expression in the testis in different groups. **A, B, C.** Control, carbimazole-treated and carbimazole + alpha-lipoic acid-treated group, respectively. The testis shows different segments of Sertoli cells; a — apical segment; b — basal segment, destroyed detached apical segment of Sertoli cells (arrowhead), interstitial tissue (arrow) empty areas in the interstitial space (*). (Bars = 50 µm).

analysed the immunocontent of vimentin expression. The results showed that vimentin was prominently expressed in the cytoplasm of the Sertoli cells with clear continuity between both apical and basal segments and the interstitial tissue in the control group. On the contrary, Sertoli cells' destruction was elucidated by the pattern of vimentin expression in the carbimazole group. There was a destruction of the apical segment of Sertoli cells with the scarce appearance of the basal segment in most of the tubules. Besides, there was

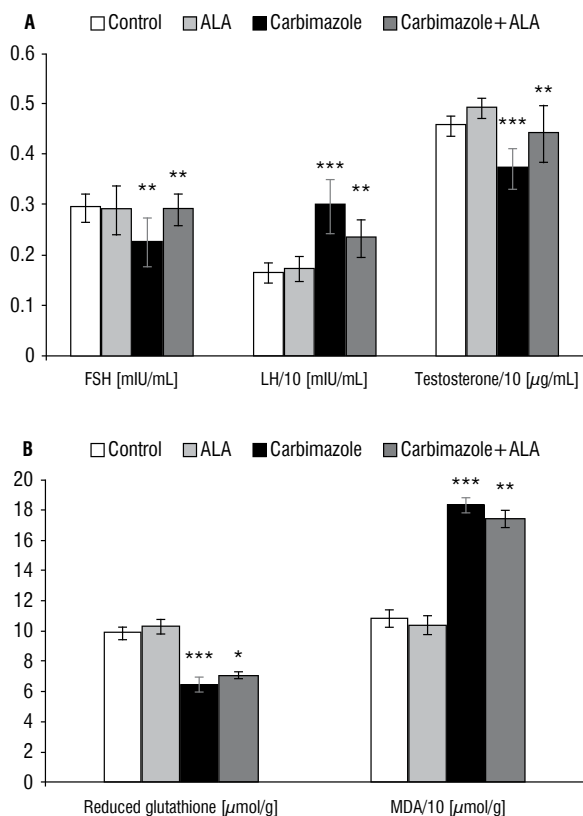


Figure 5. A, B. Histograms representing the effects of carbimazole-induced hypothyroidism and alpha-lipoic acid (ALA) on reproductive hormones, reduced glutathione, and malondialdehyde (MDA). Data are presented as mean ± standard deviation; FSH — follicle-stimulating hormone; LH — luteinizing hormone; NS — no significance; *p < 0.05; **p < 0.01; ***p < 0.001.

a lack of expression in certain areas of the interstitial tissue which appeared empty of cells. This resulted in a decrease in the area percentage of vimentin expression. On the other hand, limited conservation of the expression pattern of the control in some Sertoli cells was detected in the carbimazole + ALA group. Also, the interstitial tissue was partially protected showing fractional improvement in area percentage of vimentin expression (Table 1, Fig. 4A–C).

Biochemical analysis

Serum levels of testosterone were significantly decreased in the carbimazole group compared to the control group. Also, FSH concentrations showed a significant decline in the carbimazole group when compared to the control group. In contrast, the level of LH showed a significant increase in the carbimazole group compared to the control group. The results were improved after ALA administration in the carbimazole + ALA group, with a significant increase in testosterone and FSH levels (Fig. 5A). GSH contents

in the carbimazole group showed a significant decline when compared to the control group (Fig. 5B). A comparison of the MDA contents of the testis showed a significant increase in the carbimazole group when compared to the control group. Interestingly, the results improved in the carbimazole + ALA group, and a significant decrease was observed in MDA (Fig. 5B).

DISCUSSION

The impact of thyroid diseases on male reproduction has been an area of controversy for many years ago, due to the reports of the inability of the testis to respond metabolically to thyroid hormones [15]. Yet, in the last decades, some clinical trials have concluded that thyroid hormones have a great role in the process of testicular spermatogenesis even at and after puberty [14]. However, some authors suggested that hypothyroidism does not influence the functions or the size of the testis or seminiferous tubules [10]. Thyroid hormones are considered to be one of the main factors in cell metabolism regulation and thus play a significant role in oxidative stress [8]. The impetus of the present study is to determine the ameliorating role of ALA supplementation on the damage caused by carbimazole-induced hypothyroidism on testicular tissue of the experimental animal model. The obtained data of the present study confirmed that carbimazole can decrease the testicular volume and tubular diameter, germinal epithelium thickness, sperm count as compared to the control group. Besides, congestion and disturbance in tubular contour with damage to some tubular wall and very limited expression of androgen receptor to certain interstitial cells were observed. Moreover, detachment of germinal epithelium decreased spermatocytes density, and destruction in Sertoli cells was recorded. The above-obtained data came in accordance with Prathima et al. [32] who reported that rats exposed to carbimazole showed major histological deterioration such as congestion of blood vessels, haemorrhage, and destruction of interstitial cells with degeneration of spermatogenic cells with the irregular cell membrane. The report of Yousofvand et al. [43] revealed that hypothyroidism induced by a chemical called propylthiouracil was able to induce a significant reduction in testicular weight [43]. In another study, administration of carbimazole at a dose of 1.35 mg/kg for 3 or 6 weeks resulted in the disorganisation of germinal cells, a decrease in the diameters of the seminiferous tubules and the height of testicular

tissue epithelium. This was associated with congestion of interstitial blood vessels and oedema [35]. This may be related to the increased blood endotoxins and the state of oxidative stress that lead to capillary destruction, exudation and apoptosis. This is in accordance with Jalilvand et al.'s [19] observation that hypothyroidism increases TUNEL-positive cells in the testis. Examination of the testes of rats treated with carbimazole and ALA showed improvement in tubular diameter and germinal epithelium thickness, and no change was seen in interstitial space regularity. Also, maintenance of tubular contour with nearly normal expression of androgen receptors, vimentin, and α -SMA was observed. These data are consistent with a previous result [5] which revealed that ALA works at two levels intracellular and extracellular (at cell membrane level). Thus, giving double protection and improving the pathology of testicular tissue with normal expression of different immune markers. Gawish [11] concluded that the ALA has an ameliorative role against toxicity induced by hypothyroidism. Also, Prathima et al. [32] reported that ALA acts as a potent antioxidant and can reverse the histological changes in the testicular tissue of adult rats induced by carbimazole. Androgen receptor expression in Sertoli cells was reduced due to the state of oxidative stress induced by admission of ethanol [17]. This agreed with the finding of this experiment in which androgen receptor expression was limited to certain interstitial cells with a decrease in the area per cent in the carbimazole group. The decrease in androgen receptor expression in Sertoli cells was prominent in all stages of spermatogenesis, especially stage IV–VIII. As reported by Horibe et al. [18], marked decrease in androgen receptor expression was evident in all stages of the spermatogenic cycle in the testes of rats treated with ethanol. Reduction in androgen receptor expression can affect the pattern of α -SMA expression [29]. In the current study α -SMA expression showed prominent thickening in the wall of blood vessels, which in turn increased the surface area percentage after carbimazole supplementation. On the other hand O'Hara and Smith [29] showed reduction in α -SMA expression following androgen receptor expression in transgenic mice. Also Gosteli-Peter et al. [12] mentioned that T3 increased dramatically α -SMA mRNA and protein accumulation. Vimentin can be considered as Sertoli cell marker. It is dependent on spermatocytes renewal and attachment to Sertoli cells which is altered by oxidative stress induced by busul-

phan [22]. This goes with the pattern noticed in this experiment regarding vimentin expression in the control group as well as the destruction in the apical segment of Sertoli cells with the scarce appearance of the basal segment in most of the tubule after carbimazole treatment. On the contrary, Zamoner et al. [44] mentioned that there was no change in vimentin expression by real time-quantitative polymerase chain reaction in the testis of hypothyroid rats; however, increase in its phosphorylation and its content in the cytoskeleton of the testis was observed. In the present study, administration of carbimazole (1.35 mg/kg) for a month resulted in a significant decline in serum levels of free T3, T4, testosterone and FSH while there was a significant increase in TSH and LH levels. These findings are consistent with those of Yousofvand et al. [43] who reported a significant reduction in serum levels of testosterone hormone induced by hypothyroidism, with non-significant changes in LH and FSH serum levels. Similarly, another study showed that rats with hypothyroidism presented with high serum levels of LH hormone. Also, there was a significant decline in total serum testosterone levels. These results highlighted the great role of thyroid hormones in the regulation of FSH biosynthesis [34]. Moreover, in hypothyroidism, the serum level of the LH hormone was increased, while serum level of testosterone was decreased [25]. The authors correlated these findings to the decrease in liver synthesis of sex hormone-binding globulin (SHBG) in a hypothyroid state. SHBG is accountable for the transfer of testosterone from the testis to brain tissue, where free testosterone is dissociated and crosses the blood-brain barrier, to induce negative feedback on LH biosynthesis and its secretion [26]. Propylthiouracil-induced hypothyroidism significantly decreased serum levels of both T3 and T4 while increasing TSH level [36]. To better understand the pathological effects of hypothyroidism on testicular tissues, the oxidant-antioxidant state was studied in the testicular tissues. It seems that hypothyroidism can induce a disruption in the thiol redox status of mitochondria, which resulted in testicular structural and functional abnormalities. Our data regarding these above-mentioned data showed a significant decrease in the GSH content in testicular tissue homogenate. There was also a decrease in sperm count and motility. However, a significant improvement in the level of GSH was recorded after ALA supplementation. This may aid in

confirmation of the antioxidant system failure in the testes of carbimazole-treated rats. The results also revealed that carbimazole-induced hypothyroidism was able to increase MDA contents in the testicular tissue. In contrast, a partial improvement was noted in the carbimazole + ALA group. The testes have a defence mechanism that is composed of the enzymatic and non-enzymatic antioxidant defence system, but its potential is limited. Furthermore, the testes contain a high amount of polyunsaturated fatty acids subjected to peroxidation by many oxidative radicals. In this regard, it has been proven that the production of high amounts of free radicals is harmful to sperm structure and function due to the bad effects on both the quality and quantity of DNA content of spermatozoa [7]. Taking into consideration these above-mentioned facts, the oxidative damage of testes tissue may play a main role in the obtained results of this study. The results obtained from previous reports indicated the alterations in thyroid hormone concentrations impaired mitochondrial GSH regulation mechanism, antioxidant defence mechanism, and their ratio to the functions of testes of adult rats [2]. On the other hand, the administration of ALA with carbimazole (1.35 mg/kg body weight) resulted in a significant increase in GSH level, increase in sperm number and motility while a significant decrease in MDA testicular level was noted when compared with the carbimazole group. In agreement with our results, ALA proved to be a potent factor to restore the deteriorated antioxidants in testicular rats exposed to cadmium [9].

CONCLUSIONS

Based on the obtained data, we can conclude that ALA as an antioxidant, can ameliorate the toxic effects of hypothyroidism on spermatogenesis and improved the structural and physiological processes in the testes of hypothyroidism-induced rats. Furthermore, it can protect testicular tissues against oxidative damage. One of the limitations which we faced was the inability to add *in situ* hybridisation as a confirmatory tool for our data.

Acknowledgements

The authors would like to thank the Zagazig Scientific and Medical Research Centre (ZSMRC) team for their support and permission for performing experimentation procedures in their laboratories.

REFERENCES

- Albus U. Guide for the Care and Use of Laboratory Animals (8th Ed). In Laboratory Animals. 2012.
- Asadi N, Bahmani M, Kheradmand A, et al. The impact of oxidative stress on testicular function and the role of antioxidants in improving it: a review. *J Clin Diagn Res.* 2017; 11(5): IE01–IE05, doi: [10.7860/JCDR/2017/23927.9886](https://doi.org/10.7860/JCDR/2017/23927.9886), indexed in Pubmed: [28658802](https://pubmed.ncbi.nlm.nih.gov/28658802/).
- Bancroft JD, Gamble M. Theory and practice of histological techniques. Elsevier Health Sciences. 2008.
- Bell CA. Clinical guide to laboratory tests. Norbert W Tietz (3rd edn). Transfusion. 1995; 35(11): 972.
- Cronan JE, Zhao X, Jiang Y. Function, attachment and synthesis of lipoic acid in *Escherichia coli*. *Adv Microb Physiol.* 2005; 50: 103–146, doi: [10.1016/S0065-2911\(05\)50003-1](https://doi.org/10.1016/S0065-2911(05)50003-1), indexed in Pubmed: [16221579](https://pubmed.ncbi.nlm.nih.gov/16221579/).
- Delitala AP, Capobianco G, Cherchi PL, et al. Thyroid function and thyroid disorders during pregnancy: a review and care pathway. *Arch Gynecol Obstet.* 2019; 299(2): 327–338, doi: [10.1007/s00404-018-5018-8](https://doi.org/10.1007/s00404-018-5018-8), indexed in Pubmed: [30569344](https://pubmed.ncbi.nlm.nih.gov/30569344/).
- Divakaruni AS, Wiley SE, Rogers GW, et al. Thiazolidinediones are acute, specific inhibitors of the mitochondrial pyruvate carrier. *Proc Natl Acad Sci U S A.* 2013; 110(14): 5422–5427, doi: [10.1073/pnas.1303360110](https://doi.org/10.1073/pnas.1303360110), indexed in Pubmed: [23513224](https://pubmed.ncbi.nlm.nih.gov/23513224/).
- El Hassani RA, Buffet C, Leboulleux S, et al. Oxidative stress in thyroid carcinomas: biological and clinical significance. *Endocr Relat Cancer.* 2019; 26(3): R131–R143, doi: [10.1530/ERC-18-0476](https://doi.org/10.1530/ERC-18-0476), indexed in Pubmed: [30615595](https://pubmed.ncbi.nlm.nih.gov/30615595/).
- El-Maraghy SA, Nassar NN. Modulatory effects of lipoic acid and selenium against cadmium-induced biochemical alterations in testicular steroidogenesis. *J Biochem Mol Toxicol.* 2011; 25(1): 15–25, doi: [10.1002/jbt.20354](https://doi.org/10.1002/jbt.20354), indexed in Pubmed: [20957662](https://pubmed.ncbi.nlm.nih.gov/20957662/).
- Gautam DK, Misro MM, Chaki SP, et al. H₂O₂ at physiological concentrations modulates Leydig cell function inducing oxidative stress and apoptosis. *Apoptosis.* 2006; 11(1): 39–46, doi: [10.1007/s10495-005-3087-1](https://doi.org/10.1007/s10495-005-3087-1), indexed in Pubmed: [16374549](https://pubmed.ncbi.nlm.nih.gov/16374549/).
- Gawish AM. The protective role of alpha lipoic acid against pesticides induced testicular toxicity- histopathological and histochemical studies. *J Aquaculture Res Development.* 2010; 1(1): 101, doi: [10.4172/2155-9546.1000101](https://doi.org/10.4172/2155-9546.1000101).
- Gosteli-Peter MA, Harder BA, Eppenberger HM, et al. Triiodothyronine induces over-expression of alpha-smooth muscle actin, restricts myofibrillar expansion and is permissive for the action of basic fibroblast growth factor and insulin-like growth factor I in adult rat cardiomyocytes. *J Clin Invest.* 1996; 98(8): 1737–1744, doi: [10.1172/JCI118972](https://doi.org/10.1172/JCI118972), indexed in Pubmed: [8878423](https://pubmed.ncbi.nlm.nih.gov/8878423/).
- Ha AeW, Kim WK. The effect of fucoxanthin rich power on the lipid metabolism in rats with a high fat diet. *Nutr Res Pract.* 2013; 7(4): 287–293, doi: [10.4162/nrp.2013.7.4.287](https://doi.org/10.4162/nrp.2013.7.4.287), indexed in Pubmed: [23964316](https://pubmed.ncbi.nlm.nih.gov/23964316/).
- Hernandez A, Martinez ME. Thyroid hormone action in the developing testis: intergenerational epigenetics. *J Endocrinol.* 2020; 244(3): R33–R46, doi: [10.1530/JOE-19-0550](https://doi.org/10.1530/JOE-19-0550), indexed in Pubmed: [31977317](https://pubmed.ncbi.nlm.nih.gov/31977317/).
- Hofstee P, McKeating DR, Bartho LA, et al. Maternal selenium deficiency in mice alters offspring glucose metabolism and thyroid status in a sexually dimorphic manner. *Nutrients.* 2020; 12(1): 267, doi: [10.3390/nu12010267](https://doi.org/10.3390/nu12010267), indexed in Pubmed: [31968625](https://pubmed.ncbi.nlm.nih.gov/31968625/).
- Holmquist L, Stuchbury G, Berbaum K, et al. Lipoic acid as a novel treatment for Alzheimer's disease and related dementias. *Pharmacol Ther.* 2007; 113(1): 154–164, doi: [10.1016/j.pharmthera.2006.07.001](https://doi.org/10.1016/j.pharmthera.2006.07.001), indexed in Pubmed: [16989905](https://pubmed.ncbi.nlm.nih.gov/16989905/).
- Horibe A, Eid N, Ito Y, et al. Upregulated autophagy in sertoli cells of ethanol-treated rats is associated with induction of inducible nitric oxide synthase (inos), androgen receptor suppression and germ cell apoptosis. *Int J Mol Sci.* 2017; 18(5), doi: [10.3390/ijms18051061](https://doi.org/10.3390/ijms18051061), indexed in Pubmed: [28505146](https://pubmed.ncbi.nlm.nih.gov/28505146/).
- Horibe A, Eid N, Ito Y, et al. Ethanol-Induced autophagy in sertoli cells is specifically marked at androgen-dependent stages of the spermatogenic cycle: potential mechanisms and implications. *Int J Mol Sci.* 2019; 20(1), doi: [10.3390/ijms20010184](https://doi.org/10.3390/ijms20010184), indexed in Pubmed: [30621351](https://pubmed.ncbi.nlm.nih.gov/30621351/).
- Jalilvand N, Hosseini M, Beheshti F, et al. Protective effect of PPAR γ agonist pioglitazone, on testicular tissue and sperm parameters in hypothyroid rats. *Toxin Reviews.* 2019; 24: 1–10, doi: [10.1080/15569543.2018.1564775](https://doi.org/10.1080/15569543.2018.1564775).
- Kamel A, Hamouli-Said Z. Neonatal exposure to T3 disrupts male reproductive functions by altering redox homeostasis in immature testis of rats. *Andrologia.* 2018; 50(9): e13082, doi: [10.1111/and.13082](https://doi.org/10.1111/and.13082), indexed in Pubmed: [29968296](https://pubmed.ncbi.nlm.nih.gov/29968296/).
- Karafakioğlu YS. Effects of α lipoic acid on noise induced oxidative stress in rats. *Saudi J Biol Sci.* 2019; 26(5): 989–994, doi: [10.1016/j.sjbs.2018.08.008](https://doi.org/10.1016/j.sjbs.2018.08.008), indexed in Pubmed: [31303830](https://pubmed.ncbi.nlm.nih.gov/31303830/).
- Kopecky M, Semecky V, Nachtigal P. Vimentin expression during altered spermatogenesis in rats. *Acta Histochem.* 2005; 107(4): 279–289, doi: [10.1016/j.acthis.2005.06.007](https://doi.org/10.1016/j.acthis.2005.06.007), indexed in Pubmed: [16139876](https://pubmed.ncbi.nlm.nih.gov/16139876/).
- Krassas GE, Markou KB. The impact of thyroid diseases starting from birth on reproductive function. *Hormones (Athens).* 2019; 18(4): 365–381, doi: [10.1007/s42000-019-00156-y](https://doi.org/10.1007/s42000-019-00156-y), indexed in Pubmed: [31734887](https://pubmed.ncbi.nlm.nih.gov/31734887/).
- Krysiak R, Szkróbka W, Okopień B. The impact of testosterone on metformin action on hypothalamic-pituitary-thyroid axis activity in men: a pilot study. *J Clin Pharmacol.* 2020; 60(2): 164–171, doi: [10.1002/jcph.1507](https://doi.org/10.1002/jcph.1507), indexed in Pubmed: [31389032](https://pubmed.ncbi.nlm.nih.gov/31389032/).
- Krytskyy T, Pasyechko N. Correction of androgen deficiency in men with hypothyroidism. *Georgian Med News.* 2019(286): 77–82, indexed in Pubmed: [30829594](https://pubmed.ncbi.nlm.nih.gov/30829594/).
- La Vignera S, Vita R, Condorelli RA, et al. Impact of thyroid disease on testicular function. *Endocrine.* 2017; 58(3): 397–407, doi: [10.1007/s12020-017-1303-8](https://doi.org/10.1007/s12020-017-1303-8), indexed in Pubmed: [28429281](https://pubmed.ncbi.nlm.nih.gov/28429281/).
- La Vignera S, Vita R. Thyroid dysfunction and semen quality. *Int J Immunopathol Pharmacol.* 2018; 32: 2058738418775241, doi: [10.1177/2058738418775241](https://doi.org/10.1177/2058738418775241), indexed in Pubmed: [29737216](https://pubmed.ncbi.nlm.nih.gov/29737216/).
- Naseem Z, Iqbal MA, Ahmad S, et al. Inflammatory markers as prognosticators of cardiovascular dysfunction in hypothyroid patients. *J Biol Regul Homeost Agents.* 2019; 33(6): 1891–1895, doi: [10.23812/19-334-L](https://doi.org/10.23812/19-334-L), indexed in Pubmed: [31823594](https://pubmed.ncbi.nlm.nih.gov/31823594/).

29. O'Hara L, Smith LB. Androgen receptor roles in spermatogenesis and infertility. *Best Pract Res Clin Endocrinol Metab.* 2015; 29(4): 595–605, doi: [10.1016/j.beem.2015.04.006](https://doi.org/10.1016/j.beem.2015.04.006), indexed in Pubmed: [26303086](https://pubmed.ncbi.nlm.nih.gov/26303086/).
30. Ohkawa H, Ohishi N, Yagi K. Assay for lipid peroxides in animal tissues by thiobarbituric acid reaction. *Anal Biochem.* 1979; 95(2): 351–358, doi: [10.1016/0003-2697\(79\)90738-3](https://doi.org/10.1016/0003-2697(79)90738-3), indexed in Pubmed: [36810](https://pubmed.ncbi.nlm.nih.gov/36810/).
31. Panait N, Michel F, D'Ercole C, et al. Esophageal atresia, small omphalocele and ileal prolapse through a patent omphalomesenteric duct: a methimazole embryopathy? [Corrected]. *J Pediatr Surg.* 2013; 48(6): E9–E11, doi: [10.1016/j.jpedsurg.2013.03.073](https://doi.org/10.1016/j.jpedsurg.2013.03.073), indexed in Pubmed: [23845657](https://pubmed.ncbi.nlm.nih.gov/23845657/).
32. Prathima P, Venkaiah K, Pavani R, et al. α -lipoic acid inhibits oxidative stress in testis and attenuates testicular toxicity in rats exposed to carbimazole during embryonic period. *Toxicol Rep.* 2017; 4: 373–381, doi: [10.1016/j.toxrep.2017.06.009](https://doi.org/10.1016/j.toxrep.2017.06.009), indexed in Pubmed: [28959662](https://pubmed.ncbi.nlm.nih.gov/28959662/).
33. Rebar RW, Morandini IC, Petze JE, et al. Hormonal basis of reproductive defects in athymic mice: reduced gonadotropins and testosterone in males. *Biol Reprod.* 1982; 27(5): 1267–1276, doi: [10.1095/biolreprod27.5.1267](https://doi.org/10.1095/biolreprod27.5.1267), indexed in Pubmed: [6819011](https://pubmed.ncbi.nlm.nih.gov/6819011/).
34. Romano RM, Bargi-Souza P, Brunetto EL, et al. Hypothyroidism in adult male rats alters posttranscriptional mechanisms of luteinizing hormone biosynthesis. *Thyroid.* 2013; 23(4): 497–505, doi: [10.1089/thy.2011.0514](https://doi.org/10.1089/thy.2011.0514), indexed in Pubmed: [23240964](https://pubmed.ncbi.nlm.nih.gov/23240964/).
35. Sakr SR, ELnaby SH, Okdah Y, et al. Impact of ginger aqueous extract on carbimazole induced testicular degenerative alterations and oxidative stress in albino rats. *J Coastal Life Med.* 2017; 5(4): 167–173, doi: [10.12980/jclm.5.2017j6-219](https://doi.org/10.12980/jclm.5.2017j6-219).
36. Saha I, Chakraborty SB, Chatterjee A, et al. Arecoline inhibits pineal-testis function in experimentally induced hypothyroid rats. *Arch Physiol Biochem.* 2020; 126(1): 7–16, doi: [10.1080/13813455.2018.1486428](https://doi.org/10.1080/13813455.2018.1486428), indexed in Pubmed: [30145920](https://pubmed.ncbi.nlm.nih.gov/30145920/).
37. Schlörff EC, Husain K, Somani SM. Dose and time dependent effects of ethanol on antioxidant system in rat testes. *Alcohol.* 1999; 18(2-3): 203–214, doi: [10.1016/s0741-8329\(99\)00004-x](https://doi.org/10.1016/s0741-8329(99)00004-x), indexed in Pubmed: [10456572](https://pubmed.ncbi.nlm.nih.gov/10456572/).
38. Sedlak J, Lindsay RH. Estimation of total, protein-bound, and nonprotein sulfhydryl groups in tissue with Ellman's reagent. *Anal Biochem.* 1968; 25(1): 192–205, doi: [10.1016/0003-2697\(68\)90092-4](https://doi.org/10.1016/0003-2697(68)90092-4), indexed in Pubmed: [4973948](https://pubmed.ncbi.nlm.nih.gov/4973948/).
39. Shalaby AM, Ibrahim MA, Aboregela AM. Effect of aspartame on the placenta of adult albino rat. A histological and immunohistochemical study. *Ann Anat.* 2019; 224: 133–141, doi: [10.1016/j.aanat.2019.04.007](https://doi.org/10.1016/j.aanat.2019.04.007), indexed in Pubmed: [31108189](https://pubmed.ncbi.nlm.nih.gov/31108189/).
40. Sharpe RM. Environmental/lifestyle effects on spermatogenesis. *Philos Trans R Soc Lond B Biol Sci.* 2010; 365(1546): 1697–1712, doi: [10.1098/rstb.2009.0206](https://doi.org/10.1098/rstb.2009.0206), indexed in Pubmed: [20403879](https://pubmed.ncbi.nlm.nih.gov/20403879/).
41. Tutelyan VA, Makhova AA, Pogozheva AV, et al. [Lipoic acid: physiological role and prospects for clinical application]. *Vopr Pitan.* 2019; 88(4): 6–11, doi: [10.24411/0042-8833-2019-10035](https://doi.org/10.24411/0042-8833-2019-10035), indexed in Pubmed: [31722135](https://pubmed.ncbi.nlm.nih.gov/31722135/).
42. Xiang W, Wang Li, Cheng S, et al. Protective effects of α -lipoic acid on vascular oxidative stress in rats with hyperuricemia. *Curr Med Sci.* 2019; 39(6): 920–928, doi: [10.1007/s11596-019-2124-1](https://doi.org/10.1007/s11596-019-2124-1), indexed in Pubmed: [31845223](https://pubmed.ncbi.nlm.nih.gov/31845223/).
43. Yousofvand N, Kazemi M, Mohammadizadeh E. Effect of induced hypothyroidism by propylthiouracil (PTU) on serum levels of testosterone, luteinizing hormone, follicle stimulating hormone in adult rat. *Scientific J Ilam University Med Sci.* 2013; 21(6): 1–8.
44. Zamoner A, Barreto KP, Filho DW, et al. Propylthiouracil-induced congenital hypothyroidism upregulates vimentin phosphorylation and depletes antioxidant defenses in immature rat testis. *J Mol Endocrinol.* 2008; 40(3): 125–135, doi: [10.1677/JME-07-0089](https://doi.org/10.1677/JME-07-0089), indexed in Pubmed: [18316471](https://pubmed.ncbi.nlm.nih.gov/18316471/).