

IDENTIFICATION OF PELVIC LYMPH NODES WITH CHLOROPHYLLIN AFTER INJECTION INTO THE UTERINE CERVIX: AN EXPERIMENTAL AND CLINICAL STUDY

H. Wang, Y. Tan, X. Wang, J. Xie

Departments of Anatomy (HW) and Histology and Embryology (YT), Shanghai Medical University, Shanghai and Department of Anatomy (XW), Weifang Medical College, Department of Obstetrics and Gynecology (JX), Weifang People's Hospital, Weifang, People's Republic of China

ABSTRACT

We investigated the value of staining retroperitoneal lymph nodes with chlorophyllin in normal dogs and in women with malignant uterine tumors undergoing lymphadenectomy. In dogs, after 0.3% chlorophyllin (sodium copper chlorophyllin) was injected into the canine uterus, the concentration of dye in the bloodstream was measured with a spectrophotometer and sections of stained retroperitoneal lymph nodes were examined using light and electron microscopy. The highest blood levels were detected at 4 hrs and nearly all of the chlorophyllin was gone from the bloodstream by 18 hrs but was retained in nodal macrophages for at least 4 days. No morphological changes were found in the excised lymph nodes. Twenty-four patients with cervical carcinoma and 20 patients with endometrial carcinoma undergoing radical hysterectomy and lymphadenectomy were divided into a lymphatic coloration group (23 patients) and a non-coloration (control) group (21 patients). In the lymphatic coloration group (0.3% chlorophyllin) was injected into the cervix 5 days before elective lymphadenectomy. There were no complications attributed to injection of the chlorophyllin. The number of dissected lymph nodes in the coloration group were greater than the control group ($p < 0.01$) and the time of operation was shorter ($p < 0.01$).

These results suggest that chlorophyllin is safe and facilitates identification of retroperitoneal lymph nodes, allows more complete nodal excision and shortens the time of operation in patients undergoing radical hysterectomy with lymphadenectomy.

Injection of colored dye into lymphatic vessels or the parenchyma of an organ is a useful technique to highlight regional lymph nodes (1-4). In 1968, Averette and Ravel (1) used chlorophyllin-Ethiodol to direct operative visualization of the pelvic lymph nodes in patients with cervical carcinoma. They found that the number of lymph nodes recovered from the pelvic lymphadenectomy specimens when stained by chlorophyll was greater than the non-stained or control group. However, radiopaque substances provoke an inflammatory reaction in the regional lymph nodes and may affect lymph drainage (5). We initially stained lymphatic vessels and lymph nodes of dogs with chlorophyllin to observe the pathways along which tumor cells metastasize to supraclavicular lymph nodes. Coloration of lymphatic vessels and lymph nodes with chlorophyll was simple and effective (6). In this study, we further examined the effects of chlorophyllin on coloring of pelvic lymph nodes first in dogs and subsequently in patients with uterine carcinoma (cervical and endometrial).

Pelvic lymph nodes are typically small and numerous and are distributed along the major blood vessels and nerves. Because it is important to select an optimal injection site for staining regional lymph nodes, we evaluated the administration of chlorophyllin after dye instillation into the cervix of patients with cervical or endometrial carcinoma.

MATERIALS AND METHODS

Preparation of Chlorophyllin Injection

Sodium copper chlorophyllin powder was purchased from Hangzhou Chlorophyllin Company. Chlorophyllin was dissolved with isotonic sodium chloride solution. The final solution (0.3%) was sterilized with Millex-vv filter (0.1 μ m Millipore, MA), and preserved in a refrigerator (4°C) before administration.

Animal Experiments

Fifteen adult mongrel dogs (female, 11.2-21.8kg) were anesthetized with pentobarbital sodium (25mg/kg iv), and the abdomen opened. Chlorophyllin solution (2 ml) was injected into the uterus with a 24-gauge needle at 1 ml/min, and the abdomen closed. The dogs were divided into two groups. In five dogs, blood samples (4 ml) were serially obtained from the great saphenous vein at 1, 2, 4, 6, 8, 12, 18 and 24 h after injection, and the concentration of chlorophyllin in the blood was determined using a spectrophotometer. Ten other dogs after being similarly anesthetized and injected with chlorophyllin were exsanguinated from the femoral artery at 12, 24, 48, 96 and 144 h after injection. The common iliac nodes stained with chlorophyllin were removed and embedded with paraffin, sectioned and stained with hematoxylin and eosin. The distribution of chlorophyllin and pathologic changes of these lymph nodes were examined by light microscopy. For electron microscopy, tissue squares of the lymph nodes were fixed

overnight with 2.5% glutaraldehyde in 0.1M sodium cacodylate buffer for 1h, dehydrated in graded ethanols and processed for Quetol 812 embedding. Semithin and ultrathin sections were obtained with LBK ultratome (Luzex III, Nireco). Ultrathin sections were stained with uranyl acetate and lead citrate and examined in a TEM 1200 EXIII electron microscope (Hitachi, Tokyo).

CLINICAL EXPERIENCE

Twenty-four patients with cervical carcinoma and twenty patients with endometrial carcinoma underwent radical hysterectomy and retroperitoneal lymphadenectomy. According to criteria of the International Federation of Gynecology and Obstetrics (FIGO), clinical stages of the uterine carcinoma were determined. Eighteen patients with cervical carcinoma (16 squamous carcinomas, 2 adenocarcinomas) were stage Ib, and six patients (4 squamous carcinomas, 2 adenocarcinomas) were stage II. The patients aged from 35 to 68 years (mean 54 years). All endometrial carcinoma were adenocarcinomas. Sixteen patients were at stage Ig₁ lesions, two at Ig₂ and two at Ig₃. The patient ages were 45 to 66 years (mean 57 years). The patients with cervical and endometrial carcinomas were subdivided randomly into lymphatic coloration group (23 patients) and non-coloration injected or control group (21 patients). In the "coloration" group (13 patients with cervical carcinoma and 10 patients with endometrial carcinoma), patients were placed in the lithotomy position and the vagina and cervix "sterilized" with 1% gentian violet. 0.3% chlorophyllin (8 ml) was injected into four sites of the cervix via a 24-gauge needle. In the patients with cervical carcinoma, chlorophyllin was injected into the parenchyma surrounding the tumor. The speed of injection was 1 ml/min. Retroperitoneal lymphadenectomy was performed 4 days after injection of chlorophyllin (author JX). The lymph nodes colored with chlorophyllin

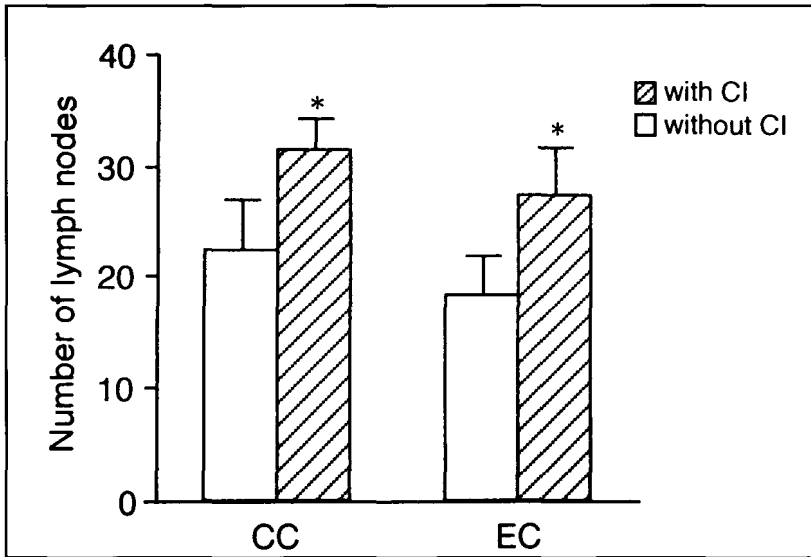


Fig. 1. Concentration of chlorophyllin in canine venous blood, after chlorophyllin was injected into the uterus. Blood samples were obtained from the great saphenous vein and measured with a spectrophotometer. Note that the bloodstream concentration of chlorophyllin was highest 4h after injection.

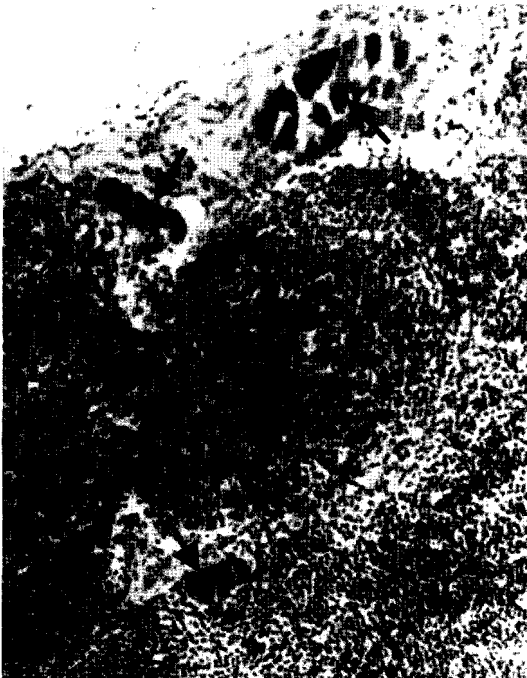

Fig. 2. Photomicrography showing chlorophyllin (arrows) in the subcapsular sinus and peritrabecular sinus of a canine common iliac lymph node, removed 2h after uterine injection of chlorophyllin. Original magnification $\times 100$.

were examined, the total number of removed lymph nodes recorded, and the time duration for lymphadenectomy noted. The removed pelvic lymph nodes were studied by a single pathologist. Frozen sections of lymph nodes stained with chlorophyllin were made with a cryostat and stained with hematoxylin and eosin. The distribution of chlorophyllin in lymph nodes was observed by light microscopy. In the non-chlorophyllin injected or control group (11 patients with cervical carcinoma and 10 patients with endometrial carcinoma), the duration of lymphadenectomy and numbers of the dissected pelvic lymph nodes were similarly recorded. Permission from the patients and from Science and Technology Committee of Shandong Province and Weifang People's Hospital was obtained beforehand.

Statistics

Values in the text, table, and figures are shown as mean \pm standard deviation (SD). Student's t-tests for paired samples were performed. A $p < 0.05$ level was taken as significant.

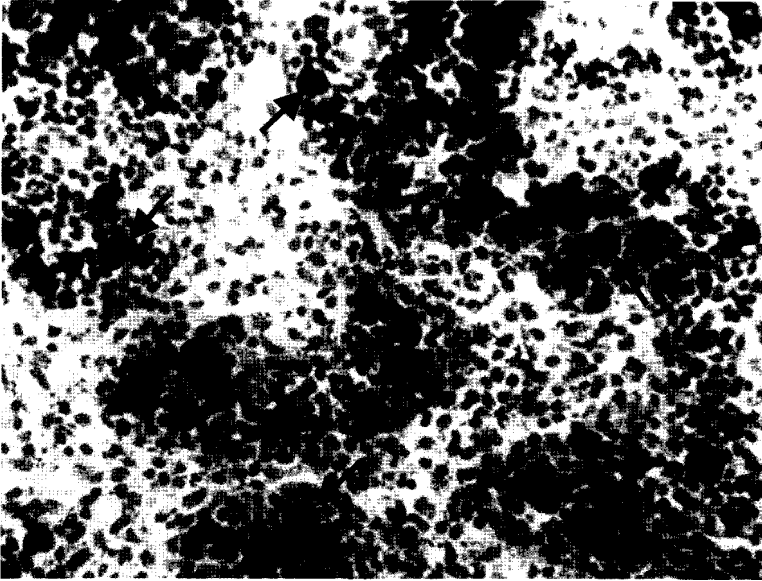


Fig. 3. Photomicrograph showing chlorophyllin phagocytosed by macrophages (arrows) in canine common lymph node 24h after injection of chlorophyllin into the uterus. Note lack of chlorophyllin in the lymphatic sinuses. Original magnification x200.

RESULTS

Animal Experiments

Lymphatic vessels and regional lymph nodes were colored green promptly after chlorophyllin was injected into the canine uterus. The common iliac nodes and lumbar nodes became green within 5 min after dye injection. The green lymph nodes contrasted sharply with nearby blood vessels, nerves and connective tissue. No notable extravasation of chlorophyllin from lymphatic vessels and lymph nodes was detected. Concentration of chlorophyllin in venous blood was highest 4h after injection (*Fig. 1*), but could not be detected 24h after uterine injection. In the dye-colored lymph nodes, lymphatic sinuses contained chlorophyllin within 24h after injection (*Fig. 2*), and chlorophyllin was phagocytosed by macrophages (*Figs. 3,4*). The tissue structure of the lymph nodes was otherwise unremarkable. Specifically, no inflammatory reaction was observed.

Clinical Observations

Patients had no complications or pain after administration of chlorophyllin into the uterine cervix. In frozen sections of the dye-colored lymph nodes, chlorophyllin was located in macrophages of the lymphatic cords. No inflammatory changes were observed. Numbers of the dissected lymph nodes obtained from patients with cervix carcinoma and endometrial carcinoma in the coloration group and control group are shown in *Table 1*. In patients with cervical carcinoma, 408 lymph nodes (31.38 ± 2.57) were excised in the coloration group. In 352 pelvic lymph nodes, 278 (78.98%) were colored well, 59 (16.76%) were partly colored, and 15 (4.26%) were not colored. In the control group, 225 lymph nodes (20.45 ± 4.28) were excised. The difference was statistically significant ($p < 0.01$) (*Table 1, Fig. 5*). The time duration of lymphadenectomy was 57 min in the coloration group and 74 min in the control group. Again, the difference was significant ($p < 0.01$).

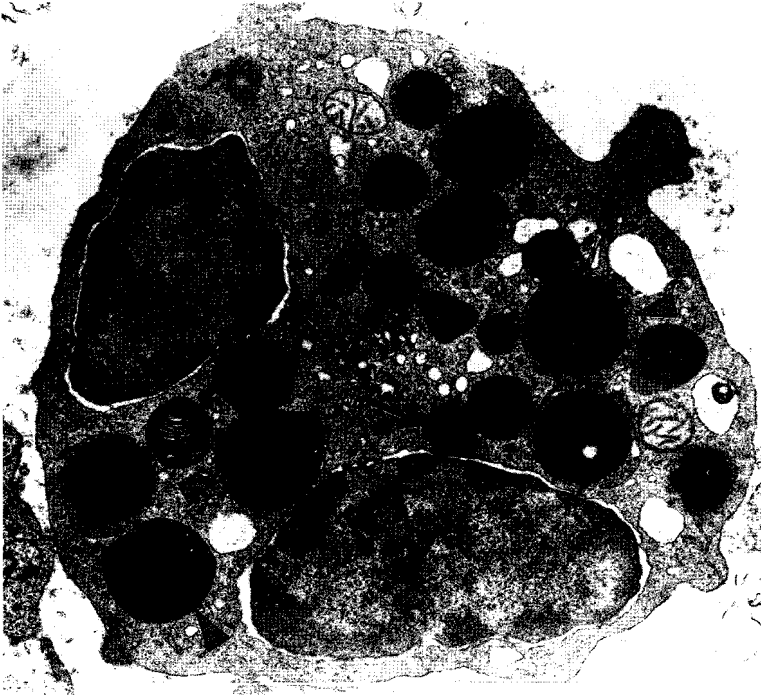


Fig. 4. Electron microscopic photograph of a macrophage in a canine lymph node. There are phagosomes (arrows) and second lysosomes (arrowheads) containing chlorophyllin in the cell. Bar, 2 μ m.

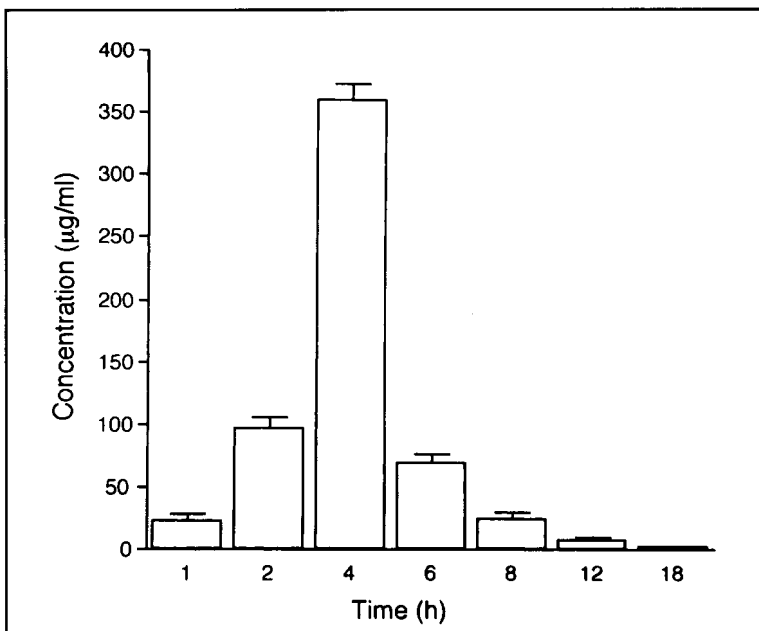


Fig. 5. Numbers of the dissected lymph nodes from patients with cervical carcinoma (CC) and endometrial carcinoma (EC). Number of the dissected lymph nodes in the lymphatic coloration group is greater than in the control group. * $p < 0.01$, Cl=chlorophyllin injection.

TABLE 1
Number of Specific Pelvic Lymph Nodes Dissected From the Patients
With and Without Chlorophyllin Injection

Groups	Patients (23) with cervical carcinoma		Patients (21) with endometrial carcinoma	
	without CI (11)	with CI (13)	without CI (11)	with CI (10)
Left— common iliac nodes	1.60±1.26	1.60±0.85	1.40±0.97	1.90±0.99
external iliac nodes	2.70±0.95	3.15±1.14	2.40±0.95	3.30±1.49
internal iliac nodes	1.00±0.82	2.00±1.08**	0.90±0.74	2.20±1.15**
obturator nodes	3.05±1.35	4.46±1.90	2.80±1.23	3.20±1.23
deep inguinal nodes	2.30±0.22	2.08±1.04	2.00±0.82	2.10±0.74
Right— common iliac nodes	1.70±1.06	2.85±0.99*	1.20±1.03	2.50±0.71**
external iliac nodes	3.10±0.88	4.38±1.56*	2.30±0.82	3.00±1.70
internal iliac nodes	1.00±0.94	2.69±1.41**	1.00±0.82	2.80±0.92**
obturator nodes	3.20±1.23	4.69±1.49*	2.30±1.64	4.20±1.87**
deep inguinal nodes	2.30±0.68	2.23±0.83	2.10±0.74	2.30±1.16

The values are mean ± standard deviation of them. *p<0.05 vs. the group with CI; **p<0.01 vs. the group with CI. CI=chlorophyllin injection.

In the patients with endometrial carcinoma, 274 lymph nodes (27.40±3.95) were removed in the coloration group. In 230 pelvic lymph nodes, 204 nodes (88.7%) were stained well, 24 (10.43%) were partly stained, and 2 (0.87%) were not stained. In the control group, 184 lymph nodes (18.4±3.13) were removed. The difference was statistically significant (p<0.01) (Table 1, Fig. 5). The duration of lymphadenectomy was 55 min in the coloration group and 72 min in the control group respectively. Again, the difference in duration of the operation between the two groups was significant (p<0.01).

DISCUSSION

In this study, we demonstrated that chlorophyllin is a useful dye for staining lymph nodes and for facilitating lymphadenectomy in patients with uterine cancer.

The pelvic lymph nodes were starkly stained green by chlorophyllin and contrasted sharply with surrounding blood vessels and nerves, thereby facilitating and expediting lymphadenectomy. Hirsch et al (2) reported that isosulfan blue is a safe and efficacious vital dye for lymphangiography and this dye is widely used for coloring sentinel lymph nodes (4,7). Hagiwara et al (3) observed that activated carbon particle (CH 40) is preferably absorbed by lymphatic capillaries and lymphatic vessels rather than blood vessels. CH 40 has been used for coloring lymph nodes during operation (8). Chlorophyll is a normal green pigment in leaves, bacteria and microorganisms capable of photosynthesis, and can be utilized by the body after ingestion for formation of physiologically active pyrrole pigments. Chlorophyllin is a water-soluble derivative of chlorophyll and no toxic symptoms result from its subcutaneous injection at dosages of

0.2-1.0 g/kg (9). We found that chlorophyllin had no adverse effects and does not cause an inflammatory reaction of dye-colored lymph nodes. Analysis of the blood samples suggests chlorophyllin in lymphatic sinuses empties by 24h after administration, with residual chlorophyllin being phagocytosed by macrophages. Chlorophyll-Ethiodol has been recommended for diagnosing regional lymph nodal metastasis of malignant pelvic tumors and to facilitate removal of lymph nodes. However, Ethiodol is an oily radiopaque material that causes a local inflammatory reaction and delays emptying of lymph nodes. Moreover, lymph nodes retain Ethiodol for two to three months or longer and the contrast agent may adversely affect lymph drainage and immune functions (1,5,10). Subcutaneous injection of patent blue, on the hand, on occasion causes an allergic reaction in patients (11,12). Allergic reaction to chlorophyll has not been found thus far by us or others (1,9). Our results suggest that coloration of pelvic lymph nodes with chlorophyllin facilitates a more complete dissection of regional lymph nodes and reduces the time of operation by helping to avoid injury to nearby blood vessels and pelvic nerves.

This is the first study to color pelvic lymph nodes by injecting chlorophyllin into the cervix before elective lymphadenectomy. Although the cervix is innervated by pelvic splanchnic nerves, the patients reported no pain on cervical injection of chlorophyllin. Because the tissue of the cervix is compact, injection favors creation of raised local tissue pressure and forced drainage of the green dye to nearby lymphatic vessels and lymph nodes. Injection of colored dye into superficial lymphatics of the foot promotes staining of sacral and obturator lymph nodes (13). The obturator nodes are embedded in connective tissue of the obturator fossa and close to the obturator blood vessels and obturator nerve. Cervical carcinoma often metastasizes to these nodes (5). In this study, a major advantage of injecting chlorophyllin into the

cervix is preoperative coloration of regional pelvic lymph nodes that drain the uterus directly. Lymphadenectomy is probably best performed 4 days after injection of chlorophyllin in order to have minimal edema of the cervix at time of operation while staining the pelvic lymph nodes optimally. Earlier we observed in dogs that intra-lymphatic injection of chlorophyllin into internal spermatic lymphatics colors the external iliac, common iliac, and lumbar lymph nodes (6). Perhaps similar administration of chlorophyllin into male genitalia with drainage via internal spermatic lymphatics may prove useful for facilitating lymphadenectomy in men with testicular and/or penile cancer.

ACKNOWLEDGMENTS

This study was supported by Scientific Research Foundation of State Education Commission for Returned Overseas Chinese Scholars to Haijie Wang (97832) and Fund of Science and Technology Committee of Shandong Province.

REFERENCES

1. Averette, HE, R Ravel: Lymphography with chlorophyll: Effects on pelvic lymphadenectomy and lymph nodes. *Obstet. Gynecol.* 31 (1968), 247-254.
2. Hirsch, J, J Tisnado, SR Cho, et al: Use of isosulfan blue for identification of lymphatic vessels: Experimental and clinical evaluation. *AJR* 139 (1982), 1061-1064.
3. Hagiwara, A, T Takahashi, K Sawai, et al: Lymph nodal vital staining with newer carbon particle suspensions compared with India ink: Experimental and clinical observations. *Lymphology* 25 (1992), 84-89.
4. Joosten, JJA, LJA Strobbe, CAP Wauters, et al: Intraoperative lymphatic mapping and the sentinel node concept in colorectal carcinoma. *Br. J. Surg.* 86 (1999), 482-486.
5. Abitbol, MM, C Meng, SL Romney: Anatomic and therapeutic aids of lymphangiography in pelvic malignancy. *Am. J. Obstet. Gynec.* 93 (1965), 95-101.
6. Tan, Y, H Wang, X Wang: Observation and image analysis on lymph node sections after

- injecting cancer cell suspension into canine internal spermatic lymphatics. *Acta Anatomica Sinica* 28 (1997), 433-437 (in Chinese).
7. Zavotsky, J, N Hansen, MB Brennan, et al: Lymph node metastasis from ductal carcinoma in situ with microinvasion. *Cancer* 85 (1999), 2439-2443.
 8. Okamoto, K, K Sawai, H Minato, et al: Number and anatomical extent of lymph node metastases in gastric cancer: Analysis using intra-lymph node injection of activated carbon particle (CH40). *Jpn. J. Clin. Oncol.* 29 (1999), 74-77.
 9. Kephart, JC: Chlorophyll derivative—their chemistry, commercial preparation and uses. *Econ. Bot.* 9 (1955), 3-38.
 10. Averette, HE, RC Hudson, MI Jr Viamonte, et al: Lymphangiadenography (lymphography) in the study of female genital cancer. *Cancer* 15 (1962), 769-775.
 11. Sinclair, DJ, FA Perera: Allergic reactions: Following patent blue dye administration. *Can. Med. Assoc. J.* 101 (1969), 100-101.
 12. Mortazavi, SH, BD Burrows: Allergic reaction to patent blue dye in lymphangiography. *Clin. Radiol.* 22 (1971), 389-390.
 13. Howett, M, EA Elmendorf: Pelvic lymphangiography in normal and pathologic states. *Obstet. Gynecol.* 26 (1965), 34-45.

Haijie Wang, MD, PhD
Department of Anatomy
Shanghai Medical University
138 Yi Xue Yuan Road
Shanghai 200032
People's Republic of China
Tel: 021-64041900-2430
Fax: 021-64037268
e-mail: haijiew@hotmail.com