

Iliotibial Band Syndrome in Runners

Innovations in Treatment

Michael Fredericson¹ and Chuck Wolf²

- 1 Stanford University School of Medicine, and Stanford University Cross-Country and Track Teams, Stanford, California, USA
- 2 Human Motion Associates, Gotha, Florida, USA

Contents

Abstract	451
1. Anatomy	452
2. Aetiology	453
3. Patient Evaluation	453
3.1 History	453
3.2 Physical Examination	453
3.3 Myofascial Restrictions	454
3.4 Flexibility Tests	454
3.5 Strength Tests	454
3.6 Imaging Studies	455
3.7 Differential Diagnosis	455
4. Treatment and Rehabilitation	455
4.1 Acute Phase	455
4.2 Subacute Phase	456
4.3 Recovery Strengthening Phase	456
4.3.1 Modified Matrix	457
4.3.2 Wallbangers	457
4.3.3 Frontal Plane Lunges	458
4.3.4 Development of the Supinators of the Loading Leg	458
4.3.5 Development of the Pronators of the Loading Leg	458
4.4 Return-to-Running Phase	458
4.5 Surgical Management	458
5. Conclusion	459

Abstract

Iliotibial band syndrome (ITBS) is the most common cause of lateral knee pain in runners. It is an overuse injury that results from repetitive friction of the iliotibial band (ITB) over the lateral femoral epicondyle, with biomechanical studies demonstrating a maximal zone of impingement at approximately 30° of knee flexion. Training factors related to this injury include excessive running in the same direction on a track, greater-than-normal weekly mileage and downhill running. Studies have also demonstrated that weakness or inhibition of the lateral gluteal muscles is a causative factor in this injury. When these muscles do not fire properly throughout the support phase of the running cycle, there is a decreased ability to stabilise the pelvis and eccentrically control femoral abduction. As a result, other muscles must compensate, often leading to excessive soft tissue

tightness and myofascial restrictions. Initial treatment should focus on activity modification, therapeutic modalities to decrease local inflammation, nonsteroidal anti-inflammatory medication, and in severe cases, a corticosteroid injection. Stretching exercises can be started once acute inflammation is under control. Identifying and eliminating myofascial restrictions complement the therapy programme and should precede strengthening and muscle re-education. Strengthening exercises should emphasise eccentric muscle contractions, triplanar motions and integrated movement patterns. With this comprehensive treatment approach, most patients will fully recover by 6 weeks. Interestingly, biomechanical studies have shown that faster-paced running is less likely to aggravate ITBS and faster strides are initially recommended over a slower jogging pace. Over time, gradual increases in distance and frequency are permitted. In the rare refractory case, surgery may be required. The most common procedure is releasing or lengthening the posterior aspect of the ITB at the location of peak tension over the lateral femoral condyle.

Iliotibial band syndrome (ITBS) is the most common cause of lateral knee pain in runners, with incidence as high as 12% of all running-related overuse injuries.^[1-4] The syndrome results from repetitive friction of the iliotibial band (ITB) sliding over the lateral femoral epicondyle. The ITB moves anterior to the epicondyle as the knee extends and posterior as the knee flexes, remaining tense in both positions.^[5]

Biomechanical studies^[6] of runners with ITBS show that in the running cycle, the posterior edge of the ITB impinges against the lateral femoral epicondyle of the femur just after foot strike. This 'impingement zone' (figure 1) occurs at, or at slightly less than, 30° of knee flexion. Repetitive irritation can lead to chronic inflammation, especially beneath the posterior fibres of the ITB, which are thought to be tighter against the lateral femoral condyle than the anterior fibres.

1. Anatomy

The ITB is considered a continuation of the tendinous portion of the tensor fascia lata (TFL) muscle, with some contribution from the gluteal muscles. It is connected to the linea aspera via the intermuscular septum until just proximal to the lateral epicondyle of the femur.^[7,8] Distally, the ITB spans out and inserts on the lateral border of the patella, the lateral retinaculum, and Gerdy's tubercle of the tibia. The

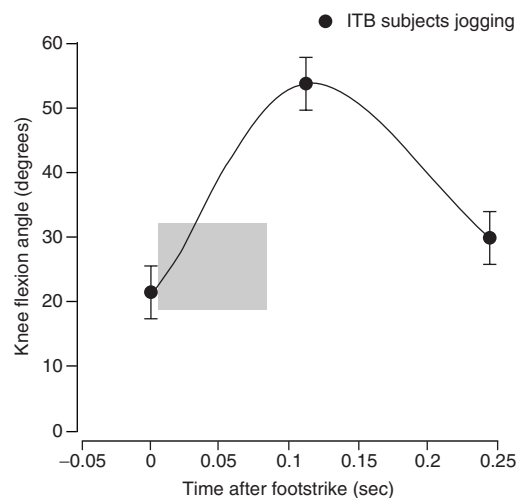


Fig. 1. Range of motion at the knee joint during the stance phase in subjects with iliotibial band (ITB) friction syndrome. Friction can occur in approximately the shaded area on the graph (this is the time in the weightbearing part of the gait cycle that the tensor fascia lata and gluteus maximus muscles are active) [reproduced from Orchard et al.^[6] Reprinted by permission of Sage Publications, Inc.].

ITB is free from bony attachment only between the superior aspect of the lateral femoral epicondyle and Gerdy's tubercle.^[8]

Together, the TFL, gluteus medius and gluteus minimus are considered the lateral gluteal muscles. The TFL is a short, straplike muscle that originates from the iliac crest just behind the anterior iliac spine and inserts into the ITB. The gluteus medius

and minimus originate at the posterior ilium between the posterior and anterior gluteal lines and insert into the greater trochanter. The gluteus medius is segmented into three distinct parts (anterior, middle and posterior) of approximately equal volume with distinct muscle fibre directions and independent innervations from the superior gluteal nerve. Gottschalk et al.^[9] believe that the posterior component of the gluteus medius and the whole gluteus minimus (both with force vectors that run almost parallel to the femoral neck) stabilise the femoral head in the acetabulum throughout the gait cycle. The anterior and middle parts of the gluteus medius have a more vertical pull and help to initiate abduction. Abduction is then completed by the tensor fasciae latae. It is critical that these muscles fire properly through the support phase of the gait cycle, eccentrically lengthening while stabilising the pelvis and controlling femoral abduction

2. Aetiology

Several training factors have been associated with ITBS, including excessive running in the same direction on a track, greater-than-normal weekly mileage, and downhill running, where decreased knee flexion at foot strike increases friction between the ITB and the lateral epicondyle.^[1,3,10]

Runners with ITBS have been found to be weaker in knee flexion and knee extension, with decreased maximal braking forces.^[10] Two Stanford University studies^[11,12] suggest that weakness in the hip abductors is another factor in ITBS. Fredericson et al.^[11] first evaluated 24 runners with ITBS and found that they all had significant weakness in the hip abductors of their affected limb compared with the uninjured limb and control runners. A second study by the Stanford University Biomechanics Lab^[12] prospectively evaluated peak hip adduction moments in 50 marathon runners at the beginning of their training programme. Seven of these runners subsequently developed ITBS during the course of their training season, and all of these had statistically significant increased peak hip adduction moments (representative of the decreased ability of the hip

abductors to eccentrically control adduction) when compared with the uninjured runners.

3. Patient Evaluation

3.1 History

The main symptom of ITBS is sharp pain or burning in the lateral knee. Patients typically start running pain-free, but develop symptoms after a reproducible time or distance. Initially, symptoms subside shortly after a run, but return with the next run. Patients often note that running downhill, lengthening their stride and sitting for long periods with the knee in a flexed position aggravates the pain. In more severe cases, pain can be present even with walking or when descending stairs.

3.2 Physical Examination

Results of the knee examination are typically unremarkable, except for local tenderness and occasional swelling over the distal ITB, 2–3cm proximal to the joint line, where the band moves over the lateral femoral condyle. Tenderness is less commonly seen at the lateral joint line, popliteal tendon, lateral collateral ligament, or anterior lateral fat pad. Occasionally, pain or paresthesia extend along the length of the band. Crepitation, snapping, or mild pitting oedema can occur over the affected area. Pain may be elicited with the Noble compression test. The patient lies on his or her side with the affected knee up and flexed 90°. The clinician applies pressure to the ITB over the lateral femoral condyle and extends the knee. The test is positive if pain occurs as the knee approaches 30° of flexion, the position in which the tensed ITB rubs directly over the lateral femoral condyle.^[4]

It is also important to test the flexibility of the gastrocnemius and soleus muscles. During closed-chain biomechanics, if these muscles are tight, the patient will have decreased ankle dorsiflexion, leading to an increase both in ankle pronation and knee flexion.

One should also screen for other causes of excessive ankle pronation including pes planus, compen-

sation for a forefoot varus, metatarsus adductus, or femoral or tibial torsion. These deformities can create an increased internal rotational moment to the leg and thigh, as well as magnification of the adductor moment created by underperforming abductors and external rotators of the hip.

Leg-length discrepancies also contribute to ITBS and should be assessed as part of a routine examination. These may be as a result of numerous factors, including true anatomic discrepancy and training on crowned roads. When a true anatomic discrepancy of $\geq 1\text{cm}$ is present, we recommend use of a heel lift or orthotic insert.^[1,3,13]

3.3 Myofascial Restrictions

Severe lateral knee pain associated with ITBS may be intensified by myofascial restrictions that are directly or indirectly associated with the excessive friction of the ITB sliding over the lateral femoral epicondyle. Myofascial restrictions include central and attachment trigger points,^[14] muscle contractures and fascial adhesions. These restrictions also may contribute to excessive tension on the ITB may precede and accompany the condition, or may linger after the primary friction syndrome has subsided. They can vary from a minor complication of ITBS to the primary cause of the lateral knee pain.

Evaluation often reveals tender areas in the vastus lateralis, gluteus minimus, piriformis and distal biceps femoris muscles.^[15] Within these tender areas, discrete trigger points are often found that can refer pain to the lateral thigh, the knee, or even the lateral lower leg. Examination consists of thorough and firm palpation of these trigger points. This is best performed with the patient in a relaxed side-lying position, with the hip on the symptomatic side flexed to about 45° and the knee slightly flexed. A pillow or bolster is placed under the leg to be palpated.

If the trigger points are sensitive and the patient reports sensations in the referral zones, myofascial treatment is strongly indicated. If the tissues are very tight and sensitive but produce no referral sensations, myofascial treatments still are likely to be effective. If no contracture, sensitivity or referral

patterns are evident, myofascial treatments are not indicated.

3.4 Flexibility Tests

We perform the modified Thomas test^[16,17] on all patients who have suspected ITBS to evaluate for flexibility deficits in the iliopsoas, rectus femoris and TFL/ITB. Ober's test is also recommended to evaluate tightness in the TFL/ITB complex.^[16]

3.5 Strength Tests

We evaluate hip abductor muscle strength in the side-lying position as described by Janda.^[17] Be aware that patients often will compensate for weakness or inhibition of the gluteus medius with substitution of the TFL, the quadratus lumborum muscles, or both. Hip abduction may be obtained by internal rotation and flexion of the hip due to the TFL, or hip hiking may be noted due to overactivation of the quadratus lumborum. A dysfunctional firing pattern also may be the source of chronic TFL tightness. The normal firing pattern should be gluteus medius, followed by TFL, ipsilateral quadratus lumborum and erector spinae.^[16]

We then recommend several functional tests, as described by the physical therapist, Gary Gray.^[18] The single-leg balance, anterior-ipsilateral reach test (figure 2) creates an environment in which the foot pronates. This results in lower extremity internal rotation and hip internal rotation, giving the clinician the opportunity to assess strength and range of



Fig. 2. Single-leg balance, anterior-ipsilateral reach test.



Fig. 3. Single-leg balance, frontal plane overhead reach test.

motion of the gluteals in the sagittal and transverse planes. We use a measuring pole and tape measure to assess the distance reached and how low the patient can go. This is an integrated assessment that evaluates the foot's ability to pronate and the entire lower extremity's ability to decelerate motion. We compare both sides for fluidity and symmetry of motion and total distances.

The single-leg balance, frontal-plane overhead reach test (figure 3) is used to assess the lateral gluteal region and its ability to decelerate motion in the frontal plane. In this test, the patient stands at a right angle to, and about 51–61cm from, the wall. The patient then performs an overhead reach using the arm farthest from the wall, while the clinician observes the patient for symmetry and fluidity of motion in the frontal plane. If motion is compensated for by excessive lateral flexion in the torso due to hip tightness in the frontal plane, this is indicative of tight lateral gluteal muscles. If the patient is able to perform the initial reach, he or she is then asked to move about 5cm further away from the wall and continue performing the reach until his threshold is determined.

3.6 Imaging Studies

If the diagnosis appears straightforward, routine imaging is rarely indicated; radiograph results are usually normal. However, radiographs may reveal a prominent lateral femoral epicondyle, which may increase the risk of impingement by jutting into the impingement zone and may be an indication of

chronic impingement. Magnetic resonance imaging studies usually are reserved for patients being considered for surgery for other knee conditions (e.g. meniscal tear). Patients with ITB syndrome may show a thickened ITB over the lateral femoral epicondyle and often a fluid collection deep to the ITB in the same region.^[19]

3.7 Differential Diagnosis

The differential diagnosis for lateral knee pain includes primary myofascial pain, patellofemoral stress syndrome, early degenerative joint disease, lateral meniscal pathology, superior tibiofibular joint sprain, popliteal or biceps femoris tendinitis, common peroneal nerve injury and referred pain from the lumbar spine. In most patients, these conditions can be ruled out easily with a careful history and physical examination. A local anaesthetic injection may help to differentiate soft-tissue pain from intra-articular or referred pain.

4. Treatment and Rehabilitation

4.1 Acute Phase

The immediate treatment goal is to reduce local inflammation at the site of ITB friction over the lateral epicondyle. Ice massage, phonophoresis, or iontophoresis are useful modalities. Oral nonsteroidal anti-inflammatory medications also may help reduce pain and inflammation. None of these are effective, however, unless the runner modifies activity. Sometimes all that is necessary is to avoid downhill running or running in one direction on a track. More commonly, however, all running and any other potentially exacerbating activity, such as cycling, should be avoided to reduce the repetitive mechanical stress at the lateral femoral condyle. Swimming (using only the arms) with a pool buoy between the legs is usually the only activity permitted during the acute phase. If grossly visible swelling in the area does not subside after 3 days of treatment, a local corticosteroid injection may be helpful to reduce local inflammation.



Fig. 4. Standing iliotibial band stretches.

4.2 Subacute Phase

Stretching exercises are started after acute inflammation subsides. When the lateral gluteal muscles become weak and do not perform their function, other muscles must compensate and perform work for which they are not suited.^[20] Contraction-relaxation exercises to lengthen shortened muscle groups are performed in three sets, consisting of a 7-second submaximal contraction followed by a 15-second stretch. Particular attention is given to increasing the length of the TFL/ITB complex.

Research at the Stanford Biomotion Lab compared the effectiveness of three common variations of the standing ITB stretch: (i) arms at sides; (ii) arms extending overhead; and (iii) arms reaching diagonally downward.^[21] Three-dimensional images of the biomechanics of five elite male distance runners were captured using a four-camera gait acquisition system with a forceplate. Lengthening of ITB tissue, as well as force generated within the stretched complex (average adduction moments), was greatest when adding an overhead arm extension to the standing ITB stretch. Athletes can try all three stretches (figure 4) to see which feels best for their body. To perform the standing stretch, the patient stands upright, using a wall for balance if needed. The symptomatic leg is extended and adducted across the uninvolvement leg. The patient exhales and slowly flexes the trunk laterally to the opposite side until a stretch is felt on the side of the hip. It is important that the foot on the side being stretched can reach optimal pronation, allowing the hip to

fully load eccentrically. Extending or tucking the pelvis can vary the area being stretched. The arm overhead standing stretch accentuates the stretch by increasing lateral trunk flexion. A more transverse plane stretch is made by bending downward and diagonally while reaching out and extending the arms with clasped hands

Myofascial restrictions should also be addressed once acute inflammation subsides. Identifying and eliminating these restrictions complements physical therapy and should precede strengthening and muscle re-education. Soft-tissue treatment significantly improves pain and often serves to definitively treat the condition. Combining this treatment with use of the foam roll and isolated stretches for the tight muscle is particularly effective in releasing myofascial restrictions (figure 5).

4.3 Recovery Strengthening Phase

Strengthening exercises can begin once range-of-motion and myofascial restrictions are resolved. There are many approaches to strengthening the hip abductors. In previous articles, we outlined a programme that started with concentric side-lying leg lifts that then progress to single-leg balance, step downs, and single-leg balance, pelvic drop exercises.^[11,15] While this approach has proved to be quite successful throughout the years, more recently we have begun to add exercises that put even greater emphasis on eccentric muscle contractions, triplanar motions and integrated movement patterns. For all exercises, it is advisable to start with 5–8 repetitions and gradually build to 2–3 sets of 15 repetitions, repeating the exercise on both legs, even if only one



Fig. 5. Foam roll mobilisation for iliotibial band.

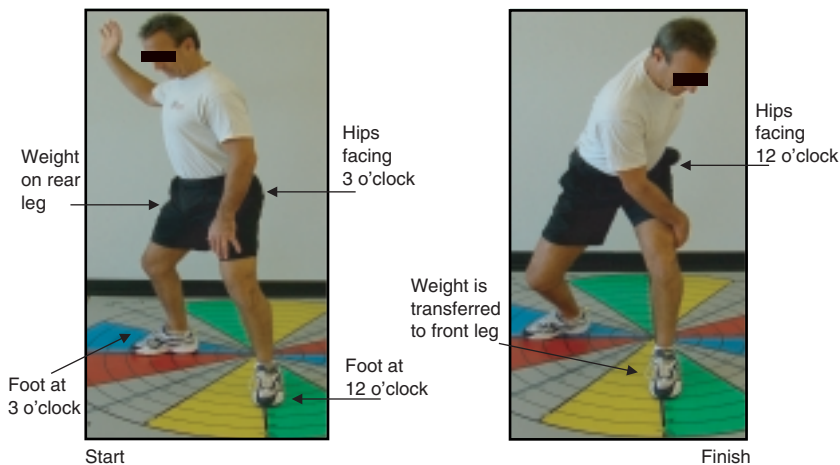


Fig. 6. Modified matrix exercise.

side is symptomatic. Examples of some of our more recent exercises are listed in sections 4.3.1–4.3.5.¹

4.3.1 Modified Matrix

To perform the modified matrix exercise (figure 6), the patient starts from a ‘stand-tall’ position, abdominals drawn in, with the feet shoulder width apart. The patient is instructed to point the left foot to the 12-o’clock position and the right foot to the 3-o’clock position. Next, the patient puts the right arm in an abducted and externally rotated position. While rotating the hips toward the left leg and transferring weight to the left leg, the patient reaches with the right hand to a point between the left hip and knee. As the patient reaches, it is imperative that he or she lower the hip as the spine flexes so that loading is felt in the hips, legs and lower back. The patient should then return to the start position by rotating the hips back to the left. Be sure a weight transfer to the right leg occurs.

4.3.2 Wallbangers

The patient stands 15–30cm from the wall (the distance will vary depending on range of motion and strength of the lateral gluteal muscles) with the right shoulder closest to a wall. Again, starting from the same stand-tall position, the patient reaches out to

the left. As the patient reaches out to the left, he or she should rotate the hips toward the left foot, flex the knees, drop the hips and maintain a neutral lumbar spine. The natural reaction when performing this movement is for the right hip to move toward the wall. The patient lets his right hip ‘bang’ into the wall (figure 7) and then immediately returns to the start position. It is critical that the patient *does not* hold the reaching position, as this removes the elastic recoil tendency of the muscle and thereby



Fig. 7. Wallbanger exercise.

1 Please keep in mind the range of motion and rotation will vary for each exercise depending upon the runner’s ability to eccentrically load through the three planes of motion, especially the frontal and transverse planes. This action will become greater as the person improves range of motion, which will inherently and functionally improve strength.

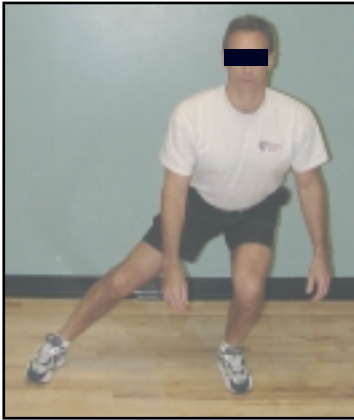


Fig. 8. Frontal plane lunges.

removes the eccentric loading required in this movement pattern. The patient then returns to the stand-tall position.

4.3.3 Frontal Plane Lunges

The patient stands with the feet approximately shoulder-width apart, knees slightly flexed and abdominals drawn in. The patient steps to the 9-o'clock position until he or she feels tension in the gluteal muscles and lower extremities and then immediately returns to the start position (figure 8).

4.3.4 Development of the Supinators of the Loading Leg

In this exercise, the patient performs the frontal plane lunge (see section 4.3.3) with a contralateral (opposite-sided) reach (figure 9). Depending on the range of motion of the patient's thoracic spine, external hip rotators and opposite or weight-loading gluteal muscles, the reach will vary. Range of motion will become greater as more flexibility in these structures is acquired. This movement pattern will cause greater activation of the peroneal muscles of the loading leg. This is due to the supination that occurs as a result of external rotation of the distal lower extremity during the reach.

4.3.5 Development of the Pronators of the Loading Leg

To perform this exercise, the patient again performs the frontal plane lunge with a medial reach (figure 10). This causes pronation of the subtalar

joint and an internal rotation reaction of the tibia, femur and hip.

4.4 Return-to-Running Phase

Return to running depends on the severity and chronicity of the condition and the patient's premorbid function. Most patients fully recover by 6 weeks. As a general rule, patients can return to running once they can perform all strengthening exercises with proper form and without pain. We recommend running every other day for the first week, starting with easy sprints on level ground and avoiding any downhill running for the first few weeks. Biomechanical studies^[6] show that faster-paced running is less likely to aggravate ITBS because at foot strike, the knee is flexed beyond 30° and the zone of impingement. During the next 3–4 weeks, gradual increases in distance and frequency are permitted.

4.5 Surgical Management

The majority of patients will respond to this conservative treatment. In the rare refractory case, various surgical techniques are recommended to decrease impingement of the ITB on the lateral femoral condyle. The most common procedures involve resecting a triangular piece of the ITB from the area overlying the lateral epicondyle when the knee is in a 30° flexed position,^[8] or Z-lengthening of the ITB.^[22]




Fig. 9. Frontal plane lunges with contralateral reach.




Fig. 10. Frontal plane lunges with medial reach.

5. Conclusion

A comprehensive approach to the treatment of ITBS involves more than the standard regimen of anti-inflammatory medication and ITB stretches. We outline a biomechanical approach that addresses muscle imbalances in the lateral hip muscles with deep tissue massage and strengthening exercises that emphasise triplanar motions and integrated movement patterns.

Acknowledgements

No sources of funding were used to assist in the preparation of this review. The authors have no conflicts of interest that are directly relevant to the content of this review.

References

1. Barber FA, Sutker AN. Iliotibial band syndrome. *Sports Med* 1992; 14 (2): 144-8
2. Clement DB, Taunton JE, Smart GW, et al. A survey of overuse running injuries. *Phys Sportsmed* 1981; 9 (5): 47-58
3. Linderburg G, Pinshaw R, Noakes TD. Iliotibial band syndrome in runners. *Phys Sportsmed* 1984; 12 (5): 118-30
4. Noble CA. Iliotibial band friction syndrome in runners. *Am J Sports Med* 1980 Jul-Aug; 8 (4): 232-4
5. Evans P. The postural function of the iliotibial tract. *Ann R Coll Surg Engl* 1979 Jul; 61 (4): 271-80
6. Orchard JW, Fricker PA, Abud AT, et al. Biomechanics of iliotibial band friction syndrome in runners. *Am J Sports Med* 1996 May-Jun; 24 (3): 375-9
7. Terry GC, Hughston JC, Norwood LA. The anatomy of the iliopatellar band and iliotibial tract. *Am J Sports Med* 1986 Jan-Feb; 14 (1): 39-45
8. Martens M, Libbrecht P, Burssens A. Surgical treatment of iliotibial band friction syndrome. *Am J Sports Med* 1989 Sep-Oct; 17 (5): 651-4
9. Gottschalk F, Kourosh S, Leveau B. The functional anatomy of tensor fascia latae and gluteus medius and minimus. *J Anat* 1989 Oct; 166: 179-89
10. Messier SP, Edwards DG, Martin DF, et al. Etiology of iliotibial band friction syndrome in distance runners. *Med Sci Sports Exerc* 1995 Jul; 27 (7): 951-60
11. Fredericson M, Cookingham CL, Chaudhari AM, et al. Hip abductor weakness in distance runners with iliotibial band syndrome. *Clin J Sport Med* 2000 Jul; 10 (3): 169-75
12. MacMahon JM, Chaudhari AM, Adriacchi TP. Biomechanical injury predictors for marathon runners: striding towards iliotibial band syndrome injury prevention [abstract]. Hong Kong: International Society of Biomechanics, 2000
13. Schweltnus MP. Lower limb biomechanics in runners with the iliotibial band syndrome, abstracted. *Med Sci Sports Exerc* 1993; 25 (5): S68
14. Simons DG, Travell JG, Simons LS. *Myofascial pain and dysfunction: the trigger point manual*. 2nd ed. Baltimore (MD): Williams & Wilkins, 1999
15. Fredericson M, Guillet M, DeBenedictis L. Quick solutions for iliotibial band syndrome. *Phys Sportsmed* 2000; 28: 52-68
16. Kendall FP, McCreary EK, Provan PG. *Muscles: testing and function*. 4th ed. Baltimore (MD): Williams & Wilkins, 1993
17. Janda V. *Muscle function testing*. London: Butterworths, 1983
18. Gray G. *Total body functional profile*. Adrian (MI): Wynn Marketing, 2001
19. Nishimura G, Yamato M, Tamai K, et al. MR findings in iliotibial band syndrome. *Skeletal Radiol* 1997 Sep; 26 (9): 533-7
20. Wolf C. IDEA. *Personal Trainer Magazine* 2002; Jul-Aug: 20-31
21. Fredericson M, White JJ, MacMahon JM, et al. Quantitative analysis of the relative effectiveness of 3 iliotibial band stretches. *Arch Phys Med Rehabil* 2002 May; 83 (5): 589-92
22. Richards DP, Barber FA, Troop RL. Iliotibial band Z-lengthening. *Arthroscopy* 2003 Mar; 19 (3): 326-9

Correspondence and offprints: Dr *Michael Fredericson*, Department of Orthopaedic Surgery, Division of Physical Medicine and Rehabilitation, Stanford University Medical Center, 300 Pasteur Drive, Stanford, R-107B, CA 94305-5336, USA.