

2015

# IMAGE ARTIFACTS IN OPTICAL COHERENCE TOMOGRAPHY ANGIOGRAPHY

R. F. Spaide  
*Northwell Health*

J. G. Fujimoto

N. K. Waheed

Follow this and additional works at: <https://academicworks.medicine.hofstra.edu/articles>

 Part of the [Ophthalmology Commons](#)

---

## Recommended Citation

Spaide R, Fujimoto J, Waheed N. IMAGE ARTIFACTS IN OPTICAL COHERENCE TOMOGRAPHY ANGIOGRAPHY. . 2015 Jan 01; 35(11):Article 1676 [ p.]. Available from: <https://academicworks.medicine.hofstra.edu/articles/1676>. Free full text article.

This Article is brought to you for free and open access by Donald and Barbara Zucker School of Medicine Academic Works. It has been accepted for inclusion in Journal Articles by an authorized administrator of Donald and Barbara Zucker School of Medicine Academic Works.



Published in final edited form as:

Retina. 2015 November ; 35(11): 2163–2180. doi:10.1097/IAE.0000000000000765.

## Image Artifacts in Optical Coherence Angiography

Richard F. Spaide, MD<sup>1</sup>, James G. Fujimoto, PhD<sup>2</sup>, and Nadia K. Waheed, MD<sup>3</sup>

<sup>1</sup>Vitreous, Retina, Macula Consultants of New York, New York, NY

<sup>2</sup>Department of Electrical Engineering & Computer Science and Research Laboratory of Electronics, Massachusetts Institute of Technology, Cambridge MA

<sup>3</sup>Department of Ophthalmology, Tufts University School of Medicine, Boston MA

### Abstract

To describe image artifacts of optical coherence tomography angiography (OCTA) and their underlying causative mechanisms. To establish a common vocabulary for the artifacts observed.

**Methods**—The methods by which OCTA images are acquired, generated and displayed are reviewed as are the mechanisms by which each or all of these methods can produce extraneous image information. A common set of terminology is proposed and used.

**Results**—OCTA uses motion contrast to image blood flow and thereby images the vasculature without the need for a contrast agent. Artifacts are very common and can arise from the OCT image acquisition, intrinsic characteristics of the eye, eye motion, or image processing and display strategies. OCT image acquisition for angiography takes more time than simple structural scans and necessitates trade-offs in flow resolution, scan quality, and speed. An important set of artifacts are projection artifacts in which images of blood vessels appear at erroneous locations. Image processing used for OCTA can alter vascular appearance through segmentation defects and because of image display strategies can give false impressions of the density and location of vessels. Eye motion leads to discontinuities in displayed data. OCTA artifacts can be detected by interactive evaluation of the images.

**Conclusions**—Image artifacts are common, and can lead to incorrect interpretations of OCTA images. Because of the quantity of data available and the potential for artifacts, physician interaction in viewing the image data will be required, much like what happens in modern radiology practice.

### Keywords

Artifacts; optical coherence tomography; optical coherence tomography angiography

### Introduction

In any imaging system, there is an object to be imaged and an image created. The image is a transformation that is related to the object through a series of rules. Unfortunately in every

real-world imaging method the image is not perfect— there are extra or missing pieces of information or the translation can go awry. These conditions lead to imaging defects called image artifacts. In fluorescein angiography, for instance, a bright crescent can be seen at the edge of an image if the edge of the iris is inadvertently included in the image or small cuneiform opacities if there is dust on the film or electronic sensor. Optical coherence tomography (OCT) angiography (OCTA) is a transformative approach in imaging ocular vessels based on flow, not simple reflectance intensity. There are a number of different techniques where flow can be derived from OCT signals. Each has the potential to visualize flow, but all methods have the potential to have additional, undesirable image artifacts that may not directly relate to flow. This paper will briefly review the techniques used to create OCTA images and then show various types of imaging artifacts that can be present. Almost every image artifact produced by an imaging system can be explained, but to do so proper understanding of the imaging strategies is required. A list of imaging terms related to OCTA is shown in the Table.

OCTA is a functional extension of OCT which visualizes microvasculature by detecting motion contrast from flowing blood.<sup>1–11</sup> The basis of OCTA is to repeatedly scan a region and then examine the resultant images for changes (Figure 1). Stationary tissue structures will show little change, while moving structures, in this case the flow of blood through vessels, can show changes from one image to the next (Figure 2). As there are many ways to measure an image, there are ultimately many ways to look for flow. Each of these methods has advantages and disadvantages, but all depend on constraints of the original OCT images. Within a region of the retina, discrete tissue locations are sampled by the OCT instrument, and a numerical value based on the reflectivity of the location is generated. This memory location is called a voxel, which is portmanteau of “volume” and “pixel”. Each voxel is an estimate of the actual reflective properties of a small volume of tissue. As in any other sampling technique, voxels can be subject to variation, some random, some not, which in aggregate are called noise. In areas where there is strong signal the noise component is small, while in areas of weak signal the noise may predominate. It is easier to be certain of change when comparing areas of large signal, but less so in regions of low signal because of the variability of noise. The proportional change in signal is measured at each voxel, and if the change is above a selected level, or threshold, flow is considered to be present. An image is created by displaying these values on a computer monitor. There are many techniques to display this information, and each has the potential to introduce artifacts into the image.

The resultant image looks like an angiogram, but is derived only from signals generated intrinsically from tissue, without the need for contrast agent injection. Therefore imaging can be performed rapidly and repeatedly, potentially on every patient visit, as well as in patients for whom fluorescein or indocyanine green angiography would not be indicated. In addition, because OCTA is depth resolved, it generates three dimensional datasets containing microvasculature flow information, enabling the retinal capillary plexuses and choroidal vasculature to be selectively viewed. OCTA differs from fluorescein angiography (FA) in that it cannot detect dye leakage, a marker of vascular permeability. On the other hand because there is no diffuse hyperfluorescence from dye leakage, OCTA has the potential to generate images with higher contrast and resolution of the microvasculature than conventional FA. Meanwhile, neighboring structural changes visible by structural OCT,

such as cystoid spaces in the retina or subretinal fluid, serve as clues that vascular leakage may be present. Indocyanine green angiography (ICA) demonstrates little leakage due to its high protein binding, and uses wavelengths longer than those employed for fluorescein angiography. This enables visualization of vessels below the retinal pigment epithelium (RPE), a location poorly visualized by FA. However the contrast seen in indocyanine green angiograms is low and the exact layer of vessels is often difficult to discern. OCTA visualizes vessels under the RPE and provides depth resolved images. In spite of these advantages, OCTA images can have many types of artifacts which are important to recognize when interpreting images. The goal of this manuscript is to provide a framework for the clinician to understand and recognize OCTA artifacts in order to reduce risk of misinterpretation.

## How is Motion Detected?

### Speckle or Intensity Decorrelation

One method for detecting motion contrast is to detect speckle or intensity changes in OCT structural images (Figure 3).<sup>5-7,10,11</sup> Light travels in waves and on striking an object, each reflecting point forms a secondary spherical wavefront. The superposition of the reflected waves can produce small regions where the light waves constructively or destructively interfere. With coherent light, such as a laser pointer, or even low coherence light as is used in OCT, the discrete areas of constructive interference can be seen as small speckles. When reflected from a stationary object the speckles will not vary much with time. Reflections from a moving object or a collection of moving objects will produce speckles that change more rapidly over time. In OCT a light beam is scanned across a region of the eye and the amount of reflection can be measured at each voxel. The scan is then repeated one or more times. The values of the pixels recorded at the two time points are compared. Areas showing large amounts of change are attributed to motion of erythrocytes in blood vessels. The faster areas of blood flow will show greater amounts of change over a given unit of time, but the exact relationship of this change versus flow speed depends on many parameters such as OCT beam size and blood vessel size, and is not necessarily linear. There are a variety of techniques used to measure the correlation between one B-scan and another.<sup>1-11</sup> Some papers refer to the intensity decorrelation in images, which is the converse of correlation. Other references calculate differences or derivatives between repeated images. Since the strength of the reflection changes between successive images, one method of describing the variation of reflection strength among pixels is to refer to “amplitude decorrelation”.

### Phase Variance

Another complementary method for detecting motion contrast is to assess changes in the phase of the light waves. The periodic fluctuations of waves of light can be likened to waves in the ocean. The crests of the wave can come at uniform periodic intervals. It is possible that a wave crest may come a little early or late and thus be out of phase with the interval between previous waves. Blood cells move and tumble and so there will induce a variation in the phase of light reflected from one instant to the next and this variance can be measured. Areas with no motion may not show zero variance because there is always residual motion and Brownian movement, but the variance will be low. For moving blood, the variance will

be much higher. Combinations of phase effects and simple amplitude changes can lead to hybrid techniques designed to gain advantages or avoid disadvantages of one specific technique or another. These theoretically could use more of the information present in the interferogram and thus more accurately characterize flow, but performance gains have yet to be proven.

## Origins of Artifacts in OCTA

Image artifacts can have multiple causes ranging from technical to clinical factors. These include: 1) how OCT data is acquired and generated, 2) the intrinsic properties of the eye and ocular pathology that is being imaged, 3) eye movement, and finally, 4) how the OCT data is processed and displayed as angiographic images. These factors govern performance as well as susceptibility to artifacts and help to conceptually frame the descriptions and examples in this manuscript.

### OCT Image Acquisition

The most practical way to perform the OCT imaging for angiography is to repeat B-scans over the same tissue position 2 to 5 times before proceeding to the next position. The sets of repeated B-scans are progressively made at successive offset positions perpendicular to the B-scan direction (a so-called “raster” pattern) to cover a field of view of the retina and in the process create a “volume scan”. This acquisition or scan protocol generates 3D data on both structure and motion contrast from blood flow. However, because OCTA requires scanning the same area multiple times, it is inherently slower than OCT structural imaging and requires trade-offs between the field of view, scan density, OCTA image quality, and image acquisition time. For these reasons, practical OCTA requires higher imaging speeds (faster A-scan rates) in comparison to structural OCT imaging.

### Intrinsic Properties of the Eye

Currently there are two main sets of wavelengths used to generate OCT images. Spectral domain (SD) OCT uses wavelengths near 800 nm, which is in the near infrared region while swept source (SS) OCT uses light sources slightly longer than 1000 nm. The longer wavelengths penetrate tissue somewhat better with the trade-off of slightly lower achievable axial resolution. SD-OCT has increased roll-off of sensitivity with depth as compared with SS-OCT and shorter wavelengths in SD-OCT are more susceptible to attenuation from scattering, limiting the ability to image the choroid. With both methods the signal from the choroid is low relative to the retina because light is lost due to scattering and attenuation from pigment in the RPE and from dense microvasculature in the choriocapillaris.<sup>12</sup> Both modalities suffer loss of signal with media opacities. Dense cataracts or diffuse vitreous hemorrhages cause a global loss of signal while focal opacities can cause a local loss of signal behind the opacity. Prominent vitreous floaters can obscure visualization of the retina and choroid (Figure 4), while subretinal hemorrhages can obscure visualization of the choroid. With large signal attenuation from whatever cause, it is more difficult to know if flow is present or not in the affected region. There are no published studies comparing the two modalities at present to determine which method is better, although theoretically SS-OCT should have fewer problems with media opacities.

## OCTA Projection Artifacts

Light passing through a blood vessel can be reflected, refracted or absorbed. The light reflected from moving blood cells forms the basis of OCTA. However the light that has passed through moving blood also encounters tissue below the blood vessel (Figure 3C). When this light strikes the RPE it is reflected back to the OCT instrument. The light that has passed through the blood vessels changes over time and so the reflection of this light is detected as having a decorrelation resembling blood flow (Figure 5). Therefore the RPE will appear to have blood vessels that have the pattern of the overlying retinal blood vessels. We refer to this effect as an OCTA projection artifact. OCT projection artifacts also occur from superficial retinal vessels which can appear in deeper retinal layers, or retinal and choroidal vessels which can even appear deep in the sclera. The OCTA projection artifacts are nearly always present and appear in any structure that is located below vasculature (Figure 6).

Understanding OCTA projection artifacts are important for accurate clinical assessment. For example, using OCTA to detect choroidal neovascularization may offer the possibility of patient diagnosis and follow-up without the need for fluorescein angiography. As such, we could image suspicious elevations and even in the absence of new vessels we might see fragments of images of the overlying retinal vessels (Figure 7). As another example, intraretinal pigment migration may serve as a reflecting point to suggest the presence of intraretinal neovascularization. OCTA projection artifacts can be readily identified by examining sequential en face images at different depths. Projection artifacts will cause superficial vessels to appear in en face images which are below the vessel, although the vessel has a limited axial depth. Some OCTA software implementations remove OCTA projection artifacts by subtracting them from images below. Snodderly estimated that 45% of photons passing through the perfoveal macula go through a blood vessel, and around the nerve the proportion is approximately 70%.<sup>13,14</sup> If a simple software algorithm was used to suppress projection images derived from the inner retina then a significant proportion of the pixels external to the retinal vessels would be suppressed or altered in some way by the algorithm. This creates the opportunity for a whole new set of image artifacts (Figure 6C).

While OCTA projection artifacts can be a hindrance, they also can be exploited. In fibrovascular pigment epithelial detachments, particularly those that have been treated with anti-vascular endothelial growth factor, there are several layers.<sup>15-17</sup> The inner most is the RPE, under this are the neovascular vessels, and deeper there appears to be a layer of fibrotic tissue. If the en face OCTA image is taken through the vessels themselves, the RPE will be included and then by default the projection images from the retinal vessels will also be seen (Figure 8). If the en face section is taken deeper, at the outer border of the vessels to include the fibrotic tissue, an image that is mostly composed of the projection from the neovascular vessels will be formed. In this case the best way to see the vessels is not to look directly at them, but to look at their projection.

The potential OCTA artifacts and what we are really seeing is a source of confusion when it comes to imaging the choriocapillaris (Figure 9). The choriocapillaris is located below and is separated from RPE by Bruch's membrane. The basement membrane of the RPE and that of the choriocapillaris form the outer layers of Bruch's membrane, which typically is 2 to 4 microns thick. Ramarattan et al<sup>18</sup> measured the choriocapillaris thickness in autopsy eyes

and found it ranged from 9.8 microns in the first decade of life to 6.5 microns in the tenth decade. When the image plane is selected to be at the level of the RPE, the projection image from the retinal vessels is seen. If an imaging slab is selected at the level where the choriocapillaris is expected to be, the retinal vessels dominate the image. If the section is moved deeper, to the hyporeflective region in the structural OCT where medium-sized vessels are expected to be seen, OCTA shows a fine interconnected layer of vessels without the retinal vascular projection image. Some of the vessels in this image look too large to be in the choriocapillaris, but the sheet of apparent high flow implies there is an OCTA projection from the choriocapillaris onto the deeper structures. Conversely, overlying pathology such as large drusen or pigment epithelial detachments can attenuate the OCT signal making regions of the choriocapillaris appear absent even though flow is likely to be present.

### Eye Motion

The goal of motion contrast techniques is to visualize the flow in vessels by looking for changes in successive repeated images. However changes in images can occur for reasons other than blood flow. Even small movements of the patient in general, or the eye in particular, can produce dramatic changes from one B-scan to the next. To reduce the effects of motion several strategies can be employed, depending on what type of motion is present. Motion of the retina and choroid can occur in the axial direction can result from pulsations related to the cardiac cycle, breathing, tremors, and microsaccades (Figure 10). This motion is manifest as a periodic displacement in the axial position of the entire retina and can be seen in volumetric structural OCT data. Because the position of the bulk retina changes with time, the corresponding decorrelation will be higher than if it were to remain stationary. Movement of reflective objects with no flow potentially can have enough decorrelation to cause the false positive appearance of flow (Figure 11). One way to reduce the effects of axial motion is to register, or align, successive B-scan images. Some OCTA image processing procedures, such as split spectrum amplitude decorrelation angiography (SSADA) reduce sensitivity to axial eye motion by reducing the axial resolution, then combine multiple lower resolution measurements in order to improve the angiographic signal to noise ratio.<sup>5</sup> In this case axial resolution is traded for decreased noise in the resulting angiographic image. Although these techniques are used to compensate for axial eye motion, transverse motion from changes in fixation and saccades remain a major source of artifacts in OCTA.

A microsaccade with return of fixation to the original position will cause a momentary change in location of the scan. The B-scans in that time period won't match because they are from different areas of the eye. The images will show large decorrelation for one or more adjacent B-scans, producing a white line artifact in the OCTA image (Figure 12). In addition, a temporary shift in fixation will cause the volume scan to be recorded from one area of the retina, and then after the change in fixation, from another area. This can produce an artifact where there is a lateral shearing of the image or it can create a shift in which areas of the fundus are lost.



One approach to deal with the image distortion caused by movements such as saccades is a software based method developed by Kraus and colleagues.<sup>19</sup> A series of two OCT volumes are obtained from the same region, first scanning acquiring B-scans in the horizontal direction, followed by scanning in the vertical (orthogonal) direction. Each B-scan is acquired rapidly, therefore distortion from eye motion within each B-scan is small. However, sequential B-scans require more acquisition time and distortion from eye motion becomes progressively worse for B-scans that are farther apart. The horizontal and vertical scanned OCT volumes represent the same retinal structures, but the effects of eye motion distortion will be different and complementary. Software based motion correction works by estimating the eye motion for each A-scan in the two volumes, translating each A-scan in the two volumes and then comparing the volumes. If the motion estimate was accurate, then the two OCT volumes should be nearly identical. This process is computationally intensive because there are many individual A-scans. In addition, it requires iteration - an initial motion estimate must be determined, tested for accuracy, updated, and the process repeated until a desired accuracy is obtained. Since this computation must be done rapidly enough to visualize the motion corrected data within a few seconds, it uses modern computer graphics cards that have been developed for video gaming and can perform rapid, highly parallel computation (Figure 13). This software approach can compensate for some movement artifacts, but can introduce artifacts of its own, including loss of detail in the image despite a high signal score, doubling of the retinal vessels (Figure 14), stretching defects (Figure 15), and a crisscross defect that looks like a quilt (Figure 16).

### Image Processing and Display

The random fluctuations of noise, particularly in low signal regions, can create a false appearance of flow when comparing one image to the next. In order to reduce this false flow artifact, a process called masking or thresholding may be used to only process OCTA from structures which have a sufficiently strong signal, effectively deleting OCTA data from low signal or noisy structures. Therefore reliable OCTA is only possible in regions where there is a strong OCT signal and artifacts can occur because of attenuation. Because the choroid has a low signal if the RPE and choriocapillaris are intact, the strategy of removing low signal results from the OCTA image compounds the difficulty of imaging flow in deeper choroidal vessels. In areas of atrophy of the RPE and choriocapillaris, these same vessels will appear to have flow (Figure 17).

OCTA has the powerful advantage that it provides three dimensional volumetric data on both retinal and choroidal vasculature. After OCTA volumetric data is generated, visualization methods are required in order to display vascular features. Most OCTA display methods generate en face images in order to be consistent with fundus imaging, such as fluorescein or indocyanine green angiography. In contrast to cross-sectional OCT structural imaging, cross sectional OCTA images are difficult to interpret because vascular networks cannot be appreciated. En face techniques which segment the layers of the retina are an efficient means for observing their contained vessels. Images of the radial peripapillary capillary network, the inner plexus of vessels and the deep plexus of vessels are readily visualized.<sup>19</sup> Unfortunately this strategy fails in numerous important situations where the normal retinal architecture is altered (Figure 19). En face imaging that relies on



segmentation strategies are going to have difficulty in eyes that are not normal. In diseased retinas edema, atrophy, bleeding, and tissue infiltration are likely to cause segmentation strategies developed in healthy eyes to fail. The resultant vascular images are not correct. The problem is compounded by decreased signal strength. In cases of retinal edema the layers increase in thickness in a variable way and contrast between the layer decreases, obviating segmentation algorithms based on normal tissue. MacTel type 2 is associated with retinal thinning and as a consequence separating the inner from the deep plexus can be difficult.<sup>20</sup> In high myopes the segmentation algorithm can fail (Figure 19), particularly in staphylomas. When the segmentation algorithms fail from any cause, layers of vessels are visualized together in ways that do not reflect actual anatomy. Interactive inspection of the sequential depth level en face slabs with the OCTA software would facilitate more accurate assessment of vascular architecture.

## The Challenge of Imaging the Living

OCTA visualizes blood flow by detecting erythrocyte motion, however the eye itself moves, so one of the major challenges is to detect erythrocyte motion separately from parasitic eye motion. The blood flow in capillaries is on the order of 1.5 to approximately 3 mm/sec,<sup>21,22</sup> and the erythrocytes travel in single-file. To produce an image that is 300 × 300 pixels, each fundus position has to be scanned at least twice to detect any type of change. The OCT beam has to be scanned across this region in a raster fashion, which itself incurs overhead in terms of wasted time during the beam scanning process. The newest commercial spectral domain OCT (SD-OCT) instruments operate at 70,000 A-scans per second and can acquire the 90,000 required A-scans twice in approximately 3 seconds. At 70,000 A-scans / second, it takes approximately 0.005 seconds to acquire each B-scan (300 A-scans) and each B-scan is performed twice, so the time between scans is ~0.005 seconds. Therefore to detect a ~2 mm/second blood flow, the system needs to be able to detect 0.01 mm (10 μm) of movement in 0.005 seconds. Disease states may cause a slower blood flow,<sup>23</sup> so the lower limit of detection needs to be much smaller than 0.01 mm. Creating a method that can detect 0.01 mm of movement in the allotted time is a challenge, and is even more complicated because the eye being imaged is connected to a living organism. (OCT instruments use mirrors, so imaging the undead is not possible.) A big problem is that methods which are highly sensitive to motion of blood can also be highly sensitive to patient eye motion, which is called bulk motion. Methods using phase information for motion contrast are especially sensitive to bulk motion and some research groups use bite plates to help stabilize the subject's head. Amplitude decorrelation methods have the advantage that they can be less sensitive to bulk motion effects.

## How Fast is Fast?

Successive B-scan images of the retina are compared over time in any decorrelation approach, including amplitude decorrelation and phase variance. Stationary tissue produces little decorrelation in images, while high flow is associated with more decorrelation. Ever decreasing flow rates cause lower and lower decorrelation signals. Some threshold is usually used to differentiate flow from no flow and to reduce noise in images. To make OCTA images have high vessel detection sensitivity, relatively low decorrelation values from slow

flows are rendered as bright pixels and somewhat lower values are rendered as dark pixels. This leads to a number of compromises. If slow flow looks bright, what about faster flow? These flows are also rendered as bright pixel values. Since further increases in flow do not increase the pixel brightness, the detection system is said to saturate. This effect makes absolute quantification of flow from OCTA images difficult at present. For example, in Figure 20 which shows an OCTA image of the inner retinal plexus, note that the larger and smaller vessels which have different flows, exhibit equivalent brightness. When the beam is scanned across the eye, flow signal can be detected even if the beam is not centered on the vessel. Given that the beam has a finite width and the flow representation saturates at a relatively low rate, vessels will be represented with a larger diameter than they really are. The widening can be thought of as a convolution function which will affect the diameter, proportionately, for smaller vessels more than larger ones (Figure 21).

Another aspect of detecting decorrelation as a marker for flow is that slow flow potentially could be rendered as a dark pixel, essentially a false negative flow signal. Slow flows may not be detected because they are below the sensitivity threshold. Some structures, such as microaneurysms can have slow flow. If the blood flow in the instant the microaneurysm is being imaged is below the sensitivity threshold, the microaneurysm will not appear in OCTA. In Figure 22 successive OCTA images of a diabetic show the variability in appearance of a set of microaneurysms. This has potential impact on using OCTA as a screening mechanism for diabetic retinopathy. If blood flow in ocular vessels or the choriocapillaris is slow, the vessels may be silent on OCTA, even if they are present. In addition flow is pulsatile - it is possible that in one interval between repeated B-scans there will not be enough flow in a region to be detected, while in another interval flow would be detected. Waiting longer times between scans would increase flow detection sensitivity, but at the expense of longer acquisition times and increased artifacts from bulk eye motion. Another approach that is used in cardiac imaging is to gate the imaging according to the cardiac cycle. This approach could conceivably be used in ocular imaging as well and may provide interesting research results in investigating choroidal blood flow.

Current commercial scan parameters of imaging a  $3 \times 3 \text{ mm}^2$  area with 0.01 mm A-scan density (100 A-scans per millimeter) are the result of trade-offs between area visualized, scan quality, and time. To increase the scan area to  $6 \times 6 \text{ mm}^2$  while maintaining the same scan density and examination time would require scan speed to be 4× greater than the 70,000 A-scans per second rate mentioned earlier, which is much more than any commercial OCT instrument currently available. Prior to the advent of OCTA, differences in scanning speed were not of much consequence, except for increasing the fundus area imaged. Now, because of the power and potential of OCTA increased scanning speeds are more desirable. As with any technology, price is highly related to quantity produced. At present very high speed OCT instruments are one-off devices using expensive components. If 10,000 instruments of the same design would be produced the per-unit cost would be much lower, but for a company to be willing to invest in the production of these instruments, demand must be present.

## A New Paradigm

Structural OCT scans can be evaluated using the interactive instrument software, but in some practices a paper printout of one page, often featuring a thickness map or a few B-scans is used. Evaluation of OCTA images for both clinical assessment and artifact detection is dependent on the operator interacting with the data. Looking at various levels of vascular data is inherently more time consuming than looking at a thickness map. Advanced methods to display OCTA data include volume rendering, which preserves the 3D character of the data and allows improved appreciation of the interrelationships among vessels because the images can be rotated in space. Volume rendering is a preferred method of visualizing radiologic images obtained from magnetic resonance or computed tomography. This method largely superseded average projection methods in radiologic evaluations. Other methods used in viewing radiologic information include multiplanar views in which orthoplanes extracted from volumetric data are viewed. This method may provide single page views that convey sufficient information obtained through OCTA, but with a potential loss of the richness of the information obtainable from an interactive interface, particularly one that can offer volume rendering. Combined viewing of OCT and OCTA orthoplane images should significantly reduce the risk of misinterpretation, while providing more comprehensive information on retinal pathology than was previously possible. Although it requires an adjustment of clinical workflow, adopting radiology reading methods for OCT and OCTA data in the future could significantly reduce risk of artifacts and improve interpretation, especially in the context of complex pathologies or surgical planning. In the shorter term, developing increased understanding of the origins of OCTA artifacts and how they are manifest in viewing OCTA data is important for clinical interpretation. There are significant challenges remaining and new paradigms are needed to more accurately display and interpret OCTA information.

## Acknowledgments

We gratefully acknowledge discussions with Tony Ko, Ph.D, Johnathan Liu, Ph.D. Kinpui Chan, Ph.D., Talisa de Carlo, and Eric Moulton. We acknowledge partial support from the Macula Foundation, National Institutes of Health R01- EY011289-29, Air Force Office of Scientific Research FA9550-12-1-0449, and the Champalimaud Foundation.

Supported by the Macula Foundation, New York, NY,

## References

1. Fingler J, Schwartz D, Yang C, Fraser SE. Mobility and transverse flow visualization using phase variance contrast with spectral domain optical coherence tomography. *Opt Express*. 2007; 15(20): 12636–12653. [PubMed: 19550532]
2. Fingler J, Readhead C, Schwartz DM, Fraser SE. Phase-contrast OCT imaging of transverse flows in the mouse retina and choroid. *Invest Ophthalmol Vis Sci*. 2008; 49(11):5055–5059. [PubMed: 18566457]
3. Yu L, Chen Z. Doppler variance imaging for three-dimensional retina and choroid angiography. *J Biomed Opt*. 2010; 15(1):016029. [PubMed: 20210473]
4. Liu G, Qi W, Yu L, Chen Z. Real-time bulk-motion-correction free Doppler variance optical coherence tomography for choroidal capillary vasculature imaging. *Opt Express*. 2011; 19(4):3657–3666. [PubMed: 21369191]

5. Jia Y, Tan O, Tokayer J, et al. Split-spectrum amplitude-decorrelation angiography with optical coherence tomography. *Optics Express*. 2012; 20(4):4710–4725. [PubMed: 22418228]
6. Mariampillai A, Standish BA, Moriyama EH, Khurana M, Munce NR, Leung MK, Jiang J, Cable A, Wilson BC, Vitkin IA, Yang VX. Speckle variance detection of microvasculature using swept-source optical coherence tomography. *Opt Lett*. 2008; 33(13):1530–1532. [PubMed: 18594688]
7. Mariampillai A, Leung MK, Jarvi M, Standish BA, Lee K, Wilson BC, Vitkin A, Yang VX. Optimized speckle variance OCT imaging of microvasculature. *Opt Lett*. 2010; 35(8):1257–1259. [PubMed: 20410985]
8. Kim DY, Fingler J, Werner JS, Schwartz DM, Fraser SE, Zawadzki RJ. In vivo volumetric imaging of human retinal circulation with phase-variance optical coherence tomography. *Biomed Opt Express*. 2011; 2(6):1504–1513. [PubMed: 21698014]
9. An L, Shen TT, Wang RK. Using ultrahigh sensitive optical microangiography to achieve comprehensive depth resolved microvasculature mapping for human retina. *J Biomed Opt*. 2011; 16(10):106013. [PubMed: 22029360]
10. Conroy L, DaCosta RS, Vitkin IA. Quantifying tissue microvasculature with speckle variance optical coherence tomography. *Opt Lett*. 2012; 37(15):3180–3182. [PubMed: 22859125]
11. Mahmud MS, Cadotte DW, Vuong B, Sun C, Luk TW, Mariampillai A, Yang VX. Review of speckle and phase variance optical coherence tomography to visualize microvascular networks. *J Biomed Opt*. 2013; 18(5):50901. [PubMed: 23616094]
12. Fixler D, Duadi H, Ankri R, Zalevsky Z. Determination of coherence length in biological tissues. *Lasers Surg Med*. 2011; 43(4):339–343. [PubMed: 21500229]
13. Weinhaus RS, Burke JM, Delori FC, Snodderly DM. Comparison of fluorescein angiography with microvascular anatomy of macaque retinas. *Exp Eye Res*. 1995; 61(1):1–16. [PubMed: 7556462]
14. Snodderly DM, Weinhaus RS, Choi JC. Neural-vascular relationships in central retina of macaque monkeys (*Macaca fascicularis*). *J Neurosci*. 1992; 12(4):1169–1193. [PubMed: 1556592]
15. Rahimy E, Freund KB, Larsen M, et al. Multilayered pigment epithelial detachment in neovascular age-related macular degeneration. *Retina*. 2014; 34(7):1289–1295. [PubMed: 24675391]
16. Spaide RF. Enhanced depth imaging optical coherence tomography of retinal pigment epithelial detachment in age-related macular degeneration. *Am J Ophthalmol*. 2009; 147(4):644–652. [PubMed: 19152869]
17. Spaide RF. Evidence of vascular abnormalization associated with periodic antiangiogenic treatments for choroidal neovascularization. *American Journal of Ophthalmology online*.
18. Ramrattan RS, van der Schaft TL, Mooy CM, de Bruijn WC, Mulder PG, de Jong PT. Morphometric analysis of Bruch's membrane, the choriocapillaris, and the choroid in aging. *Invest Ophthalmol Vis Sci*. 1994; 35(6):2857–2864. [PubMed: 8188481]
19. Spaide RF, Klancnik JM Jr, Cooney MJ. Retinal vascular layers imaged by fluorescein angiography and optical coherence tomography angiography. *JAMA Ophthalmol*. 2015; 133(1):45–50. [PubMed: 25317632]
20. Spaide RF, Klancnik JM Jr, Cooney MJ. Retinal vascular layers in macular telangiectasia type 2 imaged by optical coherence tomographic angiography. *JAMA Ophthalmol*. 2015; 133(1):66–73. [PubMed: 25317692]
21. Wolf S, Arend O, Toonen H, Bertram B, Jung F, Reim M. Retinal capillary blood flow measurement with a scanning laser ophthalmoscope. Preliminary results. *Ophthalmology*. 1991; 98(6):996–1000. [PubMed: 1866155]
22. Funatsu H, Sakata K, Harino S, Okuzawa Y, Noma H, Hori S. Tracing method in the assessment of retinal capillary blood flow velocity by fluorescein angiography with scanning laser ophthalmoscope. *Jpn J Ophthalmol*. 2006; 50(1):25–32. [PubMed: 16453184]
23. Sonkin PL, Kelly LW, Sinclair SH, Hatchell DL. Pentoxifylline increases retinal capillary blood flow velocity in patients with diabetes. *Arch Ophthalmol*. 1993; 111(12):1647–1652. [PubMed: 8155035]

**Summary Statement**

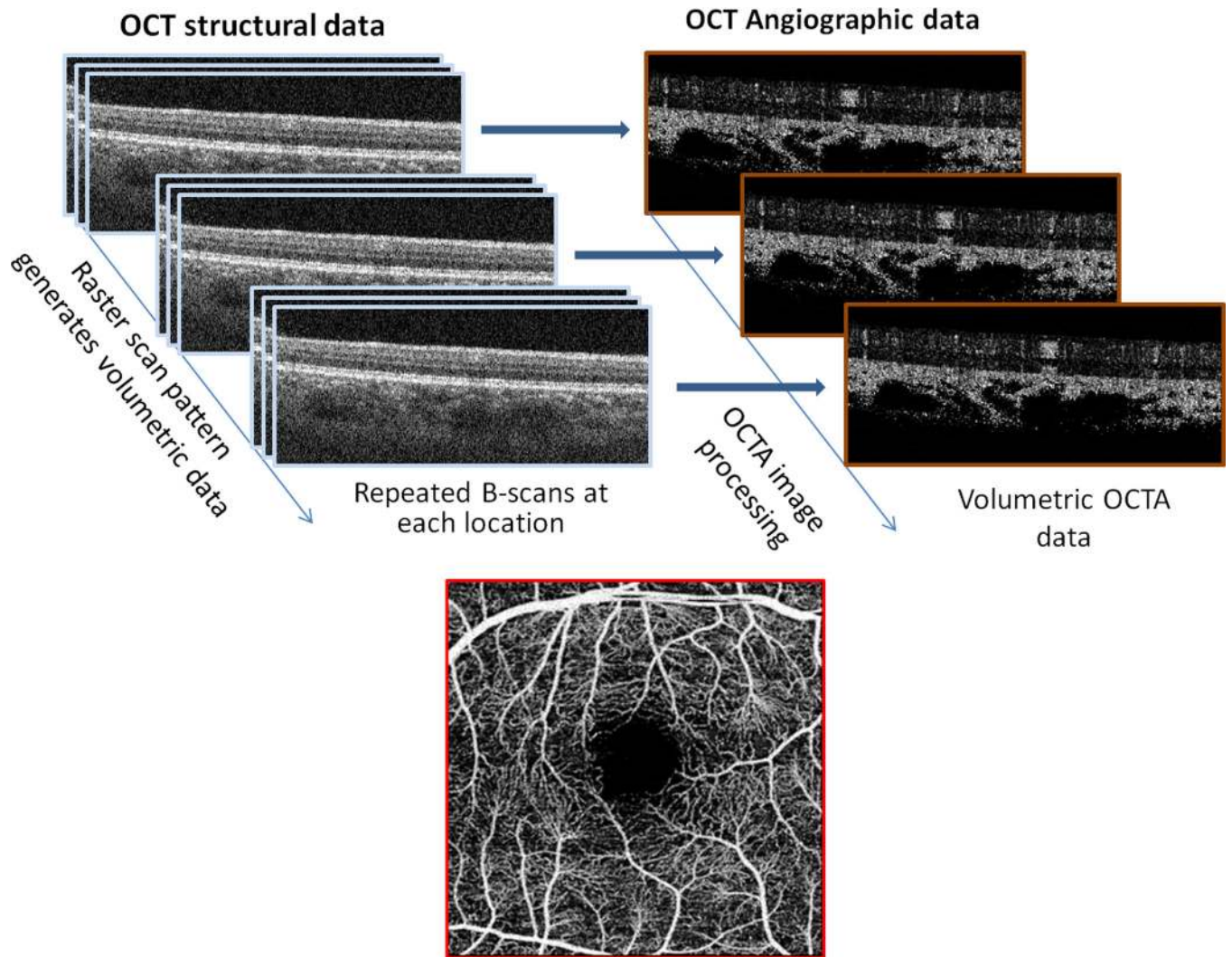
Optical coherence tomography angiography is a noninvasive technique that can provide images of retinal and choroidal vascularization. Artifacts are common and originate in relation to image acquisition, intrinsic ocular characteristics, eye motion, image processing and display strategies. Recognizing these artifacts is important in avoiding misinterpretation of diagnostic images.

Author Manuscript

Author Manuscript

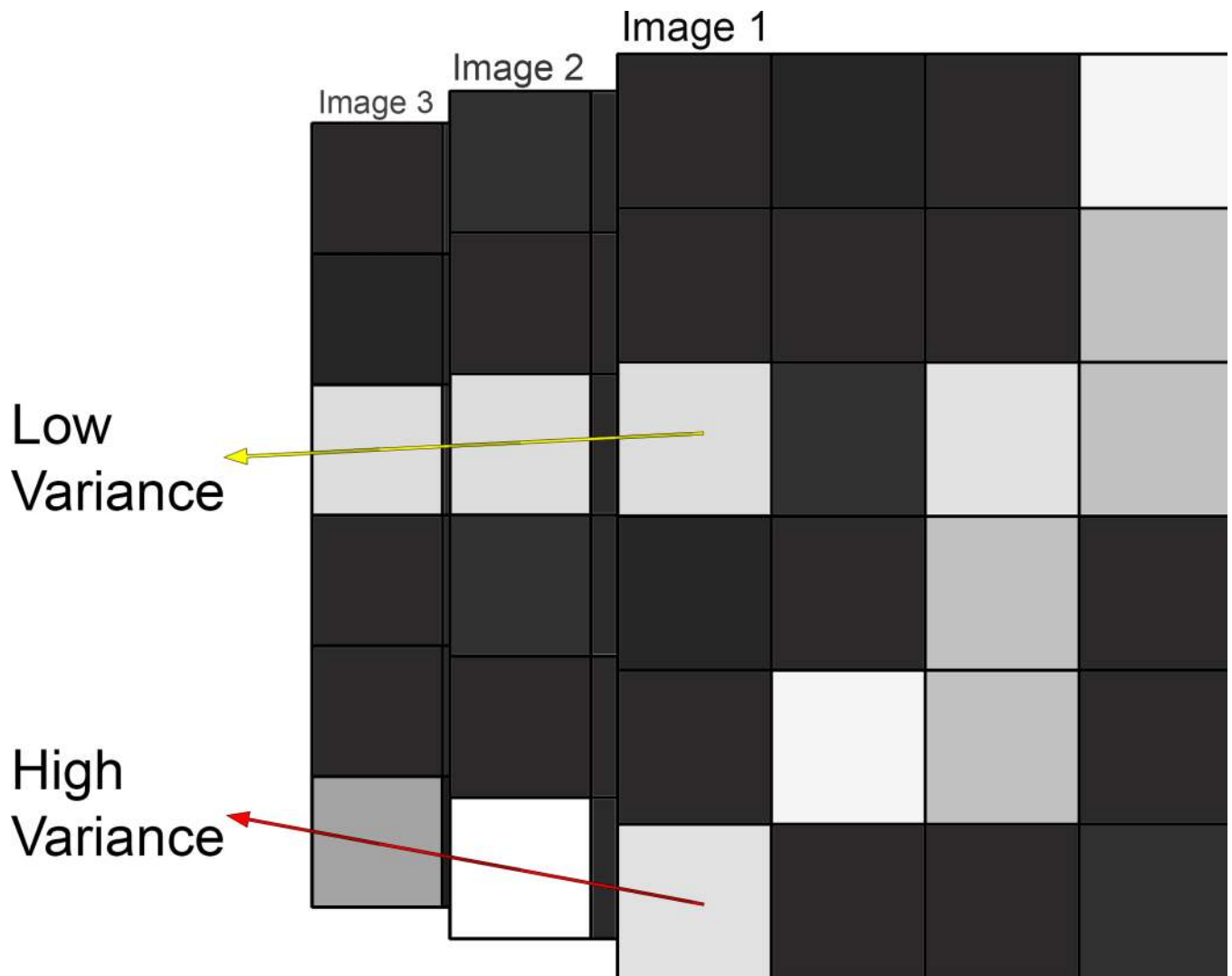
Author Manuscript

Author Manuscript



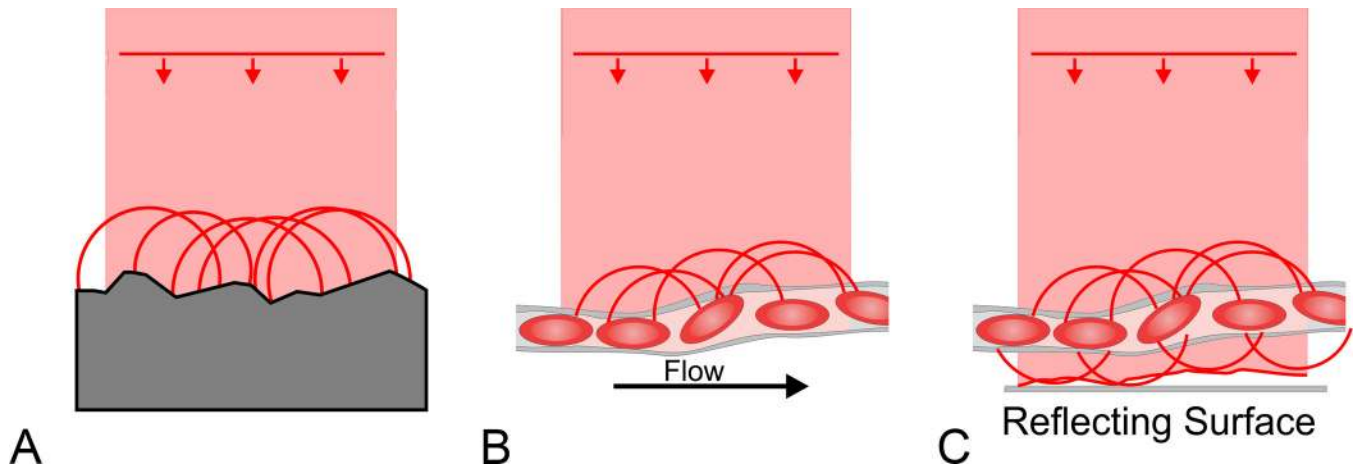
**Figure 1.** At each location in a volume scan multiple B-scans are obtained and compared. Regional variation in images is inferred to represent motion.





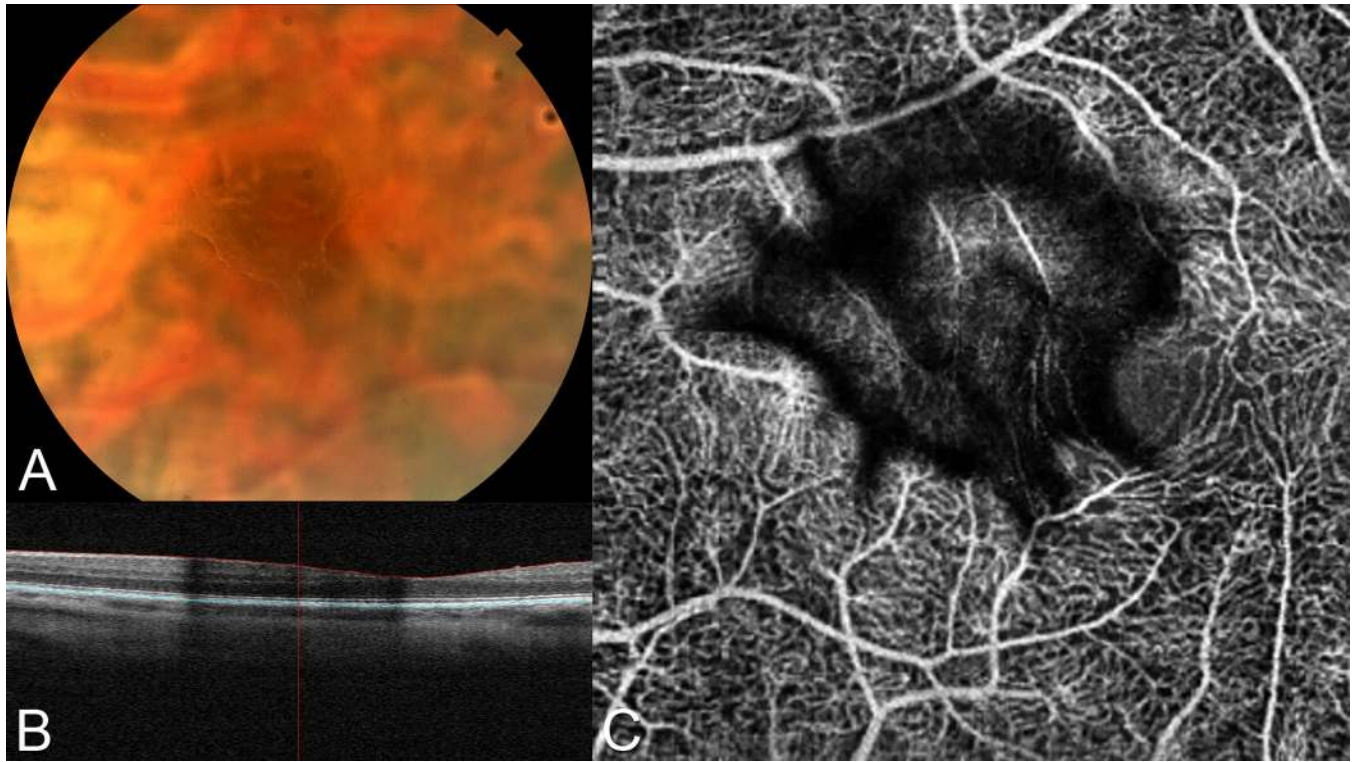
**Figure 2.** More than one image is compared in methods employing variance. Note the upper series of pixels (intersected by the yellow arrow); even though they are brighter than the background they do not vary among the images. The red arrow bisects pixels that in aggregate have the same mean value as the pixels bisected by the yellow arrow but show variability from one image to the next.



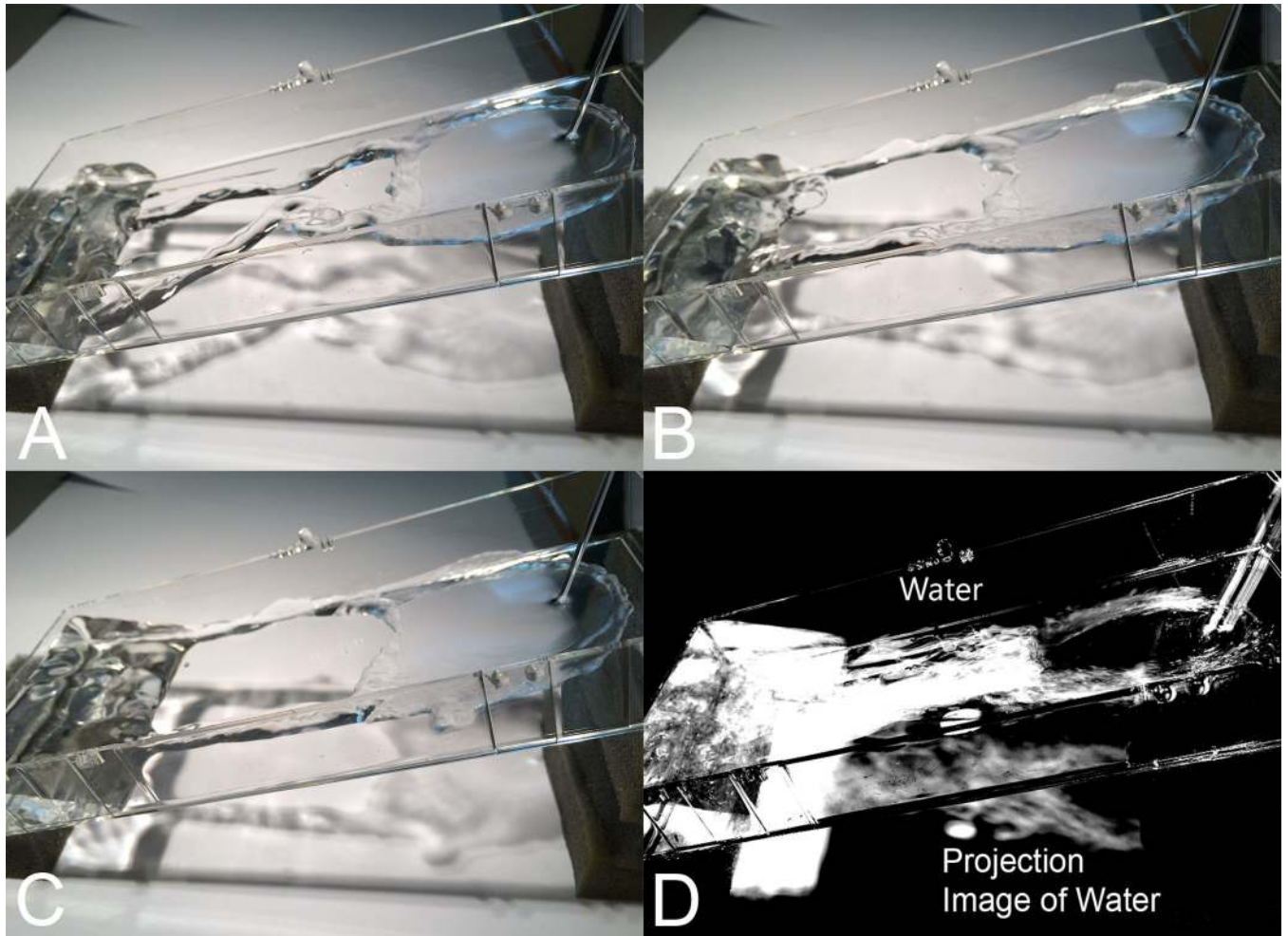


**Figure 3.**

A. The wavefront of incoming light is shown by the straight line and when reflected by the surface numerous secondary waves radiate outward in a spherical fashion. These waves may cause varying amounts of constructive and destructive interference with each other setting up the condition for speckle formation. Since the reflecting surface is stable, so are the speckles. B. In the case of moving blood cells the reflecting pattern changes through time as the cells change position. Thus the speckle pattern will change. C. Light striking the blood vessel will do more than just be reflected back to the instrument, the light will pass through the vessel, be refracted, absorbed, and scattered to varying degrees. The light passing through the vessel is free to strike deeper reflecting surfaces. The light reaching these surfaces varies over time because of the effects of the blood flow in the vessel. Therefore any reflecting surface will appear to change over time and will be rendered as having flow.

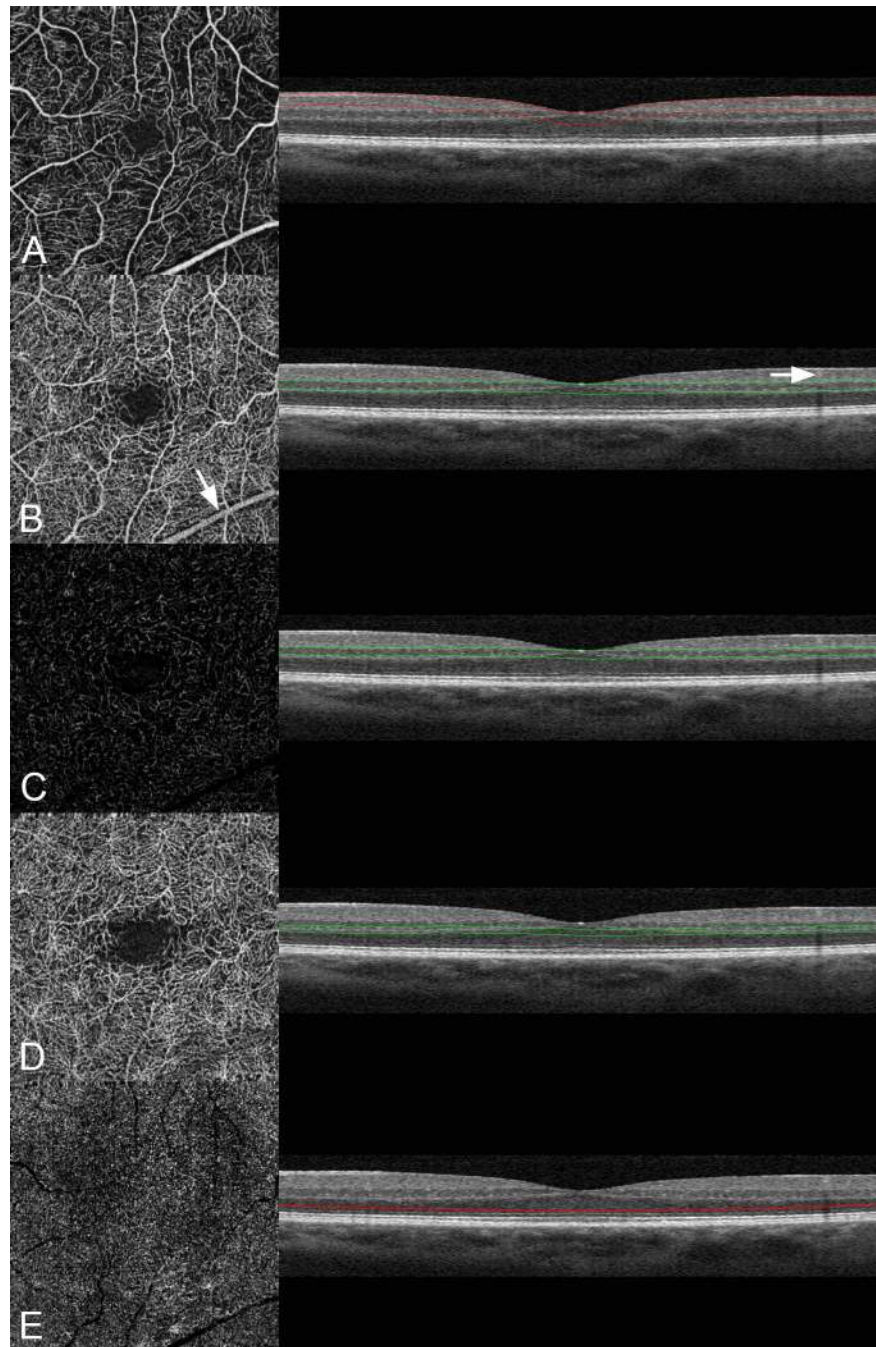


**Figure 4.** Media opacity causing artifact. A. A barely visible vitreous condensation had a peculiar shape. To improve visualization of the opacity adaptive histogram equalization was performed. B. There was shadowing of the B-scan OCT image evident. C. A defect in the angiographic image was seen that corresponded to the vitreous condensation. Note in the darkest portions of the artifact, no flow is evident from the retinal vessels because of the loss of signal caused by the vitreous opacity. By analogy loss of signal caused by the pigment in the retinal pigment epithelium decreases visualization of blood flow in the choroid.



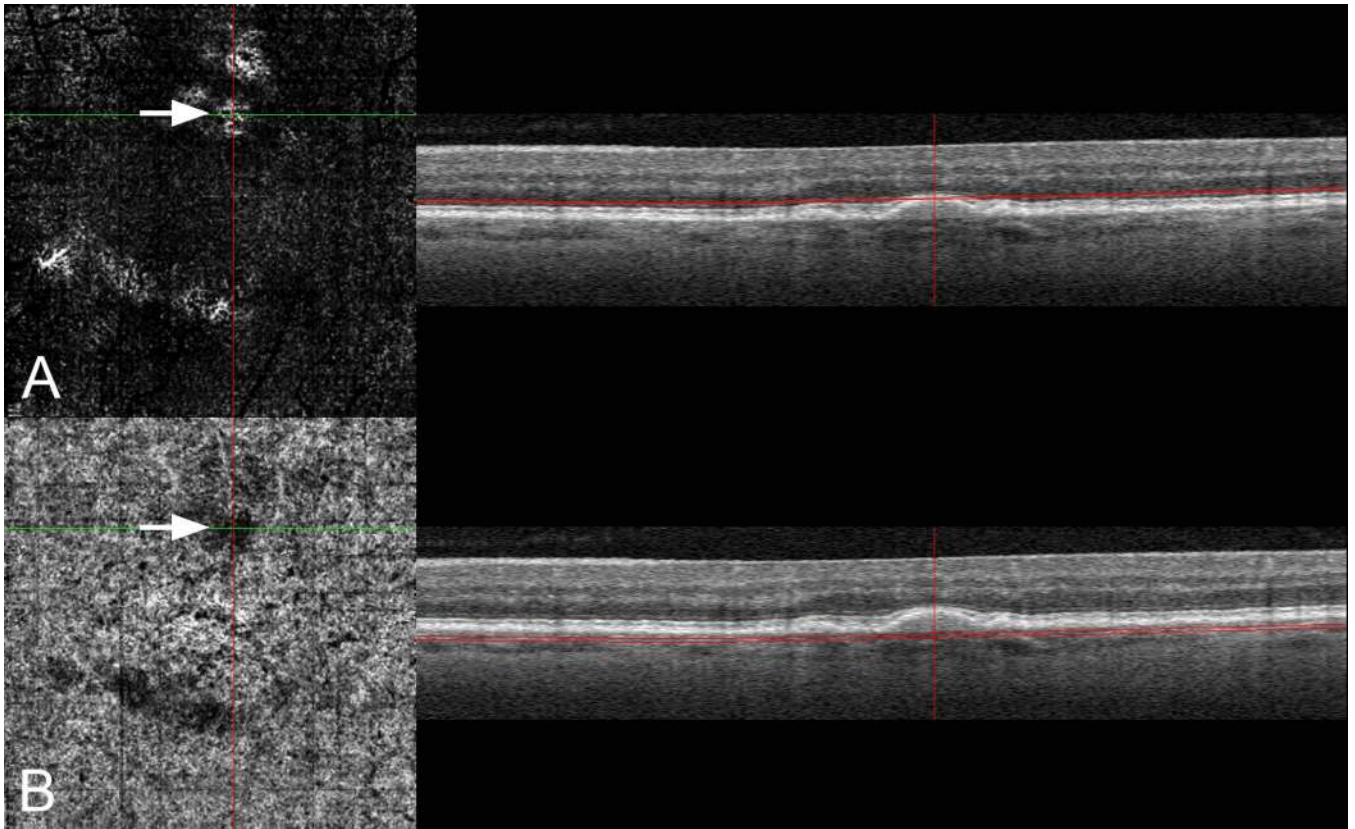
**Figure 5.** Origin of projection artifacts. A through C. Water is flowing in the clear channel and in successive images that in aggregate would be shown as a region of variable reflections. However the light going through the water strikes the background and this reflection changes over time. In D the variance image shows high variance in both locations even though flow occurred at only one region.



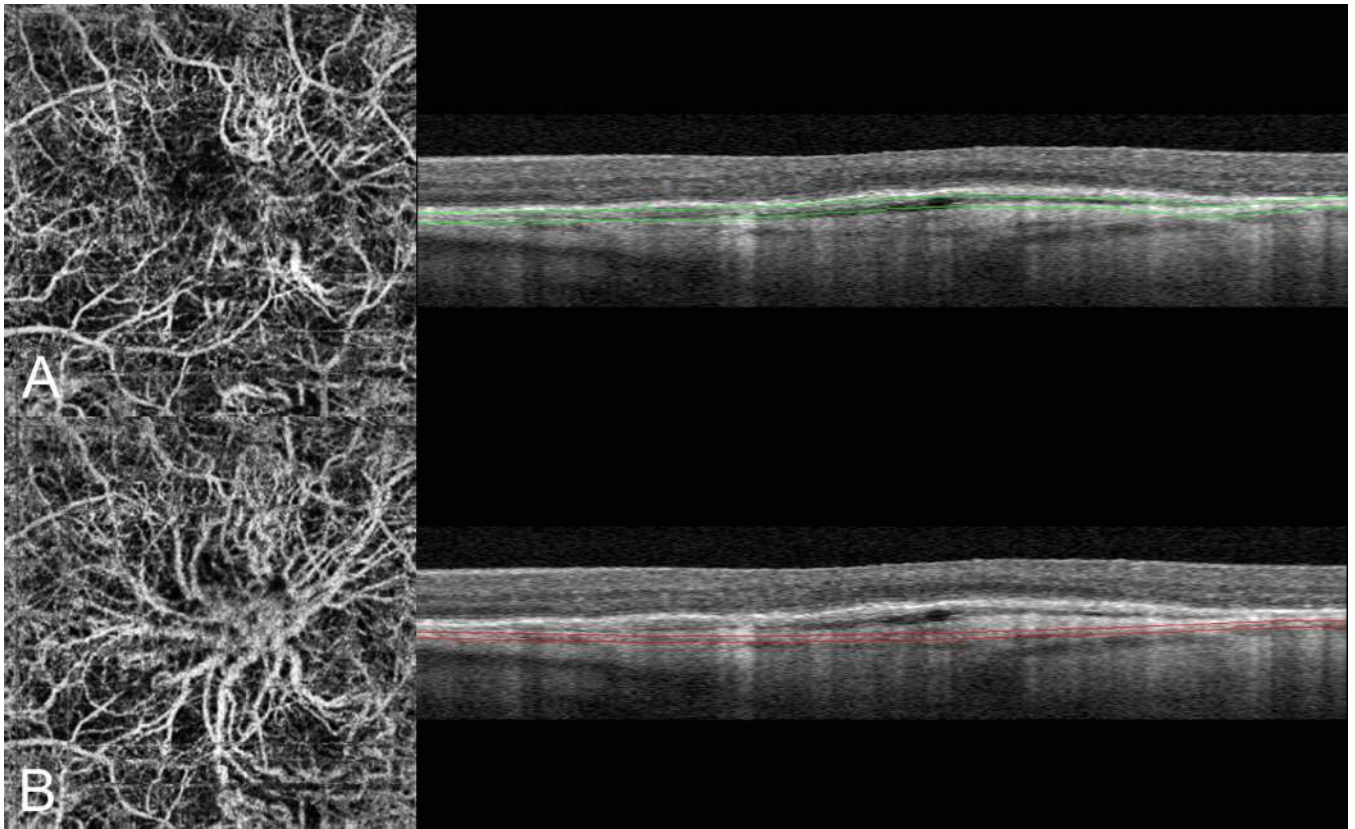


**Figure 6.** En-face layers and projection artifacts. Images A through E are different layers of the same eye. On the left is the angiographic image and on the right a B-scan image showing the level at which the angiographic image was obtained. In (A) the inner retinal circulation is shown. B. If the slab section is lowered to include the region around the inner nuclear layer the deep vascular plexus should be seen. However the vascular pattern looks quite similar to the inner plexus. Note the large retinal vessel seen in the angiographic image (arrow), but the section taken as shown in the B-scan image is clearly below the large vessel (arrow). Therefore the

inner retinal vessels are being shown because of a projection image. C. If the software option is selected to remove the projection image from the inner retina, no vessels are visible. D. If the slab section is taken slightly posteriorly the deep plexus is more clearly seen. Note the slab section is centered on the outer plexiform layer, implying much of what is seen in the angiographic image is really a projection image. E. If the slab section is placed in the outer nuclear layer a noise pattern is seen as there is no blood flow in this avascular layer.

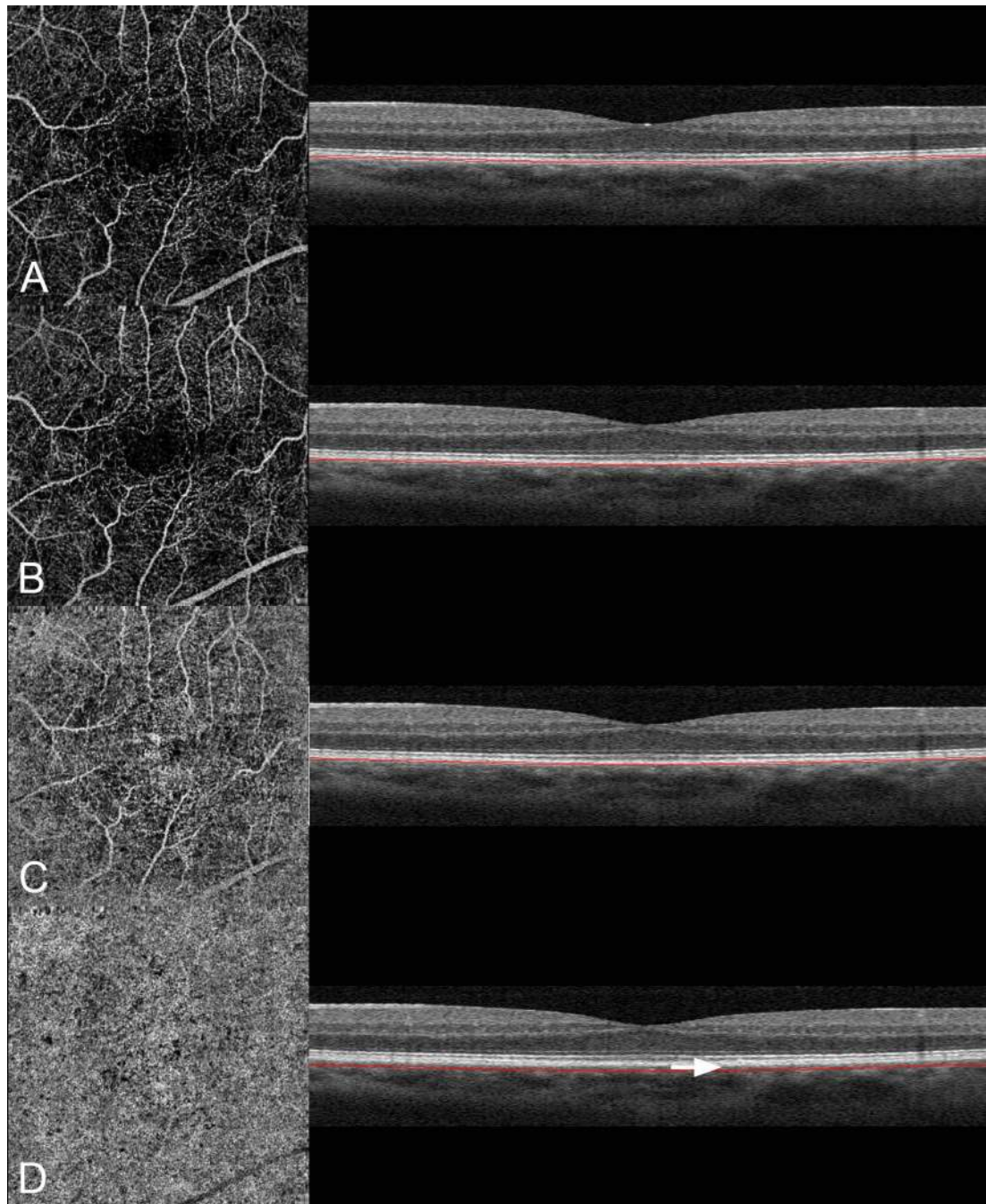


**Figure 7.**  
A. Projection artifacts from the retinal vessels to the tops of the drusen present in this patient with no choroidal neovascularization produces images that appear to have vessels. B. The same drusen attenuate the signal and cause shadowing defects in the underlying choriocapillaris, causing a false negative flow pattern (arrow).



**Figure 8.** Optimizing visualization of sub-RPE choroidal neovascularization by using the projection image. A. The OCT slab section was taken under the RPE, which is an area within a fibrovascular pigment epithelial detachment where vessels occur as shown in the structural OCT image on the right. The angiographic image on the left shows some of the choroidal neovascularization, but also shows prominent projection artifacts from the retinal circulation. Although the slab is shown by thin boundary lines the actual demarcation between the layers used to generate the angiographic image and what isn't used is a gradient and not a sharp demarcation. B. If the slab section is moved posteriorly to lie within a layer of reflective fibrotic tissue, the choroidal neovascularization under the RPE is visualized while the retinal projection artifact is not as evident.






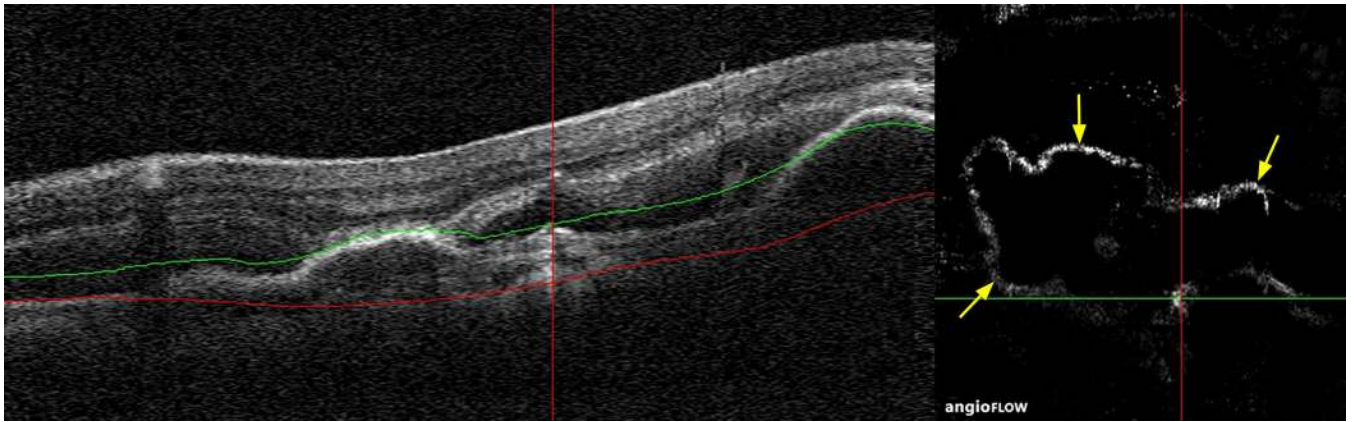
**Figure 9.**

Images A through D are different layers of the same eye illustrated in Figure 6. On the left is the angiographic image and on the right a B-scan image showing the level at which the angiographic image was obtained. A. When the slab section is brought back to the level of the retinal pigment epithelium, a clear visualization of the retinal vessels is obtained. B. The thickness and anatomic location of the slab section was brought back to the level where the choriocapillaris resides. Note the image is dominated by retinal vascular projection. C. The slab section in (B) is displaced 15 microns further back into the choroid. Note that the

angiographic image is getting brighter even though the corresponding area in the structural image is darker. The retinal vessels are less visible. D. The slab section is displaced an additional 20 microns into the choroid. The angiographic image shows a bright image suggestive of the choriocapillaris. Note the visible gap in the structural B-scan (arrow) separating the corresponding section and the expected anatomic location of the choriocapillaris.

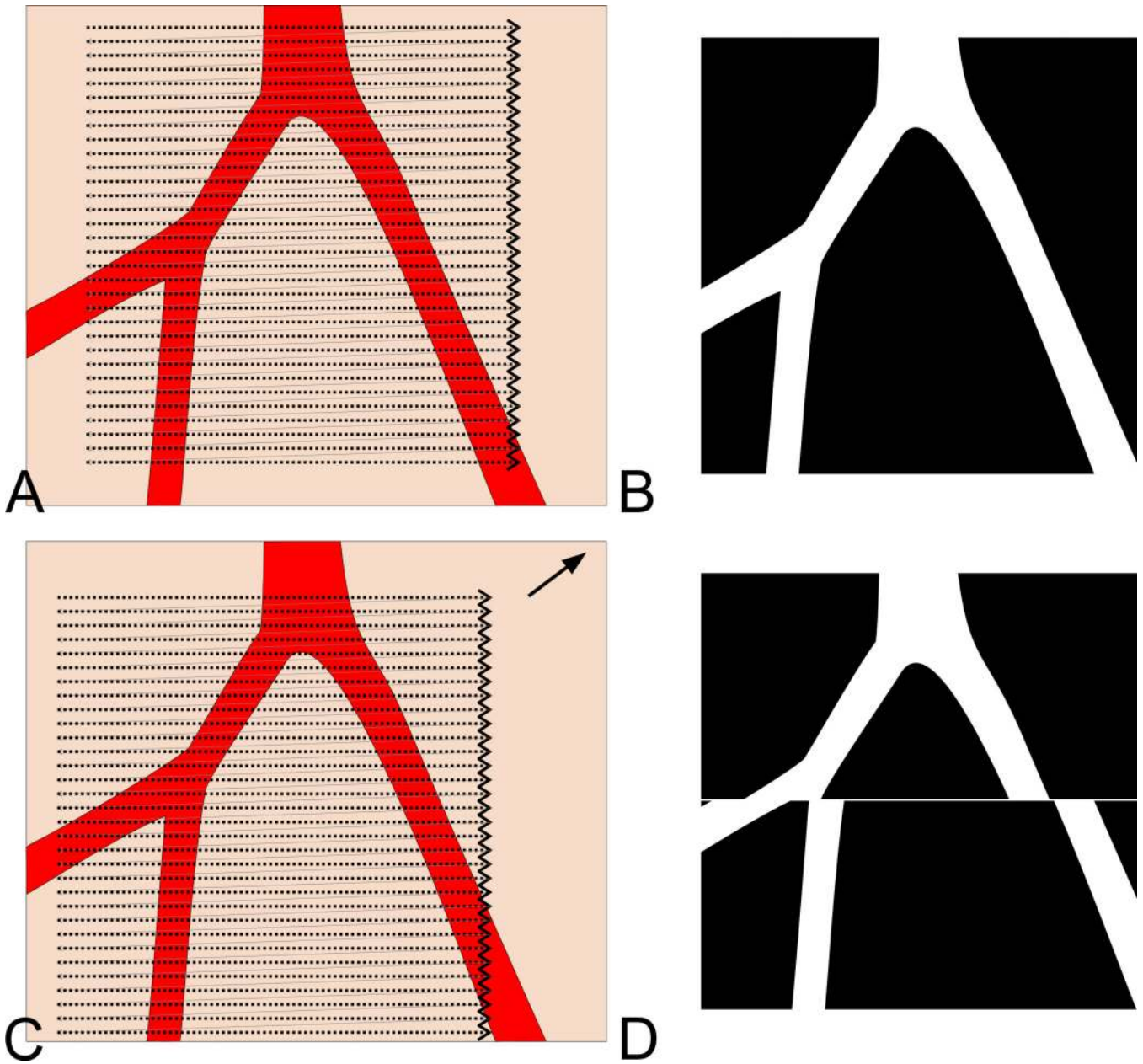


**Figure 10.**  
Volume scan with the change in axial position from one B-scan to the next uncorrected.  
Note the fine sinusoidal movement present in the axial direction.



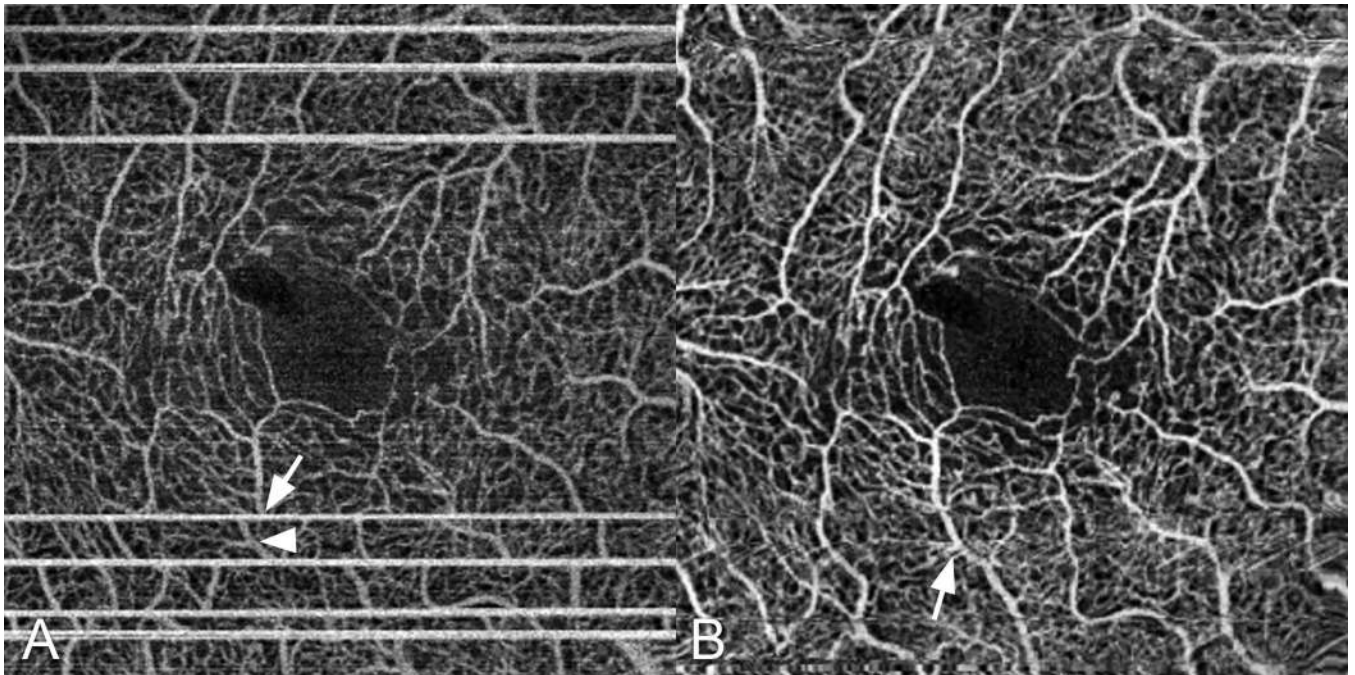
**Figure 11.**  
B scan (A) and corresponding OCTA (B) of a patient with pigment epithelial detachment.  
Note that the edges of the B scan generate a 'false positive' decorrelation signal on the  
OCTA image.





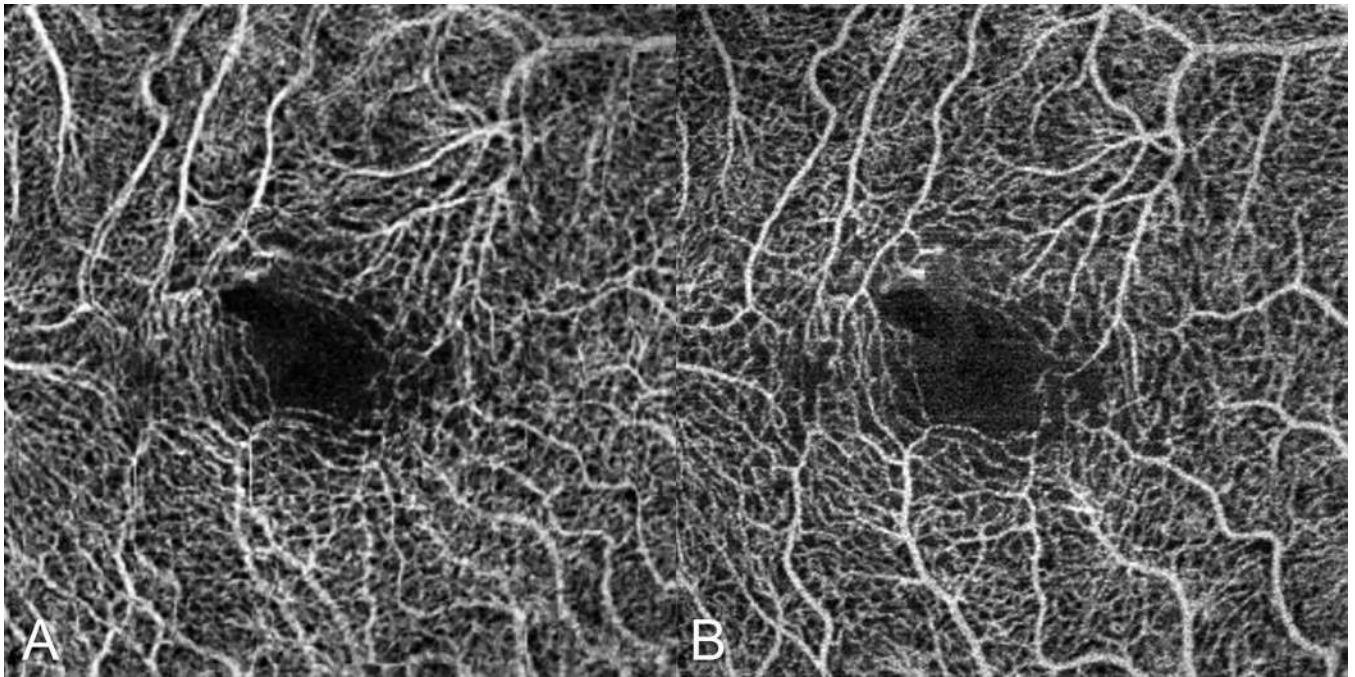
**Figure 12.**

Demonstration of motion artifact. A. The OCT instrument creates a raster pattern while scanning a selected region of the eye. The scan takes a finite amount of time, but if the patient doesn't move the image produced (B) has no motion artifact. C. If during the scan the eye moves in the direction of the black arrow the portion of the eye scanned prior to the movement will not match that of the portion of the eye after movement as shown in D. Note the white line at the junction of the two images, which is created because at that intersection of images there is a loss of correlation.



**Figure 13.**

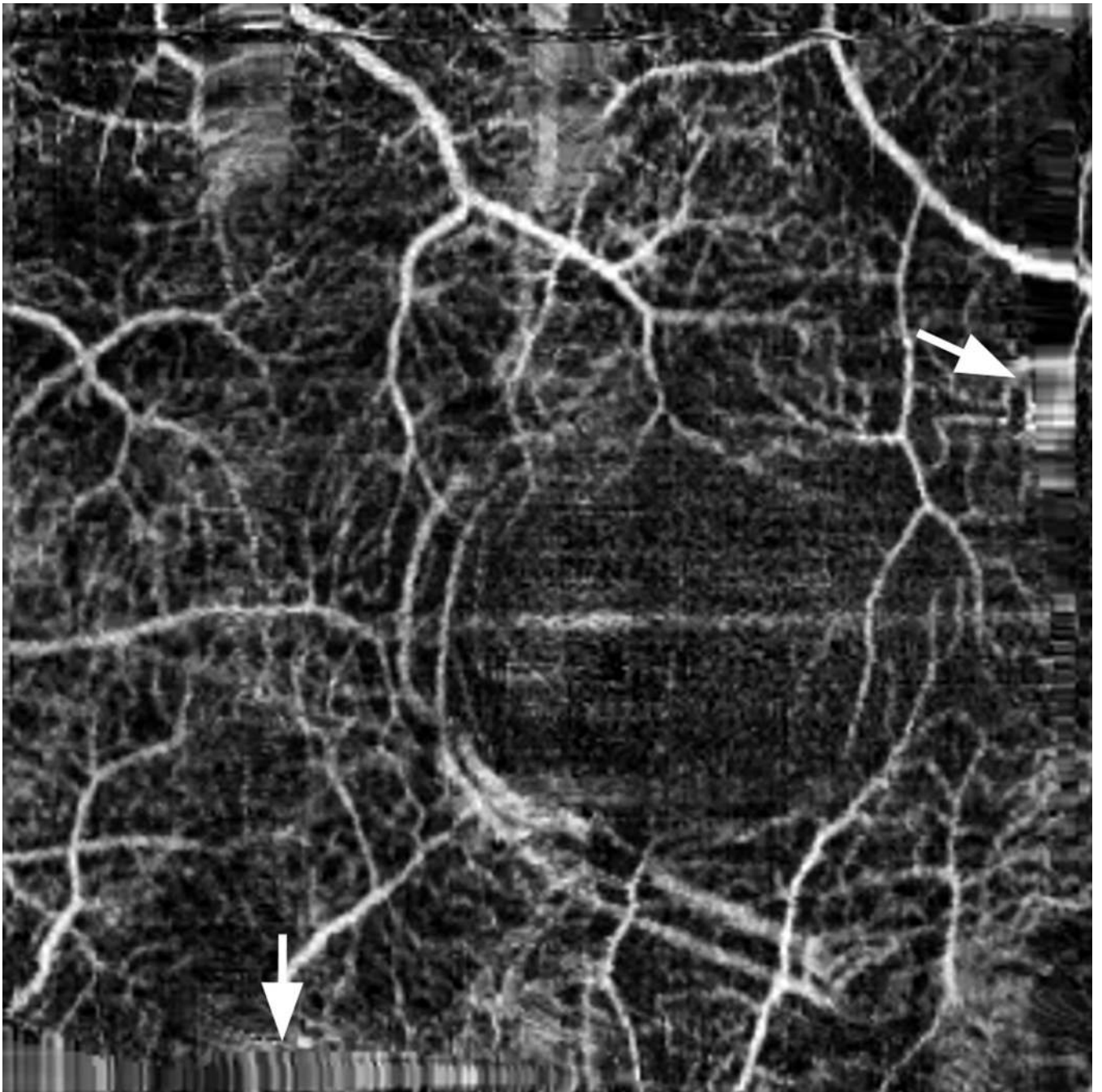
A. This patient has several white line defects, as highlighted by the arrow. Note a displacement artifact (arrowhead) in which there is a lateral displacement of part of the image. B. The effects of ocular motion on the OCTA were largely reduced by software techniques. Note the distortion and loss of detail at the branch point of the vessel (arrow).



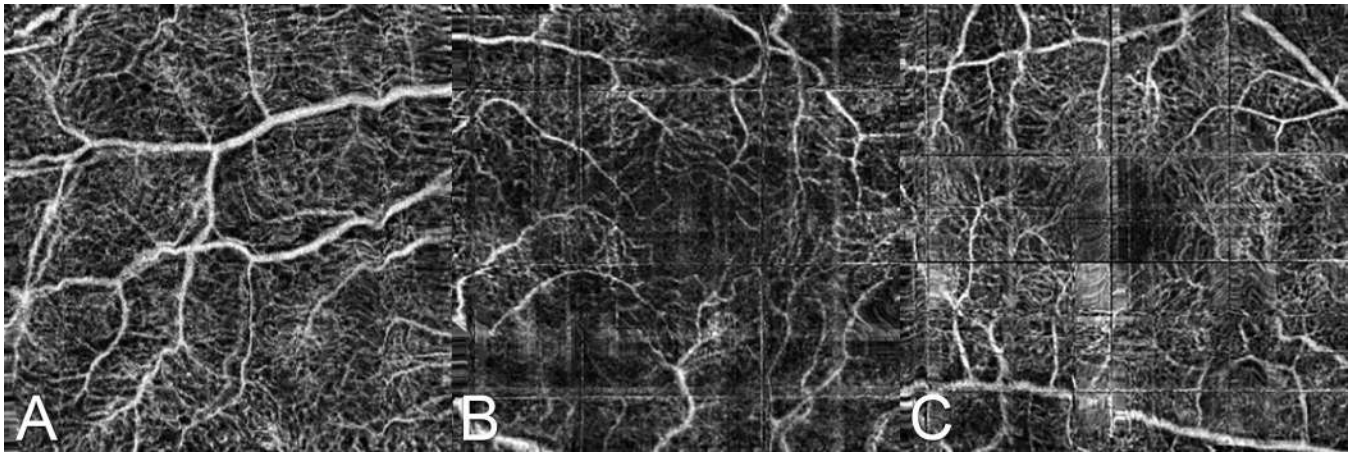
**Figure 14.**

An example of vessel doubling in (A) after software “correction” of ocular motion. B. One of the two component images used to create (A). The image in B alone shows no significant motion. There is slightly more noise as the averaging of two images to make (A) would be expected to increase the signal to noise ratio 3 dB.

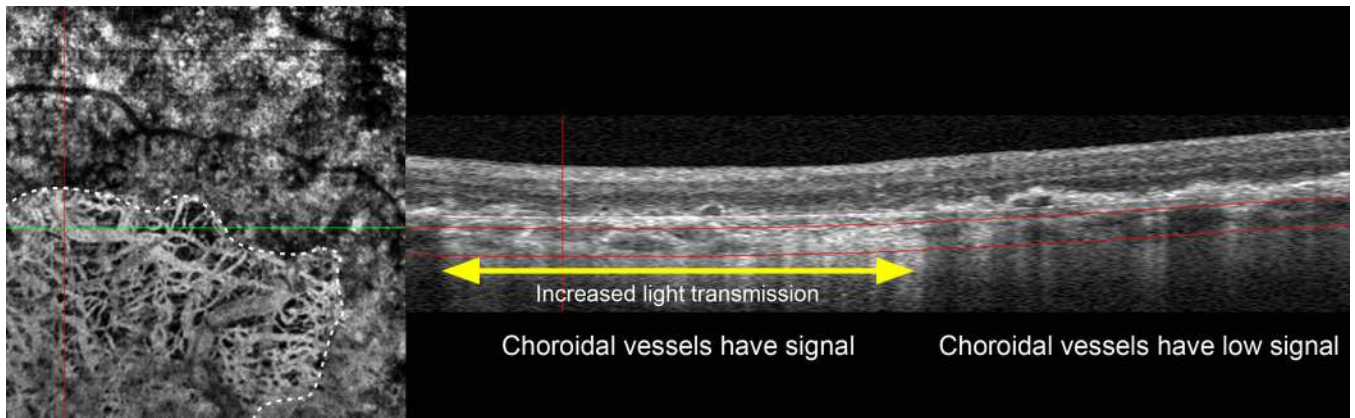




**Figure 15.**  
This image has several stretch artifacts, two of which are highlighted by the arrows.



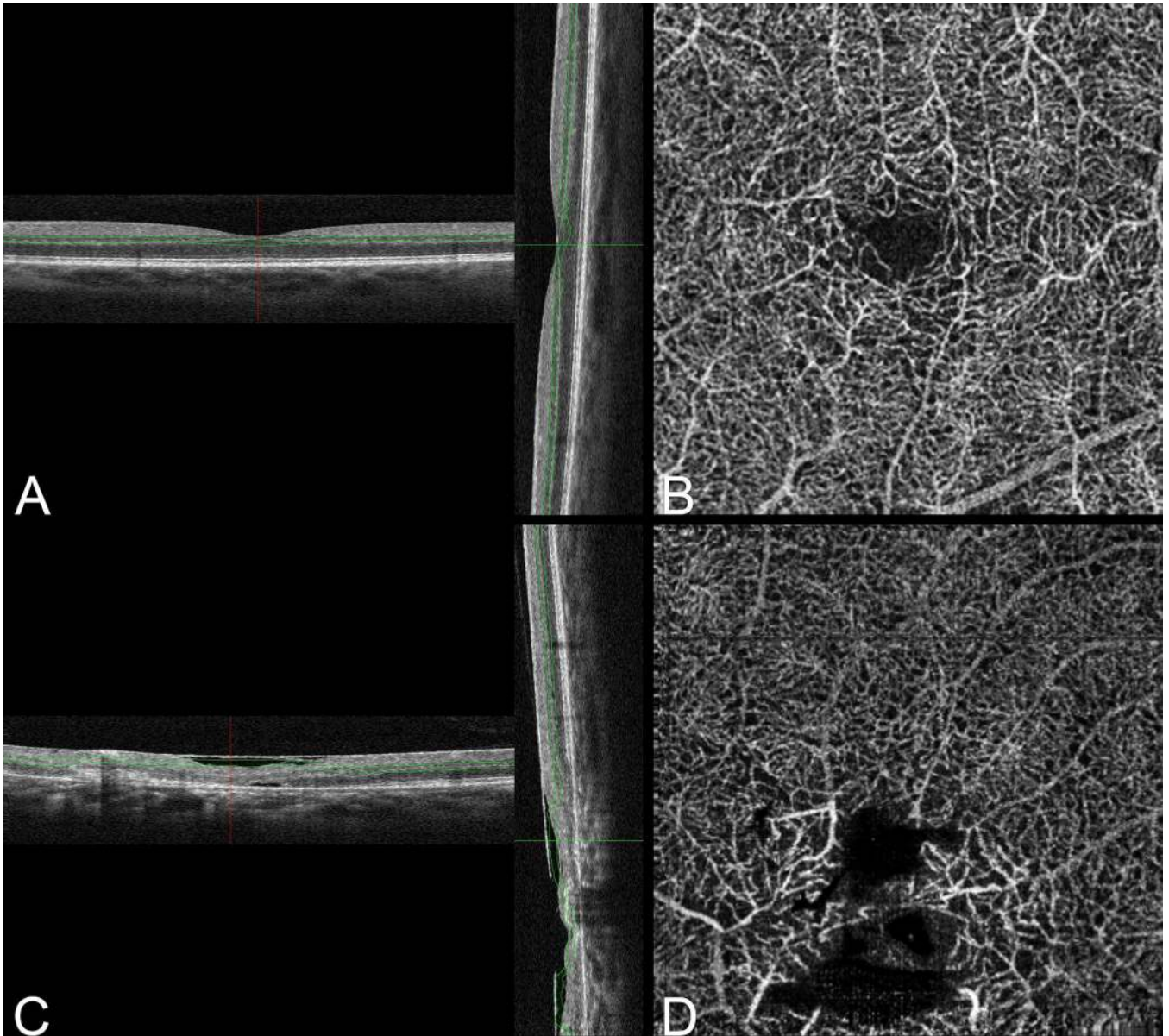
**Figure 16.** Examples of quilting defects ranging from A, a roiling distortion with some vessel doubling; B, larger rectilinear sections; to C, smaller rectangular segments some of which contain severe distortion.



**Figure 17.**

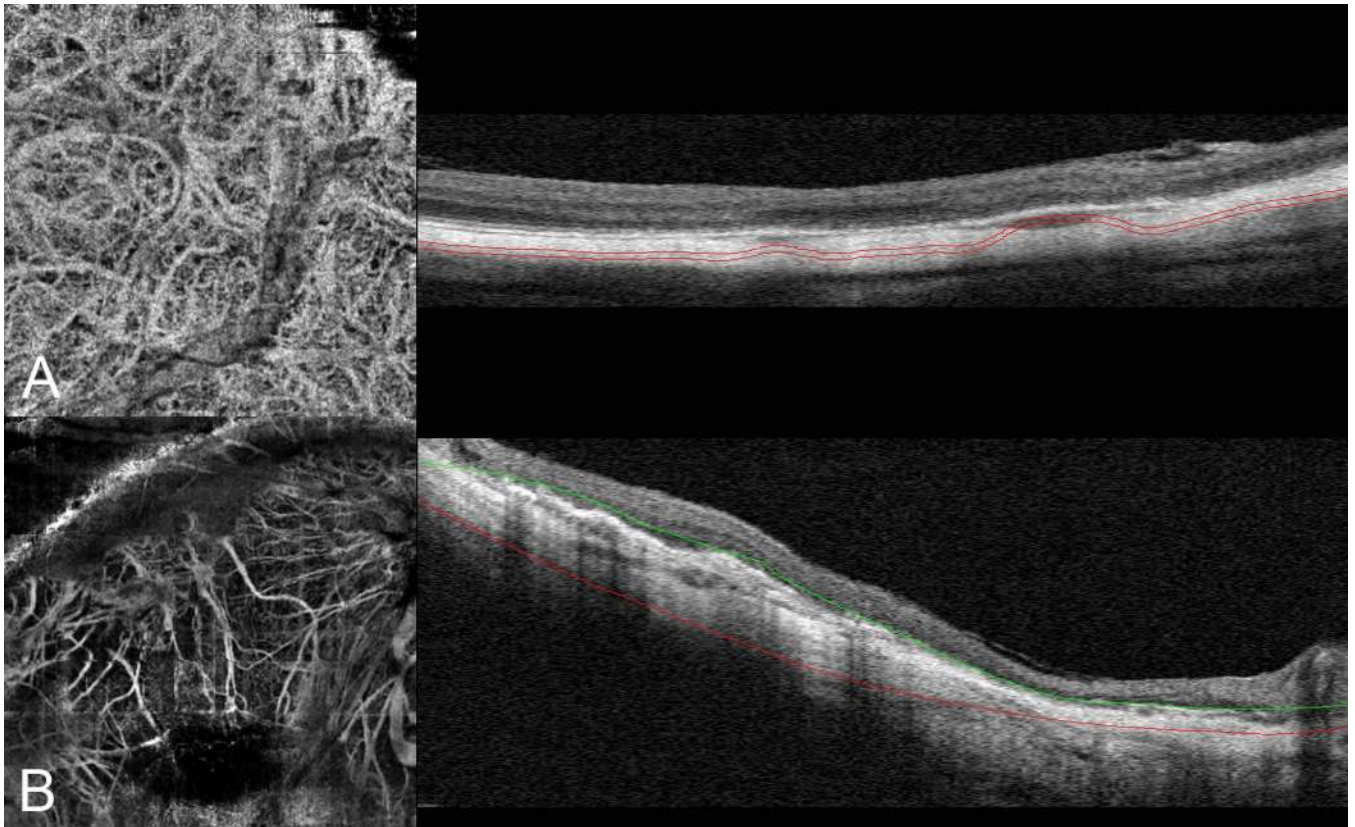
Visualization of choroidal vessels. Left, an area of atrophy of the RPE and underlying choroid is present in the bottom left of the image as demarcated by the white dashed line. Within this area the choroidal vessels are visible. Right, the B-scan image corresponding to the section at the green line of the OCTA image. The area of RPE atrophy is evident by the increased transmission of light to deeper layers (yellow double arrow). Note the reflectivity arising from within the larger choroidal vessels. In the area of intact RPE there is very little evident reflectivity from within the choroidal vessels.





**Figure 18.**

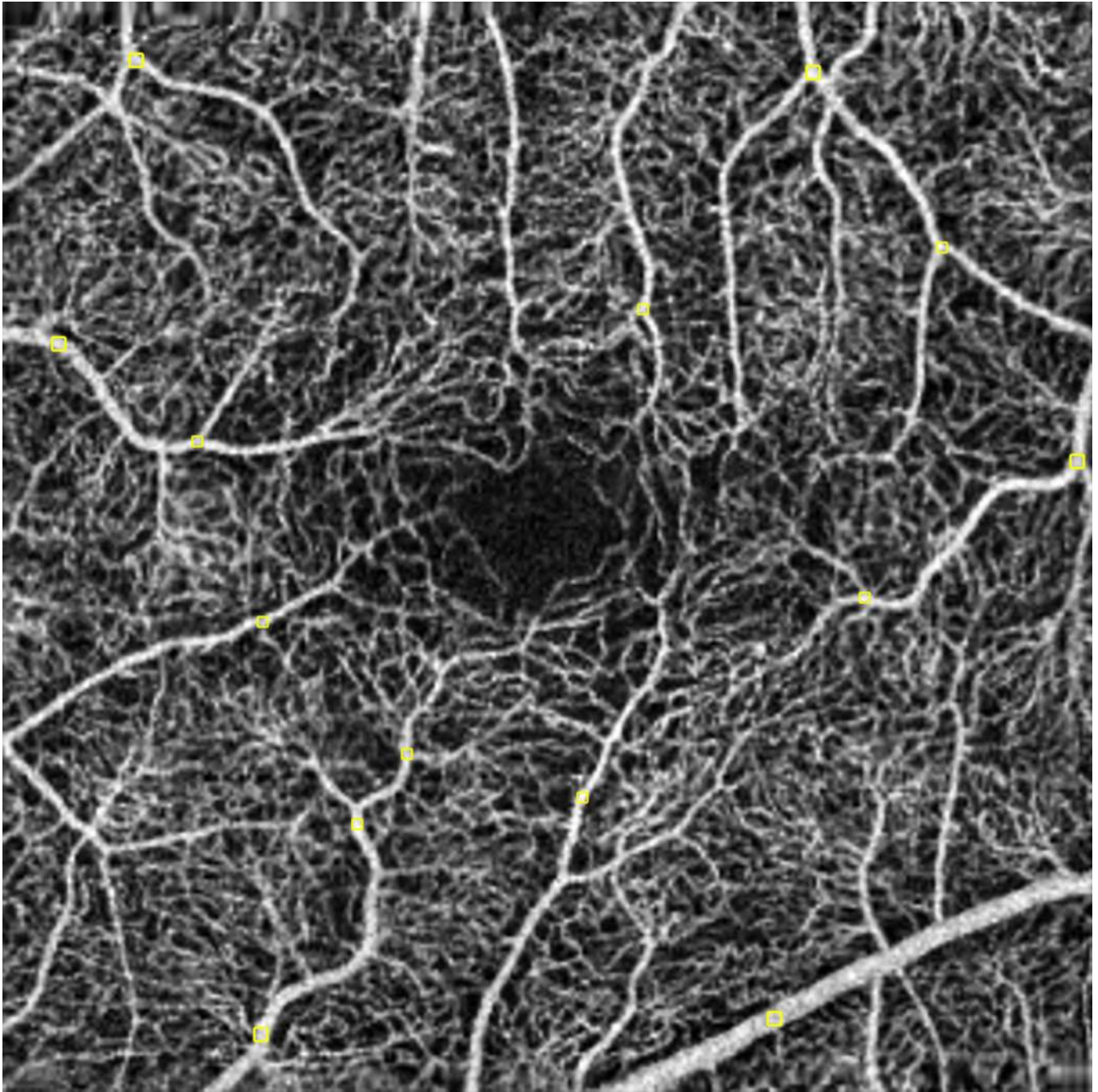
Segmentation defects. A. A normal retina is shown in a B-scan with a slab surrounding the inner nuclear layer, which typically would show the deep vascular plexus. The vertical image in A is the aggregate of B-scans section. Note the segmentation is accurate for the most part but the central macula shows some deviation of the slab as the inner nuclear layer doesn't exist in the central macula. B. The vessels imaged are the deep plexus. C. A patient with advanced macular telangiectasis Type 2. There is atrophy and collapse of the retinal layers. Note how the segmentation lines drift through various layers of the retina. D. The resultant vascular image is really vessels in more than one layer show as if they exist in a single layer. This is an inherent weakness of en-face segmentation and imaging.



**Figure 19.**

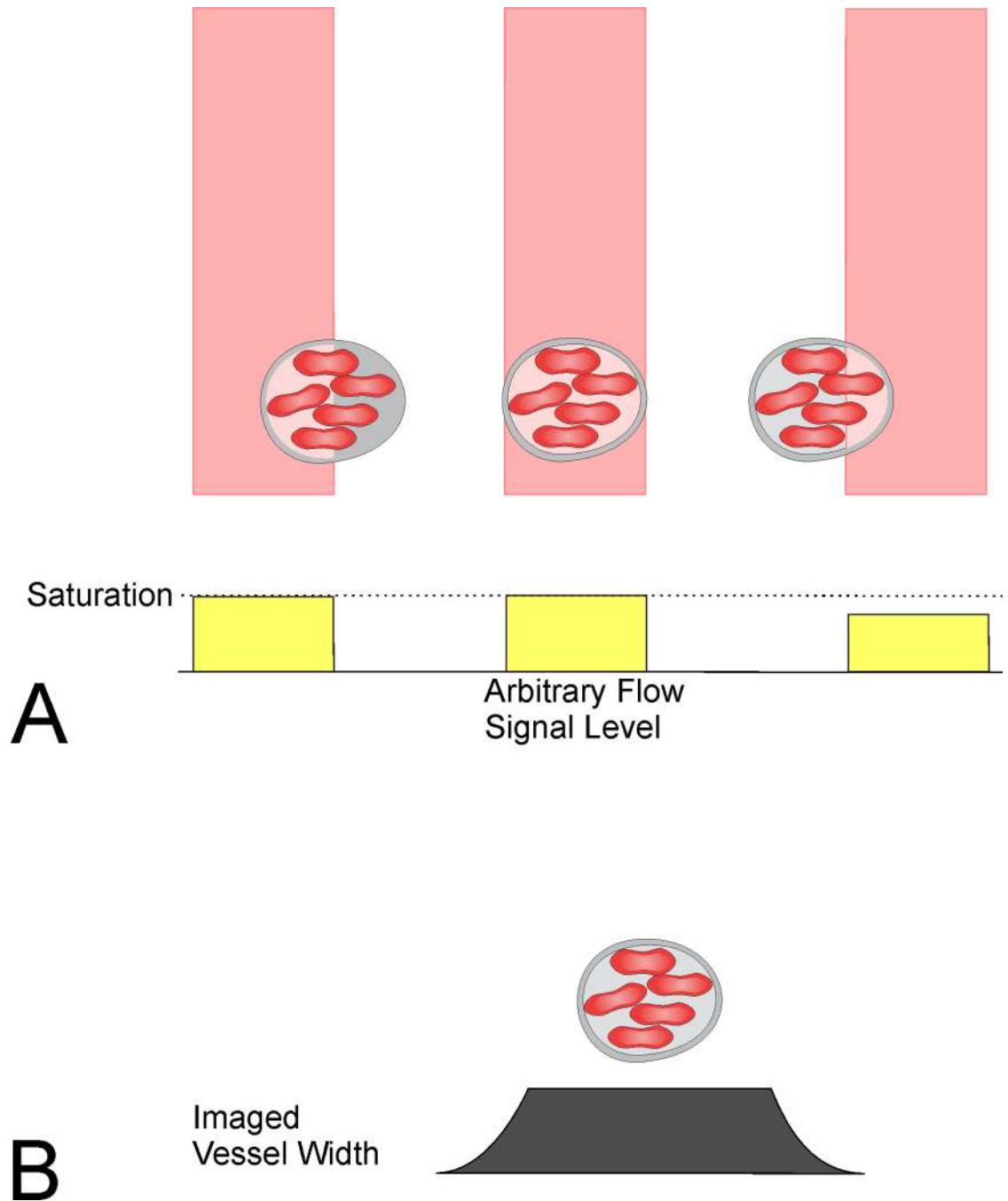
Segmentation errors in highly myopic eyes. A. The choroid was selected for segmentation but the algorithm placed the slab selected in an undulating level encompassing some large choroidal vessels and much of the sclera. The corresponding OCTA image on the left is largely a projection image with some formed by direct section of the large choroidal vessels. B. In another highly myopic eye the outer retina was selected for segmentation. The algorithm selected part of the outer retina, plus the choroid and variable amounts of sclera. The resultant angiographic representation is difficult to interpret.





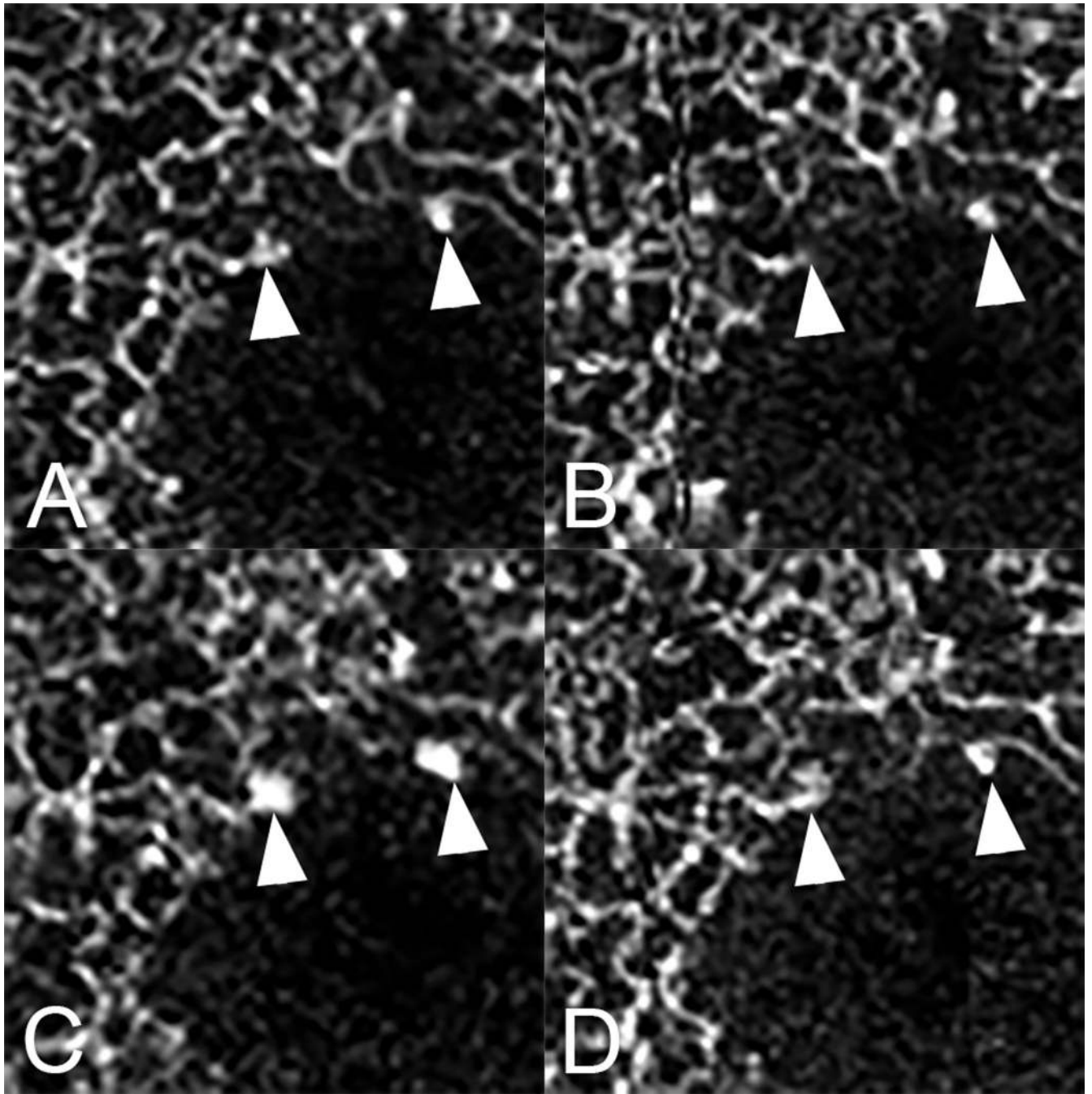
**Figure 20.**

An OCT angiogram of the inner plexus of retinal vessels. Retinal arteries are known to have faster flow than veins and bigger vessels have faster flow than smaller ones, however the regions of interest bounded by the yellow boxes have nearly identical grayscale values. This illustrates the property of saturation.



**Figure 21.** Widening of the apparent diameter of retinal vessels by motion contrast techniques. Flow signal can be detected even if the illumination beam is not centered on the vessel. The signal saturates at a low level of flow signal. The effect of these factors is the diameter of vessels is imaged to be larger than they really are. The effect proportionately is more important for smaller vessels than larger ones.





**Figure 22.** Repeated OCTA scans of a diabetic with microaneurysms (A–D). Note each image is somewhat different. The leftmost microaneurysm appears large in (A) but not visible in (B). Careful examination of the images shows small capillary segments that are visible in one image but not necessarily in all. Vessels are considered to have flow if the difference in the underlying OCT images differs by a set amount. If the differences related to flow do not reach this amount no flow is considered to be present.

Table

## Definitions

Term	Definition
A-scan rate	The maximal rate at which A-scans are acquired during a B-scan. There are various types of overhead such as the scan retrace to start the next B-scan so actual volume acquisition time can be longer than calculated from the A-scan rate alone.
Average (or mean) intensity projection	In a three dimensional volume of OCT signal or OCTA decorrelation values, the average value voxel along a line of sight is use to create the display value. This projection method shares some artifact problems with maximal intensity projection.
Decorrelation	The amount of change in a region from one sequentially repeated image to the next. Decorrelation is the converse of correlation.
Displacement artifact	Caused by eye motion during a raster scan where one part of the image is from one region of the eye, while the remaining portion of the image is from a discontinuous region. The en face image will appear to a discontinuity along the B-scan direction.
En face	Looking at the face [of the retina]. Volumetric data can be examined by summing the signal in the depth direction. The simplest en face OCT image sums the entire depth signal and resembles a fundus image. Sequential B-scan cross-sections of the volume data may be segmented and projected in depth to view en face images from specific retinal layers or depth level slabs.
False negative flow	OCTA signals with low decorrelation values suggesting no flow, where flow actually exists. The decorrelation can be too low over the time interval measured for flow to be considered present even if there is flow. Alternately signal attenuation due to media opacities or naturally occurring attenuation from structures such as pigment in the retinal pigment epithelium.
False positive flow	OCTA with decorrelation high enough to cause the appearance of flow in situations in which there is no or little flow. This can result from noise in the image or from eye motion.
Gap defect	A region of lost image information related to eye movement that may exist in the raw image data or in images with attempted software repair of eye motion.
Image artifact	Anomaly in the visual representation of information derived from an object. In a practical sense, image artifacts generally add unwanted information or subtract necessary information from the representation of the object.
Maximal intensity projection	In a three dimensional volume of OCT signal or OCT decorrelation values the highest value voxel along a line of sight is use to create the display value. This method was used in early computed tomography displays and is still used now for computed tomography and magnetic resonance imaging angiography. Injected contrast agents in these imaging modalities can be readily visualized with maximal intensity projection since the dye is radiographically denser than soft tissue. Image artifacts including displacement of the order of vessels and problems with overlapping vessels are a common consequence. It is used in OCTA because the vessels occur in a relatively flat plane.
Motion contrast	A visual output related to how much motion occurs in a given region of an image. Typically absent motion is given a low value and high amounts of motion a high value. These values are used to generate an image.
Multiplanar view	Typically 3 intersecting orthogonal views of a volume scan selected at levels of interest.
Orthogonal	At right angles
Phase	The position of a wave cycle that describes the difference between periodic repetitions present in the wave. This parameter is also used to describe the relationship between two waves with the same frequency. If we have a wave described by $y(t) = A\sin(2\pi ft)$ where A is amplitude f is frequency and t is time, then a second wave $y(t) = A\sin(2\pi ft + \phi)$ is said to have a phase difference of $\phi$ .
Projection artifact	One of the most important artifacts affecting OCTA. Light incident on a blood vessel may be reflected back toward the observer, as well as scattered elsewhere or refracted. Light which passes through the vessel will fluctuate over time and anything posterior to the vessel will be illuminated by this fluctuating light. Motion contrast techniques detect fluctuations with time, so artifactual images of vessels may be seen at deeper locations in the eye than they actual inhabit.
Quilting defect or checkerboard defect	A defect related to software correction of eye motion where multiple saccades in the vertical and horizontal direction are not corrected adequately leading to a rectilinear pattern of stretch artifacts, displacement artifacts, and distortion. Inaccurate motion correction is applied to a down sampled image and these errors are propagated through the increasing resolution iterations. The resultant image looks like a quilt or at times the undulating distortions seen in photographs by André Kertész.
Raster scan or raster pattern	Many A-scans are obtained along a scan line to form a B-scan and at the end of the scan line the scanning beam is swept back to start a new B-scan with a slight displacement away from the previous B-scan. The aggregate of this scan strategy forms a raster pattern and acquires volumetric information

Term	Definition
Saturation	The inability to distinguish different flows at the high end of the flow range. Physically different flows produce similar decorrelation values and cannot be differentiated in the display.
Segmentation	The process of dividing a larger set into two or more smaller sets according to a set of rules. In grayscale segmentation values can be thresholded, which is a form of segmentation. In analyzing B-scan images the retina can be segmented into layers.
Shadowing	Attenuation of signal behind an absorbing of scattering opacity or obstruction.
Speckle	A pattern of varying light intensity caused by mutual interference of wavefronts. Speckle is more evident with coherent or short coherence light.
Stretch artifact	A defect related to software correction of eye motion in which part of the image appears to have been stretched, much the same as if the image were printed on a rubber sheet, which is then stretched in a non-uniform way.
Thresholding	Replacing the pixel or voxel values above or below a certain value with another value to aid in image visualization or analysis. Thresholding is applied on OCT data to remove regions with low signal or noise prior to calculating OCTA decorrelation. Noise regions generate decorrelation and false positive flow artifacts. However, thresholding also means that OCTA cannot detect flow in low signal regions even if it is present (false negative). Thresholding is also applied to OCTA images prior to display. Low decorrelation values may be replaced with a zero value for display purposes. This replaces low values, which are likely to be noise with a value that would be rendered as black. Blood vessels with flows above the sensitivity threshold will stand out with greater contrast.
Vessel doubling	A defect related to software correction of eye motion in which two copies of each blood vessel appears in part or the entire image.
Volume rendering	In a three dimensional array of decorrelation all voxel values along a line of sight are used to create a representation that retains correct interrelationships of displayed vessels. Sometimes combined with surface rendering, a method that uses thresholding to help create meshes of closely related values that then can be rendered as surfaces according to a set of rules to produce a surface rendered image.
Volume scan	The 3D collection of voxels obtained by scanning a region of tissue with a raster scan.
Voxel	The combination of "volume" and "pixel". The term pixel itself is derived from "picture element" and defines the smallest 2D unit of an image that can be processed and displayed. A voxel is the 3D analog to a pixel and is the smallest unit in three dimensional space.
Wavefront	A collection of points having the same phase
White line artifact	A descriptive term for the white line seen in OCTA images associated with an eye movement. The sequential B-scans around the time of a microsaccade vary substantially and therefore generate large decorrelation values, which in turn are manifested as white lines in en face OCTA.