

Image Case : Hydatid Disease of the Liver

Ahmed Abdelrahim¹, A.Elzaki^{1,2}, H. Osman³

¹ Faculty of Radiology Science and Medical Imaging, Alzaiem Alazhari University, Khartoum North, Sudan.

² College of Applied Medical Science, Taif University, Taif, KSA

³ College of Medical Radiologic Science, Sudan University of Science and Technology, Khartoum, Sudan

Corresponding Author:
A. Elzaki

Mobile:
+966533821879

E mail:
Aminzaki2000@yahoo.
com

Key words: Liver,
Hydatid Cyst,
Ultrasonography,
Echinococcosis

Hydatid Disease which is also referred to Echinococcosis or echinococcal disease, is a parasitic disease that affects both humans and other mammals, such as sheep, dogs, rodents and horses [1].

Hydatid disease remains a clinical problem worldwide, especially in areas where animal husbandry and subsistence farming form an integral part of community life [2]. The liver is the most commonly involved organ (52-77%) [3], but hydatid disease may affect any part of the body either as a primary or secondary event [2].

There are four forms of hydatid disease. *Echinococcus granulosus* (EG) is the most common and gives rise to cystic hydatid disease (CHD). *Echinococcus multilocularis* is uncommon and causes alveolar hydatid disease (AHD), which is far more aggressive and frequently mimics malignancy [4]. The rarest clinical form is *Echinococcus vogeli* or polycystic hydatid disease (PHD), with characteristics between CHD and AHD [5]. *Echinococcus shiquicus*, has been identified on the Tibetan plateau but to date no human infection has been described. CHD is a zoonosis infecting a variety of domestic and wild animals. There is no host specificity for the larval stage of EG, but the commonest intermediate hosts are sheep, cattle, buffalo, camels and pigs [6].

The developing hydatid cyst has three layers. The outer pericyst is composed of host fibroblasts, eosinophils, giant cells and modified hepatocytes. The middle laminated membrane is a cellular and impermeable to bacteria, and the innermost layer, the germinal layer or brood capsule, is translucent

and is the origin of scolices and daughter cysts within the primary cyst [4]. The cyst usually contains crystal-clear fluid which is strongly antigenic and may cause anaphylaxis if released into the circulation of the host. Most cysts remain silent when small and present only when complications such as rupture into the biliary tree, bacterial superinfection or free intra-abdominal rupture occur. Owing to the lack of symptoms in the early stages, the actual accurate assessment of the growth rate of these cysts is difficult [2].

Several classifications of CHD exist. All were developed in endemic areas, and are important because they enable the most appropriate treatment option to be selected. The classifications are not comparable, however, which makes comparative analysis difficult. The two most widely used classifications are the morphological classifications proposed by Gharbi et al [7]. in 1981 (Table I) and Lewall and McCorkell[8] in 1985, which are based on pathology and natural history.

In 1997, the WHO Informal Working Group classification on Echinococcosis (WHO-IWGE) proposed a new standardized classification based on ultrasound images [8]. This classification is intended to follow the natural history of CHD and is divided into three groups. The first group are active, fertile cysts containing viable scolices, the second group are in a transitional stage owing to compromise either by host defense or chemotherapy, and the third group are inactive, having lost their fertility, and are degenerative [2].

Imaging modalities range from simple to complex and invasive. Plain radiographs of the abdomen and chest may reveal a thin rim of calcification delineating a cyst, or an elevated hemidiaphragm. Both signs are nonspecific. Ultrasound is readily available and cost effective. A cyst containing daughter cysts and hydatid sand (debris) are highly suggestive. Several studies have documented the excellent sensitivity (100%) of ultrasound. [9,10] A computed tomography (CT) scan of the abdomen gives better information concerning location, accessibility and possible complications. It is also helpful in identifying exogenous cysts, and the volume of the cyst can be estimated. CT is an important investigation when there is diagnostic uncertainty on ultrasound, when planning surgical intervention or when recurrent disease is diagnosed. Magnetic

resonance imaging (MRI) adds little to CT scanning and is not cost effective. Endoscopic retrograde cholangiopancreatography (ERCP) remains an important tool in cases where rupture into the biliary tree has occurred, allowing both the diagnosis of major biliary communication and clearance of the common bile duct (CBD) prior to surgery or intervention [9,10]

We reported a 40 years old male with a chronic RUQ pain, an enlarged liver and a palpable mass. The patient was referred to the x-ray department for a longitudinal abdominal ultrasound. A cystic mass with floating membrane and posterior enhancement was reported indicating a Liver hydatid cyst. The Hydatid cyst was in the range of Gharbi's type II (Image 1).

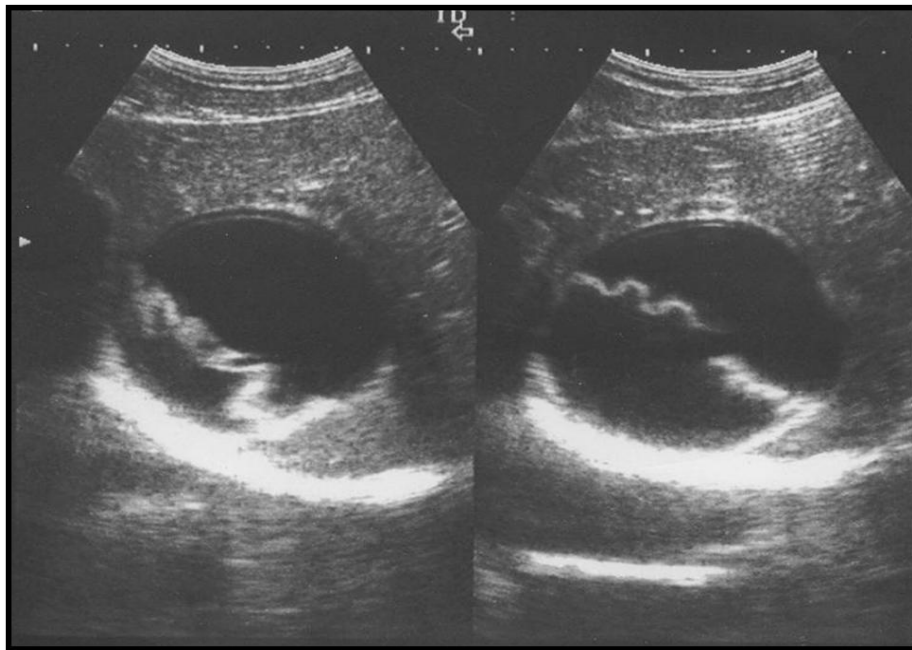


Image (1) : Gharbi type II: Fluid collection with a detached membrane

Table (1) : Gharbi classification of hydatid cysts

Type	Description
I	Pure fluid collection
II	Fluid collection with a detached membrane
III	Fluid collection with multiple septa and/or daughter cysts
IV	Hyperechoic with high internal echoes
V	Cyst with reflecting calcified thick wall

REFERENCES:

1. Berger SA, Marr JS. Human Parasitic Diseases Sourcebook. Jones and Bartlett Publishers: Sudbury, Massachusetts, 2006
2. SAJS, Vol 44 (2), 2006, 70-77
3. Sayek I, Onat D. Diagnosis and treatment of uncomplicated hydatid cyst of the liver. *World J Surg* 2001; 25: 21-27
4. Polat P, Kantarci M, Alper F, Suma S, Koruyucu M, Okur A. Hydatid disease from head to toe. *Radiographics* 2003; 23: 475-494.
5. Filice C, Brunetti E, d'Andrea F. Minimal invasive treatment for hydatid abdominal cysts: PAIR (Puncture, Aspiration, Injection, Reaspiration) – state of the art. WHO/CTD/SIP 97.3
6. Bouree P. Hydatidosis: dynamics of transmission. *World J Surg* 2001; 25: 4-9.
7. Gharbi HA, Hassine W, Brauner MW, Dupuch K. Ultrasound examination of the hydatid liver. *Radiology* 1981; 139: 459-463.
8. Lewall DB, McCorkell SJ. Hepatic echinococcal cysts: sonographic appearance and classification. *Radiology* 1985; 155: 773-775.
9. Vagionos CE, Karavias DD, Kakkos SK, Vagenas CA, Androulakis JA. Conservative treatment in the treatment of hepatic hydatidosis. *Eur J Surg* 1995; 161: 415-420.
10. Safioleas M, Misiakos E, Manti C, Katsikas D, Skalkeas G. Diagnostic evaluation and surgical management of hydatid disease of the liver. *World J Surg* 1994; 18: 859-865.