

# Circulation

JOURNAL OF THE AMERICAN HEART ASSOCIATION



## **Aberrant Right Subclavian Artery Mimics Aortic Dissection**

Maarten Janssen, Christian S. Breburda, Robert Jan M. van Geuns, Walter R. M. Hermans, Peter Klootwijk, Jos A. Bekkers and Jos R. T. C. Roelandt

*Circulation* 2000;101;459-460

Circulation is published by the American Heart Association, 7272 Greenville Avenue, Dallas, TX 75214

Copyright © 2000 American Heart Association. All rights reserved. Print ISSN: 0009-7322. Online ISSN: 1524-4539

The online version of this article, along with updated information and services, is located on the World Wide Web at:

<http://circ.ahajournals.org/cgi/content/full/101/4/459>

Subscriptions: Information about subscribing to *Circulation* is online at  
<http://circ.ahajournals.org/subscriptions/>

Permissions: Permissions & Rights Desk, Lippincott Williams & Wilkins, 351 West Camden Street, Baltimore, MD 21202-2436. Phone 410-5280-4050. Fax: 410-528-8550. Email:  
[journalpermissions@lww.com](mailto:journalpermissions@lww.com)

Reprints: Information about reprints can be found online at  
<http://www.lww.com/static/html/reprints.html>

## Aberrant Right Subclavian Artery Mimics Aortic Dissection

Maarten Janssen, MD, PhD; Christian S. Breburda, MD, PhD; Robert Jan M. van Geuns, MD;  
Walter R.M. Hermans, MD, PhD; Peter Klootwijk, MD, PhD;  
Jos A. Bekkers, MD; Jos R.T.C. Roelandt, MD, PhD

A 65-year-old woman complained of nocturnal dyspnea, a period of stabbing pain between the shoulder blades, and swollen ankles that had persisted for 3 days. Physical examination revealed an irregular heart rate of 120 bpm; a blood pressure of 140/90 mm Hg in both arms; basal crepitations over both lungs; a grade 3/6 diastolic murmur maximal at the left sternal border; no abnormalities of the abdominal region; normal pulses of the radial, femoral, and carotid arteries; and ankle edema. An ECG showed atrial flutter with variable ventricular response and normal QRS-T complexes. Complete blood cell count, renal and hepatic function tests, and serological studies gave normal results. Chest radiograph showed an enlarged heart, an elongated aorta, normal lungs, and thoracic kyphosis. Transthoracic echocardiography revealed a dilated ascending aorta, a dilated left ventricle with an end-diastolic diameter of 60 mm and an end-systolic diameter of 50 mm, trace mitral regurgitation, and 4+ aortic regurgitation. Angiography showed a dilated ascending aorta (70 mm), a dilated descending thoracic and abdominal aorta (50 mm), and 3+ aortic regurgitation with good left ventricular function. Selective coronary angiography failed because of the abnormal size of the aorta.

The patient was transferred to our institution for further evaluation and therapy. Suprasternal transthoracic echocardiography suggested an aortic dissection near the aortic arch

(Figure 1), which could explain the episode of stabbing pain between the shoulder blades. Transesophageal echocardiography revealed normal atrial and ventricular dimensions; a dilated ascending aorta (diameter at root 70 mm), with possible dissection in the aortic arch, although no entry side or mobile dissection flap could be identified (Figure 2); and 4+ aortic regurgitation and mural thickening (plaque or thrombus, maximal thickness 20 mm) of the descending aorta. Contrast-enhanced MR angiography revealed an aberrant right subclavian artery (arteria lusoria) originating from the aortic arch below the left subclavian artery (Figure 3). The right subclavian artery crossed from its origin in the aortic arch just medial of the aortic arch to the right side, mimicking an intimal dissection flap (Figure 4). Selective coronary angiography revealed normal coronary arteries. The patient was referred for surgical correction. The ascending aorta and aortic arch were replaced by a vascular prosthesis. The distal anastomosis of the prosthesis was made between the origin of the left carotid artery and the left subclavian artery. Both the right and left carotid arteries were reimplemented in the prosthesis. Because the aortic valve morphology was normal, the aortic incompetence was repaired by reducing the sinotubular junction to its normal dimension. Postoperative recovery was uncomplicated.

---

From the Departments of Cardiology and Cardiopulmonary Surgery (J.A.B.), Erasmus University Medical Center, Rotterdam, Netherlands.

Correspondence to M. Janssen, MD, PhD, Department of Cardiology, Heartcenter Rotterdam, Zuiderziekenhuis, Groene Hilledijk 315, 3075 EA Rotterdam, Netherlands. E-mail janssen.loon@ironet.nl

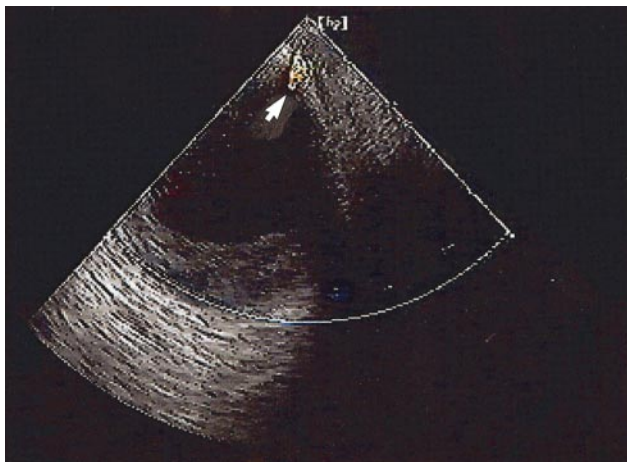
The editor of Images in Cardiovascular Medicine is Hugh A. McAllister, Jr, MD, Chief, Department of Pathology, St Luke's Episcopal Hospital and Texas Heart Institute, and Clinical Professor of Pathology, University of Texas Medical School and Baylor College of Medicine.

*Circulation* encourages readers to submit cardiovascular images to Dr Hugh A. McAllister, Jr, St Luke's Episcopal Hospital and Texas Heart Institute, 6720 Bertner Ave, MC1-267, Houston, TX 77030.

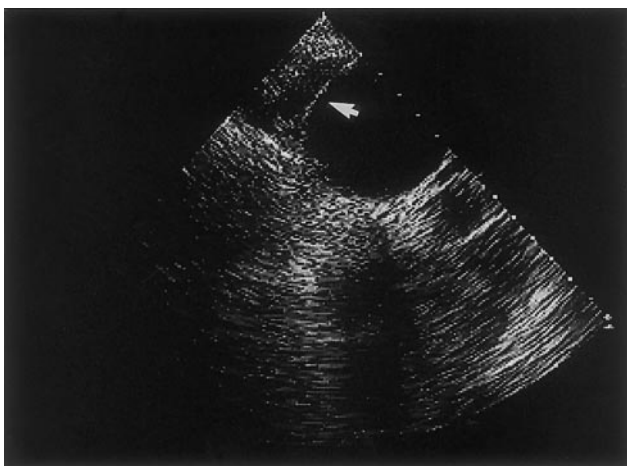
(*Circulation*. 2000;101:459-460.)

© 2000 American Heart Association, Inc.

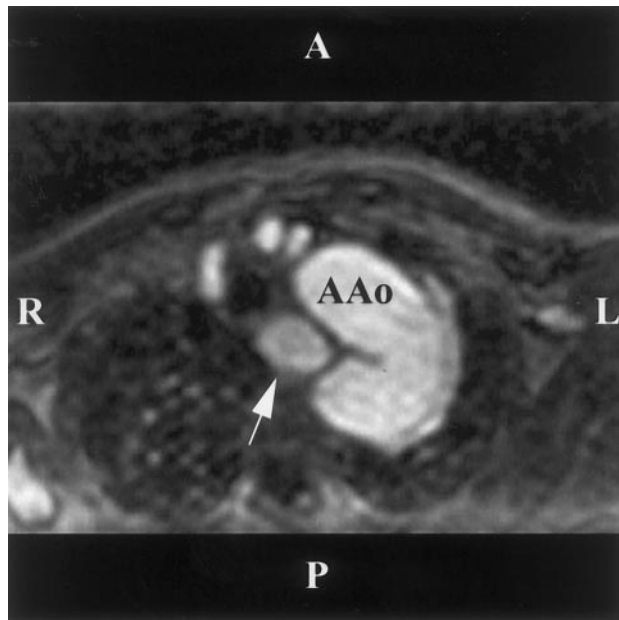
*Circulation* is available at <http://www.circulationaha.org>



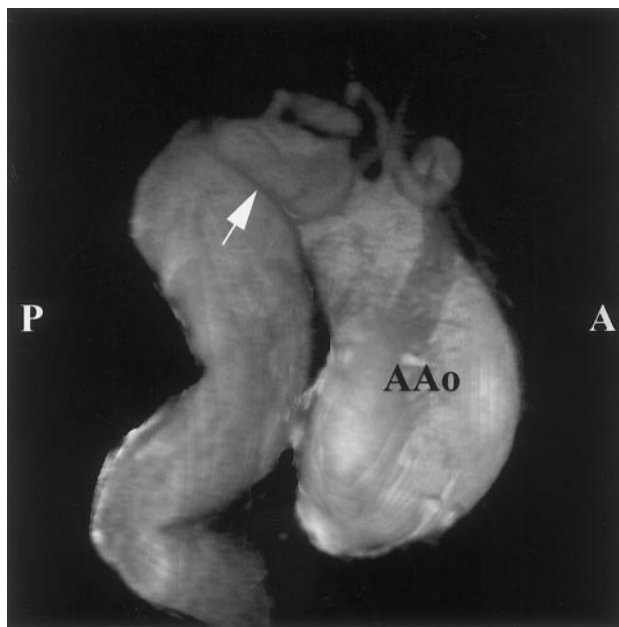**Figure 1.** Suprasternal view of ascending aorta obtained by transthoracic echocardiography showing a double lumen (arrow) suggestive of aortic dissection.



**Figure 2.** Transesophageal echocardiography of ascending aorta showing a double contour, further supporting suggestion of aortic dissection (arrow).



**Figure 3.** Contrast-enhanced MR angiography. Axial slice through aortic arch is shown. Aberrant right subclavian artery (arrow) originating from descending aorta mimics intimal flap. AAo indicates ascending aorta; A, anterior; P, posterior; L, left; and R, right.



**Figure 4.** Contrast-enhanced MR angiography and 3D visualization with volume rendering. Right-sided view. Aberrant right subclavian artery (arrow) crosses from its origin in aortic arch just medial of aortic arch to right side between aneurysm of ascending (AAo) and descending aorta. A indicates anterior; P, posterior.