

Immunohistochemical evaluation of fibrillar components of the extracellular matrix of transversalis fascia and anterior abdominal rectus sheath in men with inguinal hernia

Avaliação imunoistoquímica dos componentes fibrilares na matriz extracelular da fáscia transversal e da bainha do músculo reto abdominal de homens portadores de hérnia inguinal

ROGÉRIO DE OLIVEIRA GONÇALVES, TCBC-RJ¹; EVANDRO DE MORAES E SILVA, TCBC-RJ²; GASPAR DE JESUS LOPES FILHO, TCBC-SP³

A B S T R A C T

Objective: to evaluate the role of fibrillar extracellular matrix components in the pathogenesis of inguinal hernias. **Methods:** samples of the transverse fascia and of the anterior sheath of the rectus abdominis muscle were collected from 40 men aged between 20 and 60 years with type II and IIIA Nyhus inguinal hernia and from 10 fresh male cadavers (controls) without hernia in the same age range. The staining technique was immunohistochemistry for collagen I, collagen III and elastic fibers; quantification of fibrillar components was performed with an image analysis processing software. **Results:** no statistically significant differences were found in the amount of elastic fibers, collagen I and collagen III, and the ratio of collagen I / III among patients with inguinal hernia when compared with subjects without hernia. **Conclusion:** the amount of fibrillar extracellular matrix components did not change in patients with and without inguinal hernia.

Key words: Immunohistochemistry. Collagen. Extracellular matrix. Fascia. Hernia, inguinal.

INTRODUCTION

The incidence and prevalence of abdominal wall hernias remain essentially unknown, and from the operations for correction of abdominal wall hernias, inguinal hernia repair is the most commonly performed by the general surgeon¹.

It has been decades since the research directed at investigation of the factors involved in the weakness of the posterior wall of the inguinal canal began, in an attempt to answer the fundamental question involved in the pathogenesis of inguinal hernias, ie, if these are consequences of an excessive mechanical stress or local manifestation of a metabolic disturbance of extracellular matrix components²⁻⁶. All these works attributed to components of the extracellular matrix the property of conferring strength and integrity to the aponeuroses and fascias, these structures being considered by some authors^{7,8} as fundamental for the anatomical integrity of the posterior wall of the inguinal canal.

Inguinal hernias share a common feature: the emerging through the Fruchaud myopectineal orifice³. It is an opening in the lower abdominal wall closed just by the

transversalis fascia, whose resistance is conferred by collagen and elastic fibers – the two main extracellular matrix fibrillar components⁹.

The use of prostheses for correction of inguinal hernias has shown low recurrence rate and, therefore, is widely accepted, being the standard procedure for correction of inguinal hernias¹⁰. This raises the question whether the use of synthetic prostheses is a procedure that eliminates tension – considered the main element involved in recurrence – or indirectly addresses the metabolic changes present in the pathogenesis of inguinal hernias.

In view of the controversial findings in the literature about the possibility of inguinal hernia representing a metabolic manifestation of the connective tissue, we performed the present study in adult men with Nyhus type II and IIIA inguinal hernia¹¹. It aimed to analyze collagen I, collagen III and elastic fibers in the transversalis fascia and in the sheath of the rectus abdominis muscle of these patients, identifying possible quantitative changes of extracellular matrix fibrillar components in each of the types of hernias, when compared with individuals without hernia.

1. Surgical Clinic, Unifoa - Volta Redonda, Rio de Janeiro State – RJ, Brazil; 2. Anatomy, Unifoa - Volta Redonda, Rio de Janeiro State – RJ, Brazil; 3. Surgical Gastroenterology, UNIFESP – EPM, São Paulo, São Paulo State – SP, Brazil.

METHODS

This work was conducted at the Department of Surgical Gastroenterology, Hospital São Paulo, Federal University of São Paulo (UNIFESP), São Paulo City, São Paulo State – SP, Brazil. The Ethics Committee approved the research protocol (CEP 0801/08) without restrictions.

We used fragments of the transversalis fascia and of the anterior sheath of the rectus abdominis muscle obtained from biopsies during surgery for correction of inguinal hernias and during autopsies. We selected: 20 men aged between 20 and 60 years with Nyhus type II inguinal hernia (indirect hernia group); 20 men aged between 20 and 60 years of age with Nyhus type IIIA inguinal hernia (direct hernia group); and ten fresh cadavers of men aged between 20 and 60 years, without inguinal hernia (control group) (Table 1).

Of the selected patients, we excluded diabetics, smokers, patients with connective tissue diseases and with surgical risk equal to or greater than ASA III.

Histological Preparation

Once collected, the specimen was immediately washed in 0.9% saline and fixed in 10% paraformaldehyde solution (2.5ml), concentrated (5ml) Phosphate Buffer Solution (PBS) and distilled water (2 ml) and stored at 4°C temperature for two hours. After fixation, the solution was discarded with a pipette and 1ml of concentrated PBS plus 9ml distilled water were added, keeping it at 4°C for over 24 hours. Then the samples were embedded in paraffin. These histological preparations were subjected to immunohistochemistry staining, with the aim of evidencing the fibrillar constituents of the extracellular matrix.

All histological preparations obtained sections of the sheath of the rectus abdominis muscle and of the transversalis fascia were stained by immunohistochemical methods for collagen I, collagen III and elastin, using antibodies anticollagen type I, anticollagen type III and anti elastin.

Quantification of collagen and elastic fibers

In morphometric analysis, we used an image analysis and processing software, where the intensity

(orange-brown) and the extent of positive staining area (for collagen I, III and elastin) were obtained and the results were expressed in percentage/area. This procedure was performed for collagen I, III and elastin separately, with the aim of obtaining results of each.

Statistical Analysis

The following statistical tests were used: 1) Kruskal-Wallis test, to compare the concentration of fibrillar components in the transversalis fascia and the rectus abdominis sheath between groups and to evaluate the ratio of collagen I and III in different groups; 2) Mann-Whitney test, to compare the concentration of fibrillar components in the transversalis fascia and the rectus abdominis sheath between two groups, with and without hernia. In all tests we set at 0.05, or 5% ($\alpha=0.05$), the level of rejection of the null hypothesis, indicating significant values with Asterisks (*).

RESULTS

There was no statistically significant difference between the groups when comparing the concentration of collagen type I, collagen type III and elastic fibers in the transversalis fascia and the anterior sheath of the rectus abdominis muscle (Figure 1).

There was no statistically significant difference between groups when comparing the collagen type I and type III ratio (collagen I / III) in the transversalis fascia and the anterior sheath of the rectus abdominis muscle (Table 2).

There being no statistical significant differences between the type II Nyhus (indirect) and the type IIIA Nyhus (direct) hernia groups, and in order to increase the sample number with hernias, we compared the groups with and without hernia and found no statistically significant difference (Table 3).

DISCUSSION

Anatomical changes, as well anatomical and congenital alterations, and those promoting increased

Table 1 - Distribution of patients in the groups by age range.

Age range (in years)	Nyhus type II Indirect hernia		Nyhus type IIIA Direct hernia		Control without hernia	
	(number)	%	(number)	%	(number)	%
20 a 30	10	50%	1	5%	7	70%
31 a 40	2	10%	4	20%	1	10%
41 a 50	4	20%	6	30%	1	10%
51 a 60	4	20%	9	45%	1	10%
Total	20	100%	20	100%	10	100%

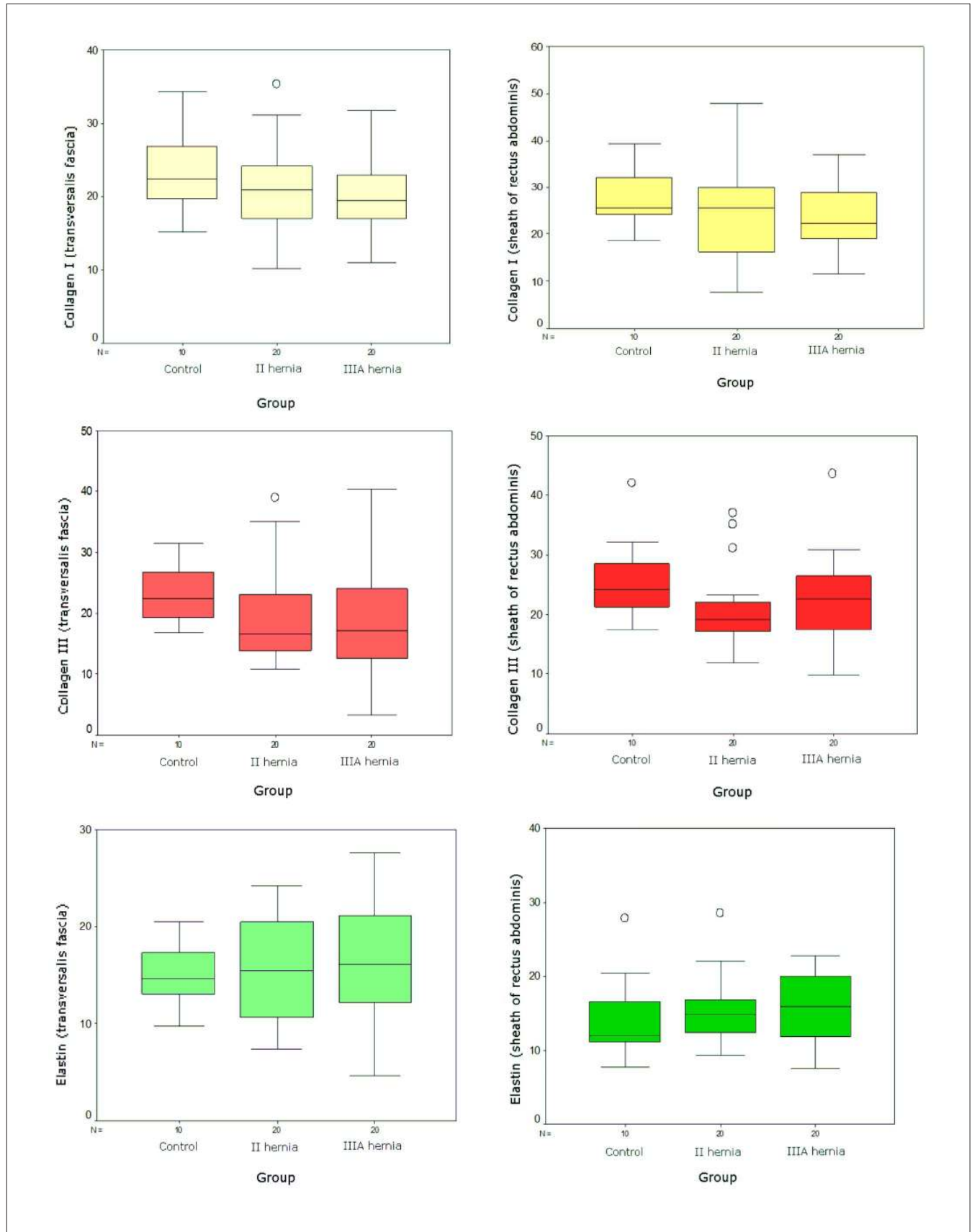


Figure 1 - Boxplot of the concentration of fibrillar components (collagen type I, collagen type III and elastic fibers) in the transversalis fascia and sheath of the rectus abdominis muscle of the control group, Nyhus type II hernia and Nyhus type IIIA hernia.

Table 2 - Comparison of the ratio between collagen fibers type I and type III in patients with type II (indirect) inguinal hernias, type IIIA (direct) inguinal hernias and controls corpses (without hernia).

Colagen I/Colagen III	Group	n	Average	Standard Deviation	Minimum	Maximum
Total		50	1.2	0.6	0.5	3.3
Transversalis Fascia	Indirect hernia	20	1.2	0.5	0.5	2.4
	Direct hernia	20	1.3	0.7	0.5	3.3
	Control	10	1.1	0.3	0.6	1.8
	Kruskal-Wallis test: p=valor=0.648					
Sheath of the Rectus Abdominis	Total	50	1.2	0.5	0.4	3.6
	Indirect hernia	20	1.3	0.7	0.4	3.6
	Direct hernia	20	1.1	0.3	0.5	1.7
	Control	10	1.1	0.3	0.7	1.7
Kruskal-Wallis test: p=valor=0.879						

intra-abdominal pressure are factors already established in the literature as participants in the pathogenesis of inguinal hernias^{4,12-14}. Nevertheless, in recent years a new concept has aroused interest in surgeons, the presence of alterations in the connective tissue of patients with inguinal hernias as a predisposing factor to its development.

Current knowledge of the biochemical and metabolic pathways that affect the pathogenesis of inguinal hernia are controversial. This work is based on the possibility of an association between changes in the proportion and/or amounts of one of the fibrillar components, elastin, collagen I and collagen III, and the weakening of the transversalis fascia involved in the pathophysiology of herniogenesis.

Table 3 - Comparison of the amount of collagens type I, type III and elastic fibers in patients with inguinal hernias (indirect or direct) and controls (corpse without hernia).

Fiber	Group	n	Average	Standard Deviation	Minimum	Maximum
Collagen fiber type I (Transversalis Fascia)	Total	50	21.3	6.1	10.2	35.2
	With hernia	40	20.8	5.9	10.2	35.2
	Control	10	23.5	6.4	15.2	34.3
p=0.254						
Collagen fiber type I (Sheath of the Rectus Abdominis)	Total	50	25.1	8.2	7.7	47.9
	With hernia	40	24.4	8.5	7.7	47.9
	Control	10	27.7	6.6	18.6	39.4
p=0.296						
Collagen fiber type III (Transversalis Fascia)	Total	50	19.8	7.6	3.3	40.4
	With hernia	40	19.0	8.0	3.3	40.4
	Control	10	22.8	4.9	16.7	31.6
p=0.326						
Collagen fiber type III (Sheath of the Rectus Abdominis)	Total	50	22.4	7.2	9.8	43.5
	With hernia	40	21.6	7.1	9.8	43.5
	Control	10	25.8	7.0	17.5	42.0
p=0.426						
Elastic fiber (Transversalis Fascia)	Total	50	15.6	5.3	4.6	27.6
	With hernia	40	15.8	5.8	4.6	27.6
	Control	10	14.9	3.4	9.8	20.5
p=0.676						
Elastic fiber (Sheath of the Rectus Abdominis)	Total	50	15.3	4.7	7.5	28.5
	With hernia	40	15.5	4.4	7.5	28.5
	Control	10	14.6	5.9	7.6	27.8
p=0.344						

Mann-Whitney Test

The first study to investigate the association of inguinal hernia and defective collagen metabolism was performed by Read¹⁵, who described thinner rectus abdominis aponeurosis and with less weight per area in patients with direct hernia. He and other authors believe that the process that influences the amount of collagen in these aponeuroses also reflects in the transversalis fascia, making it fragile and leading to hernia formation¹⁵⁻¹⁷.

The controls of the studies cited above that provided samples of the anterior sheath of the abdominal rectus muscle were patients operated on through median infraumbilical incisions for treating certain conditions that also present with disorders of connective system, such as abdominal aortic aneurysms, rendering this comparison inadequate. In this experiment, the control group consisted of corpses without inguinal hernia, which allowed the samples of the anterior sheath of the rectus abdominis and transversalis fascia to be collected directly from the inguinal region.

Studies using the transversalis fascia of patients with inguinal hernia for quantitative evaluation of collagen^{2,6,17} are controversial.

Peacock and Madden performed biochemical studies to quantify the collagen through the measurement of hydroxyproline in the transversalis fascia of patients with recurrent inguinal hernia and compared with the fascia on the same side, but found no significant difference between the side with and without the hernia¹⁸.

Bellón *et al.* conducted a more detailed study in which they assessed, the ultrastructure of the transversalis fascia by electron microscopy, determined the tissue amount of hydroxyproline through immunohistochemical staining, the percentage of type I and type III collagens and the presence of metalloproteinases in the transversalis fascia of patients with direct and indirect inguinal hernia. They found a most abundant extracellular matrix in patients with direct inguinal hernia, which they attributed to increased expression of metalloproteinases in patients with direct hernia¹⁹.

Wolwacz *et al.* used computerized assessment to quantify the collagen fibers of the transversalis fascia of patients with direct hernia stained by picosirius-polarization histochemical technique, and compared them with cadavers without hernia. They showed that the average percentage area of collagen in patients with hernia was half the area of the controls²⁰. A similar study conducted by the authors of this study showed no statistically significant differences between patients with direct hernia, indirect one and controls without hernia²¹.

There is a close association between the collagen and elastic components of the transversalis fascia, inferring an integrated action of these two components in the resistance of the posterior wall of the inguinal canal. Some studies support the hypothesis that the inelastic deformation of collagen, also altered in quantity, accompanied by quantitative and structural changes of

the elastic fiber system, would be responsible for the formation of inguinal hernia^{2,22}. However, few studies have concurrently evaluate collagen and elastic fibers in patients with inguinal hernia.

There have been demonstrated a significant decrease in collagen and an increase in the amount of elastic fibers in the transversalis fascia of patients with direct inguinal hernia patients when compared to indirect inguinal hernia. Nonetheless, this increase in elastic fibers would not raise the compliance of the elastic tissue, as these fibers display structural changes, especially with aging^{2,23}. Changes in the density of collagen in the skin of patients with hernia were demonstrated when compared to the same region of the skin of patients without hernia. However, no difference in the distribution density of the elastic fiber was observed between the two groups¹².

Ozdogan *et al.* used optical microscopy to analyze the degree of density of staining of collagen and elastic fibers in the skin, rectus sheath, transversalis fascia and peritoneum of patients with direct and indirect inguinal hernia and compared with controls who underwent cholecystectomy¹³. Samples of the sheath of the rectus abdominis muscle of the controls demonstrated a high degree of staining for collagen and elastic fibers when compared with the hernia group. No difference was found in samples from other tissues and between groups of direct and indirect hernia.

The difficulties in analyzing these works are initially in selecting the type of hernias, as patients with type II, IIIA, IIIB and IIIC hernias were used indiscriminately, and in the use of patients of both genders, since women may show connective tissue changes related to hormonal disorders caused by pregnancy and the use of hormones²³. Furthermore, the use of elderly patients may also have affected results, as there are changes of collagen and elastic fibers in patients aged over 60 years^{23,24}.

In this study, we used immunohistochemical staining to measured type I and type III collagens and elastic fibers in the transversalis fascia and the anterior rectus sheath. Their values were quantified by computer image processing, whose applicability and effectiveness have been proven^{19,25}, and found no significant differences between patients with and without hernia.

The tensile strength and stability of the connective tissue depend on the amount and variation in the proportion of collagens types I and III; in the skin this ratio is 4:1 and the increased in type III collagen leads to changes in the physical properties of the abdominal wall, facilitating the formation of hernias²⁶.

There is literature evidence that the ratio of collagen I / III is decreased in the transversalis fascia, hernia sac and skin of patients with recurrent inguinal and incisional hernia²⁷. However, in primary inguinal hernia the evidence is less clear. While some studies have shown that the ratio of collagen I / III in skin samples of patients with hernia is lower than in controls without hernia^{9,10}, other authors²⁸ showed no

differences in the ratio of collagen I / III in the transversalis fascia of patients with and without inguinal hernia.

Here we measured the ratio of collagen I / III in the transversalis fascia and in the anterior sheath of the abdominis rectus muscle of patients with Nyhus type II and IIIA inguinal hernias, finding no statistically significant differences between patients and controls.

The integrity of the transversalis fascia depends on the renewal process of its fibrillar, collagenous and elastic

components, and the involvement of other extracellular matrix constituents – proteoglycans, glycoproteins and metalloproteinases. Further studies are needed to quantify these constituents, adopting strict selection criteria for groups with hernia and controls to elucidate the pathogenesis of inguinal hernia in adults.

Our research shows that the amount of fibrillar extracellular matrix components did not change in patients with and without inguinal hernia.

R E S U M O

Objetivo: avaliar a participação dos componentes fibrilares da matriz extracelular na etiopatogenia das hérnias inguinais. **Métodos:** foram retiradas amostras da fásia transversal e da bainha anterior do músculo reto abdominal de 40 homens na faixa etária entre 20 e 60 anos, portadores de hérnia inguinal tipo II e IIIA de Nyhus e de 10 controles constituído por cadáveres frescos, na mesma faixa etária, sem hérnia. A técnica de coloração foi a imunoistoquímica para colágeno I, colágeno III e fibras elásticas e a quantificação dos componentes fibrilares foi realizada através de sistema computadorizado e software de processamento e análise de imagem. **Resultados:** não foram encontradas diferenças estatisticamente significantes na quantidade de fibras elásticas, colágeno I e colágeno III, e na proporção de colágeno VIII entre os pacientes portadores de hérnia inguinal em comparação com indivíduos sem hérnia. **Conclusão:** a quantidade dos componentes fibrilares da matriz extracelular não se alterou nos pacientes com e sem hérnia inguinal.

Descritores: Imunoistoquímica. Colágeno. Matriz extracelular. Fásia. Hérnia inguinal.

REFERENCES

1. Rutkow IM. Surgical operations in the United States. Then (1983) and now (1994). Arch Surg. 1997;123(9):132-90.
2. Rodrigues Júnior AJ, Rodrigues CJ, da Cunha AC, Jin Y. Quantitative analysis of collagen and elastic fibers in the transversalis fascia in direct and indirect inguinal hernia. Rev Hosp Clin Fac Med Sao Paulo. 2002;57(6):265-70.
3. Read RC. Attenuation of the rectus sheath in inguinal herniation. Am J Surg. 1970;120(5):610-4.
4. Wagh PV, Read RC. Collagen deficiency in rectus sheath of patients with inguinal herniation. Exp Biol Med. 1971;37(2):382-4
5. Conner WT, Peacock EE Jr. Some studies on the etiology of inguinal hernia. Am J Surg. 1973;126(6):732-5.
6. Cannon DJ, Read RC. Metastatic emphysema: a mechanism for acquiring inguinal herniation. Ann Surg. 1981;194(3):270-8.
7. Baradi AF, Heslop JH, Rao NS. Peritoneal fine structure of inguinal hernia: a scanning electron microscope study. Histol Histopathol. 1986;1(1):89-92.
8. Harrison PW. Inguinal hernia: a study of the principles involved in the surgical treatment. Arch Surg. 1922;4(3):680-9.
9. Goffi FS, Leite GM, Pinto PEL. Alguns aspectos da etiopatogenia das hérnias inguinais. Rev Paul Med. 1953;43:29-45.
10. Silva AL, Barbosa CA, Souza PL, Vieira RG. Uso do saco herniário autólogo no reforço das hernioplastias incisional e inguinal. RBM rev bras med. 2004;61:273-8.
11. Nyhus LM. Individualization of hernia repair: a new era. Surgery. 1993;114(1):1-2.
12. Bórquez PM, Garrido LO, Manterola CD, Peña PS, Schlageter CT, Orellana JJC, et al. Estudio de fibras colágenas y elásticas del tejido conjuntivo de pacientes con y sin hérnia inguinal primaria. Rev méd Chile. 2003;131(11):1273-9.
13. Ozdogan M, Yildiz F, Gurer A, Orhun S, Kulacoglu H, Aydin R. Changes in collagen and elastic fiber contents of the skin, rectus sheath, transversalis fascia and peritoneum in primary inguinal hernia patients. Bratisl Lek Listy. 2006;107(6-7):235-8.
14. Watson LF. Embryologic and anatomic consideration in etiology of inguinal and femoral hernias. Am J Surg. 1938;42(3):695-703.
15. Read RC. Pre-extraperitoneal approach to inguinofemoral herniorrhaphy. Am J Surg. 1967;114(5):672-8.
16. Berliner SD. An approach to groin hernia. Surg Clin North Am. 1984;64(2):197-213.
17. Wagh PV, Leverich AP, Sun CN, White HJ, Read RC. Direct inguinal herniation in men: a disease of collagen. J Surg Res. 1974;17(6):425-33.
18. Peacock EE Jr, Madden JW. Studies on the biology and treatment of recurrent inguinal hernia. II. Morphological changes. Ann Surg. 1984;179(5):567-71.
19. Bellón JM, Buján J, Honduvilla NG, Jurado F, Gimeno MJ, Turnay J, et al. Study of biochemical substrate and role of metalloproteinases in fascia transversalis from hernial processes. Eur J Clin Invest. 1997;27(6):510-6.
20. Wolwacz Júnior I, Trindade MRM, Cerski CT. O colágeno em fásia transversal de pacientes com hérnia inguinal direta submetidos à videolaparoscopia. Acta cir bras. 2003;18(3):196-202.
21. Gonçalves RO, Silva EM, Marques TC, Lopes Filho GJ. Avaliação histoquímica quantitativa do colágeno na fascia transversalis e na bainha anterior do músculo reto abdominal em doentes com hérnia inguinal. Rev Col Bras Cir. 2003;30(4):286-92.
22. Quintas ML. Alterações do sistema de fibras elásticas no ligamento interfoveolar do homem com envelhecimento [tese]. São Paulo: Universidade de São Paulo, Faculdade de Medicina; 1998.
23. Quintas ML, Rodrigues CJ, Yoo JH. Age related changes in the elastic fiber system of the interfoveolar ligament. Rev Hosp Clin Fac Med Sao Paulo. 2000;55(3):83-6.
24. Novelli MD, Barreto E, Matos D, Saad SS, Borra RC. Aplicação de processamento de imagens por computador na quantificação das variáveis histopatológicas da reparação tecidual de anastomose colóclicas em cães. Rev Ass Med Bras. 1997;43(4):277- 82.
25. Calil MA. Avaliação quantitativa do colágeno da pele de ratas castradas após o uso de estrogênio, progesterônio e tamoxifeno

- [dissertação]. São Paulo: Universidade Federal de São Paulo, Escola Paulista de Medicina; 1999.
26. Liberatori Filho AW. Estudo histomorfométrico de cardiomiócitos e matriz colágena do ventrículo esquerdo de ratas albinas durante o ciclo gravídico-puerperal [tese]. São Paulo: Universidade Federal de São Paulo, Escola Paulista de Medicina; 1999.
27. Junqueira LC, Carneiro J. Histologia básica. 9ª ed. Rio de Janeiro: Guanabara-Koogan; 1999.
28. Tsuji T, Hamada T. Age-related changes in human dermal elastic fibres. *Br J Dermatol.* 1981;105(1):57-63.

How to cite this article:

Gonçalves RO, Silva EM, Lopes Filho GJ. Immunohistochemical evaluation of fibrillar components of the extracellular matrix of transversalis fascia and anterior abdominal rectus sheath in men with inguinal hernia. *Rev Col Bras Cir.* [periódico na Internet] 2014;41(1). Disponível em URL: <http://www.scielo.br/rcbc>

Address for correspondence:

Rogério de Oliveira Gonçalves
E-mail: r.gov@uol.com.br

Received on 18/10/2012

Accepted for publication 18/12/2012

Conflict of interest: none.

Source of funding: none.